

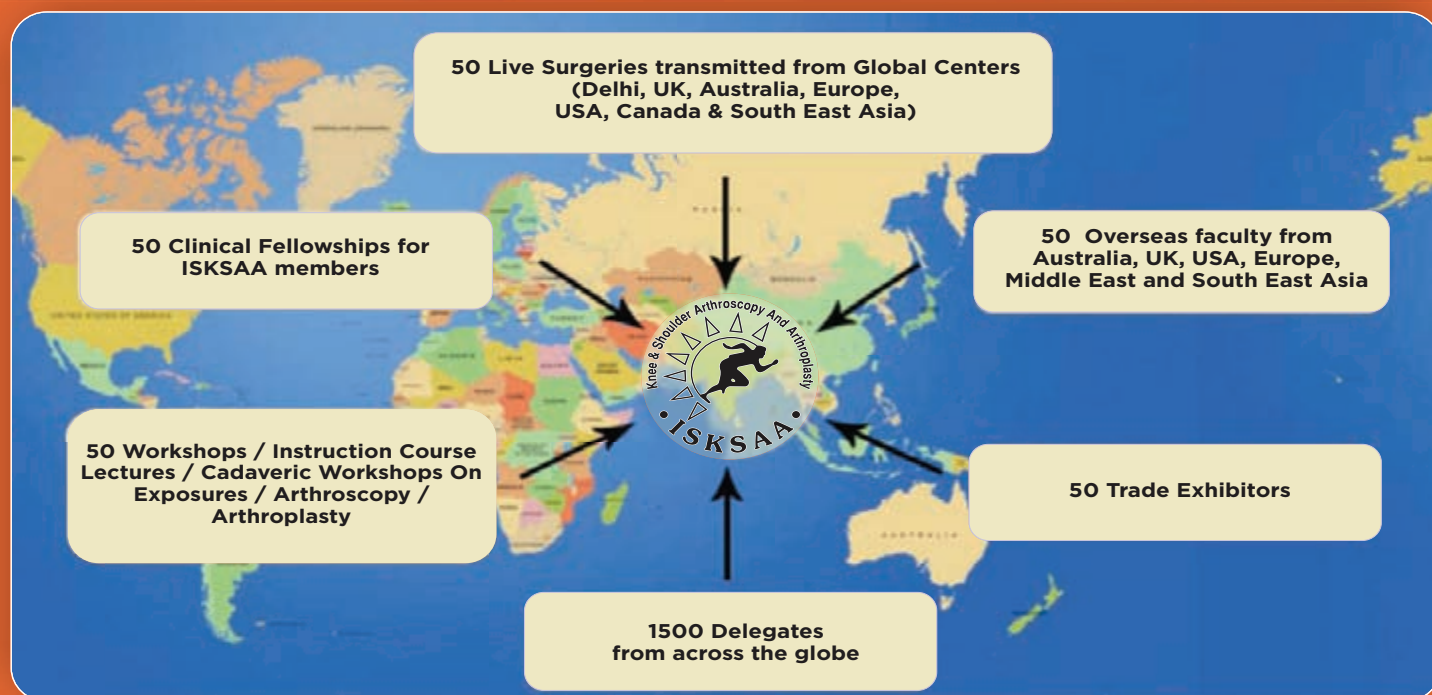# ISKSAA GLOBAL SUMMIT 2016


## 10th International Congress of ISKSAA



Preconference Cadaveric Workshops: 20th November 2016, Delhi / NCR  
Conference: 21st - 23rd November 2016, The Leela Hotel & Residences, Gurgaon, Delhi/NCR



**ISKSAA SECRETARIAT**  
**Dr Pushpinder Bajaj**  
ISKSAA PRESIDENT  
B-7/5, SAFDARJUNG ENCLAVE, NEW DELHI -110029, INDIA  
TEL : +91-11-41057555 / 41057556 / 41057557 MOBILE : +91-9811056525  
EMAIL : isksaapresident@gmail.com  
[www.isksaa.com/isksaa2016](http://www.isksaa.com/isksaa2016)



JOURNAL OF ARTHROSCOPY AND JOINT SURGERY

# JAJIS

Official Journal of the International Society for Knowledge for Surgeons on Arthroscopy and Arthroplasty (ISKSAA)

**Indexed in Scopus**

Volume 3 Number 1 January–April 2016

ISSN: 2214-9635

Available online at [www.sciencedirect.com](http://www.sciencedirect.com)

**ScienceDirect**

JAJIS  
VOLUME 3  
NUMBER 1  
JANUARY-APRIL 2016  
PAGES 1-42  
ELSEVIER



## ISKSAA International Society for Knowledge for Surgeons on Arthroscopy and Arthroplasty

ISKSAA (International Society for Knowledge for Surgeons on Arthroscopy and Arthroplasty) is a society of orthopaedic surgeons from around the world to share and disseminate knowledge, support research and improve patient care in Arthroscopy and Arthroplasty. We are proud to announce that ISKSAA membership has crossed the **1200** mark (India & Overseas) making it the **fastest growing Orthopaedic Association in the country** in just over 3 years of its inception. With over **190000 hits from over 139 countries** on the website [www.isksaa.com](http://www.isksaa.com) & more and more interested people joining as members of ISKSAA, we do hope that ISKSAA will stand out as a major body to provide opportunities to our younger colleagues in training, education and fellowships.

### Our Goals.....

- To provide health care education opportunities for increasing cognitive and psycho-motor skills in Arthroscopy and Arthroplasty
- To provide CME programs for the ISKSAA members as well as other qualified professionals.
- To provide Clinical Fellowships in Arthroscopy and Arthroplasty
- To provide opportunities to organise and collaborate research projects
- To provide a versatile website for dissemination of knowledge

### ISKSAA Life Membership

The membership is open to Orthopaedic Surgeons, Postgraduate Orthopaedic students and Allied medical personal interested in Arthroscopy & Arthroplasty.

### Benefits of ISKSAA Life membership include....

- Eligibility to apply for **ISKSAA's Prestigious Fellowship Programme**. We are finalising affiliations with ESSKA, ISAKOS, BOA, BASK, Wrightington and FLINDERS MEDICAL CENTRE, IMRI AUSTRALIA to provide more **ISKSAA Fellowships** in India, UK, USA, Australia and Europe. **We awarded 14 ISKSAA Fellowships in Feb 2013, 6 ISKSAA IMRI fellowships in Feb 2014, 54 ISKSAA fellowships in September 2014, 22 ISKSAA Wrightington MCh. fellowships in December 2014 and 40 ISKSAA Fellowships in October 2015 and are awaiting the results of ISKSAA Wrightington MCh. fellowships in December 2015.**
- **Free Subscription** of ISKSAA's official, SCOPUS INDEXED, peer reviewed, online scientific journal **Journal of Arthroscopy and Joint Surgery (JAJS)**.
- Only as a life member, you can enjoy the benefit of **reduced Congress charges** in **ISKSAA Global Summit 2016 and participate in the Cadaveric workshops.**
- **Member's only section** on the website which has access to the conference proceedings and live surgeries of ISKSAA 2012, 2013 & 2014 along with a host of other educational material.
- Important opportunity for interaction with world leaders in Arthroscopy & Arthroplasty.
- Opportunity to participate in ISKSAA courses and workshops

To enjoy all the benefits & privileges of an ISKSAA member, you are invited to apply for the Life membership of ISKSAA by going to the membership registration section of the website and entering all your details electronically. All details regarding membership application and payment options are available ([www.isksaa.com](http://www.isksaa.com))

### ISKSAA GLOBAL SUMMIT 2016 FELLOWSHIPS

We are happy to announce **over 50 Clinical Fellowships** for ISKSAA 2016 Congress ranging from 2 weeks to 1 month in India and Abroad (UK, USA, Australia & Europe) only for ISKSAA Life members. Applications for Fellowships will open at [www.isksaa.com](http://www.isksaa.com) from **1<sup>st</sup> July 2016** and will close on **31<sup>st</sup> August 2016**. These fellowships will be focussed on Arthroscopy & Arthroplasty and Sports Medicine. Members with Submission or publication of an article in JAJS, completed an ISKSAA Indian Fellowship & earlier membership of ISKSAA will be preferred for the ISKSAA International Fellowships



Pharmaceuticals Pvt Ltd

Healthcare is our Inspiration

### Product Range

#### LM-VIT GOLD

Co-enzyme10, L-carnitine, L-Arginine  
Lycopene, DHA Combination Tablets

#### Calcidura

Calcium Citrate Malate, Cholecalciferol,  
Folic Acid Tablets

#### Cyfer tab/syp

Ferrous Ascorbate 100mg EI, Folic Acid 1.5mg  
Syp-Ferrous Ascorbate 30mg EI, Folic Acid .5mg/5ml

#### C-Bone Tablet

Cholecalciferol 60000 IU

#### Cefulor-500

Cefuroxime 500mg Tablets

#### DURACLAV (625/Dry Syrup)

Amoxicillin 500mg, Clavulanate 125mg  
Amoxicillin 200mg, Clavulanate 28.5mg/ 5ml

#### Flamazox-MR

Diclofenac 50mg, Paracetamol 325mg  
Chlorzoxazone 250mg Tablets

#### Flamazox Gel

Diclofenac Diethylamine 1.16% w/w. +  
Methyl Salicylate 10% w/w. + Menthol 5% w/w.  
+ Oleum Lini 3% w/w.

#### Edcort-6

Deflazacort 6mg

#### Lorcaine Gel

Oxetacaine, Magnesium, Aluminium Hyd  
Anesthetic Antacid Gel

#### Mobilio

Tramadol 37.5 mg + Paracetamol 325mg

#### LM-VIT Cap/Syp

Lycopene with Multivitamins  
Multimineral Combination capsules

#### Seradura

Nimesulide 100mg, Serratiopeptidase 15mg tablets

#### Seradura-AP

Aceclofenac 100mg, Paracetamol 325 mg,  
Serratiopeptidase 15mg Tablets

#### Rabidura-DSR

Rabiprazole 20mg, Domperidone 30mg  
(10mgIR + 20mg SR) Capsules

#### Skelafit

Collagen Peptide 10g, Glucosamine 1500mg  
Vit C 35mg Sachets

#### Mesofose

Co-enzyme10, L-carnitine, L-Arginine  
Lycopene, DHA Combination Tablets

#### Magic HP Kit

Amoxicillin 750mg 2 tab + Clarithromycin 500mg 2 tab  
Pantaprazole 40mg 2 cap Combipack

#### Edpro Granules

Whey Protein with DHA & GLA Powder

#### Ostopure

Diacerin 50mg, Glucosamine 750mg,  
MSM 250 mg Tablets

#### Mecosure Cap

Pregabalin 75mg, Methylcobalamin 750mg Cap

#### Durazol LS

Pantaprazole 40mg + Levosulpiride 75mg SR Cap

#### BMP Forte

Cissus Quadrangularis 750mg, withania somnifera 100mg,  
Embllica Officinalis 50mg, Commiphora wightii 100mg Tablets

### Recent Introduction

## Vezeal

(Co Q10 with Amino acids)

## Collagel

(Collagen Peptide 10gm / 25ml)

XYATA LIFESCIENCES LTD.  
HONG KONG  
www.xyata.hk



XYATA LIFESCIENCES PVT. LTD.  
INDIA  
www.xyata.in

*offers the highly specialized range*



## FOR OSTEOARTHRITIS MANAGEMENT

Cross Linked

**BIOVISC**  
**ORTHO SINGLE** PFS

Hyaluronic Acid Inj. 3ml (90mg / 3ml)

Optimum Volume, Sustained Effect

90 High Concentration HA

Cross-Linked

High Molecular Weight

**HYNEES**<sup>®</sup>  
PFS

Sodium Hyaluronate Inj. 2ml (10mg / ml)

For effective management of osteoarthritis

Non Avian Source

High Molecular Weight

## FOR OSTEOPOROSIS MANAGEMENT

Recombinant Human Parathyroid Hormone (1-34)

**ELEVOSTEO**<sup>®</sup>  
Teriparatide Injection (rDNA origin)

**ELEVATING OSTEOGENESIS**

Increases Bone Formation

Reduces Risk of Fractures

**ZOLVOID**<sup>®</sup>

Zoledronic Acid Infusion 5mg/100ml

The **GOLD STANDARD** in Osteoporosis Treatment

Once A Year Dose


Effective and Safe

# For Comprehensive Mobility Solutions

A WHO - GMP Certified Company

NATIONAL TOLL FREE HELPLINE: 1800 1111 55

An ISO : 9001 - 2008 Certified Company



# INTRODUCING PATENTED TECHNOLOGIES FOR INDIANS & ASIANS

Asian & Caucasian Size

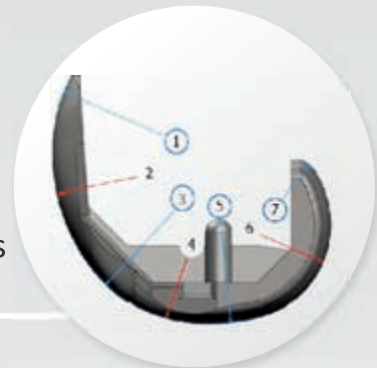


Asian Size    Caucasian Size




High Flexion Implants

The 7-Radius Patented Femoral design reflects natural anatomy and functional principles




## LATITUD™

HIP SYSTEM | Freedom of Choice



Acetabular Cup System & Uncemented Stems



Bi-Polar Cup System & Cemented Stems

A fast growing brand in US and around the globe

Approved by : US FDA | CE European | TGA Australia SFDA  
China and Singapore | DCGI,India

Pursue Life™

### United States

Maxx Orthopedics Inc. 531 Plymouth Road, Suite 526, Plymouth Meeting, PA 19462, USA. W : www.maxxmed.com

### India Sales & Marketing

Meril Life Sciences India Pvt. Ltd. 512, Midas, Sahar Plaza, J.B. Nagar, Andheri East, Mumbai 400 059 Maharashtra. India.  
T : +91 22 4047 9797 W : www.merillife.com

# Journal of Arthroscopy and Joint Surgery

An official publication of International Society for Knowledge for Surgeons on Arthroscopy and Arthroplasty

(ISSN: 2214-9635)

Volume 3, Number 1, January–April 2016

## Aims and Scope

*Journal of Arthroscopy and Joint Surgery* (JAJS) is committed to bring forth scientific manuscripts in the form of original research articles, current concept reviews, meta-analyses, case reports and letters to the editor. The focus of the Journal is to present wide-ranging, multi-disciplinary perspectives on the problems of the joints that are amenable with Arthroscopy and Arthroplasty. Though Arthroscopy and Arthroplasty entail surgical procedures, the Journal shall not restrict itself to these purely surgical procedures and will also encompass pharmacological, rehabilitative and physical measures that can prevent or postpone the execution of a surgical procedure. The Journal will also publish scientific research related to tissues other than joints that would ultimately have an effect on the joint function.

## Author inquiries

You can track your submitted article at <http://www.elsevier.com/track-submission>. You can track your accepted article at <http://www.elsevier.com/trackarticle>. You are also welcome to contact Customer Support via <http://support.elsevier.com>

## Copyright

© 2016, International Society for Knowledge for Surgeons on Arthroscopy and Arthroplasty. Published by Reed Elsevier India Pvt. Ltd. All rights reserved. Papers accepted for publication become the copyright of *International Society for Knowledge for Surgeons on Arthroscopy and Arthroplasty*, and authors will be asked to sign a transfer of copyright form, on receipt of the accepted manuscript by Elsevier. This enables the Publisher to administer copyright on behalf of the Authors, whilst allowing the continued use of the material by the Author for scholarly communication.

**This journal and the individual contributions contained in it are protected under copyright by Elsevier Ltd., and the following terms and conditions apply to their use:**

## Photocopying

Single photocopies of single articles may be made for personal use as allowed by national copyright laws. Permission of the Publisher and payment of a fee is required for all other photocopying, including multiple or systematic copying, copying for advertising or promotional purposes, resale, and all forms of document delivery. Special rates are available for educational institutions that wish to make photocopies for non-profit educational classroom use.

For information on how to seek permission visit <http://www.elsevier.com/permissions> or call: (+44) 1865 843830 (UK) / (+1) 215 239 3804 (USA).

## Derivative Works

Subscribers may reproduce table of contents or prepare lists of articles including abstracts for internal circulation within their institutions. Permission of the Publisher is required for resale or distribution outside the institution. Permission of the Publisher is required for all other derivative works, including compilations and translations (please consult [www.elsevier.com/permissions](http://www.elsevier.com/permissions)).

## Electronic Storage or Usage

Permission of the Publisher is required to store or use electronically any material contained in this journal, including any article or part of an article (please consult [www.elsevier.com/permissions](http://www.elsevier.com/permissions)).

Except as outlined above, no part of this publication may be reproduced, stored in a retrieval system or transmitted in any form or by any means, electronic, mechanical, photocopying, recording or otherwise, without prior written permission of the Publisher.

## Notice

No responsibility is assumed by the Publisher for any injury and/or damage to persons or property as a matter of products liability, negligence or otherwise, or from any use or operation of any methods, products, instructions or ideas contained in the material herein. Because of rapid advances in the medical sciences, in particular, independent verification of diagnoses and drug dosages should be made.

Although all advertising material is expected to conform to ethical (medical) standards, inclusion in this publication does not constitute a guarantee or endorsement of the quality or value of such product or of the claims made of it by its manufacturer.

## Subscription information

The *Journal of Arthroscopy and Joint Surgery* (ISSN: 2214-9635) is published thrice a year. The annual price for **individual subscription** based in India is **INR 3600**; and for international subscribers, the annual price is **USD 60**. For **institutional subscription** within and outside India, please contact the Publishers office at [journals.india@elsevier.com](mailto:journals.india@elsevier.com).

Further information is available on this journal and other Elsevier products through Elsevier's website (<http://www.elsevier.com>). Subscriptions are accepted on a prepaid basis only and are entered on a calendar year basis. Issues are sent by standard mail. Priority rates are available upon request. Claims for missing issues should be made within six months of the date of dispatch.

**Orders, claims, advertisement and journal enquiries:** please contact

**Editorial Office:** Dr Pushpinder Singh Bajaj, Bajaj Specialist Clinics, B-7/5 Safdarjung Enclave, New Delhi – 110029. Tel: 41057555 / 41057556 / 41057557. Email: [psbajaj@hotmail.com](mailto:psbajaj@hotmail.com).

**Publishing Office:** Elsevier, A division of Reed Elsevier India Pvt. Ltd., 14th Floor, Building No.10B, DLF Cyber City, Phase-II, Gurgaon-122002, Haryana, India. Email: [journals.india@elsevier.com](mailto:journals.india@elsevier.com)



# Journal of Arthroscopy and Joint Surgery

An official publication of International Society for Knowledge for Surgeons on Arthroscopy and Arthroplasty

(ISSN: 2214-9635)

Volume 3, Number 1, January–April 2016

## Editor-in-Chief

PROF RAVI GUPTA Chandigarh

MR SANJEEV ANAND UK

## Executive Editor

PROF LALIT MAINI Delhi

## Managing Editor

DR PUSHPINDER BAJAJ Delhi

## Deputy Editor

DR AMITE PANKAJ Delhi

## Section Editors

### Trauma & Rehabilitation

DR ALEXANDER WOOD UK

### Hip

DR AJAY AGGARWAL USA

### Foot & Ankle

DR MUNEEESH BHATIA UK

### Training & Education

DR JANAK MEHTA Australia

### Arthroplasty

DR MANOJ SOOD UK

### Pediatric Orthopaedics

DR PARMANAND GUPTA Chandigarh

### Orthopaedic Oncology

DR MANISH PARUTHI Mumbai

### Elbow, Wrist & Hand

DR RAJ MURALI UK

### Shoulder

DR AMOL TAMBE UK

## Associate Editors

DR DINESH PATEL USA  
DR PONKY FIRER South Africa

PROF JEGAN KRISHNAN Australia  
DR GURINDER BEDI Delhi

DR RAJESH SETHI UK  
DR DINSHAW PARDIWALA Mumbai

## Editorial Board

PROF GIANNOUDIS UK  
PROF AMAR RANGAN UK  
DR KHALID MOHAMMAD New Zealand  
MR KAPIL KUMAR UK  
DR MAKARAM SRINIVASAN UK

DR V BHALAIK UK  
DR PUNEET MONGA UK  
DR TAOFEEK ADEYEMI Nigeria  
DR MS DHILLON Chandigarh  
DR VIVEK PANDEY Karnataka

DR SUNDARARAJAN Coimbatore  
DR ASHISH DEVGAN Rohtak  
DR RAJU EASWARAN Delhi  
DR RAHUL KHARE Delhi

## Advisory Board

DR ANDREAS SETTJE Germany  
DR ANANT JOSHI Mumbai  
DR ASHOK RAJGOPAL Gurgaon  
DR ASHISH BABULKAR Pune  
DR ASIT SHAH USA  
DR ANIL BHAT Karnataka  
MR BINOD SINGH UK  
DR BINU THOMAS Tamil Nadu  
DR DAVID MARTIN Australia  
DR DAVID RAJAN Coimbatore  
DR DENNY LIE Singapore  
DR EDWARD T MAH Australia  
DR GRAHAM MERCER South Australia  
DR H K WONG Hong Kong

DR HIROYUKI SUGAYA Japan  
DR HITESH GOPALAN Cochin  
PROF J E MENDES Portugal  
DR JAAP WILLEMS Holland  
DR JOHN EBNEZAR Bangalore  
DR JVS VIDYASAGAR Hyderabad  
PROF LENNARD FUNK UK  
DR MARIO PENTA South Australia  
DR NICK WALLWORK South Australia  
DR NIRBHAY SHAH Rajkot  
DR PAOLO PALADINI Italy  
DR PARAG SANCHETI Pune  
DR PETER CAMPBELL Australia  
PROF PP KOTWAL Delhi

PROF RAJASEKARAN Coimbatore  
MR RAM VENKATESH UK  
MR R PANDEY UK  
PROF RAJ BAHADUR Chandigarh  
MR ROBERT J GREGORY UK  
DR ROHIT ARORA Austria  
DR SACHIN TAPASVI Pune  
DR SANJAY DESAI Mumbai  
DR SANJAY GARUDE Mumbai  
DR SANJAY TRIVEDI Ahmedabad  
DR SRIPATHI RAO Karnataka  
PROF SUDHIR KAPOOR Delhi  
MR VED GOSWAMI UK  
DR YOUNG LAE MOON Korea

Copyright (C) 2016, International Society for Knowledge for Surgeons on Arthroscopy and Arthroplasty. All rights reserved.

Published by Reed Elsevier India Pvt. Ltd.

No part of the publication may be transmitted in any form or by any means, electronic or mechanical, without written permission from the Editor-in-Chief.

*Disclaimer: Although all advertising material is expected to conform to ethical (medical) standards, inclusion in the publication does not constitute a guarantee or endorsement of the quality or value of such product or of the claims made of it by its manufacturer. Please consult full prescribing information before issuing prescriptions for any products mentioned in this publication.*

Printed at EIH Limited-Unit Printing Press, IMT Manesar, Gurgaon





# Journal of Arthroscopy and Joint Surgery

An official publication of International Society for Knowledge for Surgeons on Arthroscopy and Arthroplasty

(ISSN: 2214-9635)

Volume 3, Number 1, January–April 2016

## Table of Contents

### Editorial

Editorial <i>Ravi Gupta</i>	1
--------------------------------	---

### Original Articles

Humeral avulsion of glenohumeral ligaments – Detection on magnetic resonance arthrography <i>Rukhtam Saqib, Lennard Funk, Jonathan Harris</i>	3
Arthroscopic fixation using TightRope device for acute acromioclavicular joint disruptions <i>Paras Gupta, Gagan Kansal, Shekhar Srivastav, Shekhar Agarwal</i>	7
Arthroscopic stabilization of acute acromioclavicular joint dislocation with tightrope AC system: A tale of failures <i>Shreesh Kumar Gangary, Sanjay Meena</i>	13
Comparison of CT-based patient-specific templating and digital radiography templating in total knee arthroplasty <i>Rutul R. Gandhi, Alfonso Manzotti, Norberto Confalonieri, Peitro Cerveri</i>	17
A radiological comparative study between transtibial & anteromedial portal drilling of femoral tunnel in single bundle anterior cruciate ligament reconstruction: A comparison of four angles <i>Siddharth M. Shetty, Vikram Shetty, Arjun Ballal, Jeetu Mohanchandran, Anoop Hegde</i>	22
Mucoid degeneration of the anterior cruciate ligament: Partial arthroscopic debridement and outcomes <i>Gagan Khanna, Rajan Sharma, Aditya Bhardwaj, Harjot S. Gurdutta, Deepak K. Agrawal, Abhishek S. Rathore</i>	28

### Case Reports

Intra-articular lipoma arborescence of the knee – A rare clinical entity <i>Vivek Pandey, Arun Gupta, Smita Kulshrestha, Lipisha Agarwal</i>	34
Vertical intraarticular dislocation of patella <i>Amit Chauhan, Shanmuga Maheswaran, Sanjeev Anand</i>	39



Available online at [www.sciencedirect.com](http://www.sciencedirect.com)

ScienceDirect

journal homepage: [www.elsevier.com/locate/jajs](http://www.elsevier.com/locate/jajs)

## Editorial



The current issue of JAJ S contains two original papers reporting the outcome of surgical management of acromioclavicular (A.C) joint injuries by arthroscopic tight rope stabilization. Both the studies are prospective studies and have 10 and 11 patients, respectively. Both the papers have included Rockwood grade III to grade V A.C joint injuries. The similar surgical technique used by both the authors, however, has not produced similar outcomes. The first series of Gupta et al. has reported seven excellent, two good and one fair result. While Gangary et al. in their series have reported one good, seven satisfactory and two poor outcomes. The second study has reported six failures of a total number of 11 shoulders. Two shoulders required revision surgery. Of the six failed cases, four belonged to grade III injury.

Arthroscopic assisted reconstruction with non-rigid coraco-clavicular (CC) lacing is a relatively new method of surgical stabilization of the A.C joint. The main advantages of this method include better cosmetic result, shorter time of surgery, no intra-operative fluoroscopy and reduced post-surgical morbidity due to minimal invasive nature of the surgery.<sup>1,2</sup> However, the method involves a higher cost of the implant and requires a surgeon well versed with the procedure of arthroscopy.<sup>3</sup>

Some of the recent studies have shown successful outcome with coraco-clavicular lacing procedures including tight rope.<sup>1,2,4–6</sup> On the contrary, there are studies which have reported unfavorable results with these surgical procedures. Clavert et al. in a prospective multi-centric study of 116 patients have reported 50% significant persistent dislocations after arthroscopic endobutton coraco-clavicular procedures with a complication rate of 22.4%.<sup>7</sup> Similarly, Barth et al. in a multicentric study have concluded that coracoclavicular stabilization alone is not sufficient irrespective of the implant used.<sup>8</sup>

Loriaut et al. have also reported 7% patients requiring revision surgery because of persistence of dislocation after arthroscopic assisted reconstruction of A.C. joint.<sup>9</sup>

Thus the results of arthroscopic non-rigid CC fixation, in the current literature are mixed. Whether the diagonally opposite outcomes are related to variations in patient selection or execution of the surgical technique is still unknown.

But a universal similarity in all the studies emanating from single centers is that the series are small with less number of patients thus reducing the power of study. Reporting of larger case series from individual centers will certainly take out the factor of the learning curve of the surgeon, in addition to enhancing the power of the study thus eliminating the chance factor.

## REFERENCES

1. Darabos N, Vlahovic I, Gusic N, Darabos A, Bakota B, Miklic D. Is AC TightRope fixation better than Bosworth screw fixation for minimally invasive operative treatment of Rockwood III AC joint injury? *Injury*. 2015;46(suppl 6):S113–S118.
2. Vrgoč G, Japjec M, Jurina P, et al. Operative treatment of acute acromioclavicular dislocations Rockwood III and V-Comparative study between K-wires combined with FiberTape(®) vs. TightRope System(®). *Injury*. 2015;46(suppl. 6):S107–S112.
3. Horst K, Dienstknecht T, Pishnamaz M, Sellei RM, Kobbe P, Pape HC. Operative treatment of acute acromioclavicular joint injuries graded Rockwood III and IV: risks and benefits in tight rope technique vs. k-wire fixation. *Patient Saf Surg*. 2013;7:18.
4. Andreani L, Bonicoli E, Parchi P, Piolanti N, Michele L. Acromio-clavicular repair using two different techniques. *Eur J Orthop Surg Traumatol*. 2014;24(2):237–242.
5. Jensen G, Ellwein A, Voigt C, Katthagen JC, Lill H. Injuries of the acromioclavicular joint: hook plate versus arthroscopy. *Unfallchirurg*. 2015;118(12):1041–1055.
6. Natera-Cisneros L, Sarasquete-Reiriz J, Escolà-Benet A, Rodríguez-Miralles J. Acute high-grade acromioclavicular joint injuries treatment: arthroscopic non-rigid coracoclavicular fixation provides better quality of life outcomes than hook plate ORIF. *Orthop Traumatol Surg Res*. 2016;102(1):31–39.
7. Clavert P, Meyer A, Boyer P, Gastaud O, Barth J, Duparc F. Complication rates and types of failure after arthroscopic acute acromioclavicular dislocation fixation. Prospective multicenter study of 116 cases. *Orthop Traumatol Surg Res*. 2015;101(8 suppl.):S313–S316.
8. Barth J, Duparc F, Andrieu K, et al. Is coracoclavicular stabilisation alone sufficient for the endoscopic treatment of severe acromioclavicular joint dislocation (Rockwood types III, IV, and V)? *Orthop Traumatol Surg Res*. 2015;101(8 suppl.): S297–S303.
9. Loriaut P, Casabianca L, Alkhaili J, et al. Arthroscopic treatment of acute acromioclavicular dislocations using a

double button device: clinical and mri results. *Orthop  
Traumatol Surg Res.* 2015;101(8):895-901.

Received 7 March 2016

Received in revised form 9 March 2016

Accepted 15 March 2016

Ravi Gupta, MS, DNB, FAMS, FIMSA  
Professor, Department of Orthopaedics,  
Government Medical College Hospital,  
Chandigarh 160031, India

E-mail address: ravikgupta2000@yahoo.com

[http://dx.doi.org/10.1016/S2214-9635\(16\)30003-7](http://dx.doi.org/10.1016/S2214-9635(16)30003-7)  
2214-9635/

Available online at [www.sciencedirect.com](http://www.sciencedirect.com)

ScienceDirect

journal homepage: [www.elsevier.com/locate/jajs](http://www.elsevier.com/locate/jajs)

## Original Article

# Humeral avulsion of glenohumeral ligaments – Detection on magnetic resonance arthrography

Rukhtam Saqib<sup>a,\*</sup>, Lennard Funk<sup>b</sup>, Jonathan Harris<sup>c</sup><sup>a</sup> Foundation Year 2, Stepping Hill Hospital, Stockport, UK<sup>b</sup> Consultant Orthopaedic Surgeon, Wrightington Hospital, UK<sup>c</sup> Consultant Musculoskeletal Radiologist, Salford Royal Hospital, Manchester, UK

## ARTICLE INFO

## Article history:

Received 6 December 2015

Accepted 22 February 2016

Available online 22 March 2016

## Keywords:

Arthroscopy

Magnetic resonance arthrography

HAGL

Sensitivity

Prevalence

## ABSTRACT

**Background:** Humeral avulsion of the glenohumeral ligaments (HAGL) is an important cause of shoulder instability, with magnetic resonance arthrography (MRA) routinely being used for diagnosis. Our aim was to compare the diagnostic value of MRA to shoulder arthroscopy for the detection of HAGL lesions and to calculate its prevalence.

**Methods:** Patients who underwent a shoulder arthroscopy with a single surgeon and pre-operative MRA between February 2011 and March 2012 for instability were identified. MRAs were reported by experienced musculoskeletal radiologists and compared to arthroscopy findings for the presence of HAGL lesions. Sensitivity, specificity, positive and negative predictive values, prevalence and positive and negative likelihood ratios were calculated. **Results:** A total of 194 patients were identified with a HAGL lesion prevalence of 4.64% on arthroscopy. The sensitivity of MRA in detecting HAGL was 0.44 (CI: 0.14–0.79) and the specificity was 0.97 (CI: 0.94–0.99). The positive predictive value was 0.44 (CI: 0.14–0.79) and negative predictive value was 0.97 (CI: 0.94–0.99). The positive likelihood ratio was 16.44 (CI: 5.30–51.00) and negative likelihood ratio was 0.57 (CI: 0.32–1.02).

**Conclusions:** MRA appears to be specific and accurate in excluding HAGL lesions, but not sensitive. HAGLs were associated with numerous other injuries such as bankart, SLAP and Hill–Sach lesions. The prevalence of 4.64% is comparable to previous studies.

© 2016 International Society for Knowledge for Surgeons on Arthroscopy and Arthroplasty. Published by Elsevier, a division of Reed Elsevier India, Pvt. Ltd. All rights reserved.

## 1. Introduction

Humeral avulsion of glenohumeral ligaments (HAGL) is an important cause of shoulder instability.<sup>1</sup> Instability usually arises as a result of acute trauma from glenohumeral subluxation or dislocation, with a combination of hyperabduction

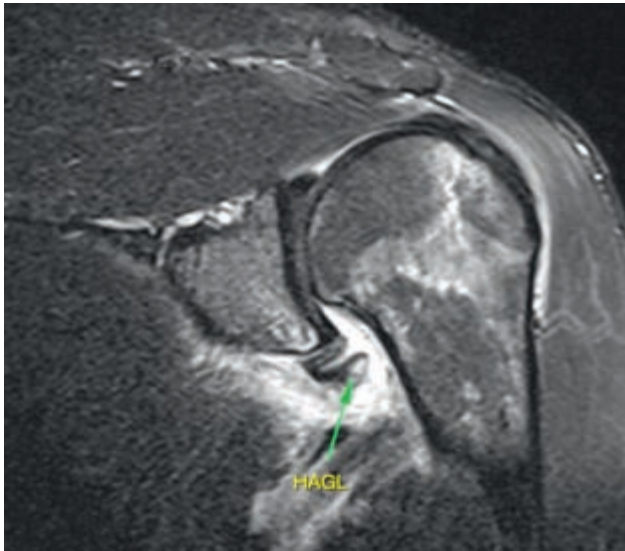
and external rotation.<sup>2</sup> MRA is well established in assessing glenohumeral pathology but its role in identifying HAGL lesions is under-reported in literature.<sup>3</sup> Jana et al. and Carlson described the J-sign referring to the conversion of the U-shaped axillary pouch to a J-shape as the inferior glenohumeral ligament (IGHL) complex drops inferiorly.<sup>3,4</sup> Other characteristics include increased intensity, thickening of the inferior capsule, a

\* Corresponding author. Tel.: +44 7719491775; fax: +44 7719491775.

E-mail address: [rukhtamsaqib@doctors.org.uk](mailto:rukhtamsaqib@doctors.org.uk) (R. Saqib).

<http://dx.doi.org/10.1016/j.jajs.2016.02.001>

2214-9635/© 2016 International Society for Knowledge for Surgeons on Arthroscopy and Arthroplasty. Published by Elsevier, a division of Reed Elsevier India, Pvt. Ltd. All rights reserved.



**Fig. 1 – A MRA demonstrating a HAGL lesion.**

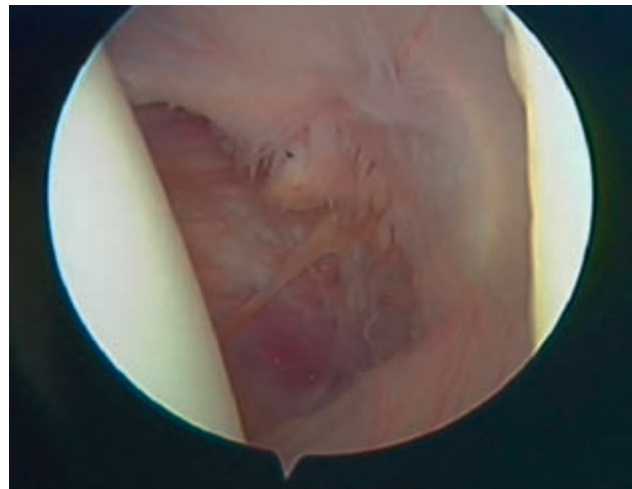
thickened wavy contour and higher intensity within the ligament itself, and extravasation of contrast material along the humeral neck (Fig. 1).<sup>3,4</sup>

Shoulder arthroscopy is the gold standard in detecting HAGL lesions through direct visualisation.<sup>5</sup> The distinguishing sign is visualisation of fibres of the subscapularis through the avulsed inferior joint capsule.<sup>6</sup> Bokor et al. described a disruption of the 'wave' between the reflection of the inferior capsule onto the humeral neck to be a reliable sign of HAGL lesions.<sup>7</sup>

The aim of our study is to assess the diagnostic value of MRA in detecting HAGL lesions compared with arthroscopy and to calculate the prevalence within our study group (Fig. 2).

## 2. Materials and methods

Shoulder arthroscopies performed by a single Consultant Orthopaedic Surgeon between February 2011 and March 2012 for instability were identified using the surgeon's operative records. All patients attended an initial outpatient clinic and were found to have clinical instability on examination, with suspicion of glenohumeral pathology including the possibility of a HAGL lesion. Of these patients, only those who had a pre-operative MRA were included and identified through PACS (Centricity PACS, GE Healthcare), Bluespир (Bluespир International, Droitwich, UK) and clinic letters. Patients were included regardless of demographics, background, side of operation or indication. The MRAs were requested by the Orthopaedic Surgeon to ensure that radiologists were made aware of the positive clinical findings on the request forms. The investigations and procedures were conducted over three hospital sites. 1.5T MRI scanners with gadolinium as contrast were used throughout with a routine standard protocol of T1 and T1 fat-sat axial, T1 fat-sat coronal and sagittal obliques, T2 fat-sat coronal oblique. All MRAs were reported by experienced specialist musculoskeletal radiologists. Findings were only included as positive when the radiologists or arthroscopist were definitive in their diagnosis.



**Fig. 2 – A HAGL lesion on shoulder arthroscopy.**

### 2.1. Statistics

Sensitivities, specificities, positive and negative predictive values (PPV/NPV), positive and negative likelihood ratios (PLR/NLR) were calculated using Statistical Package for Social Sciences (SPSS) version 22.0 (SPSS Inc. Chicago, IL, USA, 2014).

## 3. Results

A total of 744 patients underwent shoulder arthroscopic procedures for instability, of which 194 patients had a pre-operative MRA. Patients whose pathology was easily identifiable, or not related to a HAGL, on clinical examination or simpler radiological investigations such as ultrasound and X-rays did not have an MRA. The mean age was 29.9 years with a range between 13 and 69 years. 73%/27% of patients were males/females. Right to left ratio was nearly equal (52%:48%).

The prevalence of HAGL lesions on arthroscopy was 4.64% (9/194 cases). There were 4 true positives, 180 true negatives, 5 false positives and 5 false negatives. The sensitivity and specificity was 0.44 (CI: 0.14–0.79) and 0.97 (CI: 0.94–0.99) respectively. The PPV was 0.44 (CI: 0.14–0.79) and NPV was 0.97 (CI: 0.94–0.99). The PLR was 16.44 (CI: 5.30–51.00) and NLR was 0.57 (CI: 0.32–1.02). Table 1 summarises the statistical analysis.

**Table 1 – A table to show the sensitivity, specificity, positive likelihood ratios (PLR), negative likelihood ratios (NLR), positive predictive value (PPV) and negative predictive value (NPV) with 95% confidence intervals.**

Statistical test	Value	95% confidence intervals
Sensitivity	0.44	0.14–0.79
Specificity	0.97	0.94–0.99
Positive likelihood ratio	16.44	5.30–51.00
Negative likelihood ratio	0.57	0.32–1.02
Positive predictive value	0.44	0.14–0.79
Negative predictive value	0.97	0.94–0.99

Of the 9 confirmed cases of HAGLS on arthroscopy, 8/9 had an associated bankart lesion, 1/9 had an anterior labral periosteal sleeve avulsion (ALPSA), 3/9 had a superior labral tear from anterior to posterior (SLAP), 4/9 had a Hill–Sach's lesion and 2/9 had a rotator cuff tear.

#### 4. Discussion

The diagnostic value of MRA in identifying HAGL lesions has been largely under-reported.<sup>5</sup> Acid et al. compared MRA and multidetector computed tomography (MDCT) to arthroscopy and found that MRA had a sensitivity/specificity of 1.00/0.97 for humeral avulsion of IGHL lesion and 0.58/0.95 for middle glenohumeral ligament tear.<sup>5</sup> Our study showed a lower sensitivity and specificity of 0.44 (CI: 0.14–0.79) and 0.97 (CI: 0.94–0.99) for HAGL lesions. In our study, the presence of any glenohumeral ligament avulsion was considered as a HAGL lesion regardless of position which may account for the differences in statistics. Furthermore, our series was much larger with 194 patients in comparison to 40 patients, which may account for further differences.

Bigliani et al. suggested that avulsion of the IGHL would occur in up to 25% of cases with anterior dislocation in biomechanical cadaveric studies.<sup>8</sup> However, the actual prevalence has been reported to be much less in patients among literature. Wolf et al. were first to demonstrate a prevalence of 9.3% in 64 patients with shoulder instability, of which 73.5% also had a bankart lesion.<sup>6</sup> Yiannakopoulos et al. found that HAGL lesions had a prevalence of 1.57% in 127 patients with anterior shoulder instability.<sup>9</sup> Magee analysed 1000 magnetic resonance imaging (MRI) reports and found a prevalence of 1.6% on MRI and 2.1% in those who proceeded to surgery.<sup>10</sup> Liavaag et al. showed a prevalence of 21.4% of HAGL lesions on MRI in patients with traumatic shoulder dislocation and 7.1% on MRA at follow-up.<sup>11</sup> Bokor et al. found an incidence of 7.5% of HAGL lesions in 514 patients with primary instability on arthroscopy.<sup>7</sup> The incidence of HAGLs rose to 39% in patients who did not have a bankart lesion and violent injury was the cause of the initial dislocation.<sup>7</sup> Bhatia et al. found 11% of patients with bony instability had a HAGL lesion in a 64 patient series.<sup>12</sup> Bui-Mansfield et al. found an incidence of 2% for HAGL lesions in 307 patients who had a diagnostic arthroscopy for glenohumeral instability.<sup>13</sup> Mizuno et al. found a total incidence of 4.6% (14 patients) for HAGLs in 303 shoulders with recurrent dislocations and 4% (12 patients) had an isolated HAGL.<sup>14</sup> The prevalence and population age in our study of 4.64% and mean age 29.9 years is comparable to these studies.

There are several limitations of our study: firstly, a 100% commitment to the diagnosis with terms such as 'possible' and 'cannot exclude' being identified as a negative finding. Time elapsed between the MRA and shoulder arthroscopy could account for worsening or improving pathology and possibly subsequent additional injury leading to the development of a HAGL lesion. MRA reports were available to the arthroscopist prior to the procedure, which may have added an element of bias. However, we tried to minimise this by standardising the method of the procedure to assess the presence of specific glenohumeral pathology regardless of the

MRA. Nevertheless, clinical findings were available to both the radiologist and arthroscopist prior to their assessments. Furthermore, arthroscopy, although gold standard, is imperfect due to its operator-dependant nature and may result in overlooked pathology as well.

#### 5. Conclusion

In our study, we found large 95% confidence interval for PPV, PLR/NLR and sensitivity. It is therefore difficult to ascertain definitive conclusions upon diagnostic value with these statistics. Nevertheless, we are able to conclude that MRA is specific and able to predict a negative result with smaller 95% confidence intervals, but it is limited as a diagnostic tool for HAGLs due to its poor ability to produce a definitive positive result. However, by performing a MRA, the shoulder can be examined for concurring pathologies, which may provide an alternative or concurrent diagnosis. A much larger scale study with greater number of cases assessing the diagnostic value of MRA for HAGL lesions is necessary to explore the true potential of MRA. An additional study comparing MRA and MRI would help establish any further benefit, if any, for the more invasive MRA.

#### Conflicts of interest

All authors have none to declare.

#### REFERENCES

- George MS, Khazzam M, Kuhn JE. Humeral avulsion of glenohumeral ligaments. *J Am Acad Orthop Surg.* 2011;19 (March (3)):127–133.
- Martetschläger F, Ames JB, Millett PJ. HAGL and reverse HAGL lesions. *Shoulder Arthrosc.* 2014;411–418.
- Jana M, Srivastava DN, Sharma R, et al. Spectrum of magnetic resonance imaging findings in clinical glenohumeral instability. *Indian J Radiol Imaging.* 2011;21 (April–June (2)):98–106.
- Carlson CL. The J sign. *Radiology.* 2004;232(September (3)):725–726.
- Acid S, Le Corroller T, Aswad R, Pauly V, Champsaur P. Preoperative imaging of anterior shoulder instability: diagnostic effectiveness of MDCT arthrography and comparison with MR arthrography and arthroscopy. *Am J Roentgenol.* 2012;198:661–667.
- Wolf EM, Cheng JC, Dickson K. Humeral avulsion of glenohumeral ligaments as a cause of anterior shoulder instability. *Arthroscopy.* 1995;11(October (5)):600–607.
- Bokor DJ, Conboy VB, Olson C. Anterior instability of the glenohumeral joint with humeral avulsion of the glenohumeral ligament. A review of 41 cases. *J Bone Jt Surg Br.* 1999;81(January (1)):93–96.
- Bigliani LU, Pollock RG, Soslowky LJ, Flatow EL, Pawluk RJ, Mow VC. Tensile properties of the inferior glenohumeral ligament. *J Orthop Res.* 1992;10:187–197.
- Yiannakopoulos CK, Mataragas E, Antonogiannakis E. A comparison of the spectrum of intra-articular lesions in acute and chronic anterior shoulder instability. *Arthroscopy.* 2007;23(September (9)):985–990.

10. Magee T. Prevalence of HAGL lesions and associated abnormalities on shoulder MR examination. *Skelet Radiol.* 2014;43(March (3)):307-313.
11. Liavaag S, Stiris MG, Svenningsen S, Enger M, Pripp AH, Brox JI. Capsular lesions with glenohumeral ligament injuries in patients with primary shoulder dislocation: magnetic resonance imaging and magnetic resonance arthrography evaluation. *Scand J Med Sci Sports.* 2011;21(December (6)):e291-e297.
12. Bhatia DN, DasGupta B. Surgical treatment of significant glenoid bone defects and associated humeral avulsions of glenohumeral ligament (HAGL) lesions in anterior shoulder instability. *Knee Surg Sports Traumatol Arthrosc.* 2013;21(July (7)):1603-1609.
13. Bui-Mansfield LT, Taylor DC, Uhorchak JM, Tenuta JJ. Humeral avulsions of the glenohumeral ligament: imaging features and a review of the literature. *Am J Roentgenol.* 2002;179:649-655.
14. Mizuno N, Yoneda M, Hayashida K, Nakagawa S, Mae T, Izawa K. Recurrent anterior shoulder dislocation caused by a midsubstance complete capsular tear. *J Bone Jt Surg Am.* 2005;87(December (12)):2717-2723.



Available online at [www.sciencedirect.com](http://www.sciencedirect.com)

ScienceDirect

journal homepage: [www.elsevier.com/locate/jajs](http://www.elsevier.com/locate/jajs)

## Original Article

# Arthroscopic fixation using TightRope device for acute acromioclavicular joint disruptions



Paras Gupta<sup>a,\*</sup>, Gagan Kansal<sup>a</sup>, Shekhar Srivastav<sup>b</sup>, Shekhar Agarwal<sup>c</sup>

<sup>a</sup> Clinical Fellow, Delhi Institute of Trauma & Orthopedics, Sant Parmanand Hospital, New Delhi, India

<sup>b</sup> Consultant, Delhi Institute of Trauma & Orthopedics, Sant Parmanand Hospital, New Delhi, India

<sup>c</sup> Director & HOD, Delhi Institute of Trauma & Orthopedics, Sant Parmanand Hospital, New Delhi, India

## ARTICLE INFO

## Article history:

Received 11 January 2016

Accepted 13 January 2016

Available online 15 February 2016

## Keywords:

AC joint dislocation

Arthroscopic surgery

Shoulder arthroscopy

TightRope device

Outcome analysis

## ABSTRACT

**Background:** Acromioclavicular (AC) joint dislocation is a common shoulder injury that affects young adults. The treatment of these injuries depends on dislocation grade, the patient's complaints and time since injury.

**Materials:** Patients with acute AC joint injuries (Rockwood grades III–V) of less than 4 weeks duration were included in the study. We had 10 cases of AC joint injuries, which fulfilled the inclusion criteria. All patients were diagnosed based on history, examination and plain radiographs. Grading was done based on plain radiographs. Patients with grades III–V were selected for TightRope fixation. All 10 patients with AC joint injury underwent arthroscopic AC joint fixation using TightRope. Functional outcome of patients was done using constant shoulder score preoperatively and postoperatively. All patients were followed up for at least one year. We were able to achieve satisfactory reduction in all the patients.

**Results:** Mean constant score at the final follow-up was 92.2 (range 76–97). The mean difference in constant score between operated and normal shoulder was 9.8. On the basis of difference of constant score, 7 patients had excellent results, 2 had good results and 1 had fair result.

**Conclusion:** Arthroscopic fixation of acute AC joint dislocation using the TightRope device is a simple, reproducible, minimal invasive technique that enables a rapid return to activity for the acute injury.

© 2016 International Society for Knowledge for Surgeons on Arthroscopy and Arthroplasty. Published by Elsevier, a division of Reed Elsevier India, Pvt. Ltd. All rights reserved.

## 1. Introduction

Acromioclavicular (AC) joint dislocation is a common shoulder injury that typically affects young adults.<sup>1,2</sup> The treatment of these injuries depends on dislocation grade, the patient's complaints and time since injury. For Rockwood I and II

dislocations, non-operative management shows very satisfying results. Acute Rockwood IV and V dislocations are a clear indication for surgery.<sup>3</sup> The treatment guidelines for Rockwood III dislocations are not uniform.<sup>4</sup> While some publications postulate conservative treatment to be superior, others report better outcome with operative treatment of Rockwood type III dislocations.<sup>5,6</sup>

\* Corresponding author. Tel.: +91 9717260996.

E-mail address: [parasortho@gmail.com](mailto:parasortho@gmail.com) (P. Gupta).

<http://dx.doi.org/10.1016/j.jajs.2016.01.002>

2214-9635/© 2016 International Society for Knowledge for Surgeons on Arthroscopy and Arthroplasty. Published by Elsevier, a division of Reed Elsevier India, Pvt. Ltd. All rights reserved.

Conventionally open procedures have been considered as preferred modality of treatment in AC dislocations. However, recent years have seen an upsurge in the use of arthroscopic techniques for management of acute AC joint injuries.<sup>7</sup> A gold standard for the reconstruction of coracoclavicular (CC) complex is yet to emerge. Most techniques not only fail to recreate the original anatomy, but often involve the use of materials that are not strong enough to maintain the reduction during healing process.<sup>7</sup> A new option is offered by the TightRope™ system (Arthrex, Naples, USA), which consists of 2 metal buttons (1 circular and 1 oblong), joined by a continuous loop of Fibrewire suture.<sup>8</sup> The device can be used to fix the AC joint using an arthroscopic technique. This technique has been described as a simple, reproducible, minimal invasive procedure for acute AC joint fixation that enables a rapid return to activity for the acute injury. It also leaves minimal scarring and does not require any metalwork removal. We describe our experience of treating 10 patients with acute AC joint dislocation with arthroscopic TightRope™ fixation.

## 2. Materials and methods

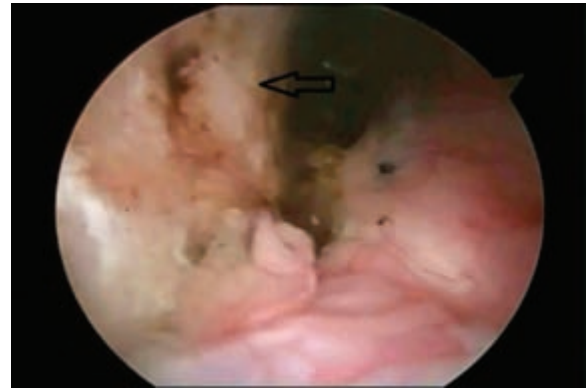
This was a prospective study where the patients with AC joint injuries treated arthroscopically with TightRope™ fixation between January 2013 and September 2014 were assessed. The patients with acute AC joint injuries of Rockwood grades III, IV & V and less than 4 weeks duration were included in the study. Exclusion criteria were AC joint injury of more than 4 weeks duration, open injuries and injuries of Rockwood grade I, II and VI. A total of 10 cases aged between 18 and 40 years fulfilled the inclusion criteria. The patients were diagnosed based on history, examination and radiographs. Grading was done based on plain radiographs done in two planes. Arthroscopic TightRope™ fixation was done in all the cases.

### 2.1. Surgical technique

The patient was positioned in the lateral decubitus position under a general anaesthesia. Preoperative antibiotics were administered. A 30° arthroscope was introduced into the glenohumeral joint via a standard posterior portal. An antero-inferior portal was created near the tip of the coracoid with an outside/in technique, using the spinal needle to ensure that the base of the coracoid could be reached. An 8.25-mm twist-in cannula (Arthrex) was inserted through this portal, and the debridement of the rotator interval was done. A 4.5-mm full-radius shaver blade was introduced through the antero-inferior cannula and into the rotator interval and debrided until the tip of the coracoid could be visualized (Fig. 1).

A radiofrequency device and a 4.5-mm shaver were then used to expose the base of the coracoid and strip the bursa and periosteum to obtain a full view of the undersurface. The AC TightRope™ Constant Drill Guide with coracoid drill stop attachment (Arthrex) was prepared with the guide set at 80 and was inserted through the antero-inferior portal. We made certain that a sufficient bone bridge existed around the 4-mm reamed tunnel (Fig. 2).

The top of the guide was positioned over the distal clavicle directly over the coracoid and a 1.5-cm incision made and

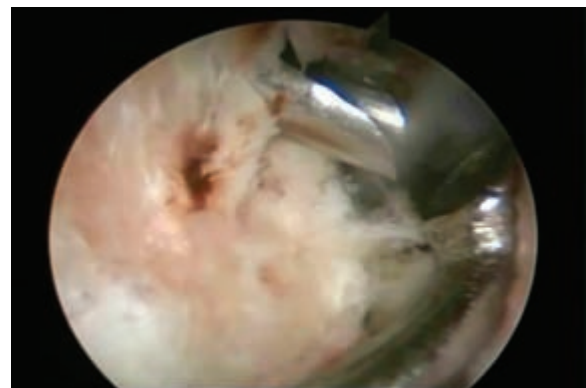


**Fig. 1 – Arthroscopic view of base of coracoid after clearance of rotator interval.**

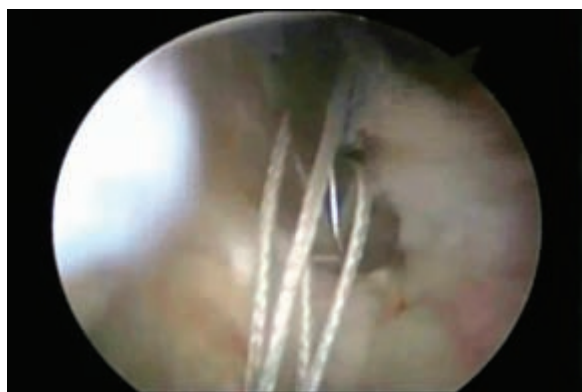continued down to the clavicle. The guide was then positioned 3 cm from the AC joint on the superior surface of the clavicle.

Using a power drill, a 2.4-mm Drill Tip Guide Pin (Arthrex) was inserted into the guide pin sleeve and was advanced through the clavicle and coracoid. The drilling was stopped at the base of the coracoid. The position of the pin was checked in relation to the coracoid and, if incorrect, the guide pin was redrilled. The drill guide was removed, and the guide pin was left in situ. The drill guide was repositioned under the pin to keep it from advancing while reaming. The 4-mm cannulated drill was then passed over the pin and through the coracoid, again under direct vision. The pin was then removed, leaving the drill in situ.

A Nitinol Suture Passing Wire (Arthrex) was passed down through the drill and taken out through the antero-inferior portal using an arthroscopic grasper, leaving the suture loop superiorly. The drill was then carefully removed, leaving the wire in position. The 2 white traction sutures from the oblong button of the TightRope™ system passed through the wire loop of the Nitinol Suture Passing Wire, which was then drawn out of the antero-inferior portal under direct vision. Once the oval button was seen under the coracoid (Fig. 3), the trailing suture was used to flip it, locking it under the bone. Once the security of the button was confirmed, the clavicle was then reduced by the surgical assistant and was confirmed by fluoroscopy. When a satisfactory reduction was achieved, the



**Fig. 2 – Drill guide passing through base of coracoid.**



**Fig. 3 – Oblong button at base of coracoid, arthroscopic view.**

sutures were tied over the top of the superior button. The wounds were then closed and aseptic dressing done.

All patients had a standard postoperative rehabilitation. Patients were followed up at regular intervals till at least one year. Post-operatively, sling or shoulder immobilizer was used for 4–6 weeks to allow the reconstruction to heal. Passive and active assisted range of motion exercises was initiated as early as 7–10 days postoperatively. Strengthening exercises were typically avoided for 6 weeks. Patient was advised to avoid non-contact sports for 3 months and contact athletic activities for 6 months. Radiographs were obtained to ascertain the quality of reduction and maintenance of reduction in the post-operative period. Functional assessment of all the patients was done using constant shoulder score.

### 3. Results

The mean age of the patients was 32 years (range 24–40 years). There were eight male and two female patients. Average duration between injury and surgery was 16 days (range 6–28 days). Three patients had Rockwood type III AC dislocation while seven patients had type V dislocation. In seven patients, dominant extremity was involved while the remaining three

had injured the non-dominant shoulder. Mode of injury was road traffic accident in 8 cases and direct fall on shoulder in 2 cases. All the patients were treated by arthroscopic TightRope™ fixation. Satisfactory reduction was achieved in all the cases. The mean duration of follow-up was 12.7 months (range 11–16 months). Mean constant score at the final follow-up was 92.2 (range 76–97). The mean difference in constant score between operated and normal shoulder was 9.8. On the basis of the difference in constant score between normal and operated sides, seven patients had excellent results, two had good results and one had fair result. There was one case of coracoid fracture at 4 weeks post-surgery in a 34-year-old male patient, which resulted in some loss of reduction. There was no case of implant loosening or osteolysis of clavicle. The details of the patients are provided in Table 1 and Fig. 4 shows pre- and post-operative clinical and radiological images.

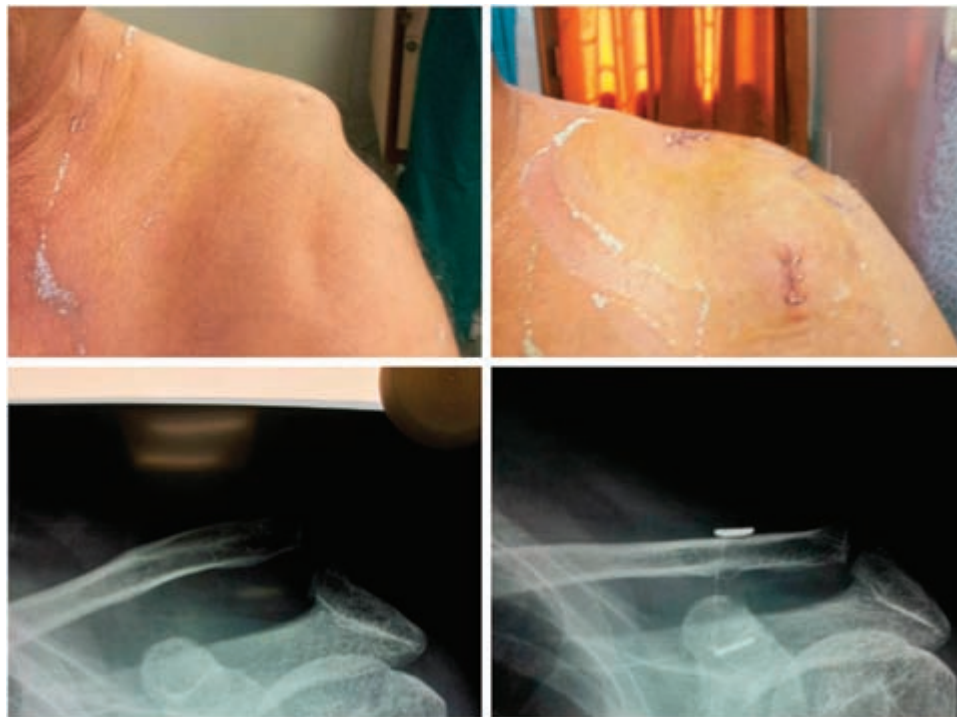
### 4. Discussion

AC dislocation is one of the most common shoulder injuries seen in general orthopaedic practice. These are commonly seen in second and third decade of life. The average incidence is 9–12% of all injuries to the shoulder.<sup>9</sup> Males are more commonly affected, with male to female ratio of 5:1. The most common mechanism of injury is a fall with direct force to the lateral aspect of shoulder with the arm in adduction. Depending on the magnitude of trauma, this injury can be classified into 6 types.<sup>10</sup> Typically, Rockwood types I and II are treated conservatively, with most patients returning to pre-injury levels of activity.<sup>11</sup> Although the treatment of type III injuries is controversial, various methods have been described, such as an augmented suture with absorbable material, stabilization with k-wires in combination with or without additional wire loop, hook plate, or the Bosworth screw.<sup>4,12–15,17</sup> In low demand patients, satisfactory results can be obtained with conservative treatment. However, in younger patients and athletes with high physical demands, early operative stabilization is favoured by many surgeons to achieve good anatomic, functional and clinical results.

Acute surgical intervention is recommended for the more severe grades of AC joint dislocation (types IV–VI).<sup>3</sup> If the joint

**Table 1 – Descriptives for the cases.**

	Age	Sex	Mode of injury	Type of injury	Interval between injury and surgery (days)	Final follow-up (months)	Final CSS	Result	Complications
1	29	M	RTA	III	10	12	88	Good	Nil
2	24	M	RTA	V	6	14	94	Excellent	Nil
3	34	M	RTA	V	18	12	76	Fair	Coracoid fracture
4	29	M	RTA	III	17	12	95	Excellent	Nil
5	36	M	Fall	V	28	11	96	Excellent	Nil
6	34	F	RTA	V	24	14	89	Good	Nil
7	28	M	RTA	III	15	12	96	Excellent	Nil
8	40	M	RTA	V	10	12	95	Excellent	Nil
9	27	F	Fall	V	20	16	97	Excellent	Nil
10	39	M	RTA	V	12	12	96	Excellent	Nil



**Fig. 4 – Pre-operative and post-operative, clinical and radiological pictures of type III acromioclavicular dislocation showing good reduction after fixation with TightRope™.**

is reduced acutely and held reduced during the healing phase, the native ligaments can heal, thus restoring the stability of the joint. Currently, there are 4 main surgical treatment options for the dislocated ACJ: (1) primary fixation of AC joint (with pins, screws, suture wires, plates, hook plates) with or without ligament repair or reconstruction,<sup>16</sup> (2) primary CC interval fixation (with Bosworth screw, wire, fascia, conjoint tendon, or synthetic sutures) with or without incorporation of AC ligament repair/reconstruction,<sup>7,17,18</sup> (3) Excision of distal clavicle with or without CC ligament transfer<sup>19,20</sup> and (4) Dynamic muscle transfer with or without excision of the distal clavicle.<sup>21</sup>

Traditional open techniques leave a large scar and often require the removal of metalwork. Recently, a number of arthroscopic techniques have been described, but most are complex or necessitate passing material around the coracoids, with the subsequent risk of cutting through the bone and of damage to the brachial plexus as it passes medial to the coracoid.<sup>7</sup> Arthroscopic surgery causes less injury to the soft tissue envelope; however, it is limited by a steeper learning curve. Scheibel et al. and Walz et al. have published results following two bundle anatomic reduction of AC joint using a TightRope™.<sup>22,23</sup> They attempted at the replacement of both conoid and trapezoid part of ac joint using two separate tunnels and TightRope™ devices. Walz et al. have reported satisfactory clinical results at the end of 58 months. However, a biomechanical study done by Mazzocca et al. comparing single clavicular tunnel, double clavicular tunnel and Weaver Dunn procedure concluded that single and double clavicular tunnel has a higher load to failure for superior translation as

compared to Weaver Dunn procedure.<sup>24</sup> The use of two clavicular tunnels did not have a significant advantage over single tunnel. Since the technique is relatively new, the literature on this technique is scarce. However, short-term results are available. A study conducted by Sameh A. El Sallakh with 10 patients with acute AC joint injuries stabilized with TightRope™ technique.<sup>25</sup> The mean follow-up period was 26.5 months. Average Constant score was 96.3 (range, 94–99) at last follow-up. The 10 patients were satisfied with their functional results and cosmetic appearance. Another study conducted by Thiel et al.,<sup>26</sup> for AC joint dislocations using TightRope™. Eleven patients had either Rockwood grade IV or V disruption. The majority of patients obtained satisfactory functional results according to the Simple Shoulder Test with 11 of 12 questions being answered positively and 11 of 12 patients were satisfied with the procedure. The rate of fixation failure was 16.6%. This case series revealed a high rate of fixation failure with the TightRope™ system. Still, most patients were satisfied with the procedure and achieved high functional shoulder results. Our results are comparable to those in the literature.<sup>27,28</sup> There was one case of coracoid fracture in our study. The fracture occurred at 4 weeks post-op resulting in shoulder stiffness and was managed conservatively. The failure was due to non-compliance of patient in post-operative period as he started strenuous manual work two weeks after surgery. He regained satisfactory range of motion gradually with physiotherapy and his constant shoulder score at one year was 76.

In acute injury, the AC joint can be reduced easily and held with strong AC TightRope™ fixation allowing the CC

ligaments to heal. As it is an elastic fixation, its removal is not required. Caution should be observed while drilling the tunnel in coracoids. It should be centred at the base or else may cause coracoid fracture. As it is a minimal invasive technique, recovery is relatively fast and the scars are cosmetically acceptable. Most patients scored high on functional scoring and were happy with both the functional and cosmetic results. The main drawbacks of our study were smaller sample size and relatively shorter follow-up. However, the early results with this small group were quite encouraging. Studies with larger number of cases, longer follow-up and control groups are needed to assess the long-term outcome and efficacy of this procedure.

## 5. Conclusion

Arthroscopic fixation of acute AC joint dislocation using the TightRope™ Device is a simple, reproducible, minimal invasive technique for acute AC joint fixation that enable a rapid return to activity for the acute injury.

## Disclaimer

None of the authors received payments or services, either directly or indirectly (i.e., via his or her institution), from a third party in support of an aspect of this work. In addition, none of the authors, or his or her institution, has had a financial relationship, in the thirty-six months prior to submission of this work, with an entity in the biomedical arena that could be perceived to influence or have the potential to influence what is written in this work. Also, none of the authors has a patent or patents, planned, pending, or issued, that is broadly relevant to the work. No author has had any other relationships, or has engaged in any other activities, that could be perceived to influence or have the potential to influence what is written in this work.

## Conflict of interest

All authors have none to declare.

## REFERENCES

1. Clayton RA, Court-Brown CM. The epidemiology of musculoskeletal tendinous and ligamentous injuries. *Injury*. 2008;39(12):1338-1344.
2. Rockwood CA, Williams G, Young D, Disorders of the acromioclavicular joint. 2nd ed. Rockwood CA, Matsen FA, eds. *The Shoulder*. vol. 1. Philadelphia: WB Saunders; 1998: 483-553.
3. Mazzocca AD, Santangelo SA, Johnson ST, Rios CG, Dumonski ML. A biomechanical evaluation of an anatomical coracoclavicular ligament reconstruction. *Am J Sports Med*. 2006;34(2):236-246; Bradley JP, Elkousy H. Decision making: operative versus non-operative treatment of acromioclavicular joint injuries. *Clin Sports Med*. 2003;22(2):277-290.
4. Galpin RD, Hawkins RJ, Grainger RW. A comparative analysis of operative versus non-operative treatment of grade III acromioclavicular separations. *Clin Orthop Relat Res*. 1985;193:150-155.
5. Hootman JM. Acromioclavicular dislocation: conservative or surgical therapy. *J Athl Train*. 2004;39(1):10-11.
6. Ceccarelli E, Bondi R, Alviti F, et al. Treatment of acute grade III acromioclavicular dislocation: a lack of evidence. *J Orthop Traumatol*. 2008;9(2):105-108.
7. Wolf EM, Pennington WT. Arthroscopic reconstruction for acromioclavicular joint dislocation. *Arthroscopy*. 2001;17(5):558-563.
8. Salzmann GM, Walz L, Schoettle PB, et al. Arthroscopic anatomical reconstruction of the acromioclavicular joint. *Acta Orthop Belg*. 2008;74(3):397-400.
9. Lemos MJ. The evaluation and treatment of the injured acromioclavicular joint in athletes. *Am J Sports Med*. 1998;26(1):137-144.
10. Rockwood Jr CA, Williams GR, Young DC, Disorders of the acromioclavicular joint. 2nd ed. Rockwood CA, Matsen FA, eds. *The Shoulder*. vol. 1. Philadelphia, PA: WB Saunders; 1998: 483-553.
11. Dias JJ, Steingold RF, Richardson RA, Tesfayohannes B, Gregg PJ. The conservative treatment of acromioclavicular dislocation: review after five years. *J Bone Joint Surg Br*. 1987;69(5):719-722.
12. Leidel BA, Braunstein V, Kirchoff C, et al. Consistency of long-term outcome of acute Rockwood grade III acromioclavicular joint separations after K-wire transfixation. *J Trauma*. 2009;66(6):1666-1671.
13. Ejam S, Lind T, Falkenberg B. Surgical treatment of acute and chronic acromioclavicular dislocation Tossy type III and V using the Hook plate. *Acta Orthop Belg*. 2008;74(4): 441-445.
14. Eberle C, Fodor P, Metzger U. Hook plate (so-called Balsler plate) or tension banding with the Bosworth screw in complete acromioclavicular dislocation and clavicular fracture. *Z Unfallchir Versicherungsmed*. 1992;85(3): 134-139.
15. Weitzmann G. Treatment of acute acromioclavicular joint dislocation by a modified Bosworth method report on twenty-four cases. *J Bone Joint Surg Am*. 1967;49:1167-1178.
16. Phillips AM, Smart C, Groom AFG. Acromioclavicular dislocation: conservative or surgical therapy. *Clin Orthop Relat Res*. 1998;353:10-17.
17. Bosworth BM. Acromioclavicular separations: new method of repair. *Surg Gynecol Obstet*. 1941;73:866-871.
18. Larsen E, Peterson V. Operative treatment of chronic acromioclavicular dislocations. *Injury*. 1987;18(1):55-56.
19. Weaver JK, Dunn HK. Treatment of acromioclavicular injuries, specially complete acromioclavicular separation. *J Bone Joint Surg Am*. 1972;54(6):1187-1194.
20. Mumford EB. Acromioclavicular dislocation. *J Bone Joint Surg*. 1941;23:799-802.
21. Berson BL, Gilbert MS, Green S. Acromioclavicular dislocations: treatment by transfer of the conjoint tendon and distal end of the coracoids process to the clavicle. *Clin Orthop*. 1978;135:157-164.
22. Scheibel M, Dröschel S, Gerhardt C, Kraus N. Arthroscopically assisted stabilization of acute high-grade acromioclavicular joint separations. *Am J Sports Med*. 2011;39(July (7)):1507-1516.
23. Walz LSG, Eichhorn S, Imhoff AB, et al. The anatomic reconstruction of AC joint dislocation using tightrope devices – a biomechanical study. *Am J Sports Med*. 2008;36(12):2398-2406.
24. Mazzocca AD, Arciero RA, Bicos J. Evaluation and treatment of acromioclavicular joint injuries. *Am J Sports Med*. 2007;35(2):316-329.

25. El Sallakh SA. Evaluation of arthroscopic stabilization of acute acromioclavicular joint dislocation using the TightRope™ system. *Orthopedics*. 2012;35(January (1)): e18–e22.
26. Thiel E, Mutnal A, Gilot GJ. Surgical outcome following arthroscopic fixation of acromioclavicular joint disruption with the tightrope device. *Orthopedics*. 2011;34(July (7)): e267–e274.
27. Richards A, Tennent TD. Arthroscopic stabilization of acute acromioclavicular joint dislocation using the TightRope system. *Tech Shoulder Elbow Surg*. 2008;9(2):51–54.
28. Vieira LAG, Visco A, Fernandes LFD, Cordero NGG. Arthroscopic treatment of acromioclavicular joint dislocation by TightRope technique (Arthrex). *Rev Bras Ortoped*. 2009;44(1):52–56.

Available online at [www.sciencedirect.com](http://www.sciencedirect.com)

ScienceDirect

journal homepage: [www.elsevier.com/locate/jajs](http://www.elsevier.com/locate/jajs)

## Original Article

# Arthroscopic stabilization of acute acromioclavicular joint dislocation with tightrope AC system: A tale of failures

Shreesh Kumar Gangary<sup>b</sup>, Sanjay Meena<sup>a,\*</sup><sup>a</sup> Department of Orthopaedics, SGT Medical College, SGT University, Gurgaon, India<sup>b</sup> Department of Orthopaedics, ESI Hospital, Okhla, 110020 New Delhi, India

## ARTICLE INFO

## Article history:

Received 13 August 2015

Accepted 4 November 2015

Available online 15 December 2015

## Keywords:

Acromioclavicular joint dislocation

Tightrope

Arthroscopy

Shoulder

## ABSTRACT

**Background:** Stabilization of acromioclavicular joint is a challenging technique with several methods described in literature from non-biological methods to biological fixation of AC joint. Arthroscopic fixation of AC joint is a newer technique with limited literature available. The aim of our study is to evaluate the results of arthroscopic stabilization of acute acromioclavicular joint with tightrope.

**Methods:** From February 2013 till August 2013, arthroscopic stabilization of acute ACJ dislocation was performed in 11 patients. The group consisted of eight men and three women with an average age of 34.2 years. The Rockwood type III to type V ACJ dislocations (III, 6; IV, 2; V, 3) were indicated for surgery. The average interval between injury and surgery was 5.4 days. In all cases, a second-generation tightrope implant was inserted by the Endobutton technique joining the distal end of the clavicle and the coracoid process. The results were evaluated using the UCLA Shoulder Scale at 10 months after surgery.

**Results:** All 11 patients returned to their preoperative activities without any restriction of shoulder motion within 5 months of surgery. The average postoperative UCLA score was 30.3 points (range 27–34). Radiographic evidence of the loss of partial reduction, with no effect on the clinical outcome, was recorded in 5 patients (45%) and loss of full reduction noted in 5 (45%) patients during postoperative rehabilitation. One patient was lost in follow-up.

**Conclusion:** Arthroscopic stabilization of acute ACJ dislocations using a single tightrope implant is a minimally invasive surgical technique, but less satisfactory result may be because of non-biological nature of fixation. Non-biological AC joint fixation is not a good method of fixation of a biological AC joint.

© 2015 International Society for Knowledge for Surgeons on Arthroscopy and Arthroplasty. Published by Elsevier, a division of Reed Elsevier India, Pvt. Ltd. All rights reserved.

\* Corresponding author. Tel.: +91 9968444612.

E-mail address: [skm900@gmail.com](mailto:skm900@gmail.com) (S. Meena).<http://dx.doi.org/10.1016/j.jajs.2015.11.003>

2214-9635/© 2015 International Society for Knowledge for Surgeons on Arthroscopy and Arthroplasty. Published by Elsevier, a division of Reed Elsevier India, Pvt. Ltd. All rights reserved.

**Table 1 – Patient demographics and coracoclavicular distance measurements.**

Patient	Age/sex	Occupation	Rockwood type	Coracoclavicular distance				Time of failure (months)	Reason of failure
				Preop	Normal/ Contralateral side	Postop	At one year		
1	30 y/M	Labourer	III	17	10	9	12	–	–
2	43 y/F	Labourer	III	19	9	9	15	3	Coracoid through
3	36 y/M	Labourer	V	20	9	9	11	–	–
4	31 y/M	Shop assistant	III	17	11	10	15	5	Coracoid through
5	33 y/F	Housewife	V	19	9	9	12	–	–
6	33 y/M	Labourer	III	18	10	9	12	–	–
7	48 y/M	Labourer	III	18	10	10	18	6	Coracoid through
8	38 y/M	Labourer	V	22	11	9	20	6	Clavicular erosion
9	25 y/M	Labourer	III	18	9	10	17	3	Coracoid through
10	49 y/M	Shop assistant	IV	20	11	10	16	2	Clavicular through
11	35 y/M	Housewife	IV	20	10	9	12	–	–

## 1. Introduction

Acromioclavicular joint (AC jt) injuries are one of the most common injuries of the shoulder joint in the young and active patient population.<sup>1</sup> The incidence of traumatic AC joint separation varies from 3 to 4 per 100,000 people with 25–52% of these occurring during sporting activities.<sup>2</sup> Most acromioclavicular (AC) joint injuries can be successfully treated non-operatively; surgery is usually needed for Rockwood grade IV–VI dislocations.<sup>3,4</sup> Treatment strategies to treat Rockwood grade III dislocations remain controversial and can be either conservative or surgery.<sup>2</sup> The principle is to reduce and temporarily fix the joint in place to allow healing of torn ligaments. Stabilization of acromioclavicular joint is a challenging technique with several methods described in literature from non-biological methods to biological methods.<sup>5</sup> The latter is a newer technique with limited literature available. The metallic fixation materials often loosen and will usually impair shoulder joint function; therefore, pins, screws or plates must be removed 6 weeks to 12 weeks after surgery, which occasionally leads to recurrence of dislocation or subluxation.<sup>6</sup> Some studies have suggested that sutures may be used to permanently replace coracoclavicular ligaments.<sup>7,8</sup> Arthroscopic fixation of acromioclavicular joint is a relatively new technique with conflicting results.

The present study aimed to assess the radiological and functional results of using arthroscopy-assisted coracoclavicular flip button device (tightrope) repair for Rockwood grade III to V AC dislocations.

## 2. Materials and methods

A series of 15 consecutive patients were treated prospectively for acute acromioclavicular joint dislocation from February 2013 to August 2013. In all cases, a second-generation tightrope implant was inserted by the Endobutton technique joining the distal end of the clavicle and the coracoid process. Inclusion criteria were a completely acute traumatic AC jt dislocation (Rockwood grade III to V), age between 18 and 45 years and a minimum of one-year follow-up. Exclusion criteria were associated lesions, low functional demand patients and

surgery delay more than one week. We excluded 4 patients: 1 patient had associated greater tuberosity fracture, 1 patient was operated after 7 days and two patients were low demand patients. This left us with 11 patients. Data were collected and include gender, age at the time of surgery, injury mechanism, Rockwood classification and complications. Coracoclavicular distance was measured and compared to the other side (Table 1). Patients with at least one-year follow-up were included in this study.

All patients were evaluated clinically and radiologically using Constant–Murley score (Table 2). Anteroposterior radiographs were obtained for both clavicles and AC joints at preop, postop, 6 weeks and 6-month interval. Coracoclavicular distance was measured and compared to normal side. All analyses were performed using SAS statistical software (SAS 9.2, Cary, NC). Reduction of AC joint was assessed using coracoclavicular distance.

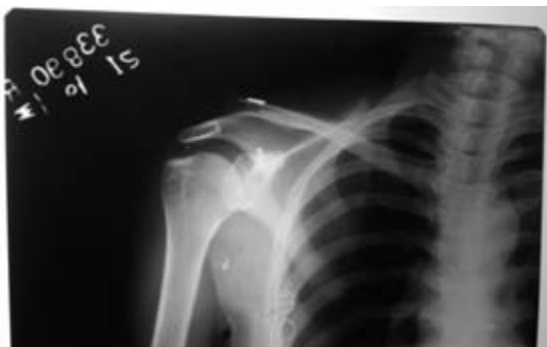### 2.1. Surgical technique

The arthroscopic procedure was performed in lateral position under general anaesthesia. Three portals were used: a posterior portal, an anterolateral portal for the optical device and an operative anterosuperior portal. The glenohumeral joint was explored using posterior portal. The anterolateral portal was used to explore the lateral and upper surfaces of the coracoid, whereas the anterosuperior portal was used to introduce a radiofrequency device to clean the lateral and inferior coracoid side. A 4-mm dedicated C-ring drill guide was introduced into the anterosuperior portal and under the coracoid. A small incision of 2 mm was made to expose the distal clavicle. The guidewire was directed from the posterior site of the clavicle to the coracoid base as close as possible to the coracoid centre under arthroscopic visualization. Then, a

**Table 2 – Summary of Constant–Murley score.**

Constant and Murley score	No of patients (%)
Excellent	0 (0%)
Good	1 (9%)
Satisfying	8 (72%)
Poor	2 (18%)





**Fig. 1 – Six months postoperative AP radiograph of the tightrope.**

4.5 mm cannulated drill pin was introduced through the clavicle and the coracoid. A tightrope (Arthrex, Naples, FL, USA) was pulled under the coracoid base using nitinol wire loop. It was then flipped under arthroscopic control. Reduction was confirmed fluoroscopically and the sutures tightened on the circular clavicular button (Fig. 1). Wound was then closed in layers.

Postoperatively, all patients were placed in a sling immobilizer for 4–6 weeks. Gentle pendulums and Codman's were begun postop day 1. Passive shoulder motion was started at 4 weeks (elevation <90), with full active motion at 6 weeks. Patients were allowed to return to manual work or sports at 4–5 months depending on the rehabilitation.

### 3. Results

There were eight men and three women. Average age of the patients was 34.2 years. According to Rockwood classification, there were 6 type III, 2 type IV and three type V. The mechanism of injury was bicycle accident in two, motor vehicle accident in seven and fall from height in two. The average interval between injury and surgery was 5.4 days. Mean coracoclavicular distance preoperatively was 18.9 (1.4) mm. Postoperative radiographs showed that reduction was good in all patients. Postoperative coracoclavicular distance was 11(0.5) mm.

The overall mean follow-up time was 12 months. The mean constant score was  $82 \pm 0.84$ . One (9%) patient rated the outcome as good, 8 (72%) rated it as satisfactory and 2 (18%) rated it as poor (Table 1). Mechanism of injury and modes of failure are summarized in Table 2. Two patients showed loss of full reduction and they were reoperated with double suture button (Dog Bone Button, Arthrex). All patients except one, who underwent resurgery, returned to their previous occupation.

### 4. Discussion

The management of acromioclavicular joint disruptions is continuously evolving. Various surgical options have been described for this injury. Traditionally done open techniques are being replaced by arthroscopic fixation.

Arthroscopic stabilization of acute AC joint dislocation is a minimally invasive procedure providing the coracoclavicular ligament complex with dynamic stability. The tightrope is a device originally described for reduction and fixation of tibiofibular syndesmosis. However, few studies have described the results of arthroscopic fixation of AC jt injury using tightrope.<sup>9–11</sup>

In our study, although initial reduction was good in all of the patients, however, radiologically failure occurred in 54% of patients. This cannot be attributed to technical failure since technical failure occurs within one month of surgery. Therefore, the reasons for failure of reduction were considered most probably due to non-distribution of stress forces onto a single suture button (AC tightrope) leading to clavicular or coracoid side pull through.

Similar to our study, other authors have also reported high failure rate. In a study by Lim et al., eight patients with an acute acromioclavicular joint injury were managed with implantation of one tightrope device. The patients were followed for a minimum of 6 months. They noted a 50% fixation failure rate, with loss of reduction occurring between the second and sixth postoperative weeks. Retrieved specimens revealed suture abrasion that was postulated to be the mechanism of failure. At final follow-up, 4 of the 8 patients had uneventful recovery with no pain and resumption of full duties.<sup>13</sup> Thiel et al. reported a failure rate of 16.6% in their series.<sup>11</sup> El Sallakh studied 10 patients and reported only one failure of fixation, which was the result of a technical error.<sup>10</sup>

Despite high rate of failure/loss of reduction, as observed on follow-up radiographs, this was not accompanied by any clinical problems and functional results, as measured by Constant–Murley score. The score was satisfactory in most but not excellent. This is consistent with the observations of other authors. Biomechanical studies have shown that tightrope has comparable biomechanical properties to the native coracoclavicular ligaments. Still tightrope has a high failure rate.<sup>14,15</sup>

The use of double tightrope may decrease the failure rate as shown by recent studies. However, loss of reduction has also been observed with the use of two tightropes. The double tightrope reconstruction technique more closely recreates the anatomy of acromioclavicular joint and the coracoclavicular complex. Salzmann et al. reported results of 23 patients of AC jt injury treated with 2 tightrope devices. At a mean follow-up of 30 months, they noted significant improvement in visual analogue scale and Constant–Murley scores. Postoperative radiographs showed unsatisfactory alignment in 8 cases. However, they noted no difference in clinical outcome compared to the patient who maintained reduction.<sup>16</sup> Scheibel et al. in their series of 28 patients of AC jt injuries managed with double tightrope showed good to excellent early results in all patients without any case of implant failure. However, 43% of their patients had posterior instability. To avoid this, they recommended addition of a percutaneous image intensifier controlled acromioclavicular cerclage in addition to the coracoclavicular stabilization.<sup>12</sup> The use of double tightrope has certain disadvantages, such as higher risks of coracoid fracture, extension of operative time and higher costs.

The principal limitation of this study is the small sample size and lack of control.

## 5. Conclusion

Arthroscopic stabilization of acute ACJ dislocations using a single tightrope implant is a minimally invasive surgical technique but with less satisfactory result, and may be because of non-biological nature, technical failure or implant failure.

## Conflicts of interest

All authors have none to declare.

## REFERENCES

1. Clayton RA, Court-Brown CM. The epidemiology of musculoskeletal tendinous and ligamentous injuries. *Injury*. 2008;39(12):1338–1344.
2. Rockwood CA, Williams GR, Young DC. *Fractures in Adults: Acromioclavicular Injuries*. Philadelphia, PA: Lippincott-Raven; 1996:1341–1413.
3. Horn JS. The traumatic anatomy and treatment of acute acromioclavicular dislocation. *J Bone Joint Surg Br*. 1954;36:194–1201.
4. Lemos MJ. The evaluation and treatment of the injured acromioclavicular joint in athletes. *Am J Sports Med*. 1998;26:137–144.
5. Fauci F, Merolla G, Paladini P, Campi F, Porcellini G. Surgical treatment of chronic acromioclavicular dislocation with biologic graft vs synthetic ligament: a prospective randomized comparative study. *J Orthop Trauma*. 2013;14(December (4)):283–290.
6. Jafary D, Keihan Shokouh H, Najd Mazhar F, Shariat Zadeh H, Mochtary T. Clinical and radiological results of fixation of acromioclavicular joint dislocation by hook plates retained for more than five months. *Trauma Mon*. 2014;19(April (2)):e13728.
7. Mardani-Kivi M, Mirbolook A, Salariyeh M, Hashemi-Motlagh K, Saheb-Ekhtiari K. The comparison of ethibond sutures and semitendinosus autograft in the surgical treatment of acromioclavicular dislocation. *Acta Orthop Traumatol Turc*. 2013;47(5):307–310.
8. El Shewy MT, El Azizi H. Suture repair using loop technique in cases of acute complete acromioclavicular joint dislocation. *J Orthop Trauma*. 2011;12(March (1)):29–35.
9. Hou Z, Graham J, Zhang Y, et al. Comparison of single and two tunnels techniques during open treatment of acromioclavicular joint disruption. *BMC Surg*. 2014;14:53.
10. El Sallakh SA. Evaluation of arthroscopic stabilization of acute acromioclavicular joint dislocation using the tightrope system. *Orthopaedics*. 2012;35(1):e18–e22.
11. Thiel E, Mutnal A, Gilot GJ. Surgical outcome following arthroscopic fixation of acromioclavicular joint disruption with the tightrope device. *Orthopedics*. 2011;34(7):e267–e274.
12. Scheibel M, Dröschel S, Gerhardt C, Kraus N. Arthroscopically assisted stabilization of acute high grade acromioclavicular joint separations. *Am J Sports Med*. 2011;39(July (7)):1507–1516.
13. Lim YW, Sood A, Van Riet RP. Acromioclavicular joint reduction, repair and reconstruction using metallic buttons—early results and complications. *Tech Shoulder Elbow Surg*. 2007;8(4):213–221.
14. Nüchtern JV, Sellenschloh K, Bishop N, et al. Biomechanical evaluation of 3 stabilization methods on acromioclavicular joint dislocations. *Am J Sports Med*. 2013;41(June (6)):1387–1394.
15. Lädermann A, Gueorguiev B, Stimec B, Fasel J, Rothstock S, Hoffmeyer P. Acromioclavicular joint reconstruction: a comparative biomechanical study of three techniques. *J Shoulder Elbow Surg*. 2013;22(February (2)):171–178.
16. Salzmänn GM, Walz L, Buchmann S, Glabgoly P, Venjakob A, Imhoff AB. Arthroscopically assisted 2 bundle anatomical reduction of acute acromioclavicular joint separations. *Am J Sports Med*. 2010;38(June (6)):1179–1187.

Available online at [www.sciencedirect.com](http://www.sciencedirect.com)

ScienceDirect

journal homepage: [www.elsevier.com/locate/jajs](http://www.elsevier.com/locate/jajs)

## Original Article

# Comparison of CT-based patient-specific templating and digital radiography templating in total knee arthroplasty



Rutul R. Gandhi<sup>a,\*</sup>, Alfonso Manzotti<sup>b</sup>, Norberto Confalonieri<sup>b,c</sup>,  
Peitro Cerveri<sup>d</sup>

<sup>a</sup> Fellow in Arthroplasty and Computer Assisted Surgery, Orthopedics and Traumatology, CTO Hospital, via Bignami, Milan, Italy

<sup>b</sup> Professor, 1st Department, Orthopedics and Traumatology, CTO Hospital, via Bignami, Milan, Italy

<sup>c</sup> Head, 1st Department, Orthopedics and Traumatology, CTO Hospital, via Bignami, Milan, Italy

<sup>d</sup> Department of Electronics, Information and Bioengineering Politecnico di Milano, Milan, Italy

## ARTICLE INFO

## Article history:

Received 22 November 2015

Accepted 13 January 2016

Available online 5 March 2016

## Keywords:

Knee arthroplasty

Digital templating

Patient-specific templating

CT templating

Templating accuracy

## ABSTRACT

**Aim:** The aim of the prospective study is to evaluate and compare the accuracy of digital templating and CT-based templating in preoperative planning, in determining the size of the femoral and tibial component in total knee arthroplasty.

**Materials and methods:** A prospective study was conducted to compare the accuracy in predicting the size of the prosthetic components in total knee replacement in 81 patients. Preoperatively, all the patients underwent the same standard protocol including digital radiographs with calibration and a CT scan. A dedicated IMPAX digital software was used to template the radiographs. The CT-based planning was performed on 3D reconstruction of CT scans as per standardized protocol for patient-specific instrumentation.

**Result:** The planning of digital radiography indicates the correct size in 71% of the cases for the femoral component and 47% for the tibial component. CT-based planning reached an accuracy of 93% for the femur and 54% for the tibia in predicting the exact size. The accuracy reaches 100% for both components if considered the maximum error of one size in CT-based planning. There were no surgical complications in any of the cases.

**Discussion:** The improvement in the ability to predict the size of the prosthetic components obtained by the CT images is statistically significant compared to that obtained by the radiographic study to predict the size of the tibial and femoral component. CT can indicate the number of size within the maximum error of measurement of one size in 100% of cases and this can be helpful to the surgeon and the organization in terms of trays to be sterilized, OR turnover, and cost savings. It appears that CT-based patient-specific templating is relatively easy to use, less invasive, saves time, and improves the accuracy in the positioning of the prosthetic components.

© 2016 International Society for Knowledge for Surgeons on Arthroscopy and Arthroplasty. Published by Elsevier, a division of Reed Elsevier India, Pvt. Ltd. All rights reserved.

\* Corresponding author at: Parekh's Hospital, Ahmedabad, India. Tel.: +91 9925037911.

E-mail address: [rutulgandhi2005@yahoo.co.in](mailto:rutulgandhi2005@yahoo.co.in) (R.R. Gandhi).

<http://dx.doi.org/10.1016/j.jajs.2016.01.001>

2214-9635/© 2016 International Society for Knowledge for Surgeons on Arthroscopy and Arthroplasty. Published by Elsevier, a division of Reed Elsevier India, Pvt. Ltd. All rights reserved.

## 1. Introduction

Accurate alignment and positioning of implants in total knee arthroplasty (TKA) is an important goal of the procedure.<sup>1-7</sup> Numerous studies have demonstrated a high frequency of implant malalignment in TKA, regardless of the surgical techniques utilized.<sup>8-10</sup> The innovation cycle of TKA has mirrored this fundamental concept. Initially, free-hand surgical cuts were performed prior to the placement of implant components. Subsequently, mechanical alignment guides were devised based on bony or external landmarks, and predetermined angular or measured resections were performed. More recently, imageless computer navigation systems have been developed to guide the surgical procedure and ultimate component alignment. The most recent innovation in TKA is patient-specific instrumentation (PSI), which has been introduced as a next generation technology in an effort to further improve the accuracy and precision of surgical technique, implant placement, and alignment. The advantages of PSI include normal realignment of the mechanical axis, minimized resection of the patient's bony tissue, reduced perioperative and postoperative blood loss, and reduced thromboembolic complications.<sup>11-13</sup>

An anticipated advantage of the PSI technology is the decrease in the number of trays to be sterilized for every TKA and hence the related cost benefit. But this depends on the accuracy of the technology to predict the exact size of the implant to be used. PSI may potentially achieve more reliable alignment parameters, decrease operative time and blood loss, and increase efficiency when compared with conventionally instrumented TKA.<sup>1,14-18</sup> However, a previous report<sup>18</sup> suggested that frequent intraoperative surgeon-directed changes may still be required. Thus, there is a need for more evidence-based data that evaluate and quantify the accuracy and reliability of CT-based templating in PSI.

Aim of this prospective study is to evaluate and compare the accuracy of two different types of preoperative planning, in determining the size of the femoral and tibial component in TKA. The two compared techniques were digital radiography and CT-based PSI (Fig. 1). Specifically, we asked the following questions:

- (1) What percentage of times was the preoperative plan able to accurately predict the actual size of the implanted femoral or tibial components?
- (2) What percentage of knees was implanted without any changes?

## 2. Materials and methods

A prospective study was conducted to compare the accuracy in predicting the size of the prosthetic components in total knee replacement in 81 patients diagnosed with primary and symptomatic osteoarthritis of the knee. Inclusion criteria were "Easy Knee": BMI  $\leq 35$ , varus/valgus deviation  $\leq 15^\circ$ , and residual flexion of the knee  $\geq 90^\circ$ .

Out of 81 patients, 37 were women and 44 were men; mean age was 68.5 years, the range extended from 53 to 79 years. In 48 cases, right side was involved, while in other 33 cases, left side was involved.

The mean hip-knee-ankle (HKA) angle is  $177.4^\circ$  and range was from  $172$  to  $184^\circ$ . Preoperatively, all the patients underwent the same standard protocol including digital radiographs with calibration and a CT scan. A dedicated IMPAX digital software (Agfa-Gevaert, NV, USA) was used to template the radiographs. On these radiographs, a sphere, 25 mm in diameter (size suggested by the manufacturer of the software), was included, which is necessary in order to properly calibrate the images and avoid systematic errors due to radiographic magnification, that is variable between the different radiographs. The best position of the sphere is medial or lateral to the knee, as close as possible to the bone level. After drawing all the axes for femur and tibia, the best fitting component is selected according to the make, model, and size of the implant.

The CT-based planning was performed on 3D reconstruction of CT scans of three joints: hip, knee, and ankle, as established in standardized protocol to build up patient-specific cutting mask (MyKnee, Medacta, Castel S. Pietro, Switzerland). All the surgeries were performed by two senior authors (M.A. and N.C.) using the same implant, and the definitive component sizes implanted were registered and

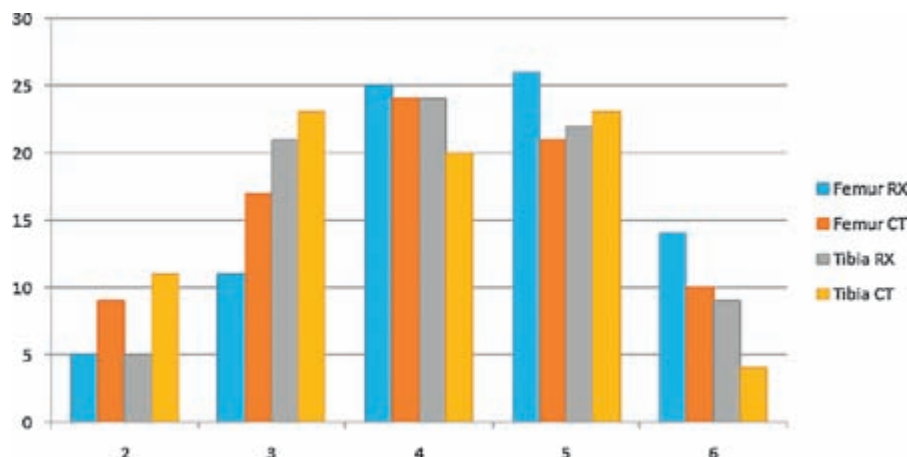


Fig. 1 – Comparison of the size of the femoral and tibial component predicted by X-ray and CT templating.

compared with the sizes suggested by both planning techniques considering also the range of error. Results' analysis was carried out using nonparametric tests.

### 3. Result

The planning of digital radiography indicates the correct size in 71% of the cases for the femoral component and 47% for the tibial component. The accuracy reaches 92-95% for both components if we consider the maximum error of one size. By evaluating the correlation of the two components together, it appears that in 65% of cases the planning digital X-ray shows exactly the prosthetic components to be implanted; this percentage becomes 93% when considering a margin of error of up to one size (Table 1).

CT-based planning reached an accuracy of 93% for the femur and 67% for the tibia considering the exact size. The accuracy reaches 100% for both components if considered the maximum error of one size. By evaluating the correlation of the two components together, it appears that in 80% of cases, the CT-based planning predicts exactly the prosthetic components to be implanted; this percentage becomes 100% as a margin of error of up to one size (Table 1).

The mean postoperative HKA angle was 177.53° (range: 173-183).

There is a statistically significant difference in X-ray-based planning and CT-based planning for predicting femur size ( $p < 0.01$ ), while there was no statistical significance as far as tibia was concerned. When comparing both femur and tibia, CT-based planning showed statistically significant accurate results compared to X-ray planning ( $p < 0.01$ ).

There were no surgical complications, including bleeding, wound complications, arterial or venous thromboembolic disease, vascular injury, neural deficit, ligament injury, instability, stiffness, fracture, infection, osteolysis, or implant loosening during any of the cases.

### 4. Discussion

The digital templating is a technique of preoperative study used to try to predict in advance the size of the prosthesis to be implanted. This method is spreading in orthopedic surgery

and has largely replaced the study of analog X-rays and acetate templating.

Several studies have shown a good ability to predict, through planning of digital radiography, the size of the tibial and femoral components of the prosthesis to be implanted.<sup>19-21</sup> In addition, the planning can provide an estimate of the angle of the bone cuts to be performed in the operating room, which can help in making a decision on how to proceed during surgery. It also allows for prevention of possible errors or technical difficulties at the time of surgery.<sup>20</sup>

However, previous studies have suggested that templating with regard to implant size selection may provide inaccurate results and the findings are not reproducible (Table 2).<sup>22-26</sup>

Trickett et al.<sup>22</sup> showed accuracy to the exact size by 50%, rising to 98% if we considered a maximum error of one size. The femoral component was generally scheduled with higher accuracy compared to that of the tibial component.

Heal and Blewitt<sup>23</sup> found preoperative radiological templating to be accurate in just 57% of cases and thus questioned its usefulness in preoperative management.

Hsu et al.,<sup>26</sup> studying 48 patients undergoing total knee replacement, as well as confirming that 54% of the size of the prosthesis was correctly predicted by the digital templating, also stated that there were no statistically significant differences when digital planning was done by an experienced surgeon in prosthetic surgery of the knee than one with less experience.

Kobayashi et al.<sup>27</sup> have finally compared the accuracy of traditional two-dimensional X-ray and three-dimensional CT scan, while getting superior results with CT, and showed that the improvement was not statistically significant and this would seem to indicate the non-necessity of preoperative CT scan in TKA.

It is therefore unclear whether these emerging technologies offer a real cost benefit or result in an improved outcome. Hence, the present study tried to evaluate the usefulness and reliability of the preoperative CT-based templating to predict the component size compared to the digital templating.

In our study, the improvement in the ability to predict the size of the prosthetic components obtained by the CT images is statistically significant compared to that obtained by the radiographic study to predict the size of the tibial and femoral component.

In fact, it was possible to predict the size of the prosthetic implant with digital radiograph in 72% of cases for the femoral

**Table 1 – Correlation between the X-ray and CT-based template size and final implant size used.**

Planning error (no. planned size vs installed size)	Femur and tibia		Femur		Tibia	
	Rx	CT-based	Rx	CT-based	Rx	CT-based
-2	0	0	0	0	0	0
-1	18 (11.2%)	26 (16.0%)	1 (1.2%)	2 (2.5%)	17 (21.0%)	24 (29.6%)
0	105 (64.8%)	130 (80.2%)	58 (71.7%)	76 (93.8%)	47 (58.0%)	54 (66.7%)
+1	28 (17.2%)	6 (3.8%)	15 (18.5%)	3 (3.7%)	13 (16.0%)	3 (3.7%)
+2	11 (6.8%)	0	7 (8.6%)	0	4 (5.0%)	0
Overall	162	162	81	81	81	81
Within ±1	151 (93%)	162 (100%)	73 (90%)	81 (100%)	77 (95%)	81 (100%)
Over ±1	11 (6.7%)	0	7 (8.6%)	0	4 (4.9%)	0

**Table 2 – Literature review of studies related to accuracy of digital templating in TKA.**

References	Patients (N)	Exact femur (%)	±1 femur (%)	Exact tibia (%)	±1 tibia (%)
Miller and Putill <sup>28</sup>	25	52	100	48	96
The et al. <sup>29</sup>	65	55	92	52	94
Trickett et al. <sup>22</sup>	40	48	98	55	100
Kniesel et al. <sup>30</sup>	46	43	97	71	98
Hsu et al. <sup>26</sup>	82	83	100	90	100
Hsu et al. <sup>26</sup>	48	58	96	50	88
Levine et al. <sup>31</sup>	176	69	100	63	97
Peek et al. <sup>25</sup>	92	71	100	60	100
Specht et al. <sup>19</sup>	50	48	92	52	94
Del Gaizo et al. <sup>20</sup>	76	66	99	66	97
Overall	700	63	98	63	97

component and 58% for the tibial component, the accuracy reached 94% and 67%, respectively as predicted by the CT. It can be concluded from the study that the data obtained by CT provide the surgeon with greater safety in deciding the size of the prosthetic components.

Another conclusion obtainable from the study is that CT can indicate the number of size within the maximum error of measurement of one size in 100% of cases, and this can certainly be helpful to the surgeon in planning the prosthesis to be implanted, also at organizational level, it ensures access to the necessary size and can save time and cost in the preparation of the operating room and sterilization of necessary trays and also reduces the risk of infection.<sup>26</sup>

Regarding costs, they are definitely smaller than the computer-assisted surgery, while, compared with the traditional. It is difficult to evaluate, since, if on the one hand, the technology PSI has increased spending for the CT or MRI and for the creation of templates cutting, on the other hand, there is a saving linked to the lesser quantity of material to be sterilized and especially the reduction of the surgical time and risk of infection.<sup>26</sup>

However, all the obtained information is subject to various limitations.

First, the relative narrowness of the sample is definitely the basis of this lack of significance.

Also our study only concerns the accuracy of the implant size selection in preoperative templating and does not refer to the overall planning of the TKA procedure regarding component placement and alignment.

Another limitation in the data analysis is the significant difference between the accuracy that the CT demonstrates in determining the size of the femoral component, which reaches 94%, when compared to the 67% achieved for the tibial component. This remarkable difference is hard to justify. Perhaps, it is due to the different reference taken by the surgeon during preoperative planning and intraoperatively to determine the rotational alignment of the tibial component. Another possible explanation is searchable in the fact that the surgical saw used to perform the bone cutting has a margin of movement which, although minimal, is still present and can vary its inclination, thus making the surface of bone also different from cover with the prosthetic component.

A further explanation that tries to explain the difference described is represented by the possibility that during the intervention, the surgeon might have needed to refine the

tibial cut to lower the joint line, to allow better alignment with the femoral component or to improve the ligament balancing. Finally, the manufacturer of the masks and cutting of the prosthesis states that the software is designed in such a way that, if the size of prosthetic seems to fall in the middle between two measurements, the lower size is selected by default.

Overall, therefore, with the first data available in the literature, it appears that technology-based patient-specific templating is relatively easy to use, less invasive, saves time, and improves the accuracy in the positioning of the prosthetic components.

The sample of patients present in the literature studies is limited, and for now, although the results appear better than the conventional method, it is necessary to extend such studies both with regard to the number of subjects and with regard to the period of follow-up. In our study the accuracy of the X-ray planning using dedicated software confirms the results obtained by other studies in the literature. Likewise the CT-based planning does provide significant more accurate data and the error is never more than one size. Further studies are needed to evaluate potential economical advantages in term of reducing hardware and sterilization costs in the operating theater despite more expensive exams.

## Conflicts of interest

All authors have none to declare.

## REFERENCES

- Ng VY, DeClaire JH, Berend KR, Gulick BC, Lombardi Jr AV. Improved accuracy of alignment with patient-specific positioning guides compared with manual instrumentation in TKA. *Clin Orthop Relat Res.* 2012;470(1):99–107.
- Rosenberger RE, Hoser C, Quirbach S, Attal R, Hennerbichler A, Fink C. Improved accuracy of component alignment with the implementation of image-free navigation in total knee arthroplasty. *Knee Surg Sports Traumatol Arthrosc.* 2008;16(3):249–257.
- Dutton AQ, Yeo SJ, Yang KY, Lo NN, Chia KU, Chong HC. Computer assisted minimally invasive total knee arthroplasty compared with standard total knee

- arthroplasty. A prospective, randomized study. *J Bone Joint Surg Am.* 2008;90(1):2-9.
4. Chin PL, Yang KY, Yeo SJ, Lo NN. Randomized control trial comparing radiographic total knee arthroplasty implant placement using computer navigation versus conventional technique. *J Arthroplasty.* 2005;20(5):618-626.
  5. Hernández-Vaquero D, Suarez-Vazquez A, Sandoval-Garcia MA, Noriega-Fernandez A. Computer assistance increases precision of component placement in total knee arthroplasty with articular deformity. *Clin Orthop Relat Res.* 2010;468(5):1237-1241.
  6. Kim YH, Kim JS, Yoon SH. Alignment and orientation of the components in total knee replacement with and without navigation support: a prospective, randomised study. *J Bone Joint Surg Br.* 2007;89(4):471-476.
  7. Park SE, Lee CT. Comparison of robotic-assisted and conventional manual implantation of a primary total knee arthroplasty. *J Arthroplasty.* 2007;22(7):1054-1059.
  8. Patil S, D'Lima DD, Fait JM, Colwell Jr CW. Improving tibial component coronal alignment during total knee arthroplasty with use of a tibial planning device. *J Bone Joint Surg.* 2007;89(2):381-387.
  9. Mizu-uchi H, Matsuda S, Miura H, Higaki H, Okazaki K, Iwamoto Y. The effect of ankle rotation on cutting of the tibia in total knee arthroplasty. *J Bone Joint Surg.* 2006;88(12):2632-2636.
  10. Matziolis G, Krockner D, Weiss U, Tohtz S, Perka C. A prospective, randomized study of computer-assisted and conventional total knee arthroplasty: three-dimensional evaluation of implant alignment and rotation. *J Bone Joint Surg.* 2007;89(2):236-243.
  11. Lombardi Jr AV, Berend KR, Adams JB. Patient specific approach in total knee arthroplasty. *Orthopedics.* 2008;31(9):927-930.
  12. Daniilidis K, Tibesku CO. A comparison of conventional and patient specific instruments in total knee arthroplasty. *Int Orthop.* 2014;38(3):503-508.
  13. Conteduca F, Iorio R, Mazza D, Ferretti A. Patient specific instruments in arthroplasty. *Int Orthop.* 2014;38(2):259-265.
  14. Howell SM, Kuznik K, Hull ML, Siston RA. Results of an initial experience with custom-fit positioning total knee arthroplasty in a series of 48 patients. *Orthopedics.* 2008;31(9):857-863.
  15. Watters TS, Mather III RC, Browne JA, Berend KR, Lombardi Jr AV, Bolognesi MP. Analysis of procedure-related costs and proposed benefits of using patient-specific approach in total knee arthroplasty. *J Surg Orthop Adv.* 2011;20(2):112-116.
  16. Spencer BA, Mont MA, McGrath MS, Boyd B, Mitrick MF. Initial experience with custom-fit total knee replacement: intra-operative events and long-leg coronal alignment. *Int Orthop.* 2009;33(6):1571-1575.
  17. Heysse TJ, Tibesku CO. Improved femoral component rotation in TKA using patient-specific instrumentation. *Knee.* 2014;21(1):268-271.
  18. Stronach BM, Pelt CE, Erickson J, Peters CL. Patient-specific total knee arthroplasty requires frequent surgeon-directed changes. *Clin Orthop Relat Res.* 2013;471(1):169-174.
  19. Specht LM, Levitz S, Iorio R, Healy WL, Tilzey JF. A comparison of acetate and digital templating for total knee arthroplasty. *Clin Orthop Relat Res.* 2007;464:179-183.
  20. Del Gaizo D, Soileau ES, Lachiewicz PF. Value of preoperative templating for primary total knee arthroplasty. *J Knee Surg.* 2009;22(4):284-293.
  21. Parvizi J. Digital templating: here to stay. *Am J Orthop (Belle Mead NJ).* 2011;40(8):394.
  22. Trickett RW, Hodgson P, Forster MC, Robertson A. The reliability and accuracy of digital templating in total knee replacement. *J Bone Joint Surg Br.* 2009;91(7):903-906.
  23. Heal J, Blewitt N. Kinemax total knee arthroplasty: trial by template. *J Arthroplasty.* 2002;17:90-94.
  24. Arora J, Sharma S, Blyth M. The role of preoperative templating in primary total knee replacement. *Knee Surg Sports Traumatol Arthrosc.* 2005;13(3):187-189.
  25. Peek AC, Bloch B, Auld J. How useful is templating for total knee replacement component sizing? *Knee.* 2012;19(4):266-269.
  26. Hsu AR, Gross CE, Bhatia S, Levine BR. Template-directed instrumentation in total knee arthroplasty: cost savings analysis. *Orthopedics.* 2012;35(11):e1596-e1600.
  27. Kobayashi A, Ishii Y, Takeda M, Noguchi H, Higuchi H, Toyabe S. Comparison of analog 2D and digital 3D preoperative templating for predicting implant size in total knee arthroplasty. *Comput Aided Surg.* 2012;17(2):96-101.
  28. Miller AG, Purtill JJ. Accuracy of digital templating in total knee arthroplasty. *Am J Orthop (Belle Mead NJ).* 2012;41(11):510-512.
  29. The B, Diercks RL, van Ooijen PM, van Horn JR. Comparison of analog and digital preoperative planning in total hip and knee arthroplasties. A prospective study of 173 hips and 65 total knees. *Acta Orthop.* 2005;76(1):78-84.
  30. Kniessel B, Konstantinidis L, Hirschmüller A, Südkamp N, Helwig P. Digital templating in total knee and hip replacement: an analysis of planning accuracy. *Int Orthop.* 2014;38(4):733-739.
  31. Levine B, Fabi D, Deirmengian C. Digital templating in primary total hip and knee arthroplasty. *Orthopedics.* 2010;33(11):797.

Available online at [www.sciencedirect.com](http://www.sciencedirect.com)

ScienceDirect

journal homepage: [www.elsevier.com/locate/jajs](http://www.elsevier.com/locate/jajs)

## Original Article

# A radiological comparative study between transtibial & anteromedial portal drilling of femoral tunnel in single bundle anterior cruciate ligament reconstruction: A comparison of four angles



Siddharth M. Shetty<sup>a</sup>, Vikram Shetty<sup>a</sup>, Arjun Ballal<sup>b,\*</sup>,  
Jeetu Mohanchandran<sup>d</sup>, Anoop Hegde<sup>c</sup>

<sup>a</sup> Associate Professor, K.S Hegde Medical Academy, Mangalore 575018, India

<sup>b</sup> Registrar, ARS Hospital, Tirupur 641604, India

<sup>c</sup> Registrar, Orthopaedic Surgeon, ARS Hospital, Tirupur 641604, India

<sup>d</sup> Postgraduate, Department Of Orthopaedic surgery, K.S Hegde Medical Academy, Mangalore 575018, India

## ARTICLE INFO

## Article history:

Received 15 August 2015

Accepted 12 November 2015

Available online 9 December 2015

## Keywords:

Anterior cruciate ligament

Transtibial

Transportal

Condylar tunnel angle

Shaft tunnel angle

Tunnel screw angle

## ABSTRACT

Femoral tunnel drilling for graft insertion is performed by transtibial or transportal technique.

**Aim:** Main objective of this study was to compare the postoperative anteroposterior and lateral radiographs after arthroscopic ACL reconstruction by transtibial and transportal techniques by measuring four angles.

**Materials and methods:** A retrospective study of 60 patients was conducted, who were further subdivided into two groups containing 30 each. The first group had patients who had undergone arthroscopic ACL reconstruction by transtibial technique and the second group had patients who had undergone ACL reconstruction by transportal technique. Post-operative anteroposterior radiographs (AP) and lateral radiographs of the operated knees were compared. Condylar tunnel (CT) and tunnel screw (TS) angles were measured in AP radiographs and compared. In lateral radiographs, shaft tunnel (ST) and TS angles were measured and compared. 'Student t-test' was used in calculating the results.

**Results:** Mean of the angles measured were tabulated and compared. CT angle was noted to be more acute in transportal group ( $38.4 \pm 8.756^\circ$ ) as compared to transtibial group ( $46.97 \pm 12.754^\circ$ ) with a significant 'p-value' (0.004). ST angle was noted to be more obtuse in the transportal group ( $119.57 \pm 11.212^\circ$ ) as compared to transtibial group ( $113.17 \pm 12.793^\circ$ ) with a significant 'p-value' (0.044).

This infers that transportal technique oriented the graft more horizontal as compared to transtibial technique.

Tunnel screw angles when compared in AP radiographs showed that transportal technique ( $5.5 \pm 4.644^\circ$ ) had more acute angulation as compared to transtibial group ( $12.57 \pm 8.287^\circ$ ) with a significant 'p-value' (<0.001). Same results were obtained when the lateral

\* Corresponding author. Tel.: +91 7708913999.

E-mail address: [ArjunBallal@5arjunballal@gmail.com](mailto:ArjunBallal@5arjunballal@gmail.com) ([ArjunBallal@5arjunballal@gmail.com](mailto:ArjunBallal@5arjunballal@gmail.com)).

<http://dx.doi.org/10.1016/j.jajs.2015.11.011>

2214-9635/© 2015 International Society for Knowledge for Surgeons on Arthroscopy and Arthroplasty. Published by Elsevier, a division of Reed Elsevier India, Pvt. Ltd. All rights reserved.



views were compared between transportal ( $9.27 \pm 8.25^\circ$ ) and transtibial technique ( $23.73 \pm 12.174^\circ$ ) with a significant 'p-value' ( $<0.001$ ). This indicated reduced screw tunnel divergence in transportal technique as compared to transtibial technique.

**Conclusion:** Transportal technique results in a more anatomical femoral tunnel placement as compared to transtibial technique.

© 2015 International Society for Knowledge for Surgeons on Arthroscopy and Arthroplasty. Published by Elsevier, a division of Reed Elsevier India, Pvt. Ltd. All rights reserved.

## 1. Introduction

There has been evolution over the ages for techniques and methods of anterior cruciate ligament reconstruction. The prime concern has been to bring about anatomical placement of the graft in the knee. The anatomical placement improves the anteroposterior translation and reduces the pivot shifting, thereby providing better rotational stability and reducing posterior cruciate ligament impingement.<sup>1–7</sup> The transtibial technique employs drilling of the femoral tunnel through a pre-drilled tibial tunnel. Whereas the transportal technique is independent of any pre-drilled tunnel.<sup>8</sup> The angulation of the femoral tunnel in the transtibial technique depends on the angulation of the pre-drilled tibial tunnel.<sup>9–11</sup> Several anatomical studies have reported that the ACL lies deep and low on the medial wall of the lateral femoral condyle in its femoral attachment.<sup>12,13</sup> Musahl and colleagues reported that a tunnel position inside the anatomical footprint of ACL brings about knee kinematics almost similar to that of the intact knee.<sup>4</sup>

The length of the graft changes when the knee flexes and extends. This has more effect on the femoral attachment than the tibial attachment, even minimal displacement along the Blumensaat's line is particularly significant.<sup>5,14,15</sup> Graft healing is affected as there can be abnormal tensile and compressive loads in a non-anatomically placed graft.<sup>16</sup>

## 2. Aims and objectives

- To radiographically compare femoral tunnel position by use of transportal versus transtibial technique in primary single bundle ACL reconstruction.
- To test the hypothesis that transportal technique could afford a better femoral tunnel position than the transtibial technique.

## 3. Materials and methods

A retrospective study was conducted in our centre of a total of 60 patients who had undergone arthroscopic ACL reconstruction by transtibial and transportal technique from January 2012 to January 2015. All the cases had undergone femoral graft fixation by titanium interference screws. The details and post-operative X-rays of these patients were collected. The inclusion criteria of the study included skeletally mature patients with normal bony anatomy, with no associated joint pathology or associated bony injuries. The 60 patients were

subdivided into two groups of 30 patients each. The first group included patients who underwent ACL reconstruction by transtibial technique and the other group who underwent ACL reconstruction by transportal technique.

Four angles were calculated in these patients in the post-operative anteroposterior and lateral radiographs.

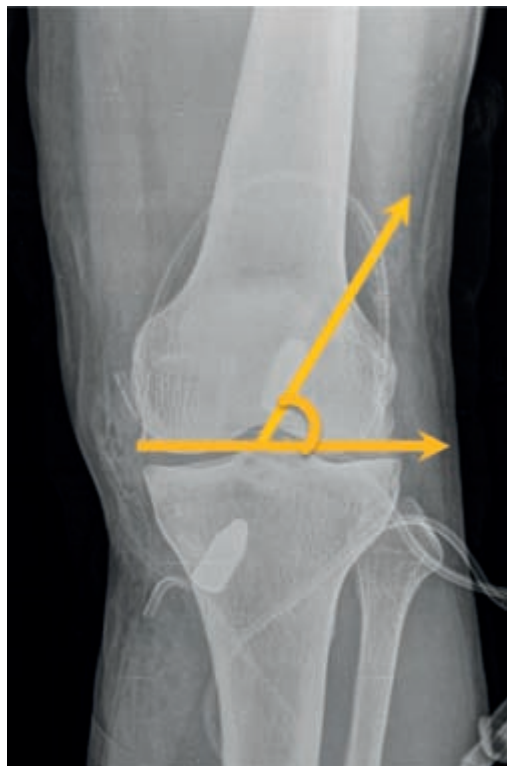In the anteroposterior (AP) radiograph:

- The condylar tunnel (CT) angle
- The tunnel screw (TS) angle

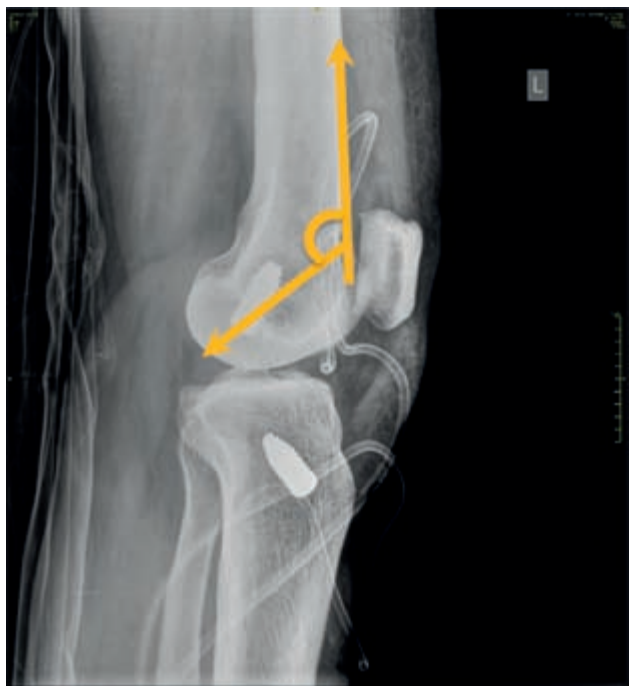In the lateral radiograph:

- The shaft tunnel (ST) angle
- The TS angle

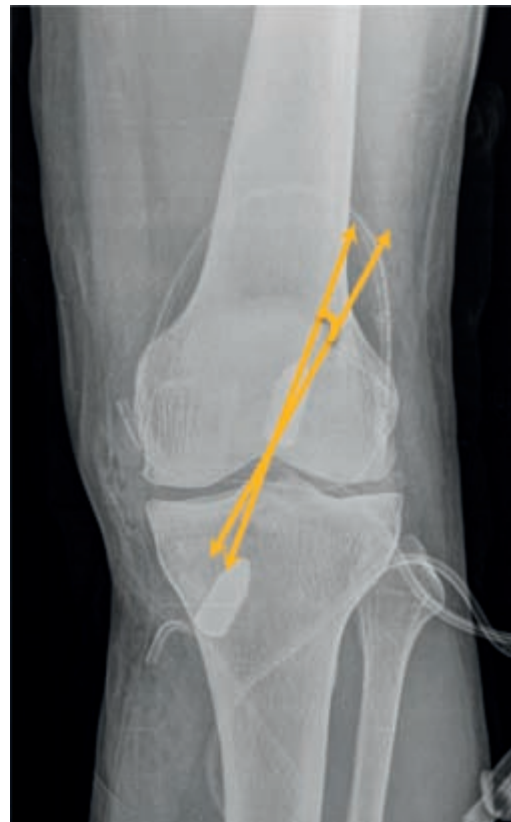**CT angle:** This angle was measured in the post-operative anteroposterior radiographs. A straight line was drawn joining



**Fig. 1 – Anteroposterior radiograph of left knee indicating the measurement of the condylar-tunnel angle. This is formed by a line drawn across the condyles of the femur and one line across the long axis of the femoral tunnel and the acute angle formed is measured.**



**Fig. 2 – Lateral radiograph of left knee indicating the measurement of the shaft-tunnel angle. This is formed by a line drawn across the long axis of the femoral shaft and one line across the long axis of the femoral tunnel and the obtuse angle formed is measured.**



**Fig. 3 – Anteroposterior radiograph of left knee indicating the measurement of the tunnel screw angle (divergence angle). This is formed by a line drawn across the long axis of the femoral tunnel and one line across the long axis of the interference screw and the acute angle formed is measured.**

both the femoral condyles. A second line straight line was drawn across the long axis of the femoral tunnel. The acute angle subtended by the intersection of these two lines formed the CT angle (Fig. 1).

*The ST angle:* This angle was measured in the post-operative lateral radiographs. A straight line was drawn along the long axis of the femoral shaft in the lateral view. A second line was drawn along the long axis of the femoral tunnel. The obtuse angle subtended by the intersection of these two lines formed the ST angle (Fig. 2).

*The TS angle:* This angle was measured in both anteroposterior and lateral radiographs. A straight line was drawn along the long axis of the femoral tunnel. The second line extended along the long axis of the screw. The angle subtended by the intersection of these two lines formed the TS angle (Figs. 3 and 4). It is also termed as the 'divergence angle'.

All the results were tabulated and the mean was compared statistically using the 'Student t-test'.

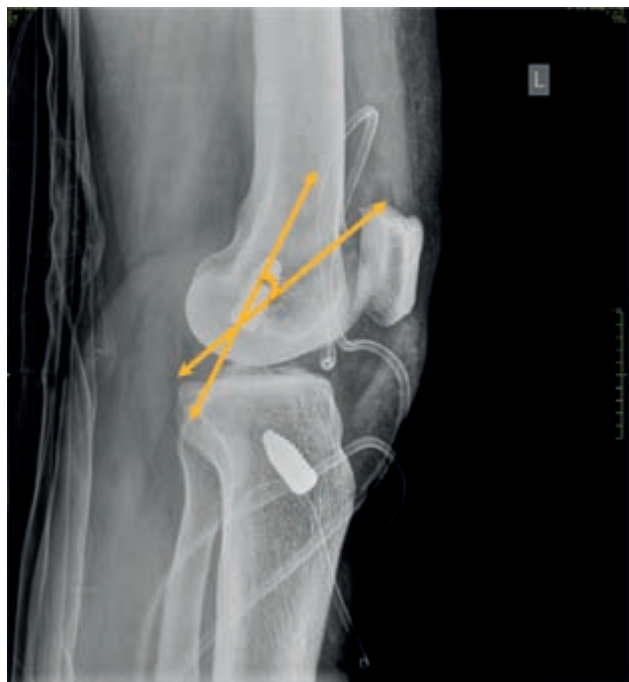#### 4. Results

All the results were tabulated and compared using the 'Student t-test' (Table 1).

On comparing the CT angles in anteroposterior radiographs, a mean of  $46.97 \pm 12.754^\circ$  was noted for the transtibial

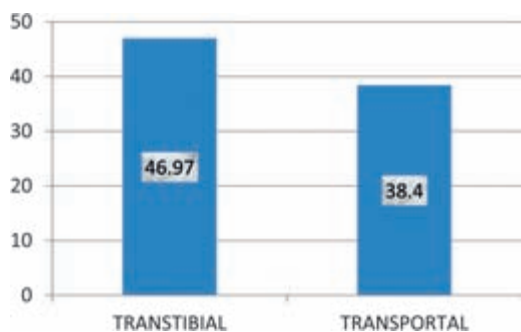
**Table 1 – Table indicating the mean and 'p-values' calculated for all the four angles measured in anteroposterior and lateral radiographs.**

	Group	N	Mean	Std. deviation	t	df	p value
Condylar-tunnel angle	Transportal	30	38.4	8.756	-3.033	58	0.004
	Transtibial	30	46.97	12.754			
Anteroposterior tunnel-screw angle	Transportal	30	5.5	4.644	-4.075	45.582	<0.001
	Transtibial	30	12.57	8.287			
Lateral tunnel-screw angle	Transportal	30	9.27	8.25	-5.388	58	<0.001
	Transtibial	30	23.73	12.174			
Shaft-tunnel angle	Transportal	30	119.57	11.212	2.061	58	0.044
	Transtibial	30	113.17	12.793			

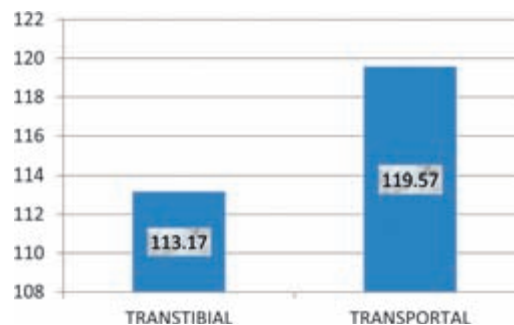


**Fig. 4 – Lateral radiograph of left knee indicating the measurement of the tunnel screw angle (divergence angle). This is formed by a line drawn across the long axis of the femoral tunnel and one line across the long axis of the interference screw and the acute angle formed is measured.**

group and  $38.4 \pm 8.756^\circ$  for the transportal group. This indicated that the CT angle was more acute and horizontal for the transportal technique than transtibial technique (Fig. 5). When the mean of ST angle was compared between transtibial and transportal techniques in the lateral radiographs, it was noted that the ST angle in the transportal technique had a mean of  $113.17 \pm 12.793^\circ$  in the transtibial technique and  $119.57 \pm 11.212^\circ$  for the transportal technique. This showed that the angle was more obtuse in the transportal



**Fig. 5 – Bar graph showing the comparison of the condylar tunnel angles of the two techniques. The x-axis represents the technique employed and the y-axis represents the mean calculated. It can be noted that the transportal technique brought about a more acute and horizontal femoral tunnel angulation.**



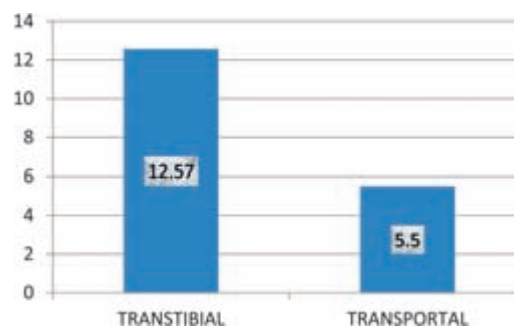
**Fig. 6 – Bar graph showing the comparison of the shaft tunnel angles of the two techniques. The x-axis represents the technique employed and the y-axis represents the mean calculated. It can be noted that the transportal technique brought about a more obtuse and horizontal femoral tunnel angulation.**

technique (Fig. 6), which indicated that the graft was horizontal in transportal technique. On comparing the TS angles in the anteroposterior radiographs, a mean of  $12.57 \pm 8.287^\circ$  was noted for the transtibial technique and  $5.5 \pm 4.644^\circ$  for the transportal technique (Fig. 7). This indicated a more acute angulation in the transportal technique, i.e.; reduced screw-tunnel divergence.

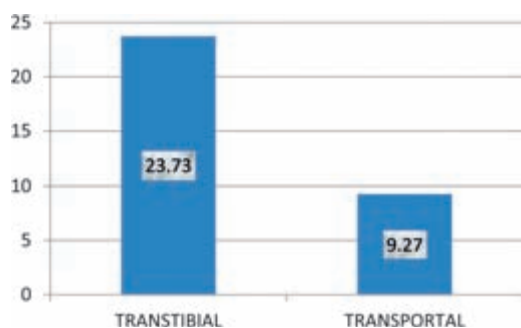
On comparing the TS angles in the lateral radiographs, the mean was noted to be  $23.73 \pm 12.174^\circ$  in transtibial technique and  $9.27 \pm 8.25^\circ$  in the transportal technique, also indicating reduced screw-tunnel divergence (Fig. 8).

## 5. Discussion

Our study reported a more vertically placed graft in the transtibial technique as compared to the transportal technique. Cain and Clancy reported a vertical placement of the graft in the femoral tunnel after transtibial technique of femoral tunnel drilling and also added that the tunnel was noted not to be centred on the native ACL footprint which



**Fig. 7 – Bar graph showing the comparison of the tunnel screw angles in the anteroposterior radiographs of the two techniques. The x-axis represents the technique employed and the y-axis represents the mean calculated. It can be noted that the transportal technique brought about a more acute femoral tunnel angulation, thereby indicating a reduced screw tunnel divergence.**



**Fig. 8 – Bar graph showing the comparison of the tunnel screw angles in the lateral radiographs of the two techniques. The x-axis represents the technique employed and the y-axis represents the mean calculated. It can be noted that the transportal technique brought about a more acute femoral tunnel angulation, thereby indicating a reduced screw tunnel divergence.**

could result in increased pivot shift.<sup>17</sup> Lee and colleagues reported that a subset of patients with vertically oriented grafts had poorer Lysholm scores as compared to ones with the more horizontally oriented grafts. They also added that this could result in reduced rotational stability.<sup>18</sup>

In transtibial technique, there is a tendency to place femoral tunnel more posteriorly.<sup>19–22</sup>

Kopf et al. compared tibial tunnel position in transtibial single bundle ACL reconstruction with cadaveric native ACL tibial footprint using CT scan. They concluded that anteroposterior position of tunnel in sagittal plane (48%) was significantly more posterior than the native anteromedial bundle footprint (25%).<sup>21</sup>

Steiner et al. performed ACL reconstructions using transtibial and transportal techniques on ten pairs of cadaveric knees. The graft placement was evaluated under direct vision. It was noted that there was more posterior placement of graft as compared to the transportal technique.<sup>23</sup>

There are studies which have reported that the anteromedial portal decreases graft tension and posterior cruciate ligament impingement as compared to transtibial technique.<sup>24,25</sup>

The results of this study indicate that both the angles prove horizontal position of the femoral tunnel using transportal approach. This supports the hypothesis that the use of a transportal approach in preparing the femoral tunnel in single bundle ACL reconstruction will result in a superior femoral tunnel position when compared with the transtibial technique.

## 6. Conclusion

Drilling of the femoral tunnel through the transportal technique enables a more horizontal and anatomical placement, resembling the native ACL of the femoral tunnel position with reduced screw-tunnel divergence when compared with the transtibial technique.

## Conflicts of interest

All authors have none to declare.

## REFERENCES

- Gabriel MT, Wong EK, Woo SL, Yagi M, Debski RE. Distribution of in situ forces in the anterior cruciate ligament in response to rotator loads. *J Orthop Res*. 2004;22:85–89.
- Yagi M, Wong EK, Kanamori A, Debski RE, Fu FH, Woo SL. Biomechanical analysis of anatomic anterior cruciate ligament reconstruction. *Am J Sports Med*. 2002;30:660–666.
- Yasuda K, Kondo E, Ichiyama H. Anteromedial reconstruction of anteromedial and posterolateral bundles of the anterior cruciate ligament using hamstring grafts. *Arthroscopy*. 2004;20:1015–1025.
- Musahil V, Plakseychuk A, VanScyoc A, et al. Varying femoral tunnels between the anatomical footprint and isometric positions: effect on kinematics of the anterior cruciate ligament-reconstructed knee. *Am J Sports Med*. 2005;33(5):712–718.
- Zavras TD, Race A, Bull AM, Amis AA. A comparative study of 'isometric' points for anterior cruciate ligament graft attachment. *Knee Surg Sports Traumatol Arthrosc*. 2001;9(1):28–33.
- Scopp JM, Jasper LE, Belkoff SM, Moorman III CT. The effect of oblique femoral tunnel placement on rotational constraint of the knee reconstructed using patellar tendon autografts. *Arthroscopy*. 2004;20(3):294–299.
- Irrgang JJ, Harner CD. Loss of motion following knee ligament reconstruction. *Sports Med*. 1995;19(2):150–159.
- Dai X, Cai Y. Measurement of anterior cruciate ligament angles in single-bundle reconstruction using the anteromedial portal. *Am J Orthop*. (June):2012;(June):268–272.
- Howell SM, Hull ML. Aggressive rehabilitation using hamstring tendons: graft construct, tibial tunnel placement, fixation properties, and clinical outcome. *Am J Knee Surg*. 1998;11(2):120–127. 23.
- Howell SM, Wallace MP, Hull ML, Deutsch ML. Evaluation of the single-incision arthroscopic technique for anterior cruciate ligament replacement. A study of tibial tunnel placement, intraoperative graft tension, and stability. *Am J Sports Med*. 1999;27(3):284–293.
- Georgoulis AD, Papadonikolakis A, Papageorgiou CD, Mitsou A, Stergiou N. Three-dimensional tibiofemoral kinematics of the anterior cruciate ligament-deficient and reconstructed knee during walking. *Am J Sports Med*. 2003;31(1):75–79.
- Arnold MP, Kooloos J, van Kampen A. Single-incision technique misses the anatomical femoral anterior cruciate ligament insertion: a cadaver study. *Knee Surg Sports Traumatol Arthrosc*. 2001;9(4):194–199.
- Colombet P, Robinson J, Christel P, et al. Morphology of anterior cruciate ligament attachments for anatomic reconstruction: a cadaveric dissection and radiographic study. *Arthroscopy*. 2006;22(9):984–992.
- Topliss C, Webb J. An audit of tunnel position in anterior cruciate ligament reconstruction. *Knee*. 2001;8(1):59–63.
- Muneta T, Yamamoto H, Sakai H, Ishibashi T, Furuya K. Relationship between changes in length and force in in vitro reconstructed anterior cruciate ligament. *Am J Sports Med*. 1993;21(2):299–304.
- Ménétreay J, Duthon VB, Laumonier T, Fritschy D. "Biological failure" of the anterior cruciate ligament graft. *Knee Surg Sports Traumatol Arthrosc*. 2008;16(3):224–231.

17. Cain Jr EL, Clancy Jr WG. Anatomic endoscopic anterior cruciate ligament reconstruction with patella tendon autograft. *Orthop Clin N Am.* 2002;33(4):717-725.
18. Lee MC, Seong SC, Lee S, et al. Vertical femoral tunnel placement results in rotational knee laxity after anterior cruciate ligament reconstruction. *Arthroscopy.* 2007;23(7):771-778.
19. Bowers AL, Bedi A, Lipman JD. Comparison of anterior cruciate ligament tunnel position and graft obliquity with transtibial and anteromedial portal femoral tunnel reaming techniques using high resolution magnetic resonance imaging. *Arthroscopy.* 2011;27:1511-1522.
20. Silva A, Sampaio R, Pinto E. ACL reconstruction: comparison between transtibial and anteromedial portal techniques. *Knee Surg Sports Traumatol Arthrosc.* 2012;20:896-903A.
21. Kopf S, Forsythe B, Wong AK, Tashman S, Irrgang JJ, Fu FH. Transtibial ACL reconstruction fails to position drill tunnels anatomically in vivo 3D CT study. *Knee Surg Sports Traumatol Arthrosc.* 2012;20:2200-2207.
22. Scanlan SF, Lai J, Donahue JP, Andriacchi TP. Variations in the three dimensional location and orientation of the ACL in healthy subjects relative to patients after transtibial ACL reconstruction. *J Orthop Res.* 2012;30:910-918.
23. Steiner ME, Battaglia TC, Heming JF, Rand JD, Festa A, Baria M. Independent drilling outperforms conventional transtibial drilling in anterior cruciate ligament reconstruction. *Am J Sports Med.* 2009;37:1912-1919.
24. Fujimoto E, Sumen Y, Deie M, Yasumoto M, Kobayashi K, Ochi M. Anterior cruciate ligament graft impingement against the posterior cruciate ligament: diagnosis using MRI plus three-dimensional reconstruction software. *Magn Reson Imaging.* 2004;22(8):1125-1129.
25. Phelan DT, Cohen AB, Fithian DC. Complications of anterior cruciate ligament reconstruction. *Instr Course Lect.* 2006;55:465-474.

Available online at [www.sciencedirect.com](http://www.sciencedirect.com)

journal homepage: [www.elsevier.com/locate/jajs](http://www.elsevier.com/locate/jajs)

## Original Article

# Mucoid degeneration of the anterior cruciate ligament: Partial arthroscopic debridement and outcomes



Gagan Khanna, Rajan Sharma, Aditya Bhardwaj<sup>\*</sup>, Harjot S. Gurdutta, Deepak K. Agrawal, Abhishek S. Rathore

Department of Orthopaedics, Sri Guru Ram Dass Institute of Medical Sciences and Research, Vallah, Amritsar, India

### ARTICLE INFO

#### Article history:

Received 28 May 2015

Accepted 7 December 2015

Available online 12 January 2016

#### Keywords:

Anterior cruciate ligament

Mucoid degeneration

Arthroscopic debridement

Notchplasty

Celery stalk

### ABSTRACT

**Background:** Mucoid degeneration of the anterior cruciate ligament (ACL) is a common pathology but is often unknown and underdiagnosed. Mucinous material within the substance of ACL produces pain and limited motion in the knee. The purpose of this study was to diagnose mucoid degeneration of ACL and to assess the effectiveness of arthroscopic treatment in these patients.

**Materials and methods:** Between 2011 and 2014, 13 patients were diagnosed to be suffering from mucoid degeneration of ACL on the basis of magnetic resonance imaging (MRI), histopathology, and arthroscopy findings. All the patients had clinical symptoms of central knee pain behind patella and were unable to extend knees fully because of pain without instability. The aim of surgery was to remove as much of the degenerative mass as possible without having to sacrifice the entire ACL. Thus, the remaining ACL consisted of some intact anteromedial or posterolateral portion of the ACL interspersed with degenerate ACL tissue. Copious debridement of mucoid hypertrophied lesions of the ACL was performed.

**Results:** Mean follow-up was of 8.4 months (range 6–12 months) and all except one patient had a full range of painless motion. All patients have resumed their normal daily activities. None complained of any instability. Postoperatively, 12 knees showed complete pain relief and 1 showed pain improvement by at least 4 Visual Analogue Scale (VAS) grades and preoperative average International Knee Documentation Committee (IKDC) score 8 was 36.39 which improved postoperatively to the average 73.18.

**Conclusions:** Mucoid degeneration of the ACL should be suspected in patients presenting pain on terminal extension or flexion without preceding trauma. Prior knowledge of condition with high index of suspicion and careful interpretation of MRI can establish the diagnosis preoperatively. Arthroscopic debridement with or without notchplasty gives excellent functional results.

© 2015 International Society for Knowledge for Surgeons on Arthroscopy and Arthroplasty. Published by Elsevier, a division of Reed Elsevier India, Pvt. Ltd. All rights reserved.

<sup>\*</sup> Corresponding author. Tel.: +91 9876118678.

E-mail address: [dradityabhardwaj@gmail.com](mailto:dradityabhardwaj@gmail.com) (A. Bhardwaj).

<http://dx.doi.org/10.1016/j.jajs.2015.12.001>

2214-9635/© 2015 International Society for Knowledge for Surgeons on Arthroscopy and Arthroplasty. Published by Elsevier, a division of Reed Elsevier India, Pvt. Ltd. All rights reserved.

**Table 1 – Pre-OP data of the patients.**

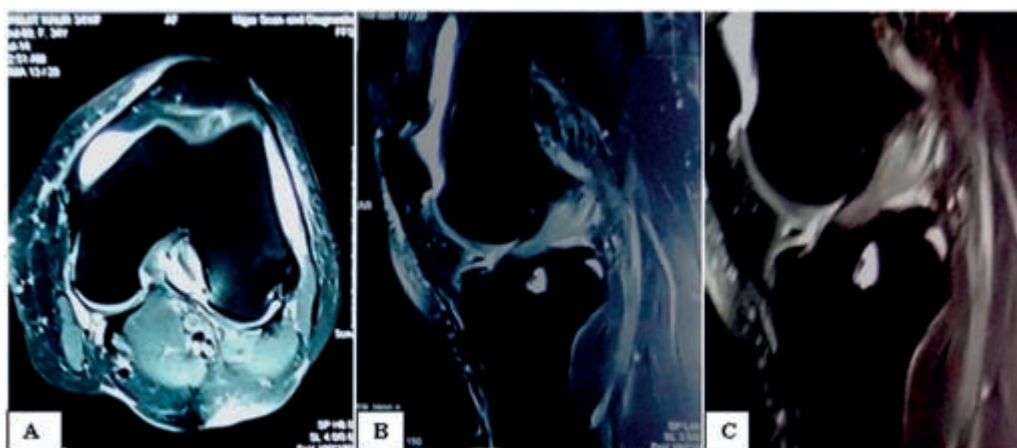
S. No.	Sex/age	Duration of symptoms (months)	H/o trauma	Complaints	Pre OP IKDC score
1.	M/32	04	Yes	Painful terminal extension	34.4
2	F/45	03	No	Painful terminal extension	32.1
3	F/40	15	No	Painful terminal extension	35.6
4	M/38	36	No	Painful terminal extension	39.1
5	M/46	24	No	Painful terminal extension	40.2
6	M/27	07	Yes	Painful terminal extension	31.03
7	F/42	06	No	Painful terminal extension	34.4
8	F/56	06	No	Painful terminal extension	29.9
9	F/31	10	Yes	Painful terminal flexion	37.9
10	F/36	08	No	Painful terminal extension	45.9
11	M/39	07	No	Painful terminal extension	40.2
12	F/46	24	No	Painful terminal extension	29.9
13	F/44	18	No	Painful terminal extension	42.5

## 1. Introduction

Mucoid degeneration (MD) of the anterior cruciate ligament (ACL) is a rare pathological entity with disputed theories of origin.<sup>1</sup> Its prevalence in magnetic resonance imaging (MRI) is 1.8–5.3%, but not all lesions are symptomatic.<sup>2,3</sup> It is characterized by infiltration of mucoïd-like substance (glycosaminoglycans) interspersed within the substance of ACL causing knee pain and limited motion. This entity was described only a decade ago by Kumar et al. in 1999.<sup>4</sup> Since then, many authors have identified and described their experiences and suggested their own guidelines for management. Regarded as a rare occurrence in the past, of late many reports of MD have highlighted the fact that it is not a rare entity and possibly was under-diagnosed or misdiagnosed and reported as partial or complete tear of ACL.<sup>5,6</sup> The excision of the degenerated ACL has been the treatment of the choice, and the authors believe that if the taut and hypertrophied ACL were to be debulked and notchplasty done, full extension could be achieved without having to excise the entire ACL, thus maintaining stability. The objective of our study was to describe the clinical characteristics and diagnosis of MD of the ACL and to assess the outcomes of treatment by partial arthroscopic ACL resection with or without notchplasty in a series of 13 patients.<sup>7</sup>

## 2. Materials and methods

This prospective study performed between 2011 and 2014 involved 13 knees. We examined the medical histories of the injured knee, the time period between the onset of pain and development mode, the concept of initial trauma and the pain location and anterior translation at the Lachman manoeuvre. The average duration of symptoms before consultation was 12.9 months (3–36 months) [Table 1]. All the patients had clinical symptoms of central knee pain behind patella and were unable to extend knees fully because of pain without instability. Anterior Lachman and anterior drawer test showed firm endpoint in all patients. McMurray was painfully positive. All patients were treated with non-steroidal anti-inflammatory drugs and physiotherapy for a minimum of 2 months before contemplating MRI and treatment. MRI was performed with 1.5 T machines. ACL mucoïd degeneration was validated by MRI according to diagnostic criteria defined by Bergin et al., overall hyper signal of the ACL in T1-T2, increased overall ACL volume, ligament fibres clearly seen in T2, continuous tibial to femoral insertion.<sup>3</sup> MRI also made it possible to measure ACL hypertrophy or notch stenosis [Fig. 1]. All the patients underwent diagnostic arthroscopy of the knee under tourniquet with appropriate anaesthesia. During diagnostic arthroscopy of the knee through standard anterolateral portal, the

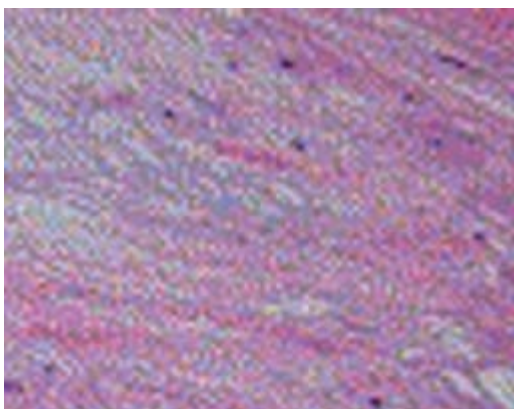


**Fig. 1 – (A–C) Magnetic resonance images showing cyst in the anterior cruciate ligament with preserved fibres with bulky ACL and increased intensity.**



**Fig. 2 – Arthroscopic image of muroid degeneration of ACL.**

diagnosis of MD, initially established on MRI, was supported by a description of the ACL aspect corresponding to the arthroscopic diagnostic criteria enumerated by McIntyre et al. continuous ACL fibres, increased ACL volume, yellowish-coloured material expressed on palpation and loss of ACL synovial lining<sup>8</sup> [Fig. 2]. The aim of surgery was to remove as much of the degenerative mass as possible without having to sacrifice the entire ACL. Thus, the remaining ACL consisted of some intact anteromedial or posterolateral portion of the ACL interspersed with degenerate ACL tissue. Copious debridement of muroid hypertrophied lesions of the ACL was performed by use of basket forceps as well as a 4.2-mm motorized shaver. The probe was used to assess the tension and the clearance of the remaining ACL and the notch. Care was taken to see that this remaining ACL had intact attachment to the femoral condyle and did not impinge on the roof or lateral wall of the notch. Notchplasty was done when a conflict was noted with the notch. The degenerated ACL and mucinous material was sent for histopathology examination. The materials were stained with H and E and then with muroid tissue-specific Alcian blue. Histopathology was suggestive of MD of ACL [Fig. 3]. Weight-bearing with free



**Fig. 3 – Histopathology images [H&E stain] showing collagen fibres mixed with mucoid material.**

mobility was authorized in the immediate postoperative period. All other patients were encouraged to perform daily active range of motion exercises with quadriceps strengthening. The average follow-up was 8.4 months. Postoperative assessment included a clinical examination. Functional state was assessed by subjective International Knee Documentation Committee (IKDC)<sup>9</sup> questionnaires.

### 3. Results

Five males and eight females (Ratio of 1:1.6) were part of the study [Table 1]. Median age of patients was 36.4 years (range 27–46 years) in males and 42.5 years (range 31–56 years) in females. The type of activity performed was: physically active, two patients (15.3%); moderately active, five patients (38.5%) and sedentary, six patients (46.2%). The average duration of symptoms before consultation was 12.9 months (3–36 months). The mean follow-up was 8.4 months (range 6–12 months). Preoperative 12 patients presented with central knee pain on terminal extension which was moderate in 9 knees and severe in 3 knees while 1 patient had difficulty in knee flexion. Four patients (30.7%) reported trivial trauma prior to the onset of symptoms. Plain radiographs of index knee were normal in all the patients. MRI was done in every patient and 3 out of the 13 patients were initially reported as partial or complete tear of ACL, whereas remaining ten were reported as MD of ACL. Arthroscopy revealed bulge in the form of cyst in all 13 cases which was suggestive of MD. MD filled the entire intercondylar notch and was unusually taut, towards 90° of flexion in 1 patient with hypertrophied AM bundle of ACL, and taut in extension in rest of the patients with hypertrophied PL bundle of ACL. The ACL fibres were interspersed with a yellowish homogenous mass. The posterolateral portion of the ACL bulged into the lateral compartment in extension impinging in the notch. By flexion–extension manoeuvre, impingements were reproduced under direct vision. Impingement was particularly apparent in knees with a severely hypertrophied ACL or narrowed notch, as well as limited knee joint extension. MD was around the posterolateral ACL fibres and the anteromedial portion was retained in 11 patients. In 1 patient, posterolateral portion of ACL was retained because of hypertrophied degenerated AM bundle of ACL. Three medial meniscectomies were done at the same time in associated knees. After judicious debridement of muroid ACL and associated cyst, the histopathology appearance and reports of the biopsy specimens were consistent with muroid degeneration of the ACL in all 13 cases. In 4 knees with evident notch narrowing, notchplasty was performed first. Mean follow-up was of 8.4 months (range 6–12 months) and all except one patient had a full range of painless motion. All patients have resumed their normal daily activities. None complained of any instability [Fig. 4]. Postoperatively, 12 knees showed complete pain relief and 1 showed pain improvement by at least 4 Visual Analogue Scale (VAS) grades, Preoperative average IKDC score<sup>8</sup> was 36.39 which improved postoperatively to the average 73.18 [Table 2]. However, few continued to have occasional pain while climbing stair, prolonged walking or squatting.





Fig. 4 – Post-OP images of patient showing complete range of motion of knee after debulking of ACL.

Table 2 – Post-OP data of the patients.

S. No.	Sex/age	Follow-up (month)	Post-OP clinically	Post-OP IKDC score
1.	M/32	06	Painless, Range on motion, No Instability	68.9
2.	F/45	07	Painless, Range on motion, No Instability	71.2
3.	F/40	12	Painless, Range on motion, No Instability	80.4
4.	M/38	08	Painless, Range on motion, No Instability	70.1
5.	M/46	08	Painless, Range on motion, No Instability	79.5
6.	M/27	08	Painless, Range on motion, No Instability	67.8
7.	F/42	12	Painless, Range on motion, No Instability	70.1
8.	F/56	10	Mild Pain But Improvement, No Instability	63.2
9.	F/31	09	Painless, Range on motion, No Instability	74.7
10.	F/36	06	Painless, Range on motion, No Instability	78.1
11.	M/39	06	Painless, Range on motion, No Instability	80.4
12.	F/46	08	Painless, Range on motion, No Instability	75.8
13.	F/44	10	Painless, Range on motion, No Instability	71.2

#### 4. Discussion

The mucoid hypertrophy of the ACL is a rare condition found in middle-aged individuals. Bergin et al. and Salvati et al. reported its occurrence as 2% and 5%, respectively, of knee where MRI was done. It usually affects middle-aged individuals with mean age of 42 years. In our study, median age was found to be 40.15 years, which is also reported by other authors. Male to female sex ratio had been confirmed to be 1:1 by Bergin et al. and 1.28:1 by Salvati et al. Our study had the ratio of 1:1.6.<sup>2,3</sup>

It becomes apparent in two subpopulations of patients. The first group is younger, active, and athletic, in whom we can assume an ACL mechanism affected by real trauma or repeated micro-traumas causing an early lesion.<sup>10</sup> The second group is older and presents with progressive degenerative ACL lesions, with frequent concomitant degenerative meniscal lesions.<sup>11</sup> Multiple theories including synovial, traumatic, degenerative, ectopic, altered joint mechanics, etc. have been put forth to explain the elusive pathological origin of MD of ACL.<sup>6,12-18</sup> [Fig. 5]. Majority of series have not reported any significant trauma prior to the onset of symptoms, whereas few others reported traumatic event before the onset of symptom. Lancaster et al.'s theory was also supported by Amiel et al. where they proved that injury to the synovium can result in exposure of ACL substance to the deleterious effects of haemarthrosis.<sup>6,19</sup> Deie et al. proved that the synovium enveloping the ACL has a healing and a protective capacity on the ACL and this diminishes once resected or damaged.<sup>20</sup>

Cha et al. believed that notch anatomy, especially smaller and vertical notch, predisposed the ACL to impingement and therefore resulting in microtrauma to the ACL.<sup>13</sup> At present, it is difficult to point out a single lone cause for the knee pain and with the literature available, it seems to be multifactorial. A study of Fealy et al. mentioned that pain could also be due to intratendinous nociceptor irritation during increased knee flexion. Decompression of ACL relieving tension amidst fibres supports this fact. Knee pain during flexion is probably due to the tightening of the anteromedial bundle. Knee pain during terminal extension has also been described. The active role of chemical mediators like substance P and calcitonin gene related peptide has also been mentioned.<sup>21</sup> Furthermore, associated pathologies like cartilage damage and meniscal tear do contribute to the pain and may be the reason of residual pain after the surgery for MD of ACL. Narvekar and Gajjar explained knee pain through increased volume and tension within the ligament.<sup>22</sup> For Kumar et al., the pain is attributable to the effect of the ACL mass in the posterior notch.<sup>4</sup> We believe that the most important source of pain is mechanical impingement, associated with unique function of the ACL in providing nociceptive sensory signals.

The gold standard imaging for the diagnosis of MD of ACL is MRI, which exhibits intermediate signal intensity on T1 weighted and high signal intensity on T2 weighted images. The ACL fibres are usually thick and ill-defined, but the orientation and continuity are usually maintained.<sup>5</sup> Bergin et al. in their study have reported detailed findings after retrospectively studying 4221 knee MRIs and helped

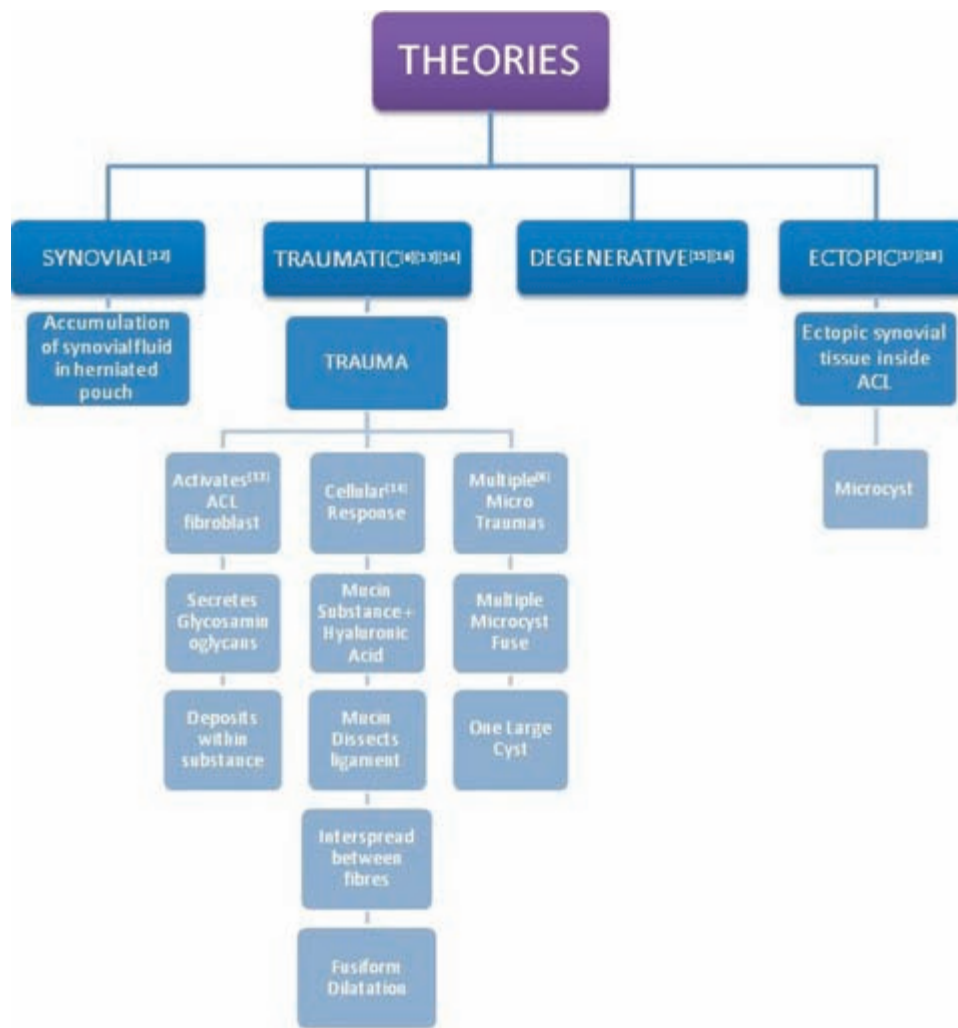


Fig. 5 – Theories of ACL mucoid degeneration.

differentiating MD from mucoid cyst.<sup>10</sup> However, the most characteristic appearance is that akin to a “Celery stalk”. Considering the limited awareness, misdiagnosis as a tear is quite common both clinically and on MRI. McIntyre et al. has described ten patients who were initially mistaken for tears on MRI, but arthroscopy and probing expressed mucoid material.<sup>8</sup> Makino et al. have described the presence of associated lesions like intraosseous tibial cyst and ganglion picked up on MRI.<sup>23</sup> The arthroscopic features include an intact but fibrillated, yellowish and hypertrophied ACL with interspersed yellowish mucinous material along the fibres exposed on probing, lack of smooth synovial lining and absent ligamentum mucosum.<sup>5</sup> In all the cases, ACL was devoid of synovial lining and ligamentum mucosum was absent as reported in the literature.

Under the microscope, MD is typically described to have dense granular glycoproteins and mucoproteins (glycosaminoglycans) located between thin, fragile collagen fibrils of ACL, which are detectable by haematoxylin and eosin or Alcian blue.<sup>7</sup> Shelly et al. have reported a unique case of metastatic adenocarcinoma of the lung into the knee mimicking MD of the ACL.<sup>24</sup> This fact establishes the importance of sending the excised specimen for the histopathology.

Most of the authors believe that debridement of mucinous substance with partial ACL debulking is an effective therapeutic option which does not cause instability. An additional notchplasty is considered essential by some authors.<sup>5</sup> But Motmans and Verheyden specifically mention that notchplasty is not required, because thorough debridement by itself resolves the impingement and thereby the pathology.<sup>25</sup> Lintz et al. performed two notchplasties out of 29 patients but not routinely.<sup>1</sup> We performed a meticulous and judicious debridement of the mucoid ACL with the aim of reducing the volume, achieving removal of the mucoid mass and decompression of the bulky pathological ACL. We did not perform notchplasty in four patients. We believe that notchplasty may be needed in some cases where notch is quite stenotic and impinged by osteophytes especially in elderly patients. However, it may not be needed in middle-aged patients where notch is free of osteophytes. Debulking of ACL alone is sufficient to achieve full range of movement.

Though all patients regained full flexion after debulking mucinous ACL, some of them continued to experience mild pain while walking or climbing stairs. This could be explained probably because of concomitant lesions like cartilage damage

in patellofemoral or tibiofemoral joint or meniscal tear. Dejour et al. demonstrated positive anterior drawer in 36% and positive pivot shift in 55% of his patients after debridement.<sup>26</sup> None demonstrated a positive pivot shift. None developed instability until final follow-up.

However, it is premature to say that these patients will not develop instability in future, as all of these were patients with sedentary activities except one who plays badminton. Whether patients whose occupation requires heavy demand from knee or athletes would not develop instability in future after partial debulking, is a matter of debate. Another notion addressed by this work is that of secondary instability. It is mentioned elsewhere only by McIntyre et al. who reported one case of atraumatic ACL rupture at 1 postoperative year after partial resection.<sup>8</sup> Our results indicate that postoperative laxity, largely asymptomatic, can increase anterior laxity over time and evoke instability.

## 5. Conclusion

Mucoid degeneration of the ACL should be suspected in patients presenting pain on terminal extension or flexion without preceding trauma. Prior knowledge of condition with high index of suspicion and careful interpretation of MRI can establish the diagnosis preoperatively. Arthroscopic debridement with or without notchplasty gives excellent functional results.

## Conflicts of interest

All authors have none to declare.

## REFERENCES

- Lintz F, Pujol N, Dejour D, Boisrenoult P, Beaufils P. Anterior cruciate ligament mucoid degeneration: selecting the best treatment option. *Orthop Traumatol Surg Res.* 2010;96:400–406.
- Salvati F, Rossi F, Limbucci N, Pistoia ML, Barile A, Masciocchi C. Mucoid metaplastic-degeneration of anterior cruciate ligament. *J Sports Med Phys Fitness.* 2008;48:483–487.
- Bergin D, Morrison WB, Carrino JA, Nallamshetty SN, Bartolozzi AR. Anterior cruciate ligament ganglia and mucoid degeneration: coexistence and clinical correlation. *Am J Roentgenol.* 2004;182:1283–1287.
- Kumar A, Bickerstaff DR, Grimwood JS, Suvama SK. Mucoid cystic degeneration of the cruciate ligament. *J Bone Joint Surg Br.* 1999;81:304–305.
- Pandey V, Suman C, Sharma S, Rao SP, Kiran Acharya K, Sambaji C. Mucoid degeneration of the anterior cruciate ligament: management and outcome. *Indian J Orthop.* 2014;48(2):197–202.
- Lancaster TF, Kirby AB, Beall DP, Wolff JD, Wu DH. Mucoid degeneration of the anterior cruciate ligament: a case report. *J Okla State Med Assoc.* 2004;97:326–328.
- Chudasama CH, Chudasama VC, Prabhakar MM. Arthroscopic management of mucoid degeneration of anterior cruciate ligament. *Indian J Orthop.* 2012;46(5):561–565.
- McIntyre J, Moelleken S, Tirman P. Mucoid degeneration of the anterior cruciate ligament mistaken for ligamentous tears. *Skeletal Radiol.* 2001;30:312–315.
- Rossi MJ, Lubowitz JH, Guttmann D. Development and validation of the International Knee Documentation Committee subjective knee form. *Am J Sports Med.* 2002;30:152.
- Scranton Jr PE, Farrar EL. Mucoid degeneration of the patellar ligament in athletes. *J Bone Joint Surg Am.* 1992;74:435–437.
- Cha JH, Lee SH, Shin MJ, Choi BK, Bin SI. Relationship between mucoid hypertrophy of the anterior cruciate ligament (ACL) and morphologic change of the intercondylar notch: MRI and arthroscopy correlation. *Skeletal Radiol.* 2008;37:821–826.
- Diard F, Chateil JF, Hauger O, Moinard M. Para-articular and intraosseous synovial cysts and articular mucoid cysts. *J Radiol.* 1999;80:679–696.
- Rolf C, Watson TP. Case report: Intratendinous ganglion of the anterior cruciate ligament in a young footballer. *J Orthop Surg Res.* 2006;1:11.
- Bui-Mansfield LT, Youngberg RA. Intraarticular ganglia of the knee: prevalence, presentation, etiology, and management. *Am J Roentgenol.* 1997;168:123–127.
- Fernandes JL, Viana SL, Mendonça JL, et al. Mucoid degeneration of the anterior cruciate ligament: magnetic resonance imaging findings of an underdiagnosed entity. *Acta Radiol.* 2008;49:75–79.
- Krudwig WK, Schulte KK, Heinemann C. Intraarticular ganglion cysts of the knee joint: a report of 85 cases and review of the literature. *Knee Surg Sports Traumatol Arthrosc.* 2004;12:123–129.
- Melloni P, Valls R, Yuguero M, Sáez A. Mucoid degeneration of the anterior cruciate ligament with erosion of the lateral femoral condyle. *Skeletal Radiol.* 2004;33:359–362.
- Hensen JJ, Coerkamp EG, Bloem JL, De Schepper AM. Mucoid degeneration of the anterior cruciate ligament. *JBR-BTR.* 2007;90:192–193.
- Amiel D, Billings Jr E, Harwood FL. Collagenase activity in anterior cruciate ligament: protective role of the synovial sheath. *J Appl Physiol.* 1985;59:902–906.
- Deie M, Ochi M, Ikuta Y. High intrinsic healing potential of human anterior cruciate ligament. Organ culture experiments. *Acta Orthop Scand.* 1995;66:28–32.
- Fealy S, Kenter K, Dines JS, Warren RF. Mucoid degeneration of the anterior cruciate ligament. *Arthroscopy.* 2001;17:E37.
- Narvekar A, Gajjar S. Mucoid degeneration of the anterior cruciate ligament. *Arthroscopy.* 2004;20:141–146.
- Makino A, Pascual-Garrido C, Rolón A, Isola M, Muscolo DL. Mucoid degeneration of the anterior cruciate ligament: MRI, clinical, intraoperative, and histological findings. *Knee Surg Sports Traumatol Arthrosc.* 2011;19:408–411.
- Shelly MJ, Dheer S, Kavanagh EC. Metastatic adenocarcinoma of the lung mimicking mucoid degeneration of the anterior cruciate ligament. *Ir J Med Sci.* 2010;179:309–311.
- Motmans R, Verheyden F. Mucoid degeneration of the anterior cruciate ligament. *Knee Surg Sports Traumatol Arthrosc.* 2009;17:737–740.
- Dejour D, Cohn J, Tavernier T. La dégénérescence spontanée du ligament croisé antérieur: étude radio clinique et anatomo-pathologique. *Rev Chir Orthop Reparatrice Appar Mot.* 2005;91:67.

Available online at [www.sciencedirect.com](http://www.sciencedirect.com)

ScienceDirect

journal homepage: [www.elsevier.com/locate/jajs](http://www.elsevier.com/locate/jajs)

## Original Article

# Intra-articular lipoma arborescence of the knee – A rare clinical entity



Vivek Pandey<sup>a,\*</sup>, Arun Gupta<sup>b</sup>, Smita Kulshrestha<sup>b</sup>, Lipisha Agarwal<sup>a</sup>

<sup>a</sup> Dept of Orthopaedic surgery, Kasturba Medical College, Manipal, Manipal University, Karnataka 576104, India

<sup>b</sup> Ojas Hospital, E-8, Kamla Nagar, Agra, Uttar Pradesh 282005, India

## ARTICLE INFO

## Article history:

Received 15 October 2015

Accepted 9 November 2015

Available online 5 December 2015

## Keywords:

Lipoma arborescence

Knee

Benign

Synovial mass

Refractory pain

## ABSTRACT

**Background:** Intra-articular lipoma arborescence (LA) is a rare entity that presents with swelling and with recurrent effusion of the joints lined by synovium, especially the large joints like knee and others. Pathologically, it is characterised by replacement of subsynovial tissue by fat cells. Magnetic resonance imaging can clinch the diagnosis.

**Method:** We describe four cases of LA, who presented with chronic intermittent pain and swelling of the knee joint. Arthroscopic synovectomy and further biopsy helped establishing the diagnosis.

**Result:** Arthroscopic resection of lesion and management of concomitant lesion help in managing the symptoms.

**Conclusions:** LA should be included in the differential diagnosis of cases with persistent, refractory, chronic knee joint swelling and pain.

© 2015 International Society for Knowledge for Surgeons on Arthroscopy and Arthroplasty. Published by Elsevier, a division of Reed Elsevier India, Pvt. Ltd. All rights reserved.

## 1. Introduction

Intra-articular lipoma arborescence (LA) is a rare, benign synovial neoplasm characterised by villous, polypoidal lipomatous transformation of synovium due to diffuse infiltration of the sub-synovial stroma by mature fat cells.<sup>1,2</sup> The exact aetiology of LA remains idiopathic and is still unclear that whether this condition is reactive to degenerative arthritis, and is post-inflammatory, post-traumatic or metaplastic. However, most of the cases reported in literature have been associated with degenerative arthritis, inflammation or trauma.<sup>3–8</sup> Clinically, it presents with a recurrent swelling of the joint with or without pain. Treatment involves synovectomy, open or

arthroscopic, which is mostly curative. We present a series of four cases of LA in the knee with their clinical presentations, management and review of the literature.

## 2. Case reports

### 2.1. Case 1

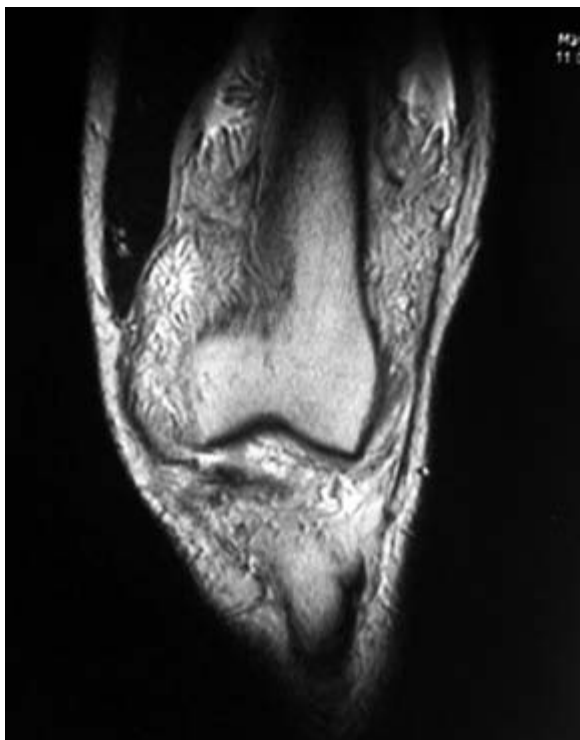
A 39-year-old man presented with a history of pain and swelling in the left knee joint for the past 4 years. Pain was mechanical in nature with no rest pain, alleviated by NSAIDs. Swelling was progressive in nature. There was no history of trauma to the joint, fever or other constitutional symptoms.

\* Corresponding author. Tel.: +91 9449615280.

E-mail address: [vivekortho@gmail.com](mailto:vivekortho@gmail.com) (V. Pandey).

<http://dx.doi.org/10.1016/j.jajs.2015.11.007>

2214-9635/© 2015 International Society for Knowledge for Surgeons on Arthroscopy and Arthroplasty. Published by Elsevier, a division of Reed Elsevier India, Pvt. Ltd. All rights reserved.

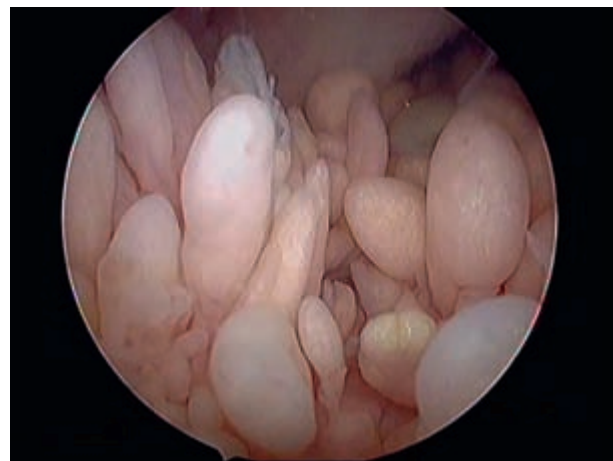

**Fig. 1 – Coronal section T2-weighted MRI, effusion with villous mass in supra-patellar area.**

Other joints were normal. The patient was treated initially by NSAIDs and physiotherapy. Physical examination revealed tenderness over the medial femoral condyle of the knee joint with synovial hypertrophy and effusion. Special tests for meniscal or ligament tears were negative. Blood tests were unremarkable. Magnetic resonance imaging (MRI) showed typical frond-like appearance of the synovium and joint effusion (Fig. 1). Due to persistent symptoms, the patient underwent arthroscopy that revealed yellowish tissue with synovial growth involving both parapatellar gutters and the supra-patellar pouch (Fig. 2). Menisci, cartilage and cruciates were normal. The yellowish frond-like synovial growth was excised arthroscopically using motorised shaver. Histopathological examination of the lesion showed synovium lined with a villous proliferation in which the villi were diffusely infiltrated by mature adipose tissue suggestive of LA (Fig. 3). At a follow-up in 42 months, the patient remains asymptomatic.

## 2.2. Case 2

A 42-year-old male presented with swelling in his right knee for the past 5 years. The swelling was more in popliteal fossa. He complained not only of pain while walking, but also morning stiffness of less than 30 min. No other joints were involved, and there were no systemic symptoms. Local examination of knee revealed synovial hypertrophy and effusion. Blood test revealed mildly elevated erythrocyte sedimentation rate (ESR) up to 40 mm per hour. Past history suggested that in view of elevated ESR, a medical practitioner empirically started him on DMARDs (hydroxychloroquine) for

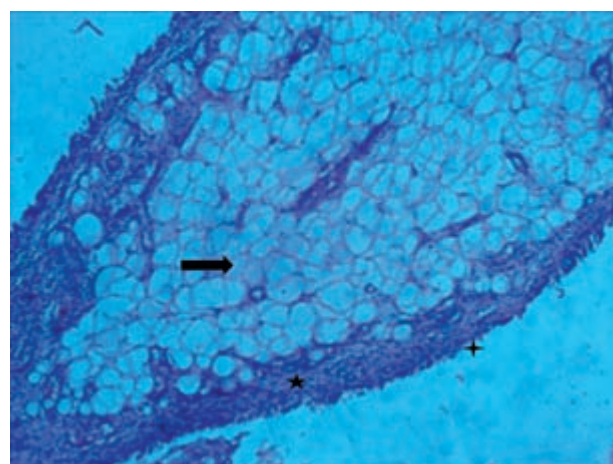


**Fig. 2 – Arthroscopic view of the LA showing yellowish polypoidal villous mass in the supra-patellar pouch and adjacent medial parapatellar gutter of the knee.**

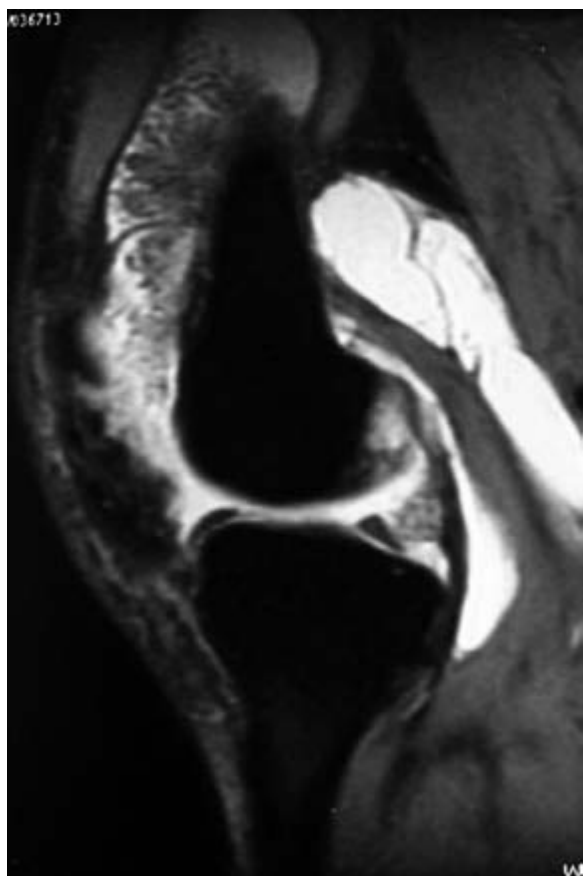
6 months suspecting an inflammatory synovitis but to no respite. Intra-articular corticosteroid injections were also given, but they gave only temporary relief. MRI was suggestive of LA and Baker's cyst (Fig. 4). Arthroscopy was performed, which showed large villous transformation of synovium in the supra-patellar pouch. The rest of the joint was normal. Fatty polypoidal mass was excised using motorised shaver. Histopathological exam showed mature adipocytes with chronic inflammatory cells in the sub-intima of synovium. At a follow-up after 32 months, he remains asymptomatic with painless full range of movement. The Baker's cyst has subsided completely.

## 2.3. Case 3

A 21-year-old male presented with right-sided moderate knee pain with recurrent swelling for 3 years. No other joints were involved. There was no history of fever, loss of weight or



**Fig. 3 – Photomicrograph of lipoma arborescens shows papillaroid structure (4 point star) with synovial lining cells (5-point star), which contain a stroma that exhibits increased mature adipose tissue (black arrow).**



**Fig. 4 – Sagittal section T2-weighted MRI, large effusion with polypoidal villous frond-like mass in supra-patellar area, with Baker's cyst.**

appetite. He had taken conservative treatment in the form of NSAIDs and physical therapy for long but to no avail. Clinical examination of right knee revealed effusion with synovial hypertrophy. Plain radiograph of the knee was normal. MRI of the knee revealed an exophytic mass in the supra-patellar pouch with lobulated villous projections with fat signal intensity. Arthroscopy of the knee revealed fatty villous projections in the supra-patellar pouch. The remainder of the joint was found to be normal. The villous hypertrophied fatty projections were removed using motorised shaver. Histopathology of the specimen was suggestive of LA. At 48 months after the surgery, the patient was found to be pain free and without effusion.

#### 2.4. Case 4

A 45-year-old male presented with acute exacerbation of left-sided non-traumatic mechanical knee pain with recurrent swelling for 2 years. No other joints were involved. There were no systemic complaints. Clinical examination of right knee revealed effusion and medial joint line tenderness with synovial hypertrophy in the supra-patellar pouch. Plain radiograph of the knee revealed narrowing of medial joint space suggestive of early osteoarthritis of the knee. MRI of the knee was not performed. Arthroscopy of the knee revealed

fatty villous projections in the supra-patellar pouch with early osteoarthritis of the medial compartment of the knee. There was degenerative tear in the body of the medial meniscus. Remainder of the joint was found to be normal. The villous hypertrophied fatty projections were removed using motorised shaver, and a partial meniscectomy was performed for the degenerative meniscal tear. Histopathology of the resected synovium was not only suggestive of LA, but also of secondary synovial chondromatosis. At a follow-up after 24 months, patient has mild pain but no swelling.

### 3. Discussion

Lipoma arborescens is considered to be a rare, benign intra-articular lipomatous lesion seen in synovial joints.<sup>9</sup> Hallel et al. suggested the use of “villous proliferative lesion of subsynovial fat”, a more suitable term, since lipoma in LA is suggestive of tumorous origin.<sup>7</sup> It is mostly reported in the supra-patellar space of the knee joint.<sup>5,7,10-12</sup> However, there are several reports of LA in the shoulder, elbow, hip, as well as the ankle.<sup>13-16</sup> Although LA is typically intra-articular, non-articular locations around bursae and tendon sheaths have also been reported.<sup>17-19</sup> Various authors have described mono-articular locations of LA, but there are rare reports of polyarticular involvement as well.<sup>20-22</sup> Polyarticular, especially bilateral knee, involvement may mistake the picture to be of inflammatory arthritis, especially due to the presence of minor elevations in inflammatory markers.

While the aetiology of LA remains elusive, most believe that it is a hyperplastic or a reactive process rather than a true neoplasm. Based on absence or presence of reactive stimulus in the joint, LA is considered to be of two types, primary and secondary. Primary LA is uncommon and is seen without any preceding trauma or inflammation. It is reported mostly in the children and adolescent population without a history of trauma or inflammation.<sup>11,21,23</sup> Rarely, primary LA can initiate degenerative change in the joint,<sup>14,24,25</sup> and possibly cause bony erosions too.<sup>26</sup> Secondary LA, which is more common, is often associated with chronic irritation due to osteoarthritis, inflammatory arthritis and trauma.<sup>3,5,6,8,27,28</sup> However, it is still unclear whether these associations are causal or merely coincidental.

LA typically presents in the 4th to 5th decade. It is quite rare in children and adolescents with very few reports available.<sup>11,13,21,23,29</sup> Patients with primary LA present with boggy swelling especially in the supra-patellar pouch and effusion with or without pain.<sup>11,21,23</sup> However, secondary LA can present as a painful swelling of the joint due to underlying inflammatory or degenerative disorder of the joint.<sup>3,6,28</sup> Some patients may present with locking or crepitus due to hypertrophied villi getting trapped between the articular surfaces. The mean age of patients in our series was 36.7 years (range: 21-45). Only one patient had associated early osteoarthritis of the medial compartment of the knee. All of them presented with painful swelling of the knee joint in the supra-patellar region. Table 1 summarises the demographic and clinical variables of all patients.

Most laboratory tests are within normal limit except in a situation where it is a case of secondary LA. Sometimes, the

**Table 1 – Demographic and clinical variables of all cases.**

Case	Age/ Sex	Physical findings	Blood test	Radiograph	Arthroscopic findings	Follow-up (months)	Recurrence
1	39/M	Medial femoral condyle tenderness, Synovial hypertrophy, effusion	Normal	Normal	Yellowish villous synovial tissue involving both parapatellar gutters and supra-patellar pouch	42	None
2	42/M	Joint effusion, Baker's cyst	Elevated ESR	Normal	Large villous transformation of synovium in supra-patellar pouch	32	None
3	21/M	Synovial hypertrophy, effusion	Normal	Normal	Fatty villous projections in the supra-patellar pouch	48	None
4	45/M	Medial joint line tenderness, Synovial hypertrophy, effusion	Normal	Narrowing of medial Joint space	Fatty villous projections in the supra-patellar pouch with early osteoarthritis of the medial compartment of the knee. Degenerative tear in the body of the medial meniscus	24	None

M, Male; ESR, erythrocyte sedimentation rate.

ESR may be high, which may cause confusion, and the patient may end up receiving treatment for inflammatory arthritis instead.

Plain radiographs are not diagnostic but may show features of secondary changes of osteoarthritis, inflammatory arthritis or trauma. Only one of the cases had osteoarthritic changes of medial compartment, whereas the rest were apparently normal. Ultrasound may reveal joint effusion and may show villous synovial projections. In most cases, MRI is the diagnostic modality of choice and is pathognomonic enough to zero down upon the near-certain diagnosis of this condition. MRI shows frond-like appearance with high-signal intensity of fat of LA in T1- and T2-weighted images and dark-signal images of fat in short tau inversion recovery (STIR) sequence. In their review of 32 MRIs of patients with LA, Vilanova et al. reported that 87% had associated degenerative changes, and 72% had a meniscal tear.<sup>30</sup> Others had synovial cyst (38%), bony erosions (25%) and chondromatosis (13%). Synovitis of infective, inflammatory, metaplastic, reactive states (giant cell tumour of synovium, gouty tophi) and degenerative origin would not show such characteristics. Occasionally, synovial haemangiomas can mimic similar MRI interpretations with regions of high-signal fat-like intensity. However, haemangiomas are always associated with dilated vascular spaces and phlebolith.<sup>31</sup>

Macroscopically, LA presents with frond-like appearance of broad-based polypoid or thin papillary villi composed of fatty yellow tissue. Although LA is considered to be non-invasive to the surrounding tissues, there are a few reports wherein authors have described invasion of LA into soft or bony tissues. Stephan et al. reported a case of extra-articular LA over the wrist where the lesion was found to be erosive over the extensor indices and extensor communis.<sup>32</sup> The tendon substance was eroded by 40–50%. Ryu et al. reported three cases of LA with bony erosion into the knee<sup>26</sup> and one by Chae et al. wherein LA of glenohumeral joint eroded into the humeral head.<sup>33</sup> Histopathologically, the central parts of villi are filled with mature adipose cells, and peripheral parts are lined with inflammatory cells.

Overall, LA is a specific entity, which perhaps represents a protective and adaptive response to some form of chronic injury to the joint in the form of fatty deposition and inflammatory lining of cells. Synovial resection, open or arthroscopic, is the definitive treatment and leads to complete cure of the disease. Open resection of LA used to be the treatment of choice in the past. However, currently, arthroscopy is the preferred treatment modality as it avoids the complications of open synovectomy, especially stiffness and scarring. Although the recurrence is not reported after complete excision of the lesion,<sup>3,11,21,23,34</sup> it can recur after incomplete excision, especially in secondary LA where it is a reactive hyperplastic lesion. All our cases at a mean follow-up of 36.5 months did not reveal any recurrence.

Differential diagnosis of a soft boggy swelling in the supra-patellar pouch includes pigmented villonodular synovitis (PVNS), synovial chondromatosis, synovial haemangioma, intra-articular lipoma and chronic synovitis. Typical brownish bloody knee aspirate and MRI appearance (PVNS has a low intensity on T1- and T2-weighted images due to haemosiderin accumulation) differentiate PVNS from LA. Synovial chondromatosis presents as multiple loose bodies, which are occasionally clinically palpable and might cause locking. It can also be visualised on plain radiograph and MRI (Low- to intermediate-signal intensities on T1- and T2-weighted images are characteristic of synovial chondromatosis). Synovial haemangioma and true intra-articular lipoma are diagnosed on the basis of classic MRI appearance. Histopathology confirms the diagnosis and certainly helps in differentiating classic LA from various differential diagnoses.

#### 4. Conclusion

LA is a benign, indolent synovial hyperplastic reactive lesion, which should be kept in mind as a differential diagnosis in patients with painless or painful boggy swelling of the knee joint, even if it is bilateral. Knee remains the commonest joint

to be involved, but other joints, as well as extra-articular locations, can get involved. Secondary changes in the joint due to degenerative or inflammatory arthritis often accompany a diagnosis of LA. MRI is the diagnostic modality and helps in narrowing the differential diagnosis. Arthroscopic resection remains the treatment of choice, with no reported recurrences.

### Conflicts of interest

All authors have none to declare.

### REFERENCES

- Adelani MA, Wupperman RM, Holt GE. Benign synovial disorders. *J Am Acad Orthop Surg*. 2008;16:268–275.
- Marengo MF, Suarez-Almazor ME, Lu H. Neoplastic and paraneoplastic synovitis. *Rheum Dis Clin North Am*. 2011;37:551–572.
- Al-Ismaïl K, Torreggiani WC, Al-Sheikh F, Keogh C, Munk PL. Bilateral lipoma arborescens associated with early osteoarthritis. *Eur Radiol*. 2002;12:2799–2802.
- Coll JP, Ragsdale BD, Chow B, Daughters TC. Best cases from the AFIP: lipoma arborescens of the knees in a patient with rheumatoid arthritis. *Radiographics*. 2011;31:333–337.
- D'Mello Z, Neogi DS, Punit AS, Sathe S. Lipoma arborescens of the knee joint after anterior cruciate ligament injury. *Orthop Surg*. 2013;5:142–145.
- Fraser AR, Perry ME, Crilly A, Reilly JH, Hueber AJ, McInnes IB. Lipoma arborescens co-existing with psoriatic arthritis releases tumour necrosis factor alpha and matrix metalloproteinase 3. *Ann Rheum Dis*. 2010;69:776–777.
- Hallel T, Lew S, Bansal M. Villous lipomatous proliferation of the synovial membrane (lipoma arborescens). *J Bone Joint Surg Am*. 1988;70:264–270.
- Howe BM, Wenger DE. Lipoma arborescens: comparison of typical and atypical disease presentations. *Clin Radiol*. 2013;68:1220–1226.
- Weiss SWG. *Benign Lipomatous Tumors*. Enzinger and Weiss's *Soft Tissue Tumors*. 4th ed. St. Louis: Mosby; 2001:571–639.
- Erol B, Ozyurek S, Guler F, Kose O. Lipoma arborescens of the knee joint. *BMJ Case Rep*. 2013;2013:.
- Haasbeek JF, Alvillar RE. Childhood lipoma arborescens presenting as bilateral suprapatellar masses. *J Rheumatol*. 1999;26:683–686.
- Kamaci S, Doral MN, Ergen FB, Yucekul A, Cil A. Lipoma arborescens of the knee. *Knee Surg Sports Traumatol Arthrosc*. 2014;23(8):2196–2201.
- Huang GS, Lee HS, Hsu YC, Kao HW, Lee HH, Chen CY. Tenosynovial lipoma arborescens of the ankle in a child. *Skeletal Radiol*. 2006;35:244–247.
- In Y, Chun KA, Chang ED, Lee SM. Lipoma arborescens of the glenohumeral joint: a possible cause of osteoarthritis. *Knee Surg Sports Traumatol Arthrosc*. 2008;16:794–796.
- Ranganath K, Rao GB, Namitha. Lipoma arborescens of the elbow. *Indian J Radiol Imaging*. 2010;20:50–52.
- Wolf RS, Zoys GN, Saldivar VA, Williams RP. Lipoma arborescens of the hip. *Am J Orthop (Belle Mead NJ)*. 2002;31:276–279.
- Moukaddam H, Smitaman E, Haims AH. Lipoma arborescens of the peroneal tendon sheath. *J Magn Reson Imaging*. 2011;33:221–224.
- Teusink M, El-Khoury G, Buckwalter J. Lipoma arborescens of the subdeltoid bursa: a case report. *Iowa Orthop J*. 2010;30:177–178.
- White EA, Omid R, Matcuk GR, et al. Lipoma arborescens of the biceps tendon sheath. *Skeletal Radiol*. 2013;42:1461–1464.
- Bejia I, Younes M, Moussa A, Said M, Touzi M, Bergaoui N. Lipoma arborescens affecting multiple joints. *Skeletal Radiol*. 2005;34:536–538.
- Cil A, Atay OA, Aydingoz U, Tetik O, Gedikoglu G, Doral MN. Bilateral lipoma arborescens of the knee in a child: a case report. *Knee Surg Sports Traumatol Arthrosc*. 2005;13:463–467.
- Silva L, Terroso G, Sampaio L, et al. Polyarticular lipoma arborescens—a clinical and aesthetical case. *Rheumatol Int*. 2013;33:1601–1604.
- Bansal M, Changulani M, Shukla R, Sampath J. Synovial lipomatosis of the knee in an adolescent girl. *Orthopedics*. 2008;31:185.
- Ikushima K, Ueda T, Kudawara I, Yoshikawa H. Lipoma arborescens of the knee as a possible cause of osteoarthritis. *Orthopedics*. 2001;24:603–605.
- Natera L, Gelber PE, Erquicia JI, Monllau JC. Primary lipoma arborescens of the knee may involve the development of early osteoarthritis if prompt synovectomy is not performed. *J Orthop Traumatol*. 2014;16:47–53.
- Ryu KN, Jaovisidha S, Schweitzer M, Motta AO, Resnick D. MR imaging of lipoma arborescens of the knee joint. *AJR Am J Roentgenol*. 1996;167:1229–1232.
- Xiao J, Xu Y, Wang J, Feng J, Shi Z. Bilateral knee lipoma arborescens combined with osteoarthritis in elderly patients. *J Int Med Res*. 2011;39:1563–1569.
- Yacyshyn EA, Lambert RG. Lipoma arborescens: recurrent knee effusions with positive cyclic citrullinated peptide. *J Rheumatol*. 2010;37:2188–2189.
- Nisolle JF, Boutsen Y, Legaye J, Bodart E, Parmentier JM, Esselinckx W. Monoarticular chronic synovitis in a child. *Br J Rheumatol*. 1998;37:1243–1246.
- Vilanova JC, Barcelo J, Villalon M, Aldoma J, Delgado E, Zapater I. MR imaging of lipoma arborescens and the associated lesions. *Skeletal Radiol*. 2003;32:504–509.
- Greenspan A, Azouz EM, Matthews 2nd J, Decarie JC. Synovial hemangioma: imaging features in eight histologically proven cases, review of the literature, and differential diagnosis. *Skeletal Radiol*. 1995;24:583–590.
- Stepan JGG, Rubin DA, Osei DA. Extra-articular lipoma arborescens of the dorsal aspect of the wrist with invasion of the extensor tendons. A case report. *JBJS Case Connect*. 2013;3:1–4.
- Chae EY, Chung HW, Shin MJ, Lee SH. Lipoma arborescens of the glenohumeral joint causing bone erosion: MRI features with gadolinium enhancement. *Skeletal Radiol*. 2009;38:815–818.
- Sola JB, Wright RW. Arthroscopic treatment for lipoma arborescens of the knee: a case report. *J Bone Joint Surg Am*. 1998;80:99–103.



Available online at [www.sciencedirect.com](http://www.sciencedirect.com)

ScienceDirect

journal homepage: [www.elsevier.com/locate/jajs](http://www.elsevier.com/locate/jajs)

## Case Report

## Vertical intraarticular dislocation of patella

Amit Chauhan<sup>a,\*</sup>, Shanmuga Maheswaran<sup>b</sup>, Sanjeev Anand<sup>b</sup><sup>a</sup> Registrar, Department of Orthopaedics, University Hospital of North Tees, Hardwick Road, Stockton on Tees TS19 8PE, UK<sup>b</sup> Consultant, Department of Orthopaedics, University Hospital of North Tees, Hardwick Road, Stockton on Tees TS19 8PE, UK

## ARTICLE INFO

## Article history:

Received 3 July 2015

Accepted 23 July 2015

Available online 5 November 2015

## Keywords:

Patella

Intraarticular dislocation

Vertical

## ABSTRACT

Dislocation of patella is a known orthopaedic emergency. It is more common in adolescents who are involved in activities such as sports and dance. More commonly laterally, intraarticular dislocation has also been described. We describe here a case of vertical intraarticular dislocation of patella in a young male managed successfully by closed reduction. This rare condition should be among the differential diagnosis of a locked knee.

© 2015 International Society for Knowledge for Surgeons on Arthroscopy and Arthroplasty. Published by Elsevier, a division of Reed Elsevier India, Pvt. Ltd. All rights reserved.

## 1. Case report

A 16-year-old male attended Accident and Emergency Department with severe pain, deformity and inability to stand on right knee. He reported a twisting injury while playing football few hours before. No previous history of any knee problems or family history of joint hyperlaxity was informed. During physical examination, there was visible skin tenting anteriorly in the patellar region without significant joint effusion. Patella was felt standing abruptly in front of his knee. One of the borders of patella was felt anteriorly with articular surface facing laterally. Quadriceps tendon was found to be taut and intact. No retinacular tenderness or soft tissue injuries were felt on palpation. No further tests could be done in emergency room due to discomfort of the patient. The distal neurovascular examination of the affected leg was normal.

## 2. What is your diagnosis?

Locked knee occurs commonly due to meniscal or cartilage conditions. Radiographs of knee in our case (Fig. 1) confirmed intraarticular vertical dislocation of patella. Closed reduction under conscious sedation was attempted with intravenous fentanyl and midazolam. Intraarticular injection of local anaesthetic and saline was also administered. Patient's leg was elevated, hyperextended and with slight manipulation, medial border of the patella was lifted off the intercondylar groove of the femur and reduction achieved. Patient immediately recovered from discomfort and was able to actively extend and flex his knee. Post reduction radiographs (Fig. 2) confirmed the normal alignment of patella. Knee was immobilized in extension brace with immediate full weight bearing for 4 weeks along with advice of elevation, rest and appropriate analgesics. Regular follow-up for 6 months with

\* Corresponding author. Tel.: +44 07474227060.

E-mail address: [amitcoolest4@gmail.com](mailto:amitcoolest4@gmail.com) (A. Chauhan).<http://dx.doi.org/10.1016/j.jajs.2015.07.002>

2214-9635/© 2015 International Society for Knowledge for Surgeons on Arthroscopy and Arthroplasty. Published by Elsevier, a division of Reed Elsevier India, Pvt. Ltd. All rights reserved.

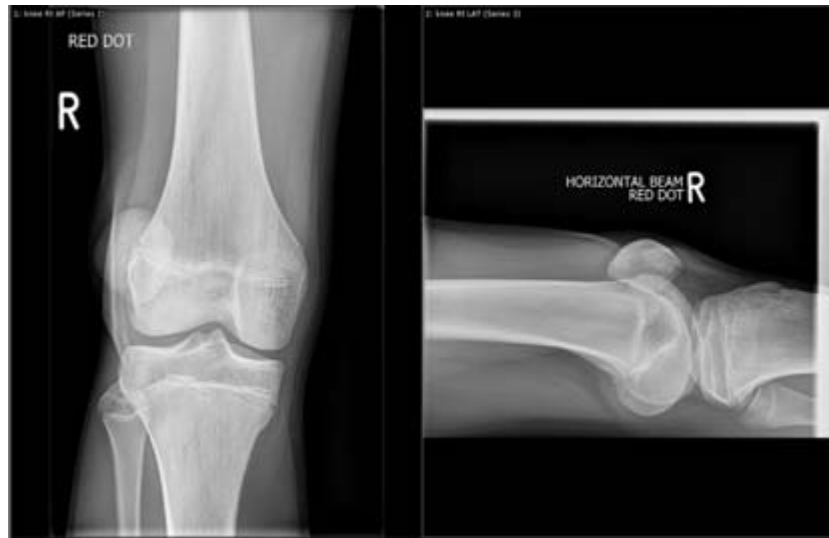

Fig. 1 – Antero-posterior and lateral radiographs showing vertical dislocation of patella.

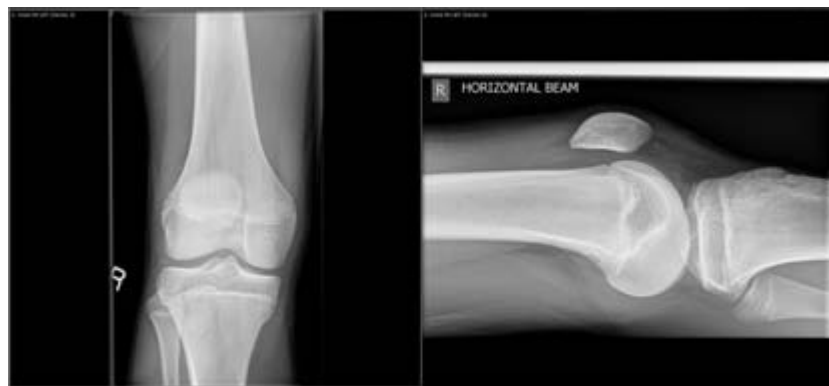

Fig. 2 – Post reduction antero-posterior and lateral radiographs showing normal alignment of patella.

dedicated knee physiotherapy team showed complete restoration of his knee movement without any sequelae.

### 3. Discussion

Patella dislocation can be extraarticular or intraarticular.<sup>1</sup> Intraarticular subtypes can be along horizontal<sup>2</sup> or vertical axis.<sup>3</sup> Superior/inferior pole of patella is locked in intercondylar groove in horizontal subtype, while patella rotates on its vertical axis such that either medial or lateral border is wedged in intercondylar groove of femur in vertical subtype.

Exact mechanism of injury is unknown. Most often these injuries are associated with sports and direct blow to the medial aspect of patella with knee in near extension or a twisting injury with forced internal rotation of femur on externally rotated planted tibia while the knee is flexed. The patella rotates on its vertical axis and gets wedged within intercondylar groove. A valgus strain on the knee also causes the patella to rotate on its vertical axis and the

continued pull of the quadriceps can hold the patella on its edge. Ligaments laxity is a factor too in adolescent patients, as in our case.<sup>4</sup>

Closed reduction under sedation or general anaesthesia, sometimes percutaneously using AO clamp or a Schanz screw, can be employed. Open reduction has also gained popularity as it reduces the risk of any chondral damage caused by repeated reduction manoeuvres and can help in repair or removal of any osteochondral fragments.<sup>4</sup>

Purpose of this report is to keep this rare condition as differential in cases of locked knee. We achieved successful outcome in our case with closed reduction, but if required, especially in elderly with osteophytes, open reduction is necessary.

### Ethical approval

Informed consent was obtained from the individual participant included in this study.

---

**Conflicts of interest**

All authors have none to declare.

**REFERENCES**

---

1. Ofluoglu O, Yasmin D, Donthineni R, Muzaffler Y. Superior dislocation of the patella with early onset

patellofemoral arthritis: a case report and literature review. *Knee Surg Sports Traumatol Arthrosc.* 2006;14: 350–355.

2. Chauhan A, Maheswaran S, Anand S. Horizontal intraarticular dislocation of patella—a case report and review of literature. *Injury Extra.* 2014;45(9): 80–82.
3. Rollinson PD. Vertical intercondylar dislocation of the patella. *Injury.* 1988;19:281–282.
4. Shetty S, Ramesh B, Gul A, Madhusudan TR, Altayeb T. Vertical dislocation of the patella: report of 2 cases. *Orthopedics.* 2009;32:768–770.



# Instructions to Authors

## Before you begin

Manuscripts submitted to *Journal of Arthroscopy and Joint Surgery* should not have been published previously or be under simultaneous consideration for publication by any other journal. Violation may lead to a retraction of the published article by the Journal and other actions as deemed necessary by the editor. All articles (including those invited) will be peer-reviewed, and accepted articles will be edited to the Journal's style. Accepted manuscripts become the permanent property of the Journal and may not be reproduced, in whole or in part, without the written permission of the editor.

Studies involving human subjects or animals should have received the approval of the institutional ethics committee. A statement to this effect and that informed consent was obtained from participating human subjects must be included in the manuscript text.

## Ethics in publishing

For information on Ethics in publishing and Ethical guidelines for journal publication see <http://www.elsevier.com/publishingethics> and <http://www.elsevier.com/ethicalguidelines>.

## Conflict of interest

All authors must disclose any financial and personal relationships with other people or organizations that could inappropriately influence (bias) their work. Examples of potential conflicts of interest include employment, consultancies, stock ownership, honoraria, paid expert testimony, patent applications/registrations, and grants or other funding. See also [http://www.elsevier.com/conflicts\\_of\\_interest](http://www.elsevier.com/conflicts_of_interest). Further information and an example of a Conflict of Interest form can be found at: [http://elsevier6.custhelp.com/app/answers/detail/a\\_id/286/p/7923/](http://elsevier6.custhelp.com/app/answers/detail/a_id/286/p/7923/).

## Submission declaration and Verification

Submission of an article implies that the work described has not been published previously (except in the form of an abstract or as part of a published lecture or academic thesis or as an electronic preprint, see <http://www.elsevier.com/postingpolicy>, that it is not under consideration for publication elsewhere, that its publication is approved by all authors and tacitly or explicitly by the responsible authorities where the work was carried out, and that, if accepted, it will not be published elsewhere in the same form, in English or in any other language, including electronically without the written consent of the copyright holder. To verify originality, your article may be checked by the originality detection service CrossCheck <http://www.elsevier.com/editors/plagdetect>.

## Authorship

All authors should have made substantial contributions to all of the following: (1) the conception and design of the study, or

acquisition of data, or analysis and interpretation of data, (2) drafting the article or revising it critically for important intellectual content, (3) final approval of the version to be submitted. Please give contribution of each author on the cover page of the manuscript.

## Changes to authorship

Ideally there should not be any change in authorship after the manuscript is submitted. In situations where there has been an omission or substantial work is done when the article is revised, an author's name may be added. This policy concerns the addition, deletion, or rearrangement of author names in the authorship of accepted manuscripts:

*Before the accepted manuscript is published in an online issue:*

Requests to add or remove an author, or to rearrange the author names, must be sent to the Journal Manager from the corresponding author of the accepted manuscript and must include: (a) the reason the name should be added or removed, or the author names rearranged and (b) written confirmation (e-mail, fax, letter) from all authors that they agree with the addition, removal or rearrangement. In the case of addition or removal of authors, this includes confirmation from the author being added or removed. Requests that are not sent by the corresponding author will be forwarded by the Journal Manager to the corresponding author, who must follow the procedure as described above. Note that: (1) Journal Managers will inform the Journal Editors of any such requests and (2) publication of the accepted manuscript in an online issue is suspended until authorship has been agreed upon by the editor.

*After the accepted manuscript is published in an online issue:*

Any requests to add, delete, or rearrange author names in an article published in an online issue will follow the same policies as noted above and result in a corrigendum.

## Reporting Clinical Trials

All randomized controlled trials submitted for publication should include a completed Consolidated Standards of Reporting Trials (CONSORT) flowchart. Please refer to the CONSORT statement website at <http://www.consortstatement.org> for more information. This journal has adopted the proposal from the International Committee of Medical Journal Editors (ICMJE) which require, as a condition of consideration for publication of clinical trials, registration in a public trials registry. Trials must register at or before the onset of patient enrolment. The clinical trial registration number should be included at the end of the abstract of the article. For this purpose, a clinical trial is defined as any research study that prospectively assigns human participants or groups of humans to one or more health-related interventions to evaluate the effects of health outcomes. Health related interventions include any intervention used to modify a biomedical or health related outcome (for example drugs,

surgical procedures, devices, behavioral treatments, dietary interventions, and process-of-care changes). Health outcomes include any biomedical or health-related measures obtained in patients or participants, including pharmacokinetic measures and adverse events. Purely observational studies (those in which the assignment of the medical intervention is not at the discretion of the investigator) will not require registration. Further information can be found at <http://www.icmje.org>.

## Copyright

Upon acceptance of an article, authors will be asked to complete a 'Journal Publishing Agreement' (for more information on this and copyright see <http://www.elsevier.com/copyright>). Acceptance of the agreement will ensure the widest possible dissemination of information. An e-mail will be sent to the corresponding author confirming receipt of the manuscript together with a 'Journal Publishing Agreement' form or a link to the online version of this agreement.

## Role of the funding source

You are requested to identify who provided financial support for the conduct of the research and/or preparation of the article and to briefly describe the role of the sponsor(s), if any, in study design; in the collection, analysis and interpretation of data; in the writing of the report; and in the decision to submit the article for publication. If the funding source(s) had no such involvement then this should be stated. Please see <http://www.elsevier.com/funding>.

## Submission of Manuscripts

The journal only accepts online submissions in electronic format. All new manuscripts must be submitted through *Journal of Arthroscopy and Joint Surgery* online and review website (<http://ees.elsevier.com/jajs>). Authors are requested to submit the text, tables, and figures in electronic form to this address. Please follow the following steps to submit your manuscript:

1. Open the homepage of the journal's website (<http://ees.elsevier.com/jajs>).
2. Register yourself for free by clicking on "Register" on the top and create a user profile with a desired username and mandatory details. On submission of the information, you will receive an E-mail confirming your registration along with the "Password".
3. Click "Log In" on the main navigation menu at the top of the journal screen to open the login page.
4. Enter your username and password in the appropriate fields (E-mailed to you at the time of registration). Click "Author Log in", this takes you to the "Author Main Menu".

**Note:** Please note that the username and password combination required for Elsevier Editorial System is different from the username and password combination used to "Track your paper" on the Elsevier "Authors' Home" website.

By submitting a manuscript, the author agrees to the following:

1. The work is original and free from plagiarism.

2. It has neither been published, nor is it not under consideration for publication at another journal.
3. All authors are aware of the authorship order. The corresponding author shall be responsible in case of dispute.
4. Once published, copyright of manuscript shall stand transferred to the Journal.
5. 'Conflict of interest' if any, must be explicitly stated at the end of the manuscript.

Manuscripts must conform to the instructions given below:

**General:** Type the manuscript using 'Times New Roman' font, size 12 in double space throughout. Please arrange the manuscript as follows: Title page, Abstract, Introduction, Methods, Results, Discussion, and References. Number all pages consecutively, beginning with the title page. All figures and Tables must be referred to in the manuscript. Consult a recent issue of the Journal for details. Only the Title page should bear the names and addresses of the author(s). Editorials, perspective and review articles are generally by invitation. However if you are interested in writing a review/perspective, you can send an email to the editor with the topic and a short summary of contents to be included. The editor will convey his decision in 7-10 days' time.

**Length of articles:** Text of original articles should be between 2000 and 3500 words. The article should not ordinarily contain more than 3 tables, 2 figures and 25 references. Case Reports are accepted only if they can be converted into 'What is your diagnosis?' format (please consult a recent issue of the Journal). Briefly, the format consists of case report of about 500 words, a diagnostic image followed by the actual diagnosis/answer and discussion (250 words) and upto 5 references. Letters discussing or criticizing material published recently in the Journal, brief presentations of data, or those pertaining to issues of relevance to health policy, practice of medicine, or the like, are welcome. These should not exceed 500 words, 1 table and 5 references.

**Title page:** In animal studies, the title should state the species; all other titles will refer to human studies. State names of authors (including first names), the departments and the institution where the work was done. Please do not add your academic qualifications, designation etc. State contribution of each author clearly. A short, running title, not exceeding 40 characters, should be provided. Please provide the name, postal address with PIN code, facsimile number and E-mail address of the author to whom communications and proofs are to be sent. Acknowledgements, if any, may be mentioned on this page.

**Acknowledgements:** These should appear at the end of the manuscript. The *source of funding* as well as a *disclosure statement* mentioning *conflict of interest*, if any, should appear under this heading.

**References:** Number the references in the order in which they first appear in the text and identify the reference numbers in the text in superscript. References must be placed at the end of the manuscript. Please use recent references as much as possible. The responsibility for accuracy of

references lies with the respective authors. The Journal is in agreement with the International Committee of Medical Journal Editors ([www.icmje.org](http://www.icmje.org)). The general arrangement, abbreviations of Journal names and punctuations followed are as per the Uniform Requirements for Manuscripts submitted to Biomedical Journals ([www.icmje.org](http://www.icmje.org)). Please pay attention to the style of references and punctuations as follows:

#### *Journal article*

List all authors when six or less as shown in the example below: Tallon D, Chard J, Dieppe P. Exploring the priorities of patients with osteoarthritis of the knee. *Arthritis Care and Res* 2000;13:312–9.

When there are seven or more authors, list only the first six and add et al.

#### *Book or monograph*

Following is an example: Cassidy JT. Juvenile rheumatoid arthritis. In: *Textbook of Rheumatology* 6th ed, Kelly et al (eds) Philadelphia Saunders 2000; pp. 1297–313.

**Tables:** Each Table should be typed on a separate page and numbered consecutively in Arabic numerals. Each table should have a title and all abbreviations should be explained in the footnote. Necessary explanatory notes, if any, may be given below the Table.

**Figures/Illustrations/Photographs:** Photographs of 300 dpi or higher resolution may be submitted as ‘jpeg’, or ‘tiff’ files in a zipped folder. In clinical photographs, identity of the subjects should be suitably masked; in case this is not

possible, a written permission from the concerned person should accompany the manuscript.

**Legends to Figures:** The Figure number (numbered consecutively in Arabic numerals), title and explanations of the Figures should appear in the legend (not on the Figure). Type the legends on a separate page. Enough information should be included to interpret the Figure without reference to the text.

**Units:** All measurements must be in metric units, preferably with corresponding SI units in parentheses.

**Editorial Process:** All articles submitted to the Journal undergo initial review by the Editor/associate editor and articles that are outside the scope of Journal or are not in the journal format are excluded. Later each article is reviewed by at least two reviewers. The time to first decision is usually less than 6 weeks.

As per the policy of the *Journal*, an Editor, who is either author of a manuscript or belongs to the same institution as any of the authors, is not assigned that manuscript and is not involved in decision-making regarding its publication. Reviewers/Editorial Board members should decline the invitation to review a manuscript which is submitted by authors from their institution.

**Reprints:** Reprints may be requested and are provided on payment.

**Address all correspondence to: Prof. Ravi Gupta or Mr. Sanjeev Anand, Chief Editors, Journal of Arthroscopy and Joint Surgery at [editorjajs@gmail.com](mailto:editorjajs@gmail.com).**



# Over Four Centuries of Publishing Experience!





With deep roots in health sciences publishing, Elsevier helps doctors advance practice of medicine by providing world-class information which helps them make critical decisions and improve patient outcomes.

Elsevier brings to you over 2,000 health sciences journals, and works with over 7,000 journal editors, 70,000 editorial board members, 300,000 reviewers and 600,000 authors. As the world's leading publisher of science and health information, Elsevier brings to you knowledge products including:

- *The Lancet*
- *The Clinics of North America*
- *Gray's Anatomy*
- *Nelson's Pediatrics*
- *Dorland's Illustrated Medical Dictionary*
- *Netter's Atlas of Human Anatomy*




## Leading Indian Journals from the House of Elsevier



For advertisement and subscription enquiries in Elsevier journals,  
please write to [journals.india@elsevier.com](mailto:journals.india@elsevier.com)








# Over Four Centuries of Publishing Experience!

With deep roots in health sciences publishing, Elsevier helps doctors advance practice of medicine by providing world-class information which helps them make critical decisions and improve patient outcomes.

Elsevier brings to you over 2,000 health sciences journals, and works with over 7,000 journal editors, 70,000 editorial board members, 300,000 reviewers and 600,000 authors. As the world's leading publisher of science and health information, Elsevier brings to you knowledge products including:

- *The Lancet*
- *The Clinics of North America*
- *Gray's Anatomy*
- *Nelson's Pediatrics*
- *Dorland's Illustrated Medical Dictionary*
- *Netter's Atlas of Human Anatomy*

## Leading Indian Journals from the House of Elsevier



For advertisement and subscription enquiries in Elsevier journals,  
please write to [journals.india@elsevier.com](mailto:journals.india@elsevier.com)



## Our Products

IN OSTEOPOROSIS

R<sub>x</sub>

Cap.



**SARVACAL**<sup>TM</sup>  
Calcium Carbonate with Calcitriol  
& Zinc Softgel Capsules

*The Essential Calcium*

*In Low Back Pain & Arthritis*

R<sub>x</sub>

Tab.



**ANKON**<sup>TM</sup> **90 / 120**  
Etoricoxib 90/120 mg

*Lets Your Patient Move ON...*

IN VITAMIN D DEFICIENCY

R<sub>x</sub>

Cap.



**D-3 ONCE**<sup>TM</sup>  
(Cholecalciferol 60,000 IU)

*The Vitamin That Matter*

In Co - R<sub>x</sub> With NSAID

R<sub>x</sub>

Cap.



**Rabbitrol D**<sup>TM</sup>

(Rabeparazole 20 mg + Domperidome 30mg SR)

Helpline : 9582874697

All products are available at 98.4 Chemist Retail Chain