

Want to receive weekly  
clinical updates about  
COVID-19?

Visit the  
PracticeUpdate  
COVID-19  
Disease Spotlight

Gain free access to expert insights on the most recent research and  
clinical information.

Our COVID-19 Disease Spotlight provides:



Weekly scans of  
premier journals



A summary of the most  
important, practice-relevant  
findings



Commentary on these  
findings to help put them  
into perspective

Don't miss out — visit [covid19.PracticeUpdate.com](https://www.covid19.PracticeUpdate.com) today!



JOURNAL OF ARTHROSCOPY AND JOINT SURGERY

# JAJJS

Official Journal of the International Society for Knowledge for  
Surgeons on Arthroscopy and Arthroplasty (ISKSA)

**Indexed In Scopus & Embase**

**Volume 8 Number 1 January-March 2021**

**E-ISSN: 2214-9635  
P-ISSN: 2542-6001**

Available online at [www.sciencedirect.com](https://www.sciencedirect.com)

**ScienceDirect**



ISKSAA (International Society for Knowledge for Surgeons on Arthroscopy and Arthroplasty) is a society of orthopaedic surgeons from around the world to share and disseminate knowledge, support research and improve patient care in Arthroscopy and Arthroplasty. We are proud to announce that ISKSAA membership has crossed the **2000** mark ( India & Overseas ) with members from **over 40 countries** making it the **fastest growing Orthopaedic Association in the country & region** in just 8 years of its inception . With over **400000 hits from over 164 countries** on the website [www.isksaa.com](http://www.isksaa.com) & more and more interested people joining as members of ISKSAA, we do hope that ISKSAA will stand out as a major body to provide opportunities to our younger colleagues in training, education and fellowships.

**Our Goals.....**

- To provide health care education opportunities for increasing cognitive and psycho-motor skills in Arthroscopy and Arthroplasty
- To provide CME programs for the ISKSAA members as well as other qualified professionals.
- To provide Clinical Fellowships in Arthroscopy and Arthroplasty
- To provide opportunities to organise and collaborate research projects
- To provide a versatile website for dissemination of knowledge

**ISKSAA Life Membership**

The membership is open to Orthopaedic Surgeons, Postgraduate Orthopaedic students and Allied medical personal interested in Arthroscopy & Arthroplasty.

**Benefits of ISKSAA Life membership include....**

- **Free Subscription** of ISKSAA's official , SCOPUS INDEXED , EMBASE INDEXED peer reviewed , online scientific journal **Journal of Arthroscopy and Joint Surgery ( JAJS )** .
- Eligibility to apply for **ISKSAA's Prestigious Fellowship Programme**. We have finalised affiliations with ESSKA , ISAKOS , BOA , BASK , BOSTAA , BESS , Edge Hill University at Wrightington and FLINDERS MEDICAL CENTRE , IMRI AUSTRALIA to provide more **ISKSAA Fellowships** in India , UK , USA , Australia and Europe . We have offered over **400 Clinical Fellowships as of date including 54 in ISKSAA 2014 , 40 in ISKSAA 2015 , 63 in ISKSAA 2016 , 55 in ISKSAA 2017 , 20 in ISKSAA 2018 & 100 in ISKSAA 2019 and over 50 ISKSAA Wrightington MCh Fellowships from 2014 to 2018 .**
- We have initiated **ISKSAA JOD & ISKSAA WHA paid fellowship programs** from 2017 for 2 months based in Australia .
- **The current round of 100 ISKSAA fellowships interviews were held in ISKSAA BESS 2019 in March 2-3<sup>rd</sup> 2019 for 2019 and 2020 at New Delhi along with the ISKSAA Wrightington MCh Fellowships .**
- **The next round of ISKSAA fellowship interviews will be in third quarter of 2021 at New Delhi .**
- We had offered **60 1 week ISKSAA certified Fellowships** from 11<sup>th</sup> – 15<sup>th</sup> June & 25-29<sup>th</sup> June 2018 for ISKSAA members registered for ISKSAA LEEDS 2018 on a first come first basis .
- Only as a life member , you can enjoy the benefit of **reduced Congress charges** in future ISKSAA Conferences .
- **Member's only section** on the website which has access to the conference proceedings and live surgeries of ISKSAA 2012 , 2013 , 2014 & 2016 along with a host of other educational material .
- Important opportunity for interaction with world leaders in Arthroscopy & Arthroplasty .
- Opportunity to participate in ISKSAA courses and workshops

To enjoy all the benefits & privileges of an ISKSAA member, you are invited to apply for the Life membership of ISKSAA by going to the membership registration section of the website and entering all your details electronically. All details regarding membership application and payment options are available on the website ([www.isksaa.com](http://www.isksaa.com))

offers the highly specialized range



**FOR OSTEOARTHRITIS MANAGEMENT**

Cross Linked

**BIOVISC**  
**ORTHO SINGLE PFS**  
Hyaluronic Acid Inj. 3ml (90mg / 3ml)

Optimum Volume, Sustained Effect

90 High Concentration HA

Cross-Linked

High Molecular Weight

**HYNEES**<sup>®</sup>  
**PFS**  
Sodium Hyaluronate Inj. 2ml (10mg / ml)

For effective management of osteoarthritis

Non Avian Source

High Molecular Weight

**FOR OSTEOPOROSIS MANAGEMENT**

Recombinant Human Parathyroid Hormone (1-34)  
**ELEVOSTEO**<sup>®</sup>  
Teriparatide Injection (rDNA origin)

**ELEVATING OSTEOGENESIS**

Increases Bone Formation

Reduces Risk of Fractures

**ZOLVOID**<sup>®</sup>  
Zoledronic Acid Infusion 5mg/100ml

The GOLD STANDARD in Osteoporosis Treatment

Once A Year Dose

Effective and Safe

**For Comprehensive Mobility Solutions**

A WHO - GMP Certified Company

NATIONAL TOLL FREE HELPLINE: 1800 1111 55

An ISO : 9001 - 2008 Certified Company

# Journal of Arthroscopy and Joint Surgery

An official publication of International Society for Knowledge for Surgeons on Arthroscopy and Arthroplasty

(ISSN: 2214-9635)

Volume 8, Number 1, January–March 2021

## Aims and Scope

*Journal of Arthroscopy and Joint Surgery* (JAJS) is committed to bring forth scientific manuscripts in the form of original research articles, current concept reviews, meta-analyses, case reports and letters to the editor. The focus of the Journal is to present wide-ranging, multi-disciplinary perspectives on the problems of the joints that are amenable with Arthroscopy and Arthroplasty. Though Arthroscopy and Arthroplasty entail surgical procedures, the Journal shall not restrict itself to these purely surgical procedures and will also encompass pharmacological, rehabilitative and physical measures that can prevent or postpone the execution of a surgical procedure. The Journal will also publish scientific research related to tissues other than joints that would ultimately have an effect on the joint function.

## Author inquiries

You can track your submitted article at <http://www.elsevier.com/track-submission>. You can track your accepted article at <http://www.elsevier.com/trackarticle>. You are also welcome to contact Customer Support via <http://support.elsevier.com>

## Copyright

© 2021, International Society for Knowledge for Surgeons on Arthroscopy and Arthroplasty. Published by Elsevier B.V. All rights reserved. Papers accepted for publication become the copyright of *International Society for Knowledge for Surgeons on Arthroscopy and Arthroplasty*, and authors will be asked to sign a transfer of copyright form, on receipt of the accepted manuscript by Elsevier. This enables the Publisher to administer copyright on behalf of the Authors, whilst allowing the continued use of the material by the Author for scholarly communication.

**This journal and the individual contributions contained in it are protected under copyright by Elsevier B.V., and the following terms and conditions apply to their use:**

## Photocopying

Single photocopies of single articles may be made for personal use as allowed by national copyright laws. Permission of the Publisher and payment of a fee is required for all other photocopying, including multiple or systematic copying, copying for advertising or promotional purposes, resale, and all forms of document delivery. Special rates are available for educational institutions that wish to make photocopies for non-profit educational classroom use.

For information on how to seek permission visit <http://www.elsevier.com/permissions> or call: (+44) 1865 843830 (UK) / (+1) 215 239 3804 (USA).

## Derivative Works

Subscribers may reproduce table of contents or prepare lists of articles including abstracts for internal circulation within their institutions. Permission of the Publisher is required for resale or distribution outside the institution. Permission of the Publisher is required for all other derivative works, including compilations and translations (please consult [www.elsevier.com/permissions](http://www.elsevier.com/permissions)).

## Electronic Storage or Usage

Permission of the Publisher is required to store or use electronically any material contained in this journal, including any article or part of an article (please consult [www.elsevier.com/permissions](http://www.elsevier.com/permissions)).

Except as outlined above, no part of this publication may be reproduced, stored in a retrieval system or transmitted in any form or by any means, electronic, mechanical, photocopying, recording or otherwise, without prior written permission of the Publisher.

## Notice

No responsibility is assumed by the Publisher for any injury and/or damage to persons or property as a matter of products liability, negligence or otherwise, or from any use or operation of any methods, products, instructions or ideas contained in the material herein. Because of rapid advances in the medical sciences, in particular, independent verification of diagnoses and drug dosages should be made.

Although all advertising material is expected to conform to ethical (medical) standards, inclusion in this publication does not constitute a guarantee or endorsement of the quality or value of such product or of the claims made of it by its manufacturer.

## Subscription information

The *Journal of Arthroscopy and Joint Surgery* (ISSN: 2214-9635) is published thrice a year. The annual price for **individual subscription** based in India is **INR 3600**; and for international subscribers, the annual price is **USD 60**. For **institutional subscription** within and outside India, please contact the Publishers office at [journals.india@elsevier.com](mailto:journals.india@elsevier.com).

Further information is available on this journal and other Elsevier products through Elsevier's website (<http://www.elsevier.com>). Subscriptions are accepted on a prepaid basis only and are entered on a calendar year basis. Issues are sent by standard mail. Priority rates are available upon request. Claims for missing issues should be made within six months of the date of dispatch.

**Orders, claims, advertisement and journal inquiries:** Please visit our Support Hub page <https://service.elsevier.com> for assistance.

**Editorial Office:** Dr Pushpinder Singh Bajaj, Bajaj Specialist Clinics, B-7/5 Safdarjung Enclave, New Delhi – 110029. Tel: 41057555 / 41057556 / 41057557. Email: [psbajaj@hotmail.com](mailto:psbajaj@hotmail.com).

# Journal of Arthroscopy and Joint Surgery

An official publication of International Society for Knowledge for Surgeons on Arthroscopy and Arthroplasty

(ISSN: 2214-9635)

Volume 8, Number 1, January-March 2021

## Editors-in-Chief

MR SANJEEV ANAND UK

DR AMOL TAMBE UK

PROF HEMANT PANDIT UK

## Executive Editors

PROF LALIT MAINI Delhi  
PROF RAVI GUPTA Chandigarh

## Managing Editor

DR PUSHPINDER BAJAJ Delhi

## Deputy Editor

MR KAPIL KUMAR UK

## Section Editors

### Trauma & Rehabilitation

DR ALEXANDER WOOD UK

### Hip

DR AJAY AGGARWAL USA

### Foot & Ankle

DR MUNEESH BHATIA UK

### Training & Education

DR JANAK MEHTA Australia

### Arthroplasty

DR MANOJ SOOD UK

### Pediatric Orthopaedics

DR PARMANAND GUPTA

### Orthopaedic Oncology

DR MANISH PARUTHI

### Elbow, Wrist & Hand

DR RAJ MURALI UK

### Shoulder

DR MANIT ARORA Mohali

## Associate Editors

DR DINESH PATEL USA  
DR PONKY FIRER South Africa

PROF JEGAN KRISHNAN Australia  
DR GURINDER BEDI Delhi

DR RAJESH SETHI UK  
DR DINSHAW PARDIWALA Maharashtra

## Editorial Board

PROF GIANNOUDIS UK  
PROF AMAR RANGAN UK  
DR KHALID MOHAMMAD New Zealand  
DR MAKARAM SRINIVASAN UK  
DR V BHALAIK UK  
DR PUNEET MONGA UK

DR TAOFEEK ADEYEMI Nigeria  
DR M S DHILLON Chandigarh  
DR VIVEK PANDEY Karnataka  
DR SUNDARARAJAN Tamil Nadu  
DR ASHISH DEVGAN Haryana  
DR RAJU EASWARAN Delhi

DR RAHUL KHARE Delhi  
DR AMITE PANKAJ Delhi  
DR DHANAJAY SABAT Delhi  
DR AMIT SHARMA Delhi  
DR YUVARAJAN P Coimbatore

## Advisory Board

DR ANDREAS SETTJE Germany  
DR ANANT JOSHI Maharashtra  
DR ASHOK RAJGOPAL Delhi  
DR ASHISH BABULKAR Pune  
DR ASIT SHAH USA  
DR ANIL BHAT Karnataka  
MR BINOD SINGH UK  
DR BINU THOMAS Tamil Nadu  
DR DAVID MARTIN Australia  
DR DAVID RAJAN Tamil Nadu  
DR DENNY LIE Singapore  
DR EDWARD T MAH Australia  
DR GRAHAM MERCER Australia  
DR H K WONG Hong Kong

DR HIROYUKI SUGAYA Japan  
DR HITESH GOPALAN Karnataka  
PROF J E MENDES Portugal  
DR JAAP WILLEMS Netherlands  
DR JOHN EBNEZAR Karnataka  
DR JVS VIDYASAGAR Andhra Pradesh  
PROF LENNARD FUNK UK  
DR MARIO PENTA Australia  
DR NICK WALLWORK Australia  
DR NIRBHAY SHAH Gujarat  
DR PAOLO PALADINI Italy  
DR PARAG SANCHETI Pune  
DR PETER CAMPBELL Australia  
PROF P P KOTWAL Delhi

PROF RAJASEKARAN Tamil Nadu  
MR RAM VENKATESH UK  
MR R PANDEY UK  
PROF RAJ BAHADUR Chandigarh  
MR ROBERT J GREGORY UK  
DR ROHIT ARORA Austria  
DR SACHIN TAPASVI Pune  
DR SANJAY DESAI Maharashtra  
DR SANJAY GARUDE Maharashtra  
DR SANJAY TRIVEDI Gujarat  
DR SRIPATHI RAO Karnataka  
PROF SUDHIR KAPOOR Delhi  
MR VED GOSWAMI UK  
DR YOUNG LAE MOON Korea

Copyright (C) 2021, International Society for Knowledge for Surgeons on Arthroscopy and Arthroplasty. All rights reserved.

Published by Elsevier B.V.

No part of the publication may be transmitted in any form or by any means, electronic or mechanical, without written permission from the Editor-in-Chief.

*Disclaimer: Although all advertising material is expected to conform to ethical (medical) standards, inclusion in the publication does not constitute a guarantee or endorsement of the quality or value of such product or of the claims made of it by its manufacturer. Please consult full prescribing information before issuing prescriptions for any products mentioned in this publication.*



# Journal of Arthroscopy and Joint Surgery

An official publication of International Society for Knowledge for Surgeons on Arthroscopy and Arthroplasty

(ISSN: 2214-9635)

Volume 8, Number 1, January–March 2021

## Table of Contents

Editorial comment <i>Kapil Kumar, Amol Tambe</i>	1
History of shoulder arthroplasty <i>W. Jaap Willems</i>	2
The biomechanics of reverse shoulder arthroplasty <i>Sanjeeve Sabharwal, Steve Bale</i>	7
Surface Replacement of the Shoulder - a Commentary <i>Sanjay S. Desai, Bharat Sharma</i>	13
Shoulder Arthroplasty - Optimising Outcome <i>Wallwork Nicholas Alexander</i>	16
Shoulder arthroplasty - Which stem? <i>Peadar Antaine Mac Suibhne, Cormac Kelly</i>	20
Surgical rationale and controversies of glenoid replacement in osteoarthritis: How to choose the glenoid implant? <i>Giuseppe Sircana, Giovanni Merolla, Paolo Paladini</i>	27
Navigation in Shoulder Arthroplasty <i>Andrew P. Dekker, Amol A. Tambe</i>	35
Total elbow arthroplasty: Evolution and biomechanics <i>Parag Kirit Shah, Chittaranjan Parimal Patel</i>	44
Total elbow arthroplasty: Potential problems and technical considerations – Case studies <i>Sudhakar Rao Challagundla, Scott Barker, Kapil Kumar</i>	49
Functional outcomes are improved after rotator cuff repair in the Indian population: A systematic review <i>Manit Arora, Sidhartha Sohan, Avinash K. Sinha</i>	57
The balloon spacer improves outcomes in only a minority of patients with an irreparable rotator cuff tear <i>Eshan N.H. Oderuth, Daniel L.J. Morris, Paul A. Manning, John M. Geoghegan, Ben W. Gooding, Malin D. Wijeratna</i>	64
Anatomical acromioclavicular joint reconstruction with conventional ACL tightrope: A novel technique <i>Sandeep K. Nema, Jose Austine, Deepak Uppin</i>	71
Management of intercondylar fractures of the humerus by triceps-reflecting anconeus pedicle (TRAP) and olecranon osteotomy approaches- A comparative study <i>Ankit Mittal, S.P.S. Gill, Manish Raj, Harish Kumar, Santosh K. Singh, Jitesh Arora</i>	75
Evolution of augmented reality applications in Orthopaedics: A systematic review <i>Sagar Bagwe Dr., Keshave Singh Dr., Abhishek Kashyap Dr., Sumit Arora Dr., Lalit Maini Dr.</i>	84

ScienceDirect®

Discover more  
breakthroughs



ELSEVIER



International Society for Knowledge for Surgeons  
on Arthroscopy and Arthroplasty

Wrightington, Wigan and Leigh   
NHS Foundation Trust



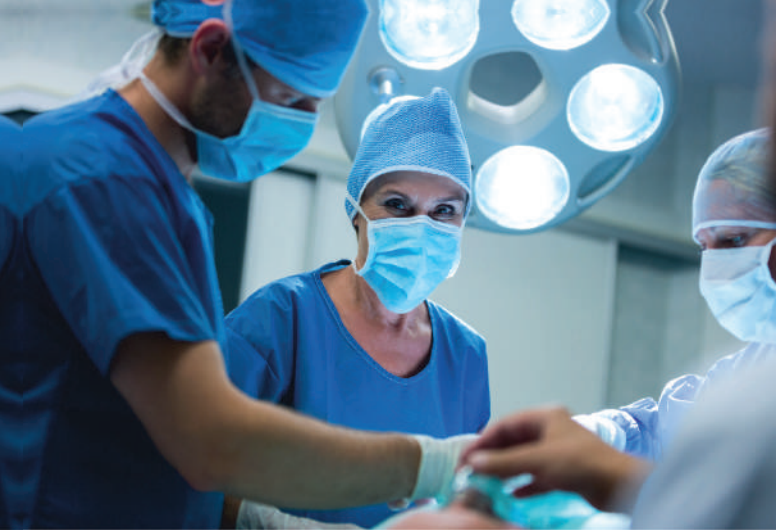Edge Hill University

### **ISKSAA – Wrightington International Training Fellowships leading to MCh degree ( 2021 ).**

Interested candidates are invited to apply for a unique opportunity for post-graduate education and subspecialist training in the UK

1. The interested candidates are encouraged to look at the University website link . The programme is aimed at motivated candidates who wish to come to UK to obtain 2-3 years of clinical experience, specialist surgical training and an MCh degree from Wrightington Hospital and Edge Hill University.
2. The interviews are slated for April 2021 in New Delhi when the recruitment team will be visiting India. The exact dates and venues will be confirmed in due course.
3. **Having cleared the IELTS exam** before the interviews will be of advantage for final selections .
4. The Clinical posts would start in July 2021 although if candidates were to be interested for August 2022 start, they could still apply.
5. The MCh course is at the Edge Hill University and although most of the payment for the course can be made along the way in installments over the 2 years, there would be an initial Commitment of £8,000 to be made to secure the place before the formalities with Royal colleges and GMC are commenced at this End. The salary scales are detailed with the information sheet as well.
6. There will be two posts per year as the "Wrightington - ISKSAA MCh Fellowship". There would be an **assured Wrightington placement** during the 2-year UK rotation via this stream . **Only ISKSAA Life Members can apply for these posts** .
7. **THE EMAIL SHOULD MENTION ISKSAA MEMBERSHIP NUMBER VERY CLEARLY**
8. THESE ARE SALARIED JOBS IN THE NHS AND SO ARE FULLY FUNDED .



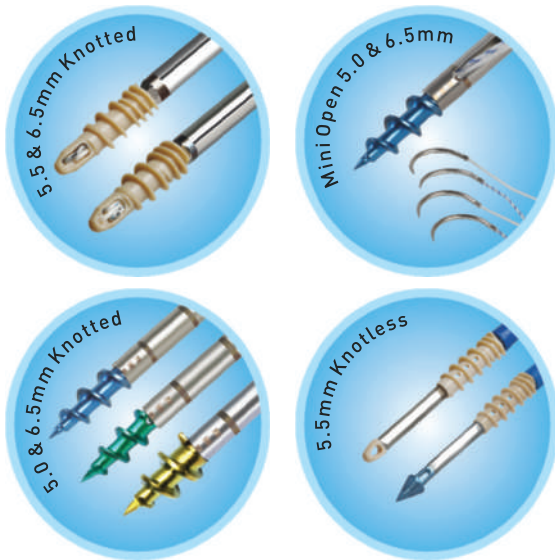


**BIOTEK**<sup>®</sup>  
we put life in metal

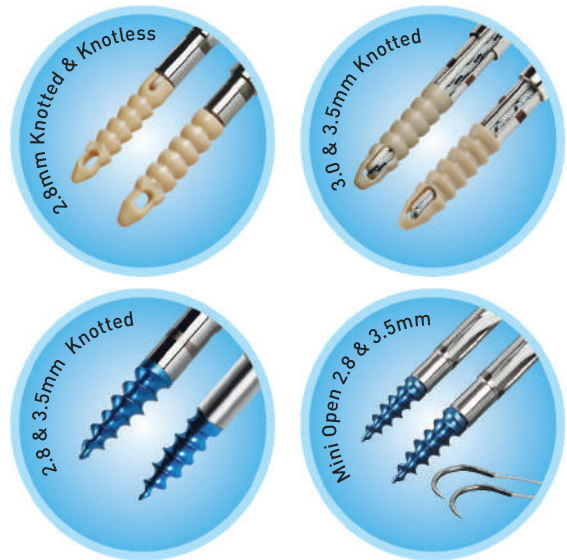Technology that touches *life.*

**SHOULDER ARTHROSCOPY**

Suture Anchors for Rotator Cuff Repair




Suture Anchors for Slap & Bankart Repair

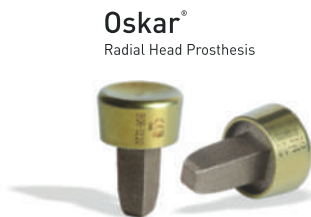
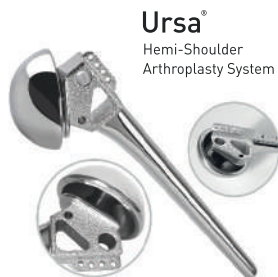
**OPEN LATARJET**

Latarjet /  
Coracoid  
Process Transfer



**EXTREMITIES**







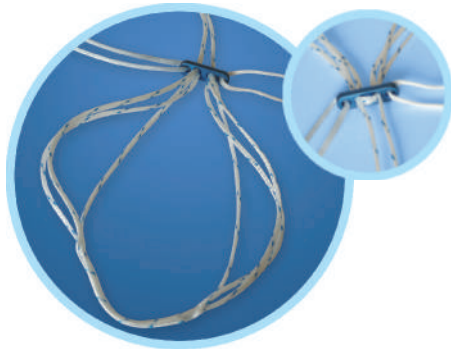
**BIOTEK**<sup>®</sup>  
we put life in metal

Technology that  
**touches** *life.*

## KNEE ARTHROSCOPY

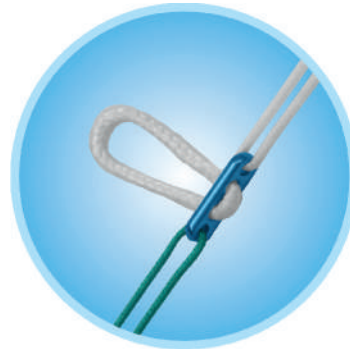### Buttonfix

Adjustable Loop Device



### Onbutton CL

Closed Loop Device



Offering two of the strongest soft tissue suspensory fixation devices for Cruciate Reconstruction.

### Softfix-PK

Interference Screws  
(PEEK)



### Softfix

Interference Screws  
(Titanium)

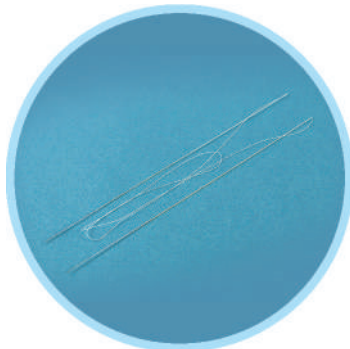


### Osteotwin

Bio Composite Interference  
Screws



### Meniscus Repair (Inside-Out)



### Biddu HTO



Above all the products are CE Certified and Indian FDA.

**BIOTEK**<sup>®</sup>  
we put life in metal

### BIOTEK - Chetan Meditech Pvt. Ltd.

Opp. V. S. Hospital, Ellisbridge, Ahmedabad 380 006. Gujarat, INDIA.  
Phone: +91 79 2657 8092, 40098394, 79 2657 7639

Email: [info@biotekortho.com](mailto:info@biotekortho.com) Website: [www.biotekortho.com](http://www.biotekortho.com)







## Editorial

## Editorial comment



## Focus on Shoulder and Elbow arthroplasty

Shoulder arthroplasty has seen an exponential rise over the last decade. There were about 2500 primary shoulder replacement procedures performed in the UK in 2012, and this number increased to more than 7500 in 2019. Simultaneously there has been a decline in numbers of hemiarthroplasty procedures and a significant increase in the numbers of reverse shoulder arthroplasty procedures, which now account for nearly 2/3 of all primary shoulder arthroplasties.<sup>1</sup>

The types of prostheses being used has also seen a change with resurfacing procedures seeing a decline and increasing popularity of stemless humeral components. The humeral stem and its influence on shoulder arthroplasty is addressed in the paper by *Mac-Suibhne and Kelly*.

Glenoid component has remained the weak link on shoulder arthroplasty, and there have been ongoing efforts to improve glenoid component, in terms of materials, design and fixation methods. *Sircana and colleagues* look at glenoid design, modes of failure and prosthetic selection.

Reverse arthroplasty is now the most common type of shoulder arthroplasty and the indications continue to broaden with increasing numbers in proximal humeral fractures in the elderly.<sup>1</sup> There continues to be an evolution in designs of reverse arthroplasty with changes in neck shaft angle, and offset, which aim to address notching, and improved functional outcomes in terms of restoration of rotations. The biomechanical principles that drive these design changes are addressed in the paper by *Sabharwal and Bale*.

As the number of primary procedures has gone up there has been a corresponding increase in revision arthroplasty. A well performed primary arthroplasty procedure should not only improve clinical outcome, but also improve the longevity of the prostheses. Technological advances including Computer software for planning, Patient specific implants and Navigation. *Tambe et al.* explore the role of navigation for shoulder arthroplasty.

Numbers for Elbow arthroplasty are significantly less than the numbers for Shoulder arthroplasty, but over the last decade there has been a change in the indications. While inflammatory arthritis was the commonest indication for Elbow arthroplasty a decade ago, most elbow replacements are now performed for acute trauma.<sup>2</sup>

The evolution of designs of elbow arthroplasty is addressed by *Shah and Patel*, while *Challangudla et al.* look at common challenges of elbow arthroplasty with technical tips to deal with these.

The increasing numbers of upper limb arthroplasties, differing techniques and numerous prosthetic designs and systems pose a challenge not only to the budding surgeon but even to a well practiced clinician. It is hence important that the principles that underpin successful arthroplasty are studied and understood by everyone who embarks on arthroplasty in the upper limb. This will ensure that correct choices are made, desirable clinical results are achieved and we have met our patients' expectations.

This special issue is an attempt to address this very important issue and facilitate a focussed discussion that should endure in the long term.

We hope that the spectre of 2020 and Covid 19 is behind us and we wish you all a safe, enjoyable and enlightening 2021.

## References

1. National Joint Registry. <https://reports.njrcentre.org.uk/>.
2. Global trends in indications for total elbow arthroplasty: a systematic review of national registries *Macken AA, Prkic A, Kodde IF, Lans J, Chen NC, Eygendaal D. EFORT Open Rev. 2020 Apr 2;5(4):215–220. https://doi.org/10.1302/2058-5241.5.190036. eCollection 2020 Apr.*

Kapil Kumar  
Woodend Hospital, Aberdeen, UK  
E-mail address: [kapil.kumar2@nhs.scot](mailto:kapil.kumar2@nhs.scot).

Amol Tambe\*  
University Hospitals of Derby and Burton NHS Foundation Trust,  
University of Nottingham, UK

\* Corresponding author. University Hospitals of Derby and Burton  
NHS Foundation Trust, UK.  
E-mail address: [amol.tambe1@nhs.net](mailto:amol.tambe1@nhs.net) (A. Tambe).

Available online 26 February 2021



## Review article

## History of shoulder arthroplasty

W. Jaap Willems<sup>a, b</sup><sup>a</sup> Expert Clinics, Tesselschade straat 4, 1054ET, Amsterdam, the Netherlands<sup>b</sup> International Knee and Joint Centre, Abu Dhabi, United Arab Emirates

## ARTICLE INFO

## Article history:

Received 25 November 2020

Accepted 2 December 2020

Available online 7 December 2020

## Keywords:

Shoulder

Arthroplasty

History

## ABSTRACT

Since the end of the 19th century, when the first shoulder prosthesis was implanted, an impressive development took place, leading to many different designs, based on the philosophy of either an anatomic replacement or the inverse prosthesis for shoulders with an absent or insufficient rotator cuff. An overview is given on these developments from the beginning to the present.

© 2020 International Society for Knowledge for Surgeons on Arthroscopy and Arthroplasty. Published by Elsevier, a division of RELX India, Pvt. Ltd. All rights reserved.

## 1. Introduction

The first joint prosthesis implanted in the body was a total shoulder prosthesis. The procedure was carried out in 1893 in Paris (France) by a surgeon Jules Emile Péan for the treatment of tuberculosis of the shoulder.<sup>1</sup>

He firstly developed an ivory implant, based on the work of the German surgeon Themistocles Gluck,<sup>2</sup> who implanted several ivory prostheses in knee, hip, wrist and elbow, mainly for the treatment of tuberculosis. However Péan never used this ivory prosthesis out of concern of its mechanical properties.

A new prosthesis was constructed for him by a Parisian dentist who specialized in prosthetic development. It was made of an iridescent platinum tube with screw holes at the distal end for attachment to the humeral bony stump, a hardened rubber ball with 2 metal loops inserted into a groove for attachment to the glenoid and to the proximal aspect of the stem (Fig. 1). It was implanted in a young patient with end stage tuberculosis in the shoulder, who refused an amputation. It lasted for 2 years, chronic fistulae developed and finally it was removed, after which the sepsis subsided. Interestingly, on the radiographs a shell of bone was surrounding the metal implant.

This was the first metal implant in the body, preceding the first metal total hip, which was implanted in 1953 and the first metal total knee in 1973.

In the 1950s several new designs were introduced, made of plastic (acrylic, polyamide or polyethylene) or metal.

The main indications were fractures or tumours.

Richard<sup>3</sup> as well as Borin<sup>4</sup> from France implanted an acrylic prostheses for proximal humeral fractures (Fig. 2); even though the tuberosities were fixed to the acrylic head, the function was generally poor.

In the Royal National Orthopaedic Hospital in the U.K. a polyethylene prosthesis, fixed to the humerus with plates and screws, was used following tumour resection; all of them failed due to loosening of the plates.

## 1.1. Metal implants since 1950

Krueger<sup>5</sup> implanted the first metal anatomic hemiarthroplasty in 1950, made of chrome-cobalt alloy (vitallium), for treatment of avascular necrosis of the humeral head, resulting in a well functioning shoulder without pain.

1 year later Neer developed a shoulder prosthesis for patients with poor function and pain after a fracture.

He worked in his early days in a fracture department and was intrigued by the pathology of the shoulder fractures, which led him to develop a hemiarthroplasty as well as a classification system of proximal humeral fractures. He focused on a design made of inert material with an elasticity close to bone, mimicking normal anatomy and including sufficient anchorage with a long stem in the bone to avoid bone resorption (Fig. 3). He published the results of this Neer I in 1955 with good results.<sup>6</sup>

In the early 1970s both in the US<sup>7</sup> and in Germany US<sup>8</sup> independently polyethylene glenoid components were developed, combined with the Neer I prosthesis, which stimulated Neer to develop his Neer II prosthesis, usable as a non constrained

E-mail address: [w.j.willems@xs4all.nl](mailto:w.j.willems@xs4all.nl).



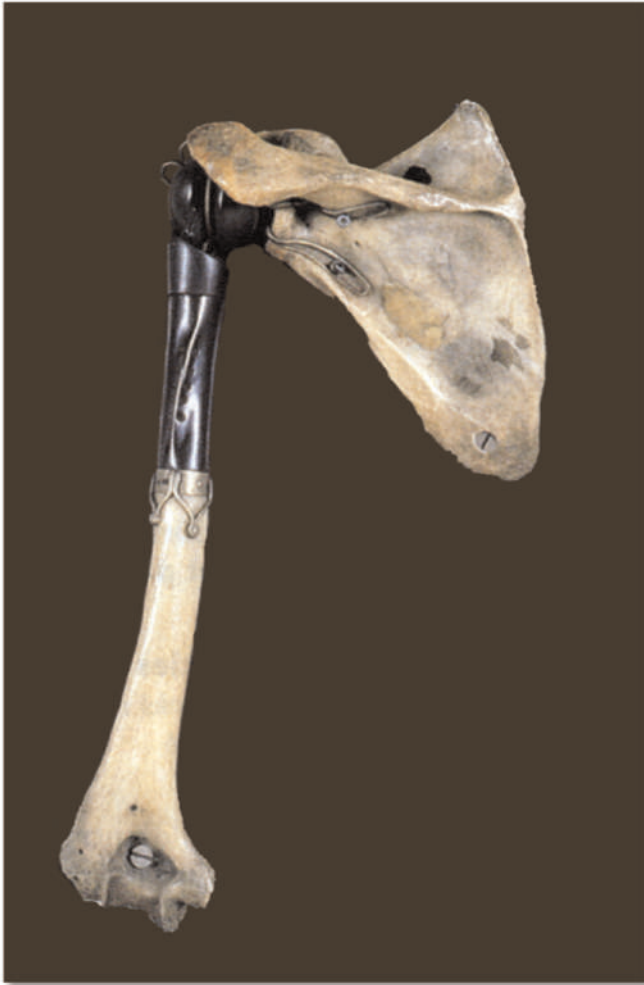

Fig. 1. Constrained prosthesis of Péan of platinum and rubber.

prosthesis in arthritis. This system however did not solve the problem of a deficient cuff, for which he developed a fixed fulcrum prosthesis, the Mark 1.

In the UK, the Stanmore prosthesis was introduced in 1972 for rheumatoid arthritis; it is a ball/socket configuration and looks like a hip prosthesis. Being a constrained design the authors reported a rather high loosening rate of the glenoid component and disappointing results.

In the US a similar type of constrained fixed fulcrum prosthesis was developed by Post,<sup>9</sup> with initially a stainless steel and later vitallium humeral stem and a combined polyethylene/metal glenoid component. This prosthesis also showed a rather high rate of complications, mainly dislocations and loosening.

Swanson<sup>10</sup> developed a bipolar shoulder prosthesis, with an unfixed metal cup with polyethylene liner articulating with a small ball of the humeral titanium cemented stem; the main indication was rheumatoid arthritis and in arthritic shoulders without cuff.

In this innovative period, when many designs appeared, Neer showed the best results with his total shoulder prosthesis and therefore paved the way for further developments, based on his type II prosthesis with a long anatomical stem and polyethylene glenoid component.

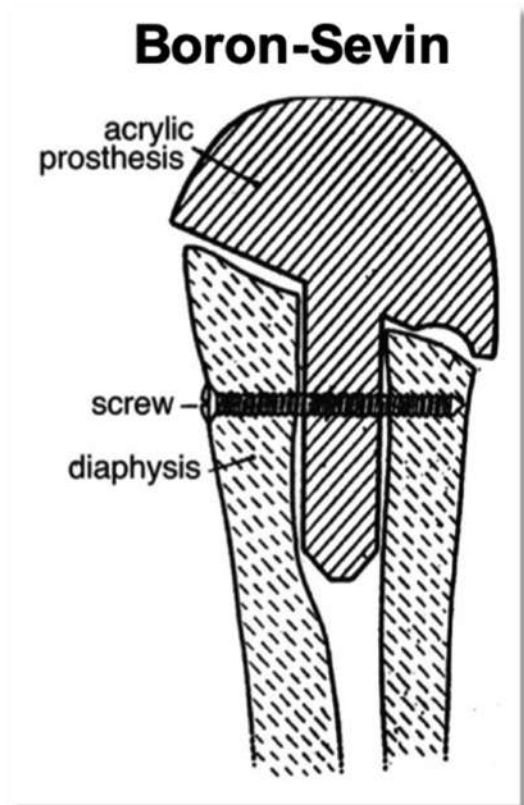


Fig. 2. Borin-Sevin devised an acrylic prosthesis for fractures.

### 1.2. Developments on humeral side

While the Neer II prosthesis was a monoblock stem, in the 1980s modularity was introduced in the second generation, consisting of a stem as well a separate head of several sizes, increasing the variability of the anatomy of shoulder.

Walch and Boileau,<sup>11</sup> based on extensive anatomical studies, showed the wide variety of the anatomy of the proximal humerus, with variation in the retroposition, inclination and offset of the head related to the humeral shaft axis as well as the retrorsion related to the epicondylar axis of the elbow. This led to the development of the third generation, with a wide variety of implants enabling to adapt the prosthesis to the anatomy instead of the earlier designs where the anatomy was adapted to the available prostheses.

Following the trend in hip arthroplasty in the last decades shorter stems were introduced, mainly relying on metaphyseal support.

The first implants in shoulder arthroplasty were made of Vitallium, a Chrome/Cobalt alloy, later on added with Molybdenum for increasing strength. In the 1980s implants of a Titanium/Aluminum/Vanadium were introduced. Presently both alloys are now widely used, either with a smooth surface, where cement is needed for fixation or they are enhanced with a variety of surface modifications, either porous coated or calcium phosphate coating with hydroxyapatite to promote ingrowth in a so-called press fit fixation.

Another development was the introduction of bone preserving implants.




Fig. 3. Neer's first design of a vitallium prosthesis, primarily developed for fractures.

Zipfel<sup>12</sup> was the first surgeon to publish a report in 1975, describing the use of a metallic humeral shell used to resurface the humeral head while articulating with a polyethylene glenoid component. Resurfacing became popular at the end of the twentieth century with good results, largely published by Copeland.<sup>13</sup>

Building on this concept, a 4th generation, stemless implant was evolved, the TESS<sup>14</sup>; for this prosthesis the head is resected and fixation is only in the metaphysis, based on metaphyseal fixation; in some later designs stability is achieved by placing the circumference of the humeral implant on the cortical bone of the neck after resection of the humeral head;

With this type of implant the approach to the glenoid is easier compared to the surface replacement, by still avoiding the stem-related problems. This caused the decline of surface replacement and might probably surpass conventional stemmed arthroplasty in the future.<sup>15</sup>

### 1.3. Developments on glenoid side

Since the introduction of the first glenoid component, designed by Kenmore,<sup>8</sup> composed of UltraHigh Molecular Weight Polyethylene (UHMW PE) this material has shown a long track record.

Since the beginning 2 variations for fixation in the glenoid have evolved, either a keeled or a pegged design.

Despite its durability and rather good wear behavior, long term

wear and its subsequent periprosthetic osteolysis stimulated research to improve this polyethylene, leading to Highly cross linked UHMW PE (HXLPE), created by a radiation and sterilization process. Another development involved the addition of an antioxidant stabilizer, Vitamin E, with the aim to inhibit oxidative degradation.

Cofield<sup>16</sup> in the 80ties was the first to use a metal backed glenoid component with a polyethylene liner. There was a high rate of lucency on the long term. Many other designs have since then emerged, e.g hybrid metal/polyethylene without metal on the glenoid surface.<sup>17</sup>

Another recent development is the inlay design, where the polyethylene component is inserted in the glenoid, leaving its surface flush with the remaining glenoid.

### 1.4. Reverse arthroplasty

Between 1970 and 1973 Neer developed 3 types of a reverse prosthesis, because he had a high failure rate of his anatomic prosthesis in patients with a deficient cuff. The Mark I had a larger ball to allow more motion, but limited the refixation of the cuff. The Mark II had a smaller ball for reattachment of the cuff; the smaller cuff however decreased the range of motion. To improve the excursions the Mark III had again a smaller ball, to allow cuff attachment but an axial rotation element in the humeral stem to facilitate a better motion.

The glenoid implant was cemented. Due to a high failure rate he abandoned further development.

In Europe the first reverse prosthesis was developed by Reeves<sup>18</sup> in 1972 for patients with a deficient cuff. It consisted of a glenoid component with a diverged threaded peg, which was cemented in the glenoid. It had an anatomic center of rotation (Fig. 4).

Since then several constrained prosthesis were described, with a small metallic sphere to reproduce either an anatomic or even lateralized center of rotation.

Gérard<sup>19</sup> (Fig. 5) published in 1973 the early results of a reverse total shoulder prosthesis, with a metal glenoid plate fixed with 2 screws in the scapula and a hole in the center where a 20 mm metal sphere was screwed into the plate. The humeral component consisted of a polyethylene semi-retentive cup fixed on a metal stem. In contrast to the implants from Neer and Reeves, this was the first uncemented glenoid component.

The Kölbl prosthesis was developed for reconstruction after tumour resection. The glenoid component was cemented as well secured with a flange, that was screwed to the base of the scapular spine or the scapular pillar.<sup>20</sup>

Kessel<sup>21</sup> introduced in 1973 a design with a large screw in the glenoid and a polyethylene humeral stem, also creating an

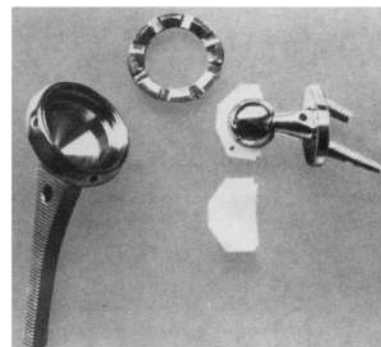


Fig. 4. First reverse prosthesis by Reeves.





Fig. 5. Gérard-Lannelongue reverse prosthesis.

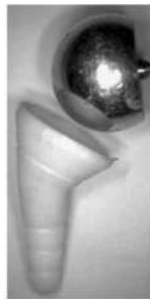

Fig. 6. The "Trompette", Grammont's first design of a medialized reverse, with a polyethylene humeral component and alumina-ceramic 2/3 sphere.

anatomic center of rotation. He published in 1979 on 21 patients with overall good results. Although there were failures, no loosening of the glenoid component was reported. This model was later modified by Bayley and Walker, with the screw coated with hydroxyapatite, the center of rotation was moved medially and distally. The humeral component was changed to metal with a polyethylene retentive liner.

Several other designs were presented:

The Liverpool shoulder was designed in 1969 by Beddow and Elly<sup>22</sup> and was based on a reverse hip prosthesis: the glenoid component and stem were cemented in the scapular pillar, a polyethylene cup was cemented in the proximal humerus. They reported a high failure rate.

Fenlin<sup>23</sup> made a larger polyethylene glenoid sphere articulating with a large cup on a metal stem. He was concerned about the scapular fixation and to overcome this problem he designed a glenoid component with 2 extensions, to be fixed in the most dense cortical bone, namely in the base of the coracoid and the scapular pillar. The deltoid function improved, but there was a high failure rate at long term follow-up. Buechel<sup>24</sup> introduced in 1978 a double mobility cup, facilitating motion between the glenoid sphere and a polyethylene ball, which in turn articulated with the humeral metal cup. The Gristina trispherical system was also a constrained system, including a small humeral metal ball and a small glenoid metal ball, that both articulated with a large, central polyethylene sphere.<sup>25</sup>

### 1.5. Grammont

While all the above implants were not very successful and many abandoned further use, Grammont's design provided a revival of the concept of the "reverse" philosophy: His basic concept was to medialize and lower the center of rotation (COR) compared to the place where it is normally found. The rationale was, that with a medialized COR the deltoid lever arm would be increased, leading to a better function.<sup>26</sup>

His first design in 1985 ("Trompette prosthesis" (Fig. 6), consisted of a two-thirds of an alumina ceramic sphere, which was fixed with cement to the glenoid. Although elevation was at or above




Fig. 7. Contemporary "platform" system, with a stemmed and stemless variant.

100°, loosening was seen. Subsequently he changed the glenosphere to a hemisphere, thus even more medializing the COR. He also changed the fixation, making a baseplate, which was fixed with a central peg and 2 diverging screws, counteracting the shear forces. This led to the first modular prosthesis in 1991, the Delta III, consisting of 5 elements, an uncemented baseplate, a gleno(hemi)sphere, a polyethylene liner, a cemented or uncemented neck and stem.

From the 1990s, the Grammont system was adopted by many shoulder surgeons for the treatment of cuff deficiency, as it was superior to all other systems.

Since the introduction of the reverse prosthesis extensive research has been carried out, to overcome 2 problems of this philosophy: notching and poor rotations. Designs with a more lateralized center of rotation try to solve these problems. Presently more than 25 variations are available on the global market.

## 2. Conclusion

Nearly 130 years passed since the first shoulder prosthesis was implanted. It took a long journey with several interesting designs, but the concepts of Neer for the anatomic prosthesis and of Grammont for the reverse prosthesis were the golden standard and formed the basis for further development.

Presently newer designs offer the possibility to implant an anatomic or reverse prosthesis on the same humeral stem or stemless implant (“platform” systems, Fig. 7).

Newer technologies, like navigation or, as alternative, PSI (patient-specific instrumentation) have increased the accuracy of implanting the prosthesis.

## References

1. Péan JE. Des moyens prothétiques destinés à obtenir la réparation des parties osseuses. *Gaz Hop Paris*. 1894;67:291.
2. Wessinghage D. Themistocles Gluck. 100 years artificial joint replacement. *Z Orthop Ihre Grenzgeb*. 1991;129(5):383–388.
3. Richard A, Judet R, René L. Reconstruction prothétique acrylique de l'extrémité supérieure de l'humérus spécialement au cours des fracturesluxations. *J Chir (Paris)*. 1952;68(8-9):537–547.
4. Borin R, Sevin L. Prothese Acrylique de l'épaule. *Presse Med*. 1951;59:1480.
5. Krueger FJ. A vitallium replica arthroplasty on the shoulder; A case report of aseptic necrosis of the proximal end of the humerus. *Surgery*. 1951;30(6):1005–1011.
6. Neer II CS. Articular replacement for the humeral head. *J Bone Joint Surg Am*. 1955;37-A(2):215–228.
7. Kenmore PI, MacCartee C, Vitek B. A simple shoulder replacement. *J Biomed Mater Res*. 1974;5(4 Pt 2):329–330.
8. Engelbrecht E, Stellbrink G. Total shoulder endoprosthesis design. *St. Georg. Chirurg*. 1976;47(10):525–530.
9. Post M, Haskell SS, Finder JG. Total shoulder replacement. *J Bone Joint Surg*. 1975;57A:1171.
10. Swanson AB, de Groot Swanson G, Maupin BK, Wei JN, Khalil MA. Bipolar implant shoulder Arthroplasty. *Orthopedics*. 1986;9(3):343–351.
11. Boileau P, Walch G. Three-dimensional geometry of the proximal humerus. Implications for surgical technique and prosthetic design. *J Bone Joint Surg Br*. 1997 Sep;79(5):857–865.
12. Zippel J. Luxationssichere schulterendoprothese model BME. *Z Orthop Ihre Grenzgeb*. 1975;113(4):454–457.
13. Levy O, Copeland SA. Cementless surface replacement arthroplasty of the shoulder. 5 to 10-year results with the Copeland mark-2 prosthesis. *J Bone Joint Surg Br*. 2001;83(2):213–221.
14. Huguet D, DeClercq G, Rio B, Teissier J, Zipoli B. Results of a new stemless shoulder prosthesis: radiologic proof of maintained fixation and stability after a minimum of three years' follow-up. *J Shoulder Elbow Surg*. 2010;19(6):847–852.
15. *Small Bone and Joint Devices Market Analysis, Size, Trends | Europe | 2018–2024*. Burnaby, BN, Canada; 2018. <https://idataresearch.com/product/small-bone-and-joint-devices-market-europe/>.
16. Coffield RH, Daly PJ. Total shoulder arthroplasty with a tissue-ingrowth glenoid component. *J Shoulder Elbow Surg*. 1992;1:77–85.
17. Pinkas D, Wiater B, Wiater JM. The glenoid component in anatomic shoulder arthroplasty. *J Am Acad Orthop Surg*. 2015 May;23(5):3127–26.
18. Reeves B, Jobbins B, Flowers F, Dowson D, Wright V. Some problems in the development of a total shoulder endo-prosthesis. *Ann Rheum Dis*. 1972;31(5):425–426.
19. Gérard Y, Leblanc JP, Rousseau B. Une prothèse totale d'épaule. *Chirurgie*. 1973;99(9):655–663.
20. Kölbl R, Friedebold G. Möglichkeiten der alloarthroplastik an der schulter. *Arch Orthop Unfall-Chir*. 1973;76(1):31–39.
21. Kessel L, Bayley I. Prosthetic replacement of shoulder joint: preliminary communication. *J R Soc Med*. 1979;72(10):748–752.
22. Blauth W, Donner K. Zur Geschichte der arthroplastik. *Z Orthop Ihre Grenzgeb*. 1979;117:997–1006.
23. Fenlin JM. Semi-constrained prosthesis for the rotator cuff deficient patient. *Orthop Trans*. 1985;9:55.
24. Buechel FF, Pappas MJ, DePalma AF. Floating-socket™ total shoulder replacement: anatomical, biomechanical, and surgical rationale. *J Biomed Mater Res*. 1978;12(1):89–114.
25. Ungethüm M, Blömer W. Endoprothetischer ersatz des schultergelenks. Möglichkeiten und deren analyse. *Z Orthop Ihre Grenzgeb*. 1986;124(1):50–56.
26. Grammont PM, Baulot E. Delta shoulder prosthesis for rotator cuff rupture. *Orthopedics*. 1993;16(1):65–68.



Contents lists available at ScienceDirect

## Journal of Arthroscopy and Joint Surgery

journal homepage: [www.elsevier.com/locate/jajs](http://www.elsevier.com/locate/jajs)

## Review article

## The biomechanics of reverse shoulder arthroplasty

Sanjeeve Sabharwal<sup>a,\*</sup>, Steve Bale<sup>b</sup><sup>a</sup> Upper Limb Fellow, Wrightington Wigan and Leigh NHS Trust, Wrightington Hospital, Hall Lane, Appley Bridge, Wrightington, Lancashire, WN6 9EP, UK<sup>b</sup> Consultant Orthopaedic Surgeon, Wrightington Wigan and Leigh NHS Trust, Wrightington Hospital, Hall Lane, Appley Bridge, Wrightington, Lancashire, WN6 9EP, UK

## ARTICLE INFO

## Article history:

Received 9 December 2020

Accepted 23 December 2020

Available online 28 December 2020

## Keywords:

Shoulder

Arthroplasty

Biomechanics

Lateralisation

## ABSTRACT

Reverse total shoulder arthroplasty has become an increasingly popular surgical procedure over the last 25 years. Since its initial conception as an implant that would address the limitations of anatomic shoulder arthroplasty in a rotator cuff deficient shoulder, the science behind its design has grown and as a result the implant has evolved rapidly. Numerous reverse shoulder arthroplasty prostheses are currently available with subtle modifications in implants potentially impacting on clinical outcomes. It is important that shoulder surgeons understand the biomechanical principles that drive these design nuances so that implant selection is better informed, and patient outcomes can be optimised. This review article examines the biomechanical principles on which the first prosthesis was based, and further evaluates the development of newer designs and the evidence that supports their application in modern clinical practice.

© 2021 International Society for Knowledge for Surgeons on Arthroscopy and Arthroplasty. Published by Elsevier, a division of RELX India, Pvt. Ltd. All rights reserved.

## 1. Introduction

## 1.1. History of the prosthesis and conventional design principles

The limitations of anatomic shoulder arthroplasty were increasingly apparent as its uptake and application in shoulder surgery increased in the 1970s. Charles Neer reported poorer outcomes amongst his own patients undergoing shoulder arthroplasty when their rotator cuff was deficient.<sup>1</sup> His initial efforts to counter superior migration of the humeral head involved oversized glenoid components with superior overhang, but functional outcomes were poor, and he quickly abandoned this technique.<sup>2</sup> Neer then attempted to address the limitations of conventional prosthesis with constrained designs, with his first prosthesis, the Mark 1, consisting of a large glenosphere articulating with socket on a long humeral stem.<sup>3</sup> The Mark 1 and its subsequent successors, the Mark 2 and 3, were all abandoned because of implant failure and glenoid loosening that occurred because of the large forces generated at the bone-implant surface on the glenoid, which occurred as a result of lateralisation of the shoulder's centre of rotation.<sup>3</sup>

In 1985, Paul Grammont revolutionised shoulder arthroplasty

with a novel reverse design that was based on 4 key concepts: [1] the centre of rotation (COR) must be fixed, medialised and distalised relative to the glenoid's surface [2] the prosthesis must be stable [3] the weight bearing part must be convex and supported by a concave component and [4] the centre of the sphere must be at, or within the glenoid neck.<sup>4</sup> In his initial design, the COR was lateral to the glenoid surface. As a result, the destabilising forces at the bone-implant surface were high and this prosthesis suffered the same fate as Neer's Mark implants. Grammont addressed these problems with his second-generation prosthesis, the Delta III which was released in 1991.<sup>3</sup> He medialised the COR by converting the glenosphere from 2/3 of a sphere to a hemisphere. In addition to the further reduction in shear forces gained by medialising the COR, the baseplate on which the glenosphere sat, had a central peg and two divergent screws which resisted the destabilising forces at the bone-implant surface. The initial Delta III glenosphere was screwed into the baseplate with threaded screws, however this was revised to a Morse taper and a counter sunk screw. Additionally, the humeral component consisted of a small cup covering less than half of the glenosphere with a neck shaft angle of 155°.

## 2. The importance of the centre of rotation

In the native shoulder joint, the COR varies through the arc of movement.<sup>5</sup> Reverse shoulder arthroplasty (RSA), is based on a

\* Corresponding author.

E-mail address: [sanjeeve.sabharwal@ic.ac.uk](mailto:sanjeeve.sabharwal@ic.ac.uk) (S. Sabharwal).



fixed COR within the glenosphere. Medialisation of the COR was key to Grammont's design principle as it facilitated a larger lever arm for the deltoid, allowing the muscle to be effective enough to initiate abduction.<sup>6</sup> The hemispherical design of the glenosphere minimised the shear forces at the bone-implant surface, increased the compressive forces and provided a resultant force vector that further stabilised the implant's fixation at the glenoid.<sup>7</sup> Despite the obvious biomechanical advantages of a medialised COR, the evolution and increasing complexity of RSA design is largely driven by the problems it also creates.

Scapular notching is a well-recognised phenomenon that is thought to occur due to mechanical impingement of the superomedial humerus against the inferior scapular neck during adduction.<sup>6</sup> It is a radiographic finding of an erosive lesion on the axillary border of the glenoid neck.<sup>8</sup> The reported incidence levels are as high as 50%,<sup>9</sup> and although it was long speculated that it would have a detrimental effect on patient outcomes, it is only recent evidence that has demonstrated that it results in poorer clinical outcomes for patients and significantly increased complication rates.<sup>10</sup> Techniques to reduce scapular notching include increasing lateral offset, eccentric positioning of the glenoid, positioning the glenoid baseplate with inferior inclination and decreasing the neck-shaft angle of the humeral component.<sup>6</sup>

Another trade off with a medialised COR is range of motion. A lateralised COR reduces subacromial impingement and effectively increases the abduction range. Gutierrez et al.<sup>11</sup> demonstrated a positive correlation between abduction range of motion and COR offset relative to the glenoid, with a laboratory setting saw-bone model demonstrating approximately 97° of abduction with a COR 10 mm from the glenoid, and 67° with a COR offset 0.5 mm from the glenoid. Loss of range of motion is also seen in rotation, as when still intact, a medialised COR de-tensions the rotator cuff, decreases its moment arm and effectively reduces internal and external rotation of the shoulder.<sup>12</sup> A medialised COR also contributes to reduction in the adduction range of motion and abutment of the polyethylene cup onto the inferior glenoid rim, which results in scapular notching.<sup>6</sup>

Another key problem that has been proposed and demonstrated with a medialised COR is that there is reduced deltoid wrapping.<sup>13</sup> The angle of abduction at which the deltoid wraps around greater tuberosity is used as surrogate measure for joint stability. The higher the angle at which the deltoid stops wrapping around it, the higher the range in abduction that compression is achieved across the joint. Lateralisation of the COR or lateralisation of humeral offset can be used to improve deltoid wrapping and the subsequent joint stability that it contributes to.

### 3. Design nuances

#### 3.1. Eccentric positioning of the glenoid component

The rationale for eccentric (inferior) positioning of the glenoid component is that it can increase the space between the glenosphere and the scapula neck, and therefore potentially reduce scapular notching. This is done while preserving the medialised position of the COR and therefore the biomechanical advantage to the deltoid. Nyffeler et al. demonstrated in their *in vitro* study that placing the glenoid component 2–4 mm more distal to the central point of the glenoid improved abduction and adduction angles and they suggested that therefore this should reduce the risk of scapular notching.<sup>14</sup> In a retrospective series of 147 patients undergoing RSA, Deuthman et al. demonstrated that increased baseplate inferiorisation or increased glenosphere overhang, were independent predictors of reduced risk of scapular notching.<sup>15</sup> To date, the only prospective randomised trial comparing eccentric and concentric

positioning was published in 2014, by Poon et al. in which 50 patients were randomised to either group.<sup>16</sup> Despite laboratory and retrospective evidence suggesting benefits to eccentric position, the authors reported that there were no differences in notching and clinical outcomes between the two groups. By the authors' own admission, this study was limited by a minimum follow up of 2 years, and a longer follow up would have increased the strength of their findings because it is well recognised that scapular notching may develop beyond this period of time.<sup>17</sup> Nevertheless, eccentric positioning of the glenoid remains one of the recommended techniques for avoiding scapular notching and numerous prosthesis designs allow for this with the design of their glenoid component.

#### 3.2. Inferior inclination of glenoid component

Inferior inclination of 10–15° of the glenosphere has often been combined with eccentric positioning with a rationale to improve the adduction range and therefore reduce scapular notching. This rationale was also driven by early laboratory analysis, and in 2008, Gutierrez et al. demonstrated, in a saw bone model, that inferior tilt of 15° resulted in a smaller adduction deficit compared to neutral or a superior tilt of 15°.<sup>18</sup> In a prospective randomised trial that included 42 patients published in 2014, Edwards et al. concluded that at 1-year follow-up, inferior tilt of 10° compared to a neutral position on the glenosphere did not reduce the incidence of scapular notching or affect clinical outcomes.<sup>19</sup> Overall, the benefits of an inferior tilt remain controversial with emerging evidence now suggesting that inferior tilt may actually be problematic in the long term. Patel et al. used a computerised model on CT images to compare glenoid inclination in 20 patients undergoing RSA and found that relative to a neutral position, 10° of inferior tilt resulted in increased scapular neck impingement.<sup>20</sup> They suggested that the likely reason for this was that the medialisation required to seat an inferiorly tilted implant shortened the scapular neck and reduced the distance to the humerus. Further research is clearly required to determine the true effect of inferior inclination as implant designs that accommodate for it are widely available for use.<sup>21</sup>

#### 3.3. Neck-shaft angle

Grammont's Delta III humeral prosthesis had a neck-shaft angle (NSA) of 155° in valgus. This compared to the 135–140° seen in a normal humerus, with the increased valgus angle providing superior stability for the implant in a cuff deficient shoulder.<sup>21</sup> Furthermore, a higher NSA also increases the abduction arc of the prosthesis.<sup>22</sup> Design evolution has been necessary because the almost horizontal orientation of the humeral cup limits the adduction arc and results in scapular notching.<sup>18</sup> Ladermann et al. demonstrated in a computerised model that compared to the traditional Grammont stem, using a prosthesis with an NSA of 135° and 145° led to minimal loss in abduction, and large gains in adduction, extension and external rotation of the shoulder.<sup>22</sup> These range of motion gains can be maintained without compromising abduction by using a humeral prosthesis with a lower NSA and providing some increase in glenoid lateralisation. Werner et al. demonstrated in their computer modelling that an NSA of 135° with 5 mm of glenoid offset was the best combination for impingement free abduction and adduction.<sup>23</sup> The role of the NSA in joint stability has also been investigated and has important implications in implant design. In their cadaveric study, Oh et al. found that with a NSA of 155°, the anterior dislocation force for a shoulder in its most unstable position, internal rotation, was significantly higher than for an NSA of 145 or 135°.<sup>24</sup> The authors proposed that this probably reflected an increased articular contact at the inferior

aspect of the glenosphere with a higher NSA. This view is supported by more recent research in the form of finite element RSA modelling performed by Langohr et al. which demonstrated that decreasing the NSA resulted in decreased contact area and increased contact stress between the glenosphere and humeral cup.<sup>25</sup>

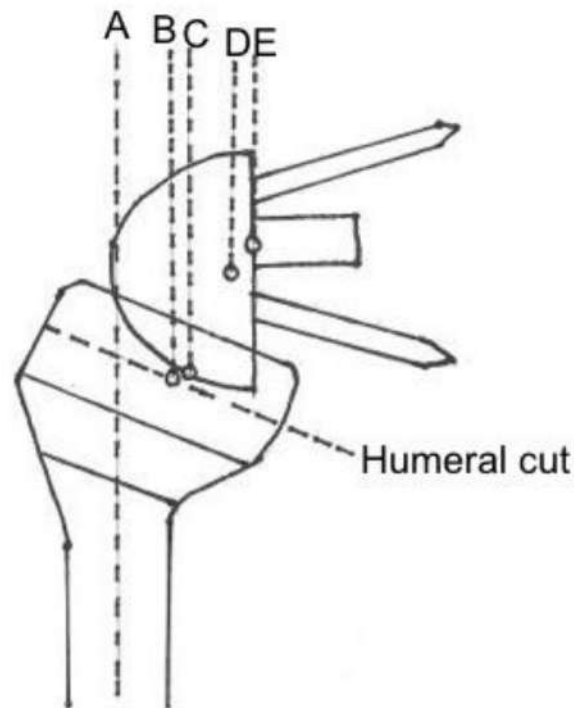
### 3.4. Humeral component version

In a cadaveric study, Berhouet et al. investigated the effect of humeral component version on ROM and inferior scapular impingement.<sup>26</sup> They concluded that increased humeral retroversion resulted in less inferior impingement but no significant gains in ROM. More recently, Konstaxis et al. examined the effects of humeral version in RSA on activities of daily living (ADLs) using computer modelling performed on 30 shoulders.<sup>27</sup> They reported that 0° of version resulted in the least amount of impingement for ADLs and that retroversion was associated with the largest gains in ROM, but retroversion also resulted in increased risk of impingement of the greater tuberosity on the coracoid. Anteversion achieved the smallest overall gains in ROM, with the exception being humeral elevation, and with impingement in an anteverted humeral component most commonly occurring between the greater tuberosity and the acromion. The authors also reflected on research that investigated the effect of version on the moment arm and length of teres minor which indicated that although there was an increased moment arm in retroversion, muscle tension was lost.<sup>28</sup> Based on the overall effect of version on impingement, ROM and teres minor function they suggested that a neutral position may be preferential for most patients.

### 3.5. Lateral offset

Despite the obvious benefits to a medialised COR, because of concerns about scapular notching, its effect on shoulder rotation and loss of shoulder contour, there was an increase in interest and innovation focused on increasing lateral offset. In its primitive design form, increased lateral offset in RSA was delivered by a more spherical glenosphere. The increase in destabilising forces at the bone-implant interface this caused generated concern about whether the benefits of lateralisation outweighed the risks. As knowledge on design biomechanics has grown over the years, an understanding of lateral offset and the different ways it can be achieved has addressed some of the key problems and popularised newer implants that achieve increased lateral offset by modifying implant design on both the humeral and glenoid components of their RSA implants.

Lateral humeral offset in the native glenohumeral joint is defined as the distance between the base of the coracoid and the most lateral point on the greater tuberosity.<sup>29</sup> In 2005, Harman et al. defined lateral offset in RSA as the distance between the baseplate and the centre point of the humeral and glenoid articulation.<sup>30</sup> In 2011, Valenti et al. defined it as the distance between the COR and the greater tuberosity.<sup>31</sup> Werthel et al.'s more recent descriptive analysis of lateral offset provides a comprehensive description of different types of lateral offset in RSA and their definitions provide useful measures that reflect differences in implant design.<sup>32</sup> The authors draw vertical lines through the prosthesis as reference points to measure lateral offset (Fig. 1). Humeral stem offset is defined as a distance between a vertical line passing between the humeral stem (A) and a vertical line passing through the middle of the articular surface of the humeral implant (B). Humeral insert offset is the distance between B and the pivot point, which is the deepest part of the humeral insert (C). Humeral lateral offset (AC) is the distance between A and C, and hence the sum of the stem offset



**Fig. 1.** Definitions of offset in RSA adapted from Werthel et al.<sup>32</sup> Line A passes through the centre of the stem. Line B passes through the middle of the humeral articular surface. Line C passes through the “pivot point”, which is the deepest point in the articular surface. Line D passes through the centre of rotation of the joint. Line E passes through the bone-glenoid interface. AB = Humeral stem offset. BC = Humeral insert offset. AC = Humeral offset. CD = perceived radii of the glenosphere. DE = Centre of rotation offset. CE = Glenoid lateral offset. AE = Global lateral offset.

and the insert offset (AB + BC). On the glenoid side, the distance from C to a line passing through the centre of rotation of the joint (D) is the perceived radius of glenosphere. The centre of rotation offset is the distance between point D and a line passing through the bone-glenoid interface (E). Glenoid lateral offset is the sum of the perceived radius of the glenosphere and the centre of rotation offset (CD + DE). Global lateral offset is the sum of the humeral lateral offset and the glenoid lateral offset (AE). Greater tuberosity lateral offset is the distance from the bone-glenoid interface to the greater tuberosity.

Glenoid lateralisation can be achieved by changing the shape of the glenosphere, lateralising the baseplate or increasing the length of the scapular neck with bone graft.<sup>32</sup> In 2019, Werthel et al.<sup>32</sup> reviewed 28 different configurations with 22 different RSA implants and reported that compared to the Delta III which has a glenoid lateral offset of 9.6 mm, the largest glenoid lateral offset achieved by design of glenosphere and baseplate was 17.9 mm. By limiting an increase in glenoid lateral offset to only 8.3 mm compared to the increase of 21.4 mm in global lateral offset achieved in the most lateralised class of prosthesis, it is clear that modern implant design reflects the concerns of glenoid loosening, and the reduction in deltoid efficiency that could occur as glenoid lateral offset increases. Pascal Boileau developed a novel approach, where he harvested autologous bone graft from the humeral head and incorporated it into a specially designed baseplate with a long central peg.<sup>33</sup> The rationale design of Boileau's bony increased-offset reverse shoulder arthroplasty (BIO-RSA), was that the benefits of lateralisation would be possible without some of the potential drawbacks. Boileau's initial study was prospective evaluation of 42 patients who underwent BIO-RSA. His group

reported that there was a 98% graft incorporation rate with low rates of scapular notching and significant gains in internal rotation at a mean follow up of 28 months.

Another area of interest had been the effect of increasing glenoid size to increase lateralisation. Werthel et al. reported an increase of only 1 mm in global lateral offset when moving from a 36 mm glenosphere to a 42 mm glenosphere.<sup>32</sup> There is some data from cadaveric analysis that impingement free range of motion increases with a larger glenosphere,<sup>26</sup> however the evidence to support increasing glenosphere size to lateralise global offset is lacking and further research is needed to support the application of this principle.

Humeral lateralisation has become increasingly popular, can be achieved in a number of different ways and is utilised more than glenoid lateralisation to achieve greater global lateral offset across the majority of implants on the market.<sup>32</sup> Firstly, while the initial Grammont design had a straight stem, many newer designs are now curved. A curved stem has a number of benefits including preservation of tuberosity and metaphyseal bone stock, preservation of remaining rotator cuff insertion and the option of modularity between anatomic and total shoulder arthroplasty.<sup>22</sup> A curved stem also results in a greater humeral stem offset. Another important design aspect relates to whether the humeral component is embedded in the metaphysis (inlay) or sits above the humeral cut (onlay). Curved stems commonly adopt an onlay system which, which further lateralises the humeral stem by increasing the distance between the centre of the midpoint of the humeral articular surface and the pivot point (the humeral insert offset). There is marginal lateralisation of approximately 3 mm gained with a more varus NSA of 135° compared to 155°, and gains on the humeral side are largely achieved by stem design and the shape of the inlay.<sup>32</sup> Modifications on the humeral side to increase lateralisation improve cuff efficiency, increase impingement free range of motion and reduces the deltoid forces required to initiate abduction relative to glenoid lateralisation.<sup>34–36</sup> Despite these benefits, it is important to recognise some of the drawbacks of excessive humeral lateralisation which has can increase soft tissue tension and the forces generated by the deltoid, potentially resulting in pain and stress fractures of the acromion.<sup>37,38</sup>

The clinical evidence-base to support lateralised RSA over non-lateralised RSA is limited. Non-comparative studies demonstrate that the rate of notching is high and external rotation gains are small after non-lateralised RSA<sup>39</sup> while proponents of lateralised RSA have demonstrated in their patients' lower rates of scapular notching and improved external rotation.<sup>17</sup> In a relatively small randomised trial of 34 patients comparing a lateralised and non-lateralised RSA, Greiner et al. showed external rotation gains in the lateralised group. Although these gains did not reach statistical significance, the population studied was small and their findings are limited by the potential of type II error.<sup>40</sup> With regards to long term outcomes Kennon et al. compared a glenoid lateralised and non-lateralised implant in a group of 100 patients, and found that at 10 year follow up there as no significant difference in complications or re-operations, but marginal gains in forward elevation with higher scapular notching rates in the non-lateralised group.<sup>41</sup> Further clinical research is needed to demonstrate the role of lateralisation in patient outcomes, and analysis of joint registry data may be an important way to study these outcomes in the future.

#### 4. Stability of the prosthesis

Instability after RSA is a well-recognised complication and although its incidence is highly variable across the literature, a review of articles published between 2005 and 2015 stated that the overall incidence was approximately 5%.<sup>42</sup> It is important to

consider the factors that contribute to increased stability in order to address the risk of dislocation. Gutierrez et al. performed a laboratory analysis on 8 RSA implants to investigate the hierarchy of factors affecting stability in RSA.<sup>43</sup> They found that the most important factors affecting stability were the compressive forces acting on the prosthesis, followed by the prosthetic socket depth, with the size of the glenosphere contributing very little.

In a cuff deficient shoulder that has undergone RSA, the joint compressive forces are related to soft tissue tensioning. Soft tissue tension can be modified using a variety of surgical techniques and prosthesis factors (Table 1).<sup>44</sup> With a medialised COR, the vector pull of the deltoid is no longer in line with the humerus and this can act as a distracting force contributing to instability.<sup>45</sup> Lengthening the humerus by retaining more proximal humerus or using a larger humeral insert can address this issue, however it does carry the risk of acromion stress fracture, loss of motion and brachial plexopathy.<sup>44</sup> Lateralising the offset of the implant will also reduce the distracting vector from the deltoid, however to date there is limited evidence demonstrating a reduction in post-operative instability achieved using a lateralised RSA implant. Matthewson et al. performed a meta-analysis of seven studies including 1306 patients undergoing RSA. The study reported that there was a reduction in dislocation risk when the subscapularis was repaired in both lateralised and medialised RSA designs, but when subscapularis was not repaired there was a reduced risk of dislocation in the lateralised RSA implants.<sup>46</sup>

From a biomechanical perspective, the importance of prosthetic socket depth can be explained using the balance stability angle (Fig. 2). This is the maximum angle that the net force on the humeral head forms with the glenoid centre line before dislocation occurs.<sup>47</sup> In an anatomic shoulder replacement this angle is approximately 30° which reflects instability derived from an unequal curvature of radii and limited constraint.<sup>6</sup> With RSA, the equal radii of curvature and increased constraint from the more conforming humeral articular surface, which prevents glenohumeral translation, results in increased stability. The RSA design is able to tolerate a joint reaction force factor of up to 45°<sup>47</sup> making it more inherently more stable, but limiting impingement free range of motion compared to an anatomic shoulder replacement. Therefore, using a deeper socket to increase stability is an option within the surgical armamentarium, but the trade-off to this is a reduction in ROM.<sup>43</sup>

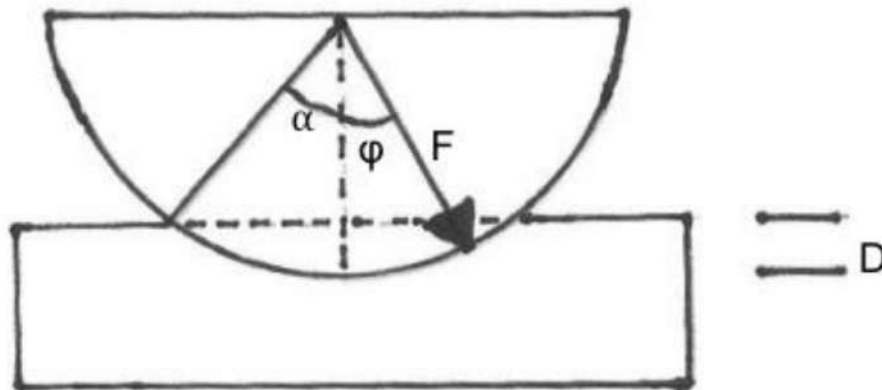
Joint stability is also affected by the position of the arm. When the glenohumeral joint in an RSA is in 90° of abduction, it is between 2 and 3 times more stable than its anatomical counterpart.<sup>48</sup> In adduction, despite the design factors that contribute to constraint, there has been general consensus that there is an increased risk on instability and this is due to inferior impingement which can generate a levering effect.<sup>6</sup> This can be addressed by eccentric positioning of the glenoid and lateralising the implant design.<sup>43</sup> In the long term, further clinical research will be important to determine how instability is affected by the variation in

**Table 1**

Factors that help restore soft tissue tension in RSA (adopted from Walker et al. <sup>44</sup>).

<b>Implant Factors</b>
Increasing glenosphere size and use of an eccentric glenoid
Use of a valgus neck shaft angle of humeral prosthesis
Thickness of humeral insert
Use of a lateral offset glenosphere
<b>Surgical Factors</b>
Changing the level of the humeral osteotomy
Place the glenoid in a more inferior position
Changing the offset of the humeral socket
Placement of glenoid with inferior tilt





**Fig. 2.** Balance stability angle ( $\alpha$ ) is the maximal angle that the net joint force ( $F$ ) can form with the concavity before dislocation occurs. The joint remains stable as long as  $\phi < \alpha$ . In RSA the  $\alpha$  is equal to  $45^\circ$ . Adapted from Berliner et al.<sup>6</sup>

implant design and the expanding indications for the use of RSA.

## 5. Deltoid function

The effect of a medialised COR on deltoid efficiency forms the core tenet of the Grammont RSA design, and deltoid function is an important part of the biomechanical principles for the prosthesis. In the native shoulder, the anterior deltoid is predominantly a flexor, the middle deltoid is an abductor and the posterior deltoid is largely an extensor.<sup>6</sup> When the COR is medialised with RSA, a larger part of the anterior and posterior deltoid is recruited and all 3 component parts of the deltoid act primarily as abductors.<sup>6</sup> Cadaveric research has demonstrated that the moment arm in all 3 sub-regions of the deltoid is increased in RSA thereby reducing the force required to initiate shoulder abduction.<sup>49</sup> The improvement in deltoid function translates into improved abduction range following RSA for rotator cuff arthropathy seen in a number of clinical studies.<sup>50</sup> These abduction gains do come at cost, and as the posterior deltoid sub-region is recruited to become an abductor, it loses its external rotation moment arm which results in the external rotation deficit commonly observed after RSA.<sup>44</sup> This is further exacerbated by the loss of tension on the residual posterior cuff. It is also important to consider effect of prior shoulder surgery on deltoid function, specifically the anterior deltoid. Schawatz et al. performed a cadaveric study assessing the functional role of the deltoid sub-regions on function.<sup>51</sup> They concluded that the anterior deltoid is crucial for balanced function and loss of the anterior deltoid may disrupt balanced abduction. The authors recommended surgeons should exercise caution when considering RSA in patients in whom there was loss of function within the anterior deltoid.

## 6. Conclusion

The evolution of RSA design since Paul's Grammont's first prosthesis, has been driven by the application of increasing knowledge of implant biomechanics as well as the growth in indications for RSA in shoulder surgery. Modern implants offer increased modularity to offset some of the drawbacks of a medialised COR such as limitation in ROM, while trying to preserve deltoid function and reduce the risk of design related complications. It is important that shoulder surgeons understand the biomechanical principals of RSA to better inform their decision making in implant selection. It is also crucial to determine the clinical benefits of many of the principals that inform design

variability, as much of scientific evidence remains laboratory-based analysis, with limited long-term data demonstrating improvement in patient outcomes.

## Contribution of authors to this review article

Steve Bale is the senior author of this review article. He was invited by the editorial board to submit an article on the biomechanics of reverse shoulder arthroplasty. He contributed to the design and editing of this manuscript. Sanjeev Sabharwal wrote the manuscript and contributed to the editing.

## Funding

There was no funding received for the writing of this review article.

## References

1. Neer 2nd CS, Watson KC, Stanton FJ. Recent experience in total shoulder replacement. *J Bone Joint Surg Am.* 1982;64(3):319–337.
2. Neer CS. *Shoulder Reconstruction.* Philadelphia: Saunders; 1990.
3. Flatow EL, Harrison AK. A history of reverse total shoulder arthroplasty. *Clin Orthop Relat Res.* 2011;469(9):2432–2439.
4. Grammont PTP, Laffay J, Deries X. Study and production of a new shoulder prosthesis. *Rhumatologie.* 1987;39:17–22.
5. Poppen NK, Walker PS. Normal and abnormal motion of the shoulder. *J Bone Joint Surg Am.* 1976;58(2):195–201.
6. Berliner JL, Regalado-Magdos A, Ma CB, Feeley BT. Biomechanics of reverse total shoulder arthroplasty. *J Shoulder Elbow Surg.* 2015;24(1):150–160.
7. Kontaxis A, Johnson GR. The biomechanics of reverse anatomy shoulder replacement—a modelling study. *Clin Biomech.* 2009;24(3):254–260.
8. Friedman RJ, Barcel DA, Eichinger JK. Scapular notching in reverse total shoulder arthroplasty. *J Am Acad Orthop Surg.* 2019;27(6):200–209.
9. Alentorn-Geli E, Samitier G, Torrens C, Wright TW. Reverse shoulder arthroplasty. Part 2: systematic review of reoperations, revisions, problems, and complications. *Int J Shoulder Surg.* 2015;9(2):60–67.
10. Mollon B, Mahure SA, Roche CP, Zuckerman JD. Impact of scapular notching on clinical outcomes after reverse total shoulder arthroplasty: an analysis of 476 shoulders. *J Shoulder Elbow Surg.* 2017;26(7):1253–1261.
11. Gutierrez S, Levy JC, Lee 3rd WE, Keller TS, Maitland ME. Center of rotation affects abduction range of motion of reverse shoulder arthroplasty. *Clin Orthop Relat Res.* 2007;458:78–82.
12. Hamilton MA, Roche CP, Diep P, Flurin PH, Routman HD. Effect of prosthesis design on muscle length and moment arms in reverse total shoulder arthroplasty. *Bull Hosp Jt Dis.* 2013;71(Suppl 2):S31–S35, 2013.
13. Roche CP, Diep P, Hamilton M, et al. Impact of inferior glenoid tilt, humeral retroversion, bone grafting, and design parameters on muscle length and deltoid wrapping in reverse shoulder arthroplasty. *Bull Hosp Jt Dis.* 2013;71(4):284–293, 2013.
14. Nyffeler RW, Werner CM, Gerber C. Biomechanical relevance of glenoid component positioning in the reverse Delta III total shoulder prosthesis. *J Shoulder Elbow Surg.* 2005;14(5):524–528.
15. Duethman NC, Aibinder WR, Nguyen NTV, Sanchez-Sotelo J. The influence of

- glenoid component position on scapular notching: a detailed radiographic analysis at midterm follow-up. *JSES Int.* 2020;4(1):144–150.
16. Poon PC, Chou J, Young SW, Astley T. A comparison of concentric and eccentric glenospheres in reverse shoulder arthroplasty: a randomized controlled trial. *J Bone Joint Surg Am.* 2014;96(16):e138.
  17. Cuff D, Clark R, Pupello D, Frankle M. Reverse shoulder arthroplasty for the treatment of rotator cuff deficiency: a concise follow-up, at a minimum of five years, of a previous report. *J Bone Joint Surg Am.* 2012;94(21):1996–2000.
  18. Gutierrez S, Comiskey CA, Luo ZP, Pupello DR, Frankle MA. Range of impingement-free abduction and adduction deficit after reverse shoulder arthroplasty. Hierarchy of surgical and implant-design-related factors. *J Bone Joint Surg Am.* 2008;90(12):2606–2615.
  19. Edwards TB, Trappey GJ, Riley C, O'Connor DP, Elkousy HA, Gartsman GM. Inferior tilt of the glenoid component does not decrease scapular notching in reverse shoulder arthroplasty: results of a prospective randomized study. *J Shoulder Elbow Surg.* 2012;21(5):641–646.
  20. Patel M, Martin JR, Campbell DH, Fernandes RR, Amini MH. Inferior tilt of the glenoid leads to medialization and increases impingement on the scapular neck in reverse shoulder arthroplasty. *J Shoulder Elbow Surg.* Oct 15 2020. <https://doi.org/10.1016/j.jse.2020.09.023>.
  21. Rugg CM, Coughlan MJ, Lansdown DA. Reverse total shoulder arthroplasty: biomechanics and indications. *Curr Rev Musculoskelet Med.* 2019;12(4):542–553.
  22. Ladermann A, Denard PJ, Boileau P, et al. Effect of humeral stem design on humeral position and range of motion in reverse shoulder arthroplasty. *Int Orthop.* 2015;39(11):2205–2213.
  23. Werner BS, Chaoui J, Walch G. The influence of humeral neck shaft angle and glenoid lateralization on range of motion in reverse shoulder arthroplasty. *J Shoulder Elbow Surg.* 2017;26(10):1726–1731.
  24. Oh JH, Shin SJ, McGarry MH, Scott JH, Heckmann N, Lee TQ. Biomechanical effects of humeral neck-shaft angle and subscapularis integrity in reverse total shoulder arthroplasty. *J Shoulder Elbow Surg.* 2014;23(8):1091–1098.
  25. Langohr GD, Willing R, Medley JB, Athwal GS, Johnson JA. Contact mechanics of reverse total shoulder arthroplasty during abduction: the effect of neck-shaft angle, humeral cup depth, and glenosphere diameter. *J Shoulder Elbow Surg.* 2016;25(4):589–597.
  26. Berhouet J, Garaud P, Favard L. Evaluation of the role of glenosphere design and humeral component retroversion in avoiding scapular notching during reverse shoulder arthroplasty. *J Shoulder Elbow Surg.* 2014;23(2):151–158.
  27. Kontaxis A, Chen X, Berhouet J, et al. Humeral version in reverse shoulder arthroplasty affects impingement in activities of daily living. *J Shoulder Elbow Surg.* 2017;26(6):1073–1082.
  28. Berton A, Gulotta LV, Petrillo S, et al. The effect of humeral version on teres minor muscle moment arm, length, and impingement in reverse shoulder arthroplasty during activities of daily living. *J Shoulder Elbow Surg.* 2015;24(4):578–586.
  29. Iannotti JP, Gabriel JP, Schneck SL, Evans BG, Misra S. The normal glenohumeral relationships. An anatomical study of one hundred and forty shoulders. *J Bone Joint Surg Am.* 1992;74(4):491–500.
  30. Harman M, Frankle M, Vasey M, Banks S. Initial glenoid component fixation in "reverse" total shoulder arthroplasty: a biomechanical evaluation. *J Shoulder Elbow Surg.* 2005;14(1 suppl S), 162S–7S.
  31. Valenti P, Sauzieres P, Katz D, Kalouche I, Kilinc AS. Do less medialized reverse shoulder prostheses increase motion and reduce notching? *Clin Orthop Relat Res.* 2011;469(9):2550–2557.
  32. Werthel JD, Walch G, Vegehan E, Deransart P, Sanchez-Sotelo J, Valenti P. Lateralization in reverse shoulder arthroplasty: a descriptive analysis of different implants in current practice. *Int Orthop.* 2019;43(10):2349–2360.
  33. Boileau P, Moineau G, Roussanne Y, O'Shea K. Bony increased-offset reversed shoulder arthroplasty: minimizing scapular impingement while maximizing glenoid fixation. *Clin Orthop Relat Res.* 2011;469(9):2558–2567.
  34. Franceschetti E, de Sanctis EG, Ranieri R, Palumbo A, Paciotti M, Franceschi F. The role of the subscapularis tendon in a lateralized reverse total shoulder arthroplasty: repair versus nonrepair. *Int Orthop.* 2019;43(11):2579–2586.
  35. Giles JW, Langohr GD, Johnson JA, Athwal GS. Implant design variations in reverse total shoulder arthroplasty influence the required deltoid force and resultant joint load. *Clin Orthop Relat Res.* 2015;473(11):3615–3626.
  36. Merolla G, Walch G, Ascione F, et al. Grammont humeral design versus only curved-stem reverse shoulder arthroplasty: comparison of clinical and radiographic outcomes with minimum 2-year follow-up. *J Shoulder Elbow Surg.* 2018;27(4):701–710.
  37. Sheth U, Saltzman M. Reverse total shoulder arthroplasty: implant design considerations. *Curr Rev Musculoskelet Med.* 2019;12(4):554–561.
  38. Chan K, Langohr GD, Mahaffy M, Johnson JA, Athwal GS. Does humeral component lateralization in reverse shoulder arthroplasty affect rotator cuff torque? Evaluation in a cadaver model. *Clin Orthop Relat Res.* 2017;475(10):2564–2571.
  39. Sirveaux F, Favard L, Oudet D, Huquet D, Walch G, Mole D. Grammont inverted total shoulder arthroplasty in the treatment of glenohumeral osteoarthritis with massive rupture of the cuff. Results of a multicentre study of 80 shoulders. *J Bone Joint Surg Br.* 2004;86(3):388–395.
  40. Greiner S, Schmidt C, Herrmann S, Pauly S, Perka C. Clinical performance of lateralized versus non-lateralized reverse shoulder arthroplasty: a prospective randomized study. *J Shoulder Elbow Surg.* 2015;24(9):1397–1404.
  41. Kennon JC, Songy C, Bartels D, et al. Primary reverse shoulder arthroplasty: how did medialized and glenoid-based lateralized style prostheses compare at 10 years? *J Shoulder Elbow Surg.* 2020;29(7S):S23–S31.
  42. Bohsali KI, Bois AJ, Wirth MA. Complications of shoulder arthroplasty. *J Bone Joint Surg Am.* 2017;99(3):256–269.
  43. Gutierrez S, Keller TS, Levy JC, Lee 3rd WE, Luo ZP. Hierarchy of stability factors in reverse shoulder arthroplasty. *Clin Orthop Relat Res.* 2008;466(3):670–676.
  44. Walker M, Brooks J, Willis M, Frankle M. How reverse shoulder arthroplasty works. *Clin Orthop Relat Res.* 2011;469(9):2440–2451.
  45. Boileau P, Watkinson DJ, Hatzidakis AM, Balg F. Grammont reverse prosthesis: design, rationale, and biomechanics. *J Shoulder Elbow Surg.* 2005;14(1 suppl S), 147S–61S.
  46. Matthewson G, Kooner S, Kwapisz A, Leiter J, Old J, MacDonald P. The effect of subscapularis repair on dislocation rates in reverse shoulder arthroplasty: a meta-analysis and systematic review. *J Shoulder Elbow Surg.* 2019;28(5):989–997.
  47. Matsen 3rd FA, Boileau P, Walch G, Gerber C, Bicknell RT. The reverse total shoulder arthroplasty. *J Bone Joint Surg Am.* 2007;89(3):660–667.
  48. Favre P, Sussmann PS, Gerber C. The effect of component positioning on intrinsic stability of the reverse shoulder arthroplasty. *J Shoulder Elbow Surg.* 2010;19(4):550–556.
  49. Ackland DC, Roshan-Zamir S, Richardson M, Pandey MG. Moment arms of the shoulder musculature after reverse total shoulder arthroplasty. *J Bone Joint Surg Am.* 2010;92(5):1221–1230.
  50. Samitier G, Alentorn-Geli E, Torrens C, Wright TW. Reverse shoulder arthroplasty. Part 1: systematic review of clinical and functional outcomes. *Int J Shoulder Surg.* 2015;9(1):24–31.
  51. Schwartz DG, Kang SH, Lynch TS, et al. The anterior deltoid's importance in reverse shoulder arthroplasty: a cadaveric biomechanical study. *J Shoulder Elbow Surg.* 2013;22(3):357–364.



Contents lists available at ScienceDirect

## Journal of Arthroscopy and Joint Surgery

journal homepage: [www.elsevier.com/locate/jajs](http://www.elsevier.com/locate/jajs)

## Review article

## Surface Replacement of the Shoulder - a Commentary

Sanjay S. Desai\*, Bharat Sharma

Shoulder and Knee Clinic, 11A Satguru, 16 French Bridge, Off Hughes Road, Mumbai, 400007, Maharashtra, India



## ARTICLE INFO

## Article history:

Received 26 January 2021

Accepted 30 January 2021

Available online 5 February 2021

## Keywords:

Shoulder

Surface

Hemi arthroplasty

Total arthroplasty

## ABSTRACT

The gain in popularity of shoulder arthroplasty in the last three decades has been dramatic. The rate of increase in shoulder arthroplasty is three to five times compared to total hip replacement and total knee replacement respectively. The debate between surface replacement arthroplasty and conventional shoulder arthroplasty has been long standing with no clear winner. Bone preservation, ease of replicating anatomy, low complications and the comfort of relatively simplified revision surgery are some of the distinct advantages of SRA over stemmed arthroplasty. In the medium term follow up of surface replacement hemi arthroplasty, glenoid pain is minimal and in a small percentage of cases. In the long term, the choice between revising an eroded glenoid versus a loose glenoid plastic with associated bone destruction, will be a decision that the surgeon will have to take along with the patient. In our view, shoulder surface replacement hemi arthroplasty is an attractive option in the young arthritic shoulder. © 2021 International Society for Knowledge for Surgeons on Arthroscopy and Arthroplasty. Published by Elsevier, a division of RELX India, Pvt. Ltd. All rights reserved.

Anatomic shoulder arthroplasty is the procedure of choice for end stage arthritis of the glenohumeral joint with intact rotator cuff. Aim of any arthroplasty surgery is to reduce pain and improve function, with return to near normal life. Shoulder resurfacing is an attractive concept because it preserves the humeral head, unlike the conventional stemmed humeral implant which sacrifices the head.

First shoulder replacement was done by a French surgeon Jules Emile Pean in 1893 to cure proximal humerus tuberculosis. In 1950's Neer took this development further and laid the foundation of modern shoulder arthroplasty.<sup>1</sup> Neer designed humerus prosthesis to deal with proximal humerus fracture. Zippel in 1975, first described the humerus resurfacing with polyethylene glenoid.<sup>2</sup> Concept of surface replacement arthroplasty (SRA) of shoulder came from early work done for hip resurfacing surgeries.<sup>3</sup> Modern orthopaedic trends changed from more conventional techniques to minimally invasive, more anatomic and bone preserving surgeries specially in young, high demand patients who may need revision in future. Copeland *et al*<sup>4</sup> popularised resurfacing shoulder arthroplasty in 1980's and did serial improvement in the earlier designs. They emphasised on replacing only the damaged cartilage with bone conservation. MARK-1 prosthesis constitutes central pegged

humerus with a screw which is fixed to lateral cortex of humerus and polyethylene fixed peg glenoid component. Later screw from humerus was eliminated because it was not providing any benefit. In 1990 MARK-2 prosthesis was developed with metal backing to glenoid and fluted taper fit peg to humerus for additional stability. Three years later HA coating was added (MARK-3) for better fixation of the implant.<sup>4,5</sup> With addition of HA coating they showed increase bone integration and reduce loosening.

A study of National Inpatient Sample (NIS) data, revealed increasing rate of shoulder arthroplasty being 103.7% between 2011 and 2017, compared to THA and TKA with increasing rates of 29.1% and 17.8% respectively.<sup>6</sup> The rise in numbers further necessitates improving functional results, reducing complications and making revision simpler.

Indications and contraindications for SRA remains same as stemmed anatomic shoulder arthroplasty. SRA is possible with humeral head collapse up to 40%.<sup>5,7</sup> Both SRA and stemmed anatomic are not advisable in B2 and C glenoid. The main argument against resurfacing hemiarthroplasty in comparison to total shoulder replacement is the glenoid erosion and the pain associated with hemi-replacement. Those not in favour of resurfacing arthroplasty argue about the difficulty in resurfacing the glenoid due to limited access with an intact head. The counter argument is that current status of glenoid longevity in stemmed total shoulder arthroplasty is about 13 years.<sup>8</sup> Hence in the long term, one needs to choose between dealing with an untouched glenoid erosion versus a loose glenoid implant with bone loss.

\* Corresponding author.

E-mail addresses: [drdesaisanjay@gmail.com](mailto:drdesaisanjay@gmail.com) (S.S. Desai), [bharatkashyap08@gmail.com](mailto:bharatkashyap08@gmail.com) (B. Sharma).



Copeland in his study<sup>4</sup> of 103 shoulders with a follow-up of 6.8 years reported Constant score of 93.7% for total SRA and 73.5% in hemi SRA. Best results were seen with primary osteoarthritis. Poor results were seen in rotator cuff arthropathy and post traumatic arthritis. Eight shoulders (7.7%) required revision surgery, of which only two were revised due to primary loosening. They concluded that results of SRA is comparable to stemmed shoulder arthroplasty.

In another study by Levy and Copeland of 79 shoulders with primary OA, 37 were treated with hemi SRA and 42 were treated with total SRA. At an average follow-up of 7.6 years, 89.9% were satisfied with the outcome. Four revisions were performed in the total SRA group and none required revision in the hemi SRA group. The results of hemi and total SRA were comparable.<sup>5</sup>

Levy in his study<sup>9</sup> of patients younger than fifty years old with a mean follow-up of 14.5 years showed excellent results after SRA in 42 shoulders. Seventeen SRA were done with metallic glenoid component and 37 were hemi SRA with microfracture of glenoid. The improvement in pain and function was maintained more than 10 years after surgery. They concluded that SRA offers a valuable tool in treating young patients with glenohumeral arthritis, providing reasonable good long-term results in 81.6% of patients while preserving bone stock in case revision surgery is required.<sup>9,10</sup>

Raiss in his study of 35 patients with three years of mean follow up found 94% satisfaction rate after total SRA and significant difference between pre and postoperative Constant score.<sup>11</sup> There were no component loosening although radiolucent lines were seen in 88% glenoid component, superior migration of humerus was noted in 14% cases but it was mild and three patients sustained neurological complications out of which two recovered completely. Neurologic complications are attributed to difficult exposure of glenoid in total RSA.

James Pritchett, published long term results (mean follow-up of 28 years) of 74 shoulders, in which total SRA was performed in 41 shoulders and hemi SRA was performed in 33 shoulders.<sup>12</sup> He reported 95% satisfaction rate, 96% survivorship of humerus component, 92% patients had no limitation in movements and 39% patients were involved in sports and strenuous activities. Twelve out of 38 radiographic analysis of glenoid showed loosening but only three required revision surgery and two humeral components showed loosening, of which one was an old design with screw and one was implanted on a deficient bone stock. Patient satisfaction and functional outcome were same in the total RSA and hemi RSA group. Six patient out of seven revision surgeries were happy with their results.

Buchner in his matched pair analysis of 44 patients compared the outcome of hemi SRA and stemmed total shoulder arthroplasty (TSA).<sup>13</sup> Twenty two patients received hemi SRA and 22 received TSA. They found decreased surgical time, minimum blood loss, less technical difficulties and reduced postoperative stay in hemi SRA as compared to TSA. Constant score, mobility, abduction and flexion at one year follow up was better in TSA group as compared to hemi SRA. However on subjective assessment there was no significant difference between the two.

Mitchell Fourman in his midterm follow up studies found hemi SRA better than stemmed hemiarthroplasty in terms of pain relief and functional scores but no significant difference in complications and range of motion.<sup>14</sup> They suggested that better functional score and pain relief in hemi SRA group is due to better restoration of anatomy, decreased postoperative adhesive capsulitis rate due to less tissue damage and decreased tension on rotator cuff in hemi SRA.

Bailie in his study<sup>15</sup> of 36 patients, less than 55 years of age in a short term follow up who underwent humerus resurfacing concluded that 97% patients were satisfied with the procedure.

They found that 30 out of 36 patients returned to their earlier activity level and they also participated in sports like heavy weight lifting, hockey tennis, golf, basketball and one patient started bobsleigh in Olympics. Two patients with B 1 type glenoid showed earlier progressive signs of glenoid wear resulting in biconcave glenoid (type B 2), there were no radiological signs of loosening in any patient.

Nicholas Iagulli in his study of 48 patients younger than 60 years showed promising outcomes in a mid-term follow up.<sup>16</sup> He found 94% satisfaction rate in patients treated with hemi SRA. Forty five out of 48 patients (94%) resumed their previous activities including labour, weight lifting, golf, tennis, hunting, even gymnast and water skiing. Rate of glenoid erosion was only 2%, which was attributed to proper patient selection and restoration of native anatomy with resurfacing humerus arthroplasty.

Our own experience is similar to that elaborated in the above quoted literature.<sup>17</sup> As compared to a stemmed hemiarthroplasty, hemi SRA is a relatively simpler bone preserving procedure, easier to replicate the anatomy, with less blood loss and complications. In all the cases where stemmed replacement is performed, SRA is also possible, except in cases with extensive collapse of the humeral head. In the medium term, pain due to glenoid bone erosion is occasional and acceptable. In the long term when revision may be required, the surgeon has to decide whether he or she prefers operating on an eroded but untouched glenoid bone versus the difficulties of revising a loose glenoid plastic with associated osteolysis.

## 1. Conclusion

Hemi SRA is certainly relevant and in fact an attractive, valuable option when dealing with glenohumeral arthritis in young, active patients with high demand. It is bone preserving, less invasive with fewer complications and provides the comfort of revision surgery, if required in the long term.

## Contribution

Sanjay S. Desai: Concept, idea and final editing. Bharat Sharma: Literature search and writing.

## Declaration of competing interest

None.

## References

1. Neer CS, Brown Jr TH, Mclaughlin HL. Fracture of the neck of the humerus with dislocation of the head fragment. *Am J Surg*. 1953 Mar;85(3):252–258. [https://doi.org/10.1016/0002-9610\(53\)90606-0](https://doi.org/10.1016/0002-9610(53)90606-0). PMID: 13030924.
2. Zilber S. Shoulder arthroplasty: historical considerations. *Open Orthop J*. 2017;11:1100–1107. <https://doi.org/10.2174/1874325001711011100>.
3. Widnall JC, Dheerendra SK, Macfarlane RJ, Waseem M. The use of shoulder hemiarthroplasty and humeral head resurfacing: a review of current concepts. *Open Orthop J*. 2013;7:334–337. <https://doi.org/10.2174/1874325001307010334>.
4. Levy O, Copeland SA. Cementless surface replacement arthroplasty of the shoulder. 5- to 10-year results with the Copeland mark-2 prosthesis. *J Bone Joint Surg Br*. 2001;83(2):213–221. <https://doi.org/10.1302/0301-620x.83b2.11238>.
5. Levy O, Copeland SA. Cementless surface replacement arthroplasty (Copeland CSRA) for osteoarthritis of the shoulder. *J Shoulder Elbow Surg*. 2004;13(3):266–271. <https://doi.org/10.1016/j.jse.2004.01.005>.
6. Wagner ER, Farley KX, Higgins I, Wilson JM, Daly CA, Gottschalk MB. The incidence of shoulder arthroplasty: rise and future projections compared with hip and knee arthroplasty. *J Shoulder Elbow Surg*. 2020;29(12):2601–2609. <https://doi.org/10.1016/j.jse.2020.03.049>.
7. Burgess DL, McGrath MS, Bonutti PM, Marker DR, Delanois RE, Mont MA. Shoulder resurfacing. *J Bone Joint Surg Am*. 2009;91(5):1228–1238. <https://doi.org/10.2106/JBJS.H.01082>.

8. Gauci M, Meijden O Van Der, Lavoue, et al. Total shoulder arthroplasty in patients younger than 60 years: results of the nice multicentre study. In: Boileau P, ed. *Shoulder Concepts-Arthroplasty for the Young Arthritic Shoulder*. Sauramps Medical; 2018:155–161.
9. Levy O, Tsvieli O, Merchant J, et al. Surface replacement arthroplasty for glenohumeral arthropathy in patients aged younger than fifty years: results after a minimum ten-year follow-up. *J Shoulder Elbow Surg*. 2015;24(7):1049–1060. <https://doi.org/10.1016/j.jse.2014.11.035>.
10. Levy O, Funk L, Sforza G, Copeland SA. Copeland surface replacement arthroplasty of the shoulder in rheumatoid arthritis. *J Bone Joint Surg Am*. 2004;86(3):512–518. <https://doi.org/10.2106/00004623-200403000-00008>.
11. Raiss P, Weiter M, Sowa B, Zeifang F, Loew M. Results of cementless humeral head resurfacing with cemented glenoid components. *Int Orthop*. 2015;39(2):277–284. <https://doi.org/10.1007/s00264-014-2540-6>.
12. Pritchett JW. Long-term results and patient satisfaction after shoulder resurfacing. *J Shoulder Elbow Surg*. 2011;20(5):771–777. <https://doi.org/10.1016/j.jse.2010.08.014>.
13. Buchner M, Eschbach N, Loew M. Comparison of the short-term functional results after surface replacement and total shoulder arthroplasty for osteoarthritis of the shoulder: a matched-pair analysis. *Arch Orthop Trauma Surg*. 2008;128(4):347–354. <https://doi.org/10.1007/s00402-007-0404-x>.
14. Fourman MS, Beck A, Gasbarro G, Irrgang JJ, Rodosky MW, Lin A. Humeral head resurfacing is associated with less pain and clinically equivalent functional outcomes compared with stemmed hemiarthroplasty at mid-term follow-up. *Knee Surg Sports Traumatol Arthrosc*. 2019;27(10):3203–3211. <https://doi.org/10.1007/s00167-019-05382-w>.
15. Bailie DS, Llinas PJ, Ellenbecker TS. Cementless humeral resurfacing arthroplasty in active patients less than fifty-five years of age. *J Bone Joint Surg Am*. 2008;90(1):110–117. <https://doi.org/10.2106/JBJS.F.01552>.
16. Iagulli ND, Field LD, Hobgood ER, et al. Surface replacement arthroplasty of the humeral head in young, active patients: midterm results. *Orthop J Sports Med*. 2014;2(1). <https://doi.org/10.1177/2325967113519407>, 2325967113519407. Published 2014 Jan 21.
17. Desai SS, Mittal A. Midterm results of surface replacement of the shoulder. *J. Arthrosc. Jt. Surg*. 2017;4(3):110–114. <https://doi.org/10.1016/j.jajs.2017.10.001>.



Contents lists available at ScienceDirect

## Journal of Arthroscopy and Joint Surgery

journal homepage: [www.elsevier.com/locate/jajs](http://www.elsevier.com/locate/jajs)

Review article

## Shoulder Arthroplasty - Optimising Outcome

Wallwork Nicholas Alexander

Orthopaedic Division, Sportsmed.SA, Adelaide, South Australia, Australia



## ARTICLE INFO

## Article history:

Received 1 December 2020

Accepted 30 January 2021

Available online 6 February 2021

## Keywords:

Shoulder  
Arthroplasty  
Review  
Planning

## ABSTRACT

Shoulder arthroplasty is an increasingly commonly performed procedure that achieves excellent functional outcomes and ameliorates pain in the majority. In preparing for a shoulder arthroplasty it is vital that the surgeon makes assessment of a number of factors. These factors are discussed and as to which of these determine the outcome. There are patient specific factors, such as the degree of joint and soft tissue damage, the presence of bone loss, the type of arthritis present and any co-morbidities. The type of prosthesis selected also can influence outcome. The surgical technique and ongoing care and rehabilitation considerations will affect the patient satisfaction. The planning for surgery is enhanced by the use of imaging and technology.

© 2021 International Society for Knowledge for Surgeons on Arthroscopy and Arthroplasty. Published by Elsevier, a division of RELX India, Pvt. Ltd. All rights reserved.

## 1. Introduction

Shoulder arthroplasty surgery has increased in utilization dramatically over the last decade. In Australia the rate increases by 5% per year and has risen 187% between 2008 and 2019.<sup>1</sup> The utilization of reverse total shoulder arthroplasty (RTSA) has increased at a much faster rate, as it also has expanded the indications for arthroplasty. In Denmark there has been a 10 fold increase in use of RTSA and it is anticipated that this rate will continue to multiply by 3–7 times by 2030.<sup>2</sup>

The surgery is anticipated to alleviate pain and to restore function to the joint that is compromised by a number of different pathologies. All studies show high rates of success and good outcomes but it is evident that there are some individuals who experience a less satisfactory result.<sup>3</sup>

We review the scientific evidence of those cases that had an unsatisfactory outcome in order to improve our current surgical outcomes.

Pre operative assessment planning and preparation involves a number of steps that can enhance surgical experience, improve patient satisfaction and provide enhanced long-term implant survival.

In preparation for successful shoulder arthroplasty it is important to identify factors that are modifiable. From a patient perspective the cessation of smoking has a significant benefit in outcome.<sup>4</sup> Whereas the effect of obesity on outcome and function is

a less significant determinant.<sup>1</sup>

## 2. Outcome assessment

Outcome is assessed against a number of metrics, the clinical assessment of patients is frequently used as a measure of outcome and validated tests such as the Constant- Murley<sup>5</sup> score or ASES<sup>6</sup> utilize a combination of objective and subjective tests. Common factors in clinical assessment are the levels of pain and the amount of motion achieved. This data is then used for statistical analysis.

In assessing outcomes for arthroplasty revision surgery has been used by joint registries world wide as a clinical indicator.<sup>1</sup> This represents a defined and easily reported point and can be used as a comparator in populations or large numbers of patients. This data provides national and international guidance for prosthesis performance. However, on an individual patient or surgeon level due to the low volume of surgeries performed using this data can often create a skewed perspective.

Some registries are now expanding their role to include patient related outcome measures to provide better clarity on the performance of arthroplasty.<sup>7</sup> The level of patient satisfaction may not directly correlate with other measures and can display a bimodal distribution in outcomes with the majority extremely satisfied and a further peak extremely unsatisfied. This later group of patients may have dissatisfaction and an unsuccessful outcome due to infection, rotator cuff secondary failure, glenoid implant loosening, instability or fracture. Each of these factors will be considered in detail.

E-mail address: [nick.wallwork@sportsmed.com.au](mailto:nick.wallwork@sportsmed.com.au).



### 3. Infection

Infection is associated with all surgery however the impacts for a prosthetic replacement often result in revision surgery, compromised outcome and significant financial cost.<sup>8</sup> Infection can be regarded as a potentially preventable event. It is clearly shown that the infection rates vary across countries, hospitals and individual surgeon's practices.<sup>9</sup> The rate of infection can be reduced by undertaking best-practice with a system wide approach to reducing the risk. On an institutional level, hospitals that adhere to high standards of monitoring and clinical surveillance such as mandatory hand hygiene protocols have documented lower rates of infection.<sup>10</sup>

The operating room environment needs to be controlled with reduced cross air flow and the limiting personnel in the theatre have shown to reduce infection.<sup>11</sup>

The surgical team's level of experience,<sup>12</sup> and the duration of surgery are also factors that can be optimized to further reduce infection.<sup>13</sup>

Male sex is associated with a higher rate of infection and unsatisfactory outcomes<sup>14</sup> and the reasons for this are not entirely clear. But it is noted that males carry a higher level of colonization with cutibacterium acnes and a number of strategies are available to screen and decolonize patients for pathogenic bacteria prior to surgery.<sup>15</sup>

The appropriate and rational utilization of prophylactic antibiotics needs to be determined for an individual surgeon's patient population.

### 4. Rotator cuff dysfunction

The rotator cuff and specifically the subscapularis tendon provide the stability of a conventional shoulder replacement as well as the function of the joint. The persisting dysfunction of the rotator cuff is a frequent cause of unsatisfactory outcome from surgery and is the highest reported cause for revision surgery.<sup>1,14,16</sup>

The pre-operative clinical assessment of the rotator cuff is compromised by a restricted range of motion and pain inhibition. It is also not possible to determine clinically, what the rotator function will be after surgery by alone ensuring tendon integrity.

Radiological assessment by CT scan or MRI can be performed and looks at factors such as humeral head superior migration, tendon integrity and muscle wasting. The analysis of fatty infiltration<sup>17</sup> as a proportion of the respective muscle has become a standard for assessment of the rotator cuff. This has been used to assess the suitability and likely success for rotator cuff repair as well as implied functional assessment when deciding between conventional and reverse arthroplasty prosthesis.

It is evident from registry data that many surgeons are increasingly electing to avoid rotator cuff complications and need for revision surgery by selecting a RTSA.<sup>1</sup> Rotator cuff tears and dysfunction increase with incidence with age and females have a higher rate of revision surgery for rotator cuff failure.<sup>16</sup> Hence it would seem appropriate that in current clinical practice females aged over 75 have a higher rate of RTSA.

The described surgical approach for shoulder arthroplasty includes multiple options to address the subscapularis. This includes performing a tenotomy, taking an osteotomy or techniques to preserve the attachment. Similarly, there are varied techniques for repair and reattachment of the subscapularis. However a number of comparison studies have failed to document an advantage of any one technique over another.<sup>18</sup>

The selection of an anatomically appropriate sized implant restores the optimum tendon functional length and biomechanically a prosthesis that is too small will result in a reduced range of

motion and poor strength, whereas an oversized prosthesis tensions the rotator cuff and predisposes to pain and failure.

The implant size can be estimated accurately by pre-operative templating with X-rays and CT scans and at the time of surgery by assessing the size of bone resection.

The intra-operative technique for clinical assessment of correct size, utilizes a combination of described bony landmarks and soft tissue tension tests. These include that the articular head of the prosthesis is no more than 5 mm over the level of the greater tuberosity, the translation of the trialed joint should be up to 50% of the head diameter or 15 mm, the shoulder achieves 40° of external rotation without tension on the subscapularis repair and allow for 60° of internal rotation.

#### 4.1. Glenoid loosening and failure

Glenoid component loosening is a frequent cause for conventional shoulder arthroplasty failure in registry data analysis,<sup>1</sup> literature reviews<sup>19</sup>, case series in France<sup>20</sup> and insurance data in the USA.<sup>21</sup> The rate increases with the longevity of the prosthesis. The causes of early glenoid failure are multifactorial but achieving a well supported stable implant in neutral version improves survivorship.<sup>20</sup> This is critical for a conventional total shoulder arthroplasty, but the RTSA is more tolerant of variations in version. The rate of aseptic loosening is higher for uncemented implants.<sup>1</sup>

Glenoid version can be measured on X-Rays<sup>22</sup> and is much improved by CT methods.<sup>23</sup> It is found by determining a perpendicular to the plane of the scapula and measuring the angle between it and the glenoid articular surface. A normal anatomic variation exists and an increased trend for retroversion leads to a predisposition for osteoarthritis. In osteoarthritis progressive articular wear predominates over the posterior glenoid resulting in defined patterns of bone loss.<sup>24</sup>

Implantation of a glenoid component in as little as 10–15° of retroversion will lead to increased edge loading biomechanically<sup>25</sup> and can lead to early failure.<sup>26</sup> The failure rate increases with increasing deformity.<sup>27</sup>

Hence for the longevity of the prosthesis it is essential that the glenoid version is corrected accurately at the time of surgery. For preoperative planning the routine use of CT and 3 D modeling software allows the surgeon to develop a plan. This process alone can improve the accuracy of implantation<sup>28</sup> and is further enhanced by the use of intra-operative guides or patient specific instrumentation<sup>28, 29</sup> This improvement in targeting to correct version is even more significant for less experienced surgeons.<sup>30</sup>

Whilst discussing the varied techniques for correction of glenoid bone defects is beyond the scope of this article it is worth noting that preference for a RTSA maybe appropriate. As in a RTSA there is a greater tolerance for persisting retroversion<sup>31</sup> and corrective bone grafts beneath a baseplate have a very high rate of union.<sup>32</sup>

In RTSA inferior glenoid progressive bone loss and notching can be seen in up to 93% of cases at 10 years for earlier prosthetic designs.<sup>33</sup> This has been correlated with a worse outcome on functional scores and specifically with forward flexion and abduction.<sup>34,35</sup> The accurate positioning of the glenosphere with accentuated inferior inclination and translation to create inferior overhang reduces the rate of notching and improves the range of internal rotation.

Glenoid component wear is an important consideration to prevent aseptic loosening in arthroplasty. The selection of an implant that utilizes highly crosslinked poly-ethylene has an advantage in laboratory studies.<sup>36</sup>

## 5. Instability

Prosthetic instability is frequently described as a common cause for revision and is the outcome of the previously discussed complication of rotator cuff failure, can be due to poor implant sizing and glenoid asymmetric wear. It also includes episodes of prosthesis dissociation, which are implant specific but do increase in frequency as the complexity and modularity of the prosthesis increases. Prosthesis selection to minimize revision surgery is improved by critical analysis of population data by registries.<sup>1</sup>

In RTSA instability can occur in the early post-operative period and is more common in cases of fracture, inflammatory arthritis, or in the presence of humeral bone loss. RTSA instability occurs more frequently if the implant is inserted without anatomic retroversion. Late instability is due to implant wear and assumed progressive loss in tone and function of the deltoid.<sup>33</sup> Current implant design aim to improve stability by increasing the glenoid offset and providing relatively larger size glenospheres.

The rehabilitation from shoulder arthroplasty needs to protect the shoulder from early instability and damaging the subscapularis repair. This requires the shoulder to be restricted in external rotation range and also to avoid being loaded in extension and adduction. Many of the published protocols for rehabilitation need to be improved by qualitative research as they are descriptive in nature and are not based on outcome data.<sup>37</sup>

## 6. Fracture

Periprosthetic fractures of the humerus requiring revision occurs in approximately 0.6%–3% of all shoulder arthroplasties undertaken in the US.<sup>38</sup> The overall incidence is likely to be higher as some do not require revision surgery. The risk of fracture increases with increasing age. To reduce the risk of fracture a smaller diameter and shorter stem can be used and the clinical data supports this as a safe option.<sup>39</sup> The rate of revision surgery for humeral loosening alone is very low and this appears to be similar between cemented and cementless implants.<sup>1</sup>

Acromial stress fractures occur in 4% of RTSA<sup>40</sup> and whilst these fractures do not require revision surgery they result in persisting pain and a compromised range of motion. These fractures have a higher incidence in females with associated osteoporosis and decreased pre-operative range of motion and the prosthesis is sited more medially and distally.

## 7. Conclusions

In planning for a successful arthroplasty it is important to assess the patient and determine what functional outcome is anticipated and set realistic expectations for recovery.

The patient assessment will encourage optimization of health for surgery including the cessation of smoking, addressing anaemia and taking skin swabs for commensal organism determination.

Preoperative screening investigation includes a CT scan and possibly an MRI scan. This allows selection for either a conventional arthroplasty or RTSA, due to the assessment of the rotator cuff integrity and quality as well as the degree of bony deformity.

The utilization of 3-D planning software has a proven advantage in determining the best position to site the implants. This demonstrates the need for the correction of glenoid version and the degree of inclination. The sizing of the implants and the selection of adjuvant techniques or augments can be made. This can be developed into patient specific guides to facilitate surgery.

Surgical outcomes are enhanced by performing surgery with an experienced team in a facility that performs higher volumes of arthroplasty and has robust infection control practices.

The prosthesis selected should have appropriate modularity to facilitate anatomic restoration but have limited complexity. The data on long term outcomes for individual prostheses are available in unbiased registry reports and the selection of a high performing implant is essential.

The implant selected for conventional arthroplasty needs to replicate the geometry and size of the humeral head and have a cemented glenoid component supported in neutral version. For RTSA the position of the glenosphere requires inferior inclination and overhang but it is important not to be too medialised or inferiorly placed. The humeral stem should be as short as possible to preserve bone stock and placed in anatomic retroversion.

Adhering to these planning and preparation practices, which are evidence based should result in improved outcomes, whether they be determined by revision rate, clinical assessment tools or by patient satisfaction.

## References

1. Australian Orthopaedic Association National Joint Replacement Registry. *Hip, Knee and Shoulder Arthroplasty: 2019 Annual Report*. 2019.
2. Padegimas Eric, Maltenfort Mitchell, Lazarus Mark, et al. Future patient demand for shoulder arthroplasty by younger patients: national projections. *Clin Orthop*. 2015;473(6):1860–1867.
3. Somerson JS, Hsu JE, Neradilek MB, Matsen 3rd FA. Response to weber and McFarland regarding: "analysis of 4063 complications of shoulder arthroplasty reported to the US food and drug administration from 2012 to 2016. *J Shoulder Elbow Surg*. 2020;29(8):e322–e323.
4. Schwartz AM, Farley KX, Boden SH, et al. The use of tobacco is a modifiable risk factor for poor outcomes and readmissions after shoulder arthroplasty. *Bone Joint Lett J*. 2020;1–6.
5. Constant C, Murley A. A clinical method of functional assessment of the shoulder. *Clin Orthop*. 1987;214:160–164.
6. Richards RR, An KN, Lu Bigliani, et al. A standardized method for the assessment of shoulder function. *J Shoulder Elbow Surg*. 1994;3:347–352.
7. Grassi A, Golinelli D, Tedesco D, et al. Patient related outcome measures (PROMS) after elective hip, knee shoulder arthroplasty. *BMC Musculoskel Disord*. 2019;20(1):374.
8. Glen MD, FRCS, Dunbar, Michael, MD, FRCS, PhD, FCAHS Lethbridge Lynn, Richardson C. Total cost of surgical site infection in the two years following primary knee replacement surgery. *Infect Control Hosp Epidemiol*. 2020;41(8):938–942.
9. Segreti J, Parvizi J, Berbari E, Ricks P, Berrios-Torres SI. Introduction to the centers for disease control and prevention and healthcare infection control practices advisory committee guideline for prevention of surgical site infection: prosthetic joint arthroplasty section. *Surgery*. 2017;18:394–400. *Infect*.
10. Lehtimäki K, Rasmussen JV, Mokka J, et al. Risk and risk factors for revision after primary reverse shoulder arthroplasty for cuff tear arthropathy and osteoarthritis: a Nordic Arthroplasty Register Association study. *J Shoulder Elbow Surg*. 2018;27:1596–1601.
11. Richards J, Inacio MC, Beckett M, et al. Patient and procedure-specific risk factors for deep infection after primary shoulder arthroplasty. *Clin Orthop Relat Res*. 2014;472:2809–2815.
12. Brown JS, Gordon RJ, Peng Y, Hatton A, Page RS, Macgroarty KA. Lower operating volume in shoulder arthroplasty is associated with increased revision rates in the early postoperative period: long-term analysis from the Australian Orthopaedic Association National Joint Replacement Registry. *J Shoulder Elbow Surg*. 2020;29(6):1104–1114.
13. Swindell HW, Alrabaa RG, Boddapati V, Trofa DP, Jobin CM, Levine WN. Is surgical duration associated with postoperative complications in primary shoulder arthroplasty? *J Shoulder Elbow Surg*. 2020;29(4):807–813.
14. Hsu JE. CORR insights R: what factors are associated with revision or worse patient-reported outcomes after reverse shoulder arthroplasty for cuff-tear arthropathy? A study from the Danish shoulder arthroplasty registry. *Clin Orthop*. 2020;478(5):1098–1100.
15. MacNiven Ian, MBBCh BAO, Hsu Jason, Neradilek Moni, Matsen Frederick. Preoperative skin-surface cultures can help to predict the presence of propionibacterium in shoulder arthroplasty wounds. *JBJS Open Access*. 2018;3(1), e0052.
16. Gauci MO, Cavalier M, Gonzalez JF, et al. Revision of failed shoulder arthroplasty: epidemiology, etiology, and surgical options. *J Shoulder Elbow Surg*. 2020;29(3):541–549.
17. Somerson Jeremy, Hsu Jason, Gorbaty Jacob, Gee Albert. Classifications in brief: goutallier classification of fatty infiltration of the rotator cuff musculature. *Clin Orthop*. 2016;474(5):1328–1332.
18. Lapner P, Pollock JW, Zhang T, et al. A randomized controlled trial comparing subscapularis tenotomy with peel in anatomic shoulder arthroplasty. *J Shoulder Elbow Surg*. 2020;29(2):225–234.
19. Papadonikolakis Anastasios, Neradilek Moni, Matsen Frederick. Failure of the

- glenoid component in anatomic total shoulder arthroplasty: a systematic review of the English-language literature between 2006 and 2012. *J Bone Joint Surg Am.* 2013;95(24):2205–2212.
20. Knowles NK, Columbus MP, Wegmann K, Ferreira LM, Athwal GS. Revision shoulder arthroplasty: a systematic review and comparison of North American vs. European outcomes and complications. *J Shoulder Elbow Surg.* 2020;29(5):1071–1082.
  21. Dillon MT, Ake CF, Burke MF, et al. The Kaiser Permanente shoulder arthroplasty registry: results from 6,336 primary shoulder arthroplasties. *Acta Orthop.* 2015;86(3):286–292.
  22. Friedman RJ, Hawthorne KB, Genez BM. The use of computerized tomography in the measurement of glenoid version. *J Bone Joint Surg Am.* 1992;74(7):1032–1037.
  23. Iannotti JP, Walker K, Rodriguez E, Patterson TE, Jun BJ, Ricchetti ET. Accuracy of 3-dimensional planning, implant templating, and patient-specific instrumentation in anatomic total shoulder arthroplasty. *J Bone Joint Surg Am.* 2019;101(5):446–457.
  24. Walch G, Badet R, Boulahia A, Khoury A. Morphologic study of the glenoid in primary glenohumeral osteoarthritis. *J Arthroplasty.* 1999;14(6):756–760.
  25. Shapiro TA, McGarry MH, Gupta R, Lee YS, Lee TQ. Biomechanical effects of glenoid retroversion in total shoulder arthroplasty. *J Shoulder Elbow Surg.* 2007;16(3 Suppl):S90–S95.
  26. Farron A, Terrier A, Buchler P. Risks of loosening of a prosthetic glenoid implanted in retroversion. *J Shoulder Elbow Surg.* 2006;15(4):521–526. <https://doi.org/10.1016/j.jse.2005.10.003>.
  27. Walch G, Moraga C, Young A, Castellanos-Rosas J. Results of anatomic non-constrained prosthesis in primary osteoarthritis with biconcave glenoid. *J Shoulder Elbow Surg.* 2012;21(11):1526–1533.
  28. Min KS, Fox HM, Bedi A, Walch G, Warner JJP. Patient-specific planning in shoulder arthroplasty. *Bone Joint Lett J.* 2020;102-B(3):365–370.
  29. Nashikkar PS, Scholes CJ, Haber MD. Computer navigation re-creates planned glenoid placement and reduces correction variability in total shoulder arthroplasty: an in vivo case-control study. *J Shoulder Elbow Surg.* 2019;28(12):e398–e409.
  30. Jacquot A, Gauci MO, Chaoui J, et al. Proper benefit of a three dimensional pre-operative planning software for glenoid component positioning in total shoulder arthroplasty. *Int Orthop.* 2018;42(12):2897–2906.
  31. Collin P, Herve A, Walch G, Boileau P, Muniandy M, Chelli M. Mid-term results of reverse shoulder arthroplasty for glenohumeral osteoarthritis with posterior glenoid deficiency and humeral subluxation. *J Shoulder Elbow Surg.* 2019;28(10):2023–2030.
  32. Paul RA, Maldonado-Rodriguez N, Docter S, et al. Glenoid bone grafting in primary reverse total shoulder arthroplasty: a systematic review. *J Shoulder Elbow Surg.* 2019;28(12):2447–2456.
  33. Bacle G, Nove-Josserand L, Garaud P, Walch G. Long-term outcomes of reverse total shoulder arthroplasty: a follow-up of a previous study. *J Bone Joint Surg Am.* 2017;99(6):454–461.
  34. Jang YH, Lee JH, Kim SH. Effect of scapular notching on clinical outcomes after reverse total shoulder arthroplasty. *Bone Joint Lett J.* 2020;102-B(11):1438–1445.
  35. Simovitch R, Flurin PH, Wright TW, Zuckerman JD, Roche C. Impact of scapular notching on reverse total shoulder arthroplasty midterm outcomes: 5-year minimum follow-up. *J Shoulder Elbow Surg.* 2019;28(12):2301–2307.
  36. Alexander JJ, Bell SN, Coghlan J, Lerf R, Dallmann F. The effect of vitamin E-enhanced cross-linked polyethylene on wear in shoulder arthroplasty—a wear simulator study. *J Shoulder Elbow Surg.* 2019;28(9):1771–1778.
  37. Bullock GS, Garrigues GE, Ledbetter L, Kennedy J. A systematic review of proposed rehabilitation guidelines following anatomic and reverse shoulder arthroplasty. *J Orthop Sports Phys Ther.* 2019;49(5):337–346.
  38. Canton G, Fazzari F, Fattori R, Ratti C, Murena L. Post-operative periprosthetic humeral fractures after reverse shoulder arthroplasty: a review of the literature. *Acta Bio-Med Ateneo Parmense.* 2019;90(12-S):8–13.
  39. Leonidou A, Virani S, Buckle C, Yeoh C, Relwani J. Reverse shoulder arthroplasty with a cementless short metaphyseal humeral prosthesis without a stem: survivorship, early to mid-term clinical and radiological outcomes in a prospective study from an independent centre. *Eur J Orthop Surg Traumatol.* 2020;30(1):89–96.
  40. Zmistowski B, Gutman M, Horvath Y, Abboud JA, Williams Jr GR, Namdari S. Acromial stress fracture following reverse total shoulder arthroplasty: incidence and predictors. *J Shoulder Elbow Surg.* 2020;29(4):799–806.





## Review article

## Shoulder arthroplasty - Which stem?

Peadar Antaine Mac Suibhne, MB, BCh, BAO, MCh, MRCS, Specialist Registrar, etc.<sup>a</sup>,  
Cormac Kelly<sup>b, \*</sup>



<sup>a</sup> MRCS, Specialist Registrar, The Robert Jones and Agnes Hunt Orthopaedic Hospital, Oswestry, Shropshire, SY10 7AB, UK

<sup>b</sup> FRCSI, FRCSEd Orth, Consultant Orthopaedic Surgeon, The Robert Jones and Agnes Hunt Orthopaedic Hospital, Oswestry, Shropshire, SY10 7AB, UK

## ARTICLE INFO

## Article history:

Available online 5 February 2021

## 1. Introduction

Shoulder arthroplasty has gone through a variety of design alterations since its inception in the 1880s with ivory endoprostheses implanted by Themistocles Gluck and the first formally credited shoulder arthroplasty by Jules Emile Péan in 1893.<sup>1</sup> In more recent decades the demand for shoulder arthroplasty has continued to increase and with this demand has come more technological improvements. The modern popularity of shoulder arthroplasty did not take hold until the 1950s when Charles Neer published a case series of hemi-arthroplasties in the management of proximal humerus fractures.<sup>2</sup> The implant design consisted of a monoblock stemmed humeral implant without any glenoid resurfacing. Two decades later Neer further published promising results relating to patient satisfaction following shoulder arthroplasty for glenohumeral osteoarthritis (OA).<sup>3</sup> This was followed by the realisation of the importance of the integrity of the rotator cuff in anatomic arthroplasty success as demonstrated by proximal migration of the humeral head in cuff deficient patients.<sup>4</sup> In the years that followed further design changes and various iterations of constraints led to what is now the conventional reverse total shoulder arthroplasty (rTSA) based around Grammont's principles in 1985.<sup>4</sup> Anatomic and reverse shoulder arthroplasty was built on the traditional model of lower limb arthroplasty with an intramedullary stem to support the humeral head arthroplasty.

The need for a stemmed implant is well established in arthroplasty surgery especially hip and knee but the necessity in shoulder arthroplasty was questioned by several surgeons including Steve Copeland in the 1980s.<sup>5</sup> He began implanting humeral head surface replacements in 1986 and by 1993 his design had evolved to

include a hydroxyapatite coating. Results showing comparable outcomes to stemmed implants were published in 2003.<sup>5</sup> With further evolution of implant designs came the recognition of associated complications of each design.<sup>4</sup> However, access to the glenoid was compromised when the humeral head was not removed and one answer came with the introduction of the Total Evolution Shoulder System [TESS] from Biomet (Biomet; Warsaw, Indiana) in 2004. This was the first of so called "stemless" design and since then many more comparable implants have been released with variation in implant length and fixation design. All implants and evolving designs share common goals: improved implant survivorship, easier revision if required with preserved bone stock and improved clinical outcome and patient satisfaction. Terminology can be confusing as some implants have been referred to "short stem" or "stemless" at different times or in different publications. In this article we use the term "stemless" designs to refer to implants that do not extend their fixation beyond the metaphysis and have finned or caged designs.

## 2. Anatomical considerations

We now have a good understanding of the original anatomy being replaced and the variation across a population. A humeral head radius range of between 22 mm and 25 mm has been described with an arc of 150°. The centre of rotation of the proximal humerus is determined by considering it spherical in morphology whilst the entire articular surface is more ellipsoid in dimensions.<sup>6–9</sup> Thus, most humeral head implants have a spherical shape with the thickness of the head related to the section of the sphere. Some implants vary the head thickness while maintaining the same radius of curvature. The position of the humeral head relative to the humeral shaft was seen to be critical by some authors<sup>8</sup> and was adopted in many 3rd generation designs. The centre of rotation of the humeral head has been shown to lie between

\* Corresponding author.

E-mail address: [cormac.kelly@nhs.net](mailto:cormac.kelly@nhs.net) (C. Kelly).

5 mm and 11 mm medial and 1 mm–5 mm posterior to the shaft in its offset. Head inclination and thickness are approximately 40° to 45° and 15 mm–20 mm respectively relative to the anatomical neck axis with native version of 18° to 25° retroverted. The range however has been shown to be from 5° anteverted to 60° retroverted.<sup>6,7,9</sup> The relative relationship between the humeral head and shaft leads to difficulties when stemmed implants are used. Even in more modular “third generation” implants allowing integrated offset adjustment the position of the head remains dependent upon the proximal humeral shaft with stemmed implants whether short or standard length. So true stemless implants may offer the best alternative for reproducing anatomy providing they are inserted correctly.

### 3. Introduction of varied stems

At present there are a variety of implants available and these can be categorised as standard-stemmed, short-stemmed, resurfacing implants and stemless implants.

There are benefits and disadvantages with each both for patients and surgeons. Standard length stemmed implants were the first to be used by Neer in the treatment of proximal humerus fractures in the form of a monoblock construct. More modern implants typically come in modular form allowing more variation and customisation to accommodate an individual patient's anatomy including offset, neck/shaft inclination, height and even in some implants, version. The fixation can be further cemented or uncemented, each offering benefits and restrictions. Press-fit implants are dependent upon satisfactory bone stock particularly in metaphyseal-fix implants and are also more restricted by patient anatomy – narrow canals, post-traumatic deformity. Relative indications for standard-stemmed implants include proximal humeral bone loss, poor proximal bone stock or a wide intra-medullary canal. If bone stock proximally is extremely poor a standard length stem with diaphyseal fixation is most appropriate.<sup>10</sup> Many surgeons consider the gold standard to be stemmed designs.

### 4. Stemmed implants: Cemented vs. Uncemented

Cemented implantation allows for some of these issues of abnormal anatomy to be overcome with improved implant position and version.<sup>11</sup> Cement also allows some further impregnation with antibiotics in an effort to reduce peri-prosthetic infection, albeit that only short-term follow-up studies have shown benefit of this.<sup>12</sup> Cemented implants were also found to be superior to their uncemented counterparts in long-term follow-up with patients reporting a better quality of life and objectively improved forward flexion.<sup>11</sup> When comparing cemented and uncemented implants regardless of stem length, uncemented implants were also found to be more likely to require revision, however this was further noted to be due to glenoid related issues rather than humeral problems. Male gender, younger age and post-traumatic arthritis also seemed to have an effect, although to a lesser extent.<sup>11</sup> Cementing implants may better distribute stresses to cortical bone and lessen proximal stress shielding. However, the technique come with some undesired effects including cement toxicity, bone stock loss from reaming and more difficult revision due to cement removal. Cement pressurisation is thought to be important for fixation and this may be more difficult in shorter stemmed implants where the stem tip ends in the widened metaphyseal-diaphyseal junction.

Coating of uncemented implants varies and some implants avoid fixation distally by using polished surfaces in an effort to avoid distal fixation with proximal stress shielding (see Fig. 1). We are not aware of publications which support or refute this model.

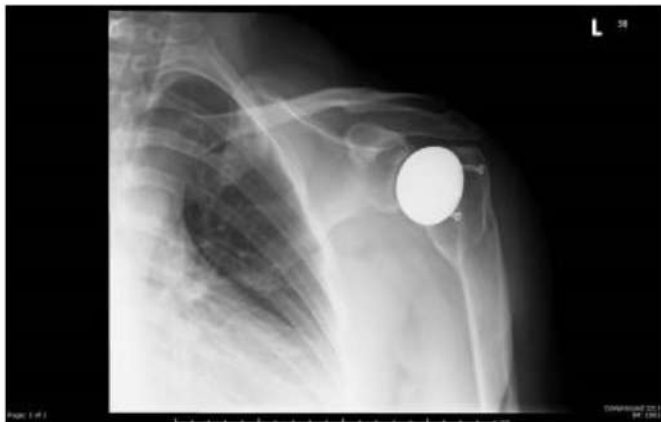

Fig. 1. A stemmed implant with proximal coating (with permission Mathys, Bettlach, Switzerland).

### 5. Resurfacing implants

Preservation of proximal bone stock led to the emergence of resurfacing implants. These are designed to replace the surface of the humeral head while maintaining the humeral head bone stock. The aim of such devices is to replace the arthritic joint surface whilst restoring normal anatomy, while avoiding diaphyseal fixation. Version, inclination, and off-set restoration are all possible through a press-fit design. The theoretical benefits of resurfacing implants are similar to those quoted with stemless implants, including humeral component placement independent of diaphyseal morphology and easy, accurate implantation. Revision is also simplified without stem removal or excessive bone excision. Young patients with increased activity and concentric glenoids are ideal candidates for such surface replacement hemiarthroplasty implants<sup>5,13</sup>(see Fig. 2). Less favourable outcomes are expected if used in certain patients including those with significant humeral head bone loss in excess of 40%, deformity secondary to trauma and considerable glenoid wear.<sup>13</sup>

The majority of surface replacement implanted were hemiarthroplasty at a time when the benefit of total arthroplasty was questioned. The increased enthusiasm for total arthroplasty in the past 15 years and the impaired glenoid exposure with resurfacing implants has added to the trend towards stemless implants that involve a humeral head osteotomy, particularly in patients with significant glenoid wear. Furthermore, anatomical restoration

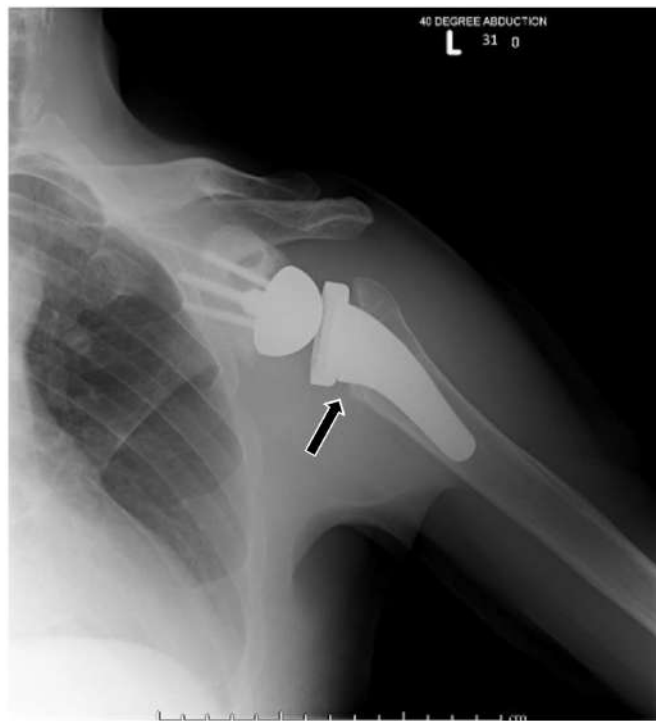


**Fig. 2.** Copeland resurfacing hemi-arthroplasty with bone graft in a 46 year old male – 18 year follow-up post-surgery for complex head split fracture dislocation.

proposed by resurfacing have been suggested to be less than initially reported with associated increased offset and suggested overstuffing of the glenohumeral joint.<sup>14,15</sup> Radiolucent lines have also been attributed to the use of resurfacing implants in up to 25% of patients however several authors have reported these findings without any clear correlation between radiological and clinical findings.<sup>16</sup> Stress shielding, increased glenoid wear and thus increased failure-rates have been reported, especially in those with non-concentric glenoids.<sup>5,17</sup> A reported revision rate of approximately 18% in resurfacing patients was seen in patients with pre-existing rotator-cuff disease and glenoid wear<sup>17</sup> and when compared to TSA, a matched-pair analysis found significant improvement in range of motion and Constant score in the TSA group.<sup>18</sup> The popularity of resurfacing implants has waned with the emergence of stemless and short stem designs.

## 6. Short stems

Short-stem humeral implants have increased in popularity in place of their long-stem equivalents with encouraging mid-term results.<sup>19–24</sup> They are typically press-fit in design, initially with grit-blasted coating and now with porous or hydroxyapatite coating surfaces to allow in-growth. The pore size and titanium alloy coupled with a metaphyseal taper allow for cancellous fixation in the metaphysis as opposed to in the cortical bone of the diaphysis.<sup>23</sup> A short-stem implant offers numerous theoretical benefits over longer stemmed implants including preservation of proximal bone stock, easier insertion, and subsequent removal. A smaller stem should also result in less stress shielding as only the metaphyseal bone is loaded as well as being more independent of the humeral diaphysis and thus avoiding distorted humeral shaft anatomy. This does however allow for an increased risk of malpositioning as it is independent of the shaft. Shorter stems do not however negate all issues associated with their longer stem counterparts and intra-operative fractures remain possible during impaction, specifically around the anterior cortex of the lesser tuberosity.<sup>23</sup> Outcomes 3 years after surgery in over 100 TSAs showed clinically significant improvement in shoulder function scores and no evidence of loosening in those who received a proximal porous-coated short stem. Medial resorption was detected in over 9% of patients, however 94.6% of patients reported high levels of satisfaction and no correlation between clinical findings and radiographic changes was detected.<sup>25</sup> Longer-term follow-up between 4 and 7 years showed good clinical improvement with no evidence of loosening despite 40% of operated shoulders displaying an element



**Fig. 3.** Reverse Short-Stem TSA (Aequalis Ascend Flex®, Wright Medical, Memphis Tennessee, U.S.) showing proximal humeral stress shielding with a short-stemmed implant. In larger canals the manufacturers now recommend avoiding larger implants and choosing cemented implants.

of bone loss in the proximal humerus,<sup>25</sup> (See Fig. 3.).

## 7. Stemless implants

With further interest in reducing proximal bone stock loss, stemless implants have come to the fore (see Table 1). The enthusiasm for such implants is founded in the theoretical benefits offered. Placement of the implant is entirely independent of the humeral diaphysis allowing anatomic placement without need for concern regarding the offset. Without the need for diaphyseal preparation comes the added benefit of preserved bone stock and a reduced risk of intra-operative and peri-prosthetic fracture. Fracture around implants may have worse outcome in standard stems although this is not clearly obvious in the literature. Ease of implantation is demonstrated by reduced blood loss and operating time.<sup>26</sup> Despite clear benefits of stemless implants, they are not without disadvantages and complications. A complication rate of 7.8% in TSAs using stemless humeral implants has been reported<sup>27</sup> with many of the reported complications were intra-operative lateral cortical fractures sustained at implantation, none requiring intervention with uncomplicated resolution. Asymptomatic loosening has also been reported.<sup>27</sup> A further multi-centre, mid-term follow-up on a single implant found a revision rate of 6.3% with rotator cuff failure in 2.9% of cases being the most common indication,<sup>28</sup> the results of which are in line with stemless implants as a whole. Not all patients requiring TSA are suitable candidates for the use of stemless implants and exclusion criteria include poor bone quality, osteopaenia, osteoporosis, significant cysts, and other bone disorders. Assessment of the bone quality in the metaphysis can be difficult and x-ray appearance may not be reliable. Some companies advise the “thumb compression” test. This involved pressing with the thumb on the cut metaphyseal bone to assess density. Soft osteoporotic cancellous bone will imprint easily and then is



**Table 1**  
Summary of currently available stemless shoulder implants.

Manufacturer	Model	Location
Zimmer-Biomet®	Sidus®	Warsaw, Indiana, U.S.
Zimmer-Biomet®	Comprehensive Nano®	Warsaw, Indiana, U.S.
Mathys Medical®	Affinis Short®	Bettlach, Switzerland
Wright Medical®	Simpliciti®	Memphis, Tennessee, U.S.
Arthrex®	Eclipse®	Naples, Florida, U.S.
DepuySynthes®	Global Icon®	Warsaw, Indiana, U.S.
LimaCorporate®	SMR Stemless®	Arlington, Texas, U.S.
Exactech®	Equinox®	Gainesville, Florida, U.S.
OrthoScience®	Catalyst®	Naples, Florida, U.S.
IDO®	Verso®	Theale, Reading, U.K.

**Table 2**  
Summary of currently available short stem shoulder implants.

Manufacturer	Model	Location
Zimmer-Biomet®	Comprehensive®	Warsaw, Indiana, U.S.
Zimmer-Biomet®	Anatomical Shoulder®	Warsaw, Indiana, U.S.
Wright Medical®	Aequalis Ascend Flex®	Memphis, Tennessee, U.S.
Arthrex®	Univers Apex®	Naples, Florida, U.S.

probably unsuitable for a stemless implant. The fixation of stemless implants varies between central screw cages and various finned designs. There is little evidence to suggest at this early stage that one design is superior to another. Screw fixation has been found to have reportedly less calcar osteolysis when compared to impact fixation implants. Alikhah et al. compared the Zimmer-Biomet Sidus® to the Arthrex Eclipse® reporting that impact fixation does not appear to be clinically inferior to the screw fixation method.<sup>29</sup> A large variety of short stem and stemless implants are now available (see Tables 2 and 3) and each design may have a different set of technical tips and failure mechanism. Certainly, if using such implants, the surgeon should ensure a full range of standard stemmed implants are available in case fixation is poor (see Fig. 4a & b) or there is perioperative fracture.

**8. Humeral bone changes with short and stemless implants**

Proximal Stress shielding has been observed with many stem designs but especially uncemented. Distal fixation appears to unload the proximal bone causing various patterns of bone remodelling and some osteolysis. Concerns have been raised relating to the radiological changes noted on short stem humeral implants.<sup>22</sup> When using finite element analysis (FEA) bone models, 3D virtual models were created with set parameters for bone quality and compared under conditions mimicking resurfacing and stemless implants. Stemless implants showed less bone loss at the fixation site when compared to the resurfacing implants whilst both groups

showed more bone loss in the ‘unhealthy bone’ model.<sup>30</sup> These results were similar to those reported by Hawi et al. where stemless implants showed some radiological changes but no inferiority in clinical outcome.<sup>31</sup> In a further FEA study, shortening of the stems produced bone stresses more closely resembling those of cortical bone when analysed in a finite element bone model. Trabecular bone stresses were increased in the stemless models, in keeping with the change in load distribution secondary to design.<sup>24</sup> Comparing finite element models at 45 and 75° of abduction with 10 implants of pegged, boundary crossing and peripherally fixed showed patterns of predicted bone stresses and resorption. Stresses were greatest across all implants at 0–5 mm below the resection level, with resorption most likely between 0 and 15 mm below the resection level. Primary difference between implants was seen in the trabecular bone where centrally pegged implants showed the lowest resorption potential.<sup>24</sup> Calcar changes have been observed in some implants and their long-term relevance is unclear at this stage<sup>28</sup> (see Fig. 5). Certainly, progressive osteolysis must be investigated to exclude other causes such as low-grade infection or wear debris (see Fig. 6).

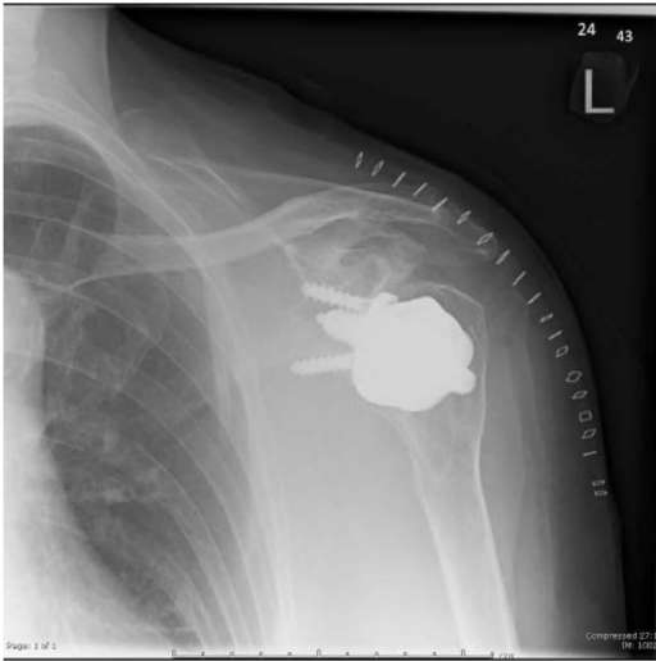**9. Long versus. Short stems: The evidence**

In a comparison of long versus short and coated versus uncoated stems, less radiographic changes have been reported in the short, coated stems.<sup>32</sup> Short-stemmed press-fit implants have been found to have a higher rate of loosening (aseptic and otherwise) than comparable implants for reasons unknown. Radiological signs of loosening seen in 71.0% of cases, 8.7% of these being identified as being at risk of further loosening and an overall revision rate of 8.2%, however the short follow-up period of 24 months of this study may under-estimate the true revision rate.<sup>20</sup> A further short-term follow-up study comparing ‘traditional length’ and ‘short stem’ implants found no difference in functional outcome however did show radiological adaptations. The authors recommended further longer-term studies with particular interest in calcar osteolysis.<sup>33</sup>

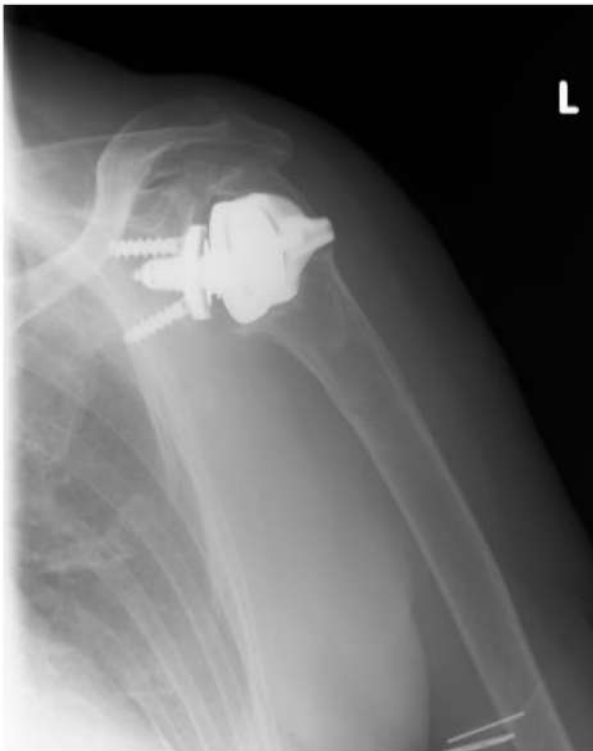A study addressing the functional performance of implants, comparing range of motion and 3D-Motion analysis showed similar performance and showed non-inferiority in the stemless group when compared to the stemmed group.<sup>34</sup> To our knowledge there are no published long-term studies comparing the clinical or functional outcome of stemless and standard-length or short stemmed implants, however we are aware of a trial registered in 2019 described as a patient-blinded trial to compare patient satisfaction, clinical outcome and complication rates of stemmed vs. stemless TSA.<sup>35</sup> Wiater et al. compared the Zimmer-Biomet Comprehensive® Mini to the Comprehensive® Mini in a randomised controlled trial of 270 patients. At 2-year follow-up the short-term clinical results were comparable.<sup>36</sup>

**Table 3**  
Recent publications on short and stemless implants and their follow-up periods.

Study	Implant	Type	Mean Follow-up (Months)	Number of patients
Romeo et al. (2020) <sup>1</sup>	Eclipse®/Univers II® (Arthrex®)	Comparative	24	327
Wiater et al. (2020) <sup>2</sup>	Comprehensive® Mini/Comprehensive® Nano	Randomised controlled (multi-centre)	24	270
Leonidou et al. (2020) <sup>3</sup>	Verso® (IDO®)	Case Series	36	37
Jordan et al. (2019) <sup>4</sup>	Affinis Short® (Mathys®)	Case Series (multi-centre)	48	207
Beck et al. (2018) <sup>5</sup>	TESS® (Biomet®)	Case Series	95	31
Spranz et al. (2017) <sup>6</sup>	TESS®	Comparative	52	12
Hawi et al. (2017) <sup>7</sup>	Eclipse® (Arthrex®)	Case Series	108	52
Uschok et al. (2017) <sup>8</sup>	Eclipse®	Randomised	68	14
Ballas et al. (2016) <sup>9</sup>	TESS®	Case Series	44	27
Habermeyer et al. (2015) <sup>10</sup>	Eclipse®	Case Series	72	68
Bell & Coghlan (2014) <sup>11</sup>	Affinis Short®	Case Series	<24	12

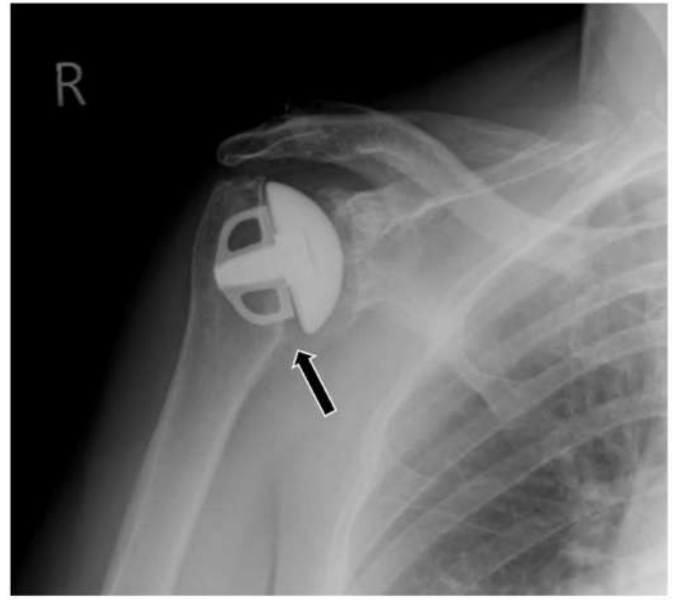


*a*

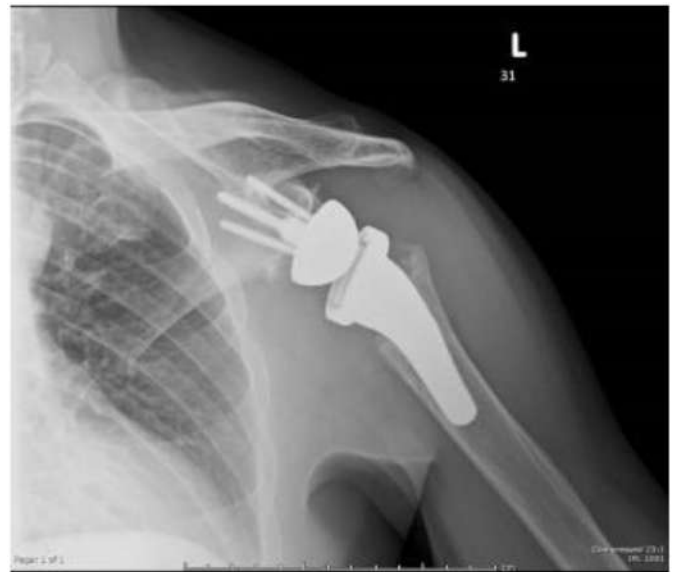

*b*

**Fig. 4.** a: Stemless humeral implant (Lima Corporate, Italy) post-operative x-ray. b: 6-month post-operative x-ray (Lima Corporate, Italy). Rotational displacement probably secondary to poor bone stock. The early clinical result remains excellent however, it may have been wiser to choose a stemmed implant.



**Fig. 5.** Stemless humeral implant (Affinis Short®, Mathys, Bettlach, Switzerland) showing calcar humeral sided stress shielding.



**Fig. 6.** Progressive osteolysis despite a good clinical result, aspiration revealed Cutibacterium Acnes low grade infection.

### 10. Reverse TSA with stemless implants

Use of stemless implants in reverse arthroplasty is novel except for one design.<sup>37</sup> Concern over the biomechanics of the reverse implant made many companies reluctant to embark on shorter design stems however recent introduction of stemless and short stems to reverse arthroplasty is prominent. We are aware of only two published results in this area of a single design with one group reporting thirty-seven prostheses in 36 patients and one deep infection. A survivorship was reported at mean 3-years follow-up

(Range 1–7 years). The authors reported comparable outcomes with reference to various outcome scores whilst preserving bone stock and allowing for reproducible, 'easy' surgery.<sup>37</sup> A further mid-term follow-up study of reverse TSA using stemless implants reported 56 implants reviewed at mean follow-up of 58 months. One revision surgery was performed for instability converting to a conventional implant. One intra-operative complication of a metaphyseal crack was reported whilst no evidence of humeral loosening was found. A further five cases of scapular notching were reported with no clinical implication.<sup>38</sup>

## 11. Other review articles on stemless implants

The paucity of robust evidence in this field is further echoed by the lack of available systematic reviews of available research. One such review article found 19 TSA and hemi-arthroplasty (HA) studies with a total of 1115 patients identified. Only 4 studies on two implant designs (Eclipse and TESS) including 162 patients had a mean follow-up between 60 and 120 months. Six reverse TSA studies using two implants (Verso and TESS) with a total of 346 patients were identified, all with a mean follow-up between 18 and 60 months. A reliable improvement in outcomes compared with preoperative scores across studies was described with a cumulative 0.7% (8 of 1115) humeral component complication rate for TSA and HA components. There was a cumulative 1.7% (6 of 346) humeral complication rate for reverse TSA prostheses.<sup>39</sup>

## 12. Conclusions

Stemless and short stem shoulder implants are increasingly popular compared to standard diaphyseal implants (see Table 3). They seem to offer advantage especially in revision surgery where ease of removal is obvious. Reproduction of the anatomy of the proximal humerus may be easier however there are few long-term clinical studies or randomised control trials to definitively prove benefits. Surgeons should therefore be cautious about their use and contribute to local and national joint registries. Standard length compatible implants both cemented and uncemented should always be available in case of perioperative failure.

## Declaration of competing interest

Mr Peadar MacSuibhne has no conflicts of interest.

Mr Cormac Kelly is a Consultant to Mathys Switzerland and is part of the design team for the Mathys stemless Implant, He receives no personal royalties or payments. Mathys do sponsor the Shoulder Training Fellowship at the Robert Jones and Agnes Hunt Hospital.

## References

- Bankes, M.J. and R.J. Emery, Pioneers of Shoulder Replacement: Themistocles Gluck and Jules Emile Péan. (1058-2746 (Print)).
- Neer CS. 2nd, *The classic: Articular replacement for the humeral head.* 1955. *Clin Orthop Relat Res.* 2011;469(9):2409–2421.
- Hughes M, Neer CS. 2nd, *Glenohumeral joint replacement and postoperative rehabilitation.* *Phys Ther.* 1975;55(8):850–858.
- Flatow, E.L. and A.K. Harrison, A History of Reverse Total Shoulder Arthroplasty. (1528-1132 (Electronic)).
- Copeland S. The continuing development of shoulder replacement: "reaching the surface." *J Bone Joint Surg Am.* 2006;88(4):900–905.
- Harryman, D.T., et al., The effect of articular conformity and the size of the humeral head component on laxity and motion after glenohumeral arthroplasty. A study in cadavera. *J. Bone Joint Surg Am.* 1995 Apr;77(4):555-63. doi: 10.2106/00004623-199504000-00008. PMID: 7713972. (0021-9355 (Print)).
- Robertson, D.D., et al., Three-dimensional Analysis of the Proximal Part of the Humerus: Relevance to Arthroplasty. (0021-9355 (Print)).
- Boileau P, Walch G. The three-dimensional geometry of the proximal humerus. Implications for surgical technique and prosthetic design. *J Bone Joint Surg Br.* 1997;79(5):857–865.
- Iannotti, J.P., et al., The Normal Glenohumeral Relationships. An Anatomical Study of One Hundred and Forty Shoulders. (0021-9355 (Print)).
- Owens CJ, Sperling JW, Cofield RH. Long-stemmed humeral components in primary shoulder arthroplasty. *J Shoulder Elbow Surg.* 2014;23(10):1492–1498.
- Litchfield, R.B., et al., Cemented versus Uncemented Fixation of Humeral Components in Total Shoulder Arthroplasty for Osteoarthritis of the Shoulder: A Prospective, Randomized, Double-Blind Clinical Trial-A JOINTs Canada Project. (1532-6500 (Electronic)).
- Nowinski RJ, et al. Antibiotic-loaded bone cement reduces deep infection rates for primary reverse total shoulder arthroplasty: a retrospective, cohort study of 501 shoulders. *J Shoulder Elbow Surg.* 2012;21(3):324–328.
- Levy O, Copeland SA. Cementless surface replacement arthroplasty (Copeland CSRA) for osteoarthritis of the shoulder. *J Shoulder Elbow Surg.* 2004;13(3):266–271.
- Mechlenburg I, et al. The Copeland resurfacing humeral head implant does not restore humeral head anatomy. A retrospective study. *Arch Orthop Trauma Surg.* 2013;133(5):615–619.
- Mansat P, et al. Resurfacing humeral prosthesis: do we really reconstruct the anatomy? *J Shoulder Elbow Surg.* 2013;22(5):612–619.
- Rydholm U, Sjögren J. Surface replacement of the humeral head in the rheumatoid shoulder. *J Shoulder Elbow Surg.* 1993;2(6):286–295.
- Smith T, et al. Humeral surface replacement for osteoarthritis. *Acta Orthop.* 2013;84(5):468–472.
- Buchner M, Eschbach N, Loew M. Comparison of the short-term functional results after surface replacement and total shoulder arthroplasty for osteoarthritis of the shoulder: a matched-pair analysis. *Arch Orthop Trauma Surg.* 2008;128(4):347–354.
- Romeo AA, et al. Eclipse stemless shoulder prosthesis vs. Univers II shoulder prosthesis: a multicenter, prospective randomized controlled trial. *J Shoulder Elbow Surg.* 2020;29(11):2200–2212.
- Casagrande, D.J., et al., Radiographic Evaluation of Short-Stem Press-Fit Total Shoulder Arthroplasty: Short-Term Follow-Up. (1532-6500 (Electronic)).
- Denard, P.J., et al., Proximal Stress Shielding Is Decreased with a Short Stem Compared with a Traditional-Length Stem in Total Shoulder Arthroplasty. (1532-6500 (Electronic)).
- Denard PJ, et al. Radiographic changes differ between two different short press-fit humeral stem designs in total shoulder arthroplasty. *J Shoulder Elbow Surg.* 2018;27(2):217–223.
- Jost PW, et al. Total shoulder arthroplasty utilizing mini-stem humeral components: technique and short-term results. *HSS J : the musculoskeletal journal of Hospital for Special Surgery.* 2011;7(3):213–217.
- Razfar N, et al. Comparison of proximal humeral bone stresses between stemless, short stem, and standard stem length: a finite element analysis. *J Shoulder Elbow Surg.* 2016;25(7):1076–1083.
- Schnetzke M, et al. Mid-term results of anatomical total shoulder arthroplasty for primary osteoarthritis using a short-stemmed cementless humeral component. *Bone Joint Lett J.* 2018;100-b(5):603–609.
- Berth A, Pap G. Stemless shoulder prosthesis versus conventional anatomic shoulder prosthesis in patients with osteoarthritis: a comparison of the functional outcome after a minimum of two years follow-up. *J Orthop Traumatol.* 2013;14(1):31–37.
- Hawi, N., et al., Anatomic Stemless Shoulder Arthroplasty and Related Outcomes: A Systematic Review. (1471-2474 (Electronic)).
- Jordan RW, et al. Mid-term results of a stemless ceramic on polyethylene shoulder prosthesis – a prospective multicentre study. *Shoulder Elbow.* 2019, 1758573219866431.
- Alikhah, A., et al., Screw Fixation in Stemless Shoulder Arthroplasty for the Treatment of Primary Osteoarthritis Leads to Less Osteolysis when Compared to Impaction Fixation. (1471-2474 (Electronic)).
- Santos B, et al. Bone remodelling of the humerus after a resurfacing and a stemless shoulder arthroplasty. *Clin Biomech.* 2018;59:78–84.
- Hawi, N., et al. Nine-year outcome after anatomic stemless shoulder prosthesis: clinical and radiologic results. *J Shoulder Elbow Surg.* 2017;26(9):1609–1615.
- Godenèche, A., et al., Comparison of Revision Rates and Radiographic Observations of Long and Short, Uncoated and Coated Humeral Stem Designs in Total Shoulder Arthroplasty. (2058-5241 (Print)).
- Denard PJ, et al. Stress shielding of the humerus in press-fit anatomic shoulder arthroplasty: review and recommendations for evaluation. *J Shoulder Elbow Surg.* 2018;27(6):1139–1147.
- Spranz, D.M., et al., Functional Midterm Follow-Up Comparison of Stemless Total Shoulder Prostheses versus Conventional Stemmed Anatomic Shoulder Prostheses Using a 3D-Motion-Analysis. (1471-2474 (Electronic)).
- Issa, Z.A.-O., et al., Patient-reported Outcome after Stemmed versus Stemless Total Shoulder Arthroplasty for Glenohumeral Osteoarthritis: A Patient-Blinded Randomized Clinical Trial. (1745-6215 (Electronic)).
- Wiater JM, et al. Prospective, blinded, randomized controlled trial of stemless versus stemmed humeral components in anatomic total shoulder arthroplasty: results at short-term follow-up. *J Bone Joint Surg Am.* 2020;102(22):



- 1974–1984.
37. Leonidou, A., et al., Reverse Shoulder Arthroplasty with a Cementless Short Metaphyseal Humeral Prosthesis without a Stem: Survivorship, Early to Mid-term Clinical and Radiological Outcomes in a Prospective Study from an Independent Centre. (1633-8065 (Print)).
  38. Ballas, R. and L. Béguin, Results of a Stemless Reverse Shoulder Prosthesis at More than 58 Months Mean without Loosening. (1532-6500 (Electronic)).
  39. Uppill-Brown A, Satariano N, Feeley B. Stemless shoulder arthroplasty: review of short and medium-term results. *JSES Open Access*. 2019;3(3):154–161.



Contents lists available at ScienceDirect

## Journal of Arthroscopy and Joint Surgery

journal homepage: [www.elsevier.com/locate/jajs](http://www.elsevier.com/locate/jajs)

## Review article

## Surgical rationale and controversies of glenoid replacement in osteoarthritis: How to choose the glenoid implant?

Giuseppe Sircana<sup>a, \*</sup>, Giovanni Merolla<sup>a, b</sup>, Paolo Paladini<sup>a</sup><sup>a</sup> Unit of Shoulder and Elbow Surgery, Cervesi Hospital, Cattolica, RN, Italy<sup>b</sup> International Doctorate School (PhD) in Clinical and Experimental Medicine, Italy

## ARTICLE INFO

## Article history:

Received 5 December 2020

Received in revised form

26 December 2020

Accepted 2 January 2021

Available online 6 January 2021

## Keywords:

Total shoulder arthroplasty

Glenoid replacement

Glenoid loosening

## ABSTRACT

Total shoulder arthroplasty is an effective procedure in restoring anatomy and biomechanics of the arthritic shoulder. It provides excellent clinical results, and its use is increasing worldwide. Glenoid loosening is the weak link in shoulder replacement, accounting for nearly one third of all total shoulder arthroplasty complications. Its causes and possible solutions have been object of extensive investigation. To strengthen glenoid fixation and provide long-term survival to the implant, several technical improvements have been proposed, different materials have been tested and various prosthetic glenoid designs have been developed, including cemented and uncemented all-polyethylene components, metal-backed, hybrid, inlay and augmented components. Thus, the surgeon has been provided with many options, but no clear superiority of one implant over the others has been proved. The choice of the right implant requires careful evaluation of patient's pathology, anatomy and expectation and a thorough understanding of prosthetic shoulder biomechanics and of mechanisms of failure. The aim of this review is to discuss the available options for glenoid implants in TSA, describe the causes of failure and report author's preferences in glenoid replacement.

© 2021 International Society for Knowledge for Surgeons on Arthroscopy and Arthroplasty. Published by Elsevier, a division of RELX India, Pvt. Ltd. All rights reserved.

## 1. Introduction

TSA is the procedure of choice to restore anatomy and biomechanics of the arthritic shoulder.<sup>1–3</sup> Its outcomes are improving over time,<sup>4</sup> thanks to refining of implant design and improvement of implantation techniques, and its use is increasing worldwide.<sup>4–6</sup> In spite of the good clinical results,<sup>2,4,7</sup> TSA is not devoid of complications: they are reported to occur in 10.7–14.7% of patients.<sup>8,9</sup> Complication rates remained substantially stable even after the tremendous increase in implantation rate<sup>8,10</sup>; however, they are increasing in absolute numbers. A general classification of complications could divide them in: involving soft tissues, glenoid component and humeral component.<sup>8</sup> Complications involving the glenoid component are by far the most common: glenoid loosening

is reported to account for 23–32% of complications and to affect 2.5–5.3% of all shoulders.<sup>8–10</sup> Therefore, long-term results of TSA are bound to the survival of the glenoid component. In this review, we will discuss the available options for glenoid implants in TSA, describe the causes of failure and report our preferences in glenoid replacement.

## 2. Glenoid components

Long term fixation of the glenoid component remains an unsolved problem. Manufacturers have introduced on the market new prosthetic glenoid designs and refined the older ones, in order to reduce loosening rate. Results improved over time,<sup>4</sup> although no component design proved clearly superior to the others (Table 1).

## 2.1. Cemented all-polyethylene components

Cemented APGCs are, at present, the most commonly used implants. Keeled glenoid components were the first to be introduced in the early 1970s.<sup>11</sup> They attained 10-years survival rates of 93–95% and 15-years survival rates that reach 92%.<sup>12,13</sup> In a

*Abbreviations:* TSA, total shoulder arthroplasty; APGC, all-polyethylene glenoid component; RTSA, reverse total shoulder arthroplasty.

\* Corresponding author. Unit of Shoulder and Elbow Surgery, Cervesi Hospital, AUSL Romagna, Via L. v. Beethoven 46, 47841, Cattolica, Italy.

E-mail addresses: [gsirca@hotmail.it](mailto:gsirca@hotmail.it) (G. Sircana), [giovannimerolla@hotmail.com](mailto:giovannimerolla@hotmail.com) (G. Merolla), [palpaolo@me.com](mailto:palpaolo@me.com) (P. Paladini).

<https://doi.org/10.1016/j.jajs.2021.01.002>

2214-9635/© 2021 International Society for Knowledge for Surgeons on Arthroscopy and Arthroplasty. Published by Elsevier, a division of RELX India, Pvt. Ltd. All rights reserved.

**Table 1**  
Comparison of glenoid components' design of anatomical total shoulder arthroplasty.

Glenoid component design	Strengths	Weaknesses
Cemented all-polyethylene components	Good long-term survivorship High patient satisfaction	High rate of long-term radiolucent lines Risk of radiographic loosening
Central peg bone-ingrowth all polyethylene components	Excellent central peg bone ingrowth	Long term results unavailable
Cementless all-polyethylene components	Good central peg bone ingrowth	High rate of radiolucent lines Long term results unavailable
Standard metal-backed components	Modularity Bone ingrowth of porous-coated metal	High polyethylene wear High rate of revision
Trabecular tantalum metal-backed components	Bone ingrowth of trabecular tantalum coating Good mid-term survivorship	Risk of metal debris
Hybrid components	Monoblock design Low rate of radiolucent lines	Long term results unavailable
Inlay components	Preserved glenoid bone Reduction of eccentric loading	Long term results unavailable
Posteriorly-augmented components	Suitable for B2 and B3 glenoids Restoration of glenoid version and joint line Preserved glenoid bone	High rate of failure with components >10 mm of augmentation (posterior wear > 25°)

multicentre study on 396 TSA, 10-years glenoid survivorship was reported to be as high as 98.3% and 93.5% of the included patients were satisfied with their implant.<sup>14</sup> Their weak spot has always been radiographic outcome, with presence of radiolucent lines reported in up to 84% of patients and radiographic loosening reaching 44%.<sup>13,15</sup> Revision has an obvious influence on clinical results,<sup>15</sup> while the relationship between presence of radiolucent lines and clinical outcome has some unclear aspects:<sup>15,16</sup> early radiolucent lines are not correlated to radiographic failure,<sup>16</sup> but mid-term clinical results and complications are significantly related to the presence of radiolucent lines.<sup>14,17</sup> Granted the good clinical results, effort was spent to reduce radiolucent lines and radiographic loosening, modifying some characteristics of glenoid components. Curved back components were introduced as more conforming to the underlying glenoid: a comparison of radiological results of curved- and flat-backed glenoids showed higher radiolucent line score in flat-backed components.<sup>18</sup> The greatest change in glenoid design was the adoption of pegged fixation. The use of pegged components decreases peak stress on cement mantle, granting longer duration of the fixation, and increase stability, limiting micromotion.<sup>19,20</sup> Peg design and macrostructure determine the pull-out force a glenoid can resist before displacement: they influence cement flow around pegs and cement pressurization during implantation.<sup>21</sup> Increased cement pressurization around pegs reduces the incidence of radiolucent lines.<sup>22,23</sup> Comparisons of keeled and pegged components led to alternating results,<sup>16,24–27</sup> generally favouring pegged components in radiolucency rate and survival. A recent meta-analysis<sup>28</sup> reports no difference in clinical outcomes and radiolucencies between the two fixation designs, but significantly lower revision rate with the use of pegged implants.

## 2.2. Cementless all-polyethylene components

In the continuous effort to enhance glenoid fixation, central peg bone-ingrowth minimally cemented components have been developed. They attain primary fixation through cementation of their peripheral pegs and press-fitting of their central peg. Secondary fixation is then obtained thanks to bone ingrowth into the fins of the uncemented central peg. It was supposed that reduced use of cement would decrease thermal damage to glenoid cancellous bone, preventing radiolucent lines formation, and bone ingrowth into the central peg would provide long term survival. Good clinical and radiographic outcomes at short and mid-term follow-up were obtained, with good integration of the central peg and low rate and grade of radiolucencies.<sup>29–37</sup> With CT scan analysis, osseous ingrowth on the central peg has been demonstrated to

increase over time, with uniformly absent radiolucent lines around pegs.<sup>35,38</sup> At a long-term follow-up, 97% survival was achieved, with 81% of the implants demonstrating peg osteointegration and no radiolucent lines.<sup>39</sup>

It has been proposed to implant polyethylene components completely without cementation. These implants rely, for primary fixation, on press-fitting of pegs directly into bone. Biomechanical studies clarified that the pull-out strength a peg is able to resist is enough to provide primary fixation.<sup>40</sup> Multiple pegs can resist shear forces<sup>41</sup> and, being positioned at the periphery of the implant and in the denser subchondral bone, they could contrast the rocking horse phenomenon.<sup>40,42,43</sup> In the clinical setting, at a short-term follow-up, good functional recovery was obtained; 12% of patients showed radiological signs of loosening, but no need for revision.<sup>44</sup> At a mean follow-up of 8.4 years, 88% survival was demonstrated, with 74% of progressive radiolucent lines and 71% peg osteointegration.<sup>45</sup>

## 2.3. Metal-backed components

Metal-backed glenoids present some theoretical advantages: these implants could be used with both anatomic and reverse arthroplasties without need for replacement, making revision easier and faster, and long-term stable fixation should be assured by the bone ingrowth into the component coating. Clinical reports showed functional results comparable to that of APGCs<sup>46,47</sup>; moreover, they demonstrated reduced rate of radiolucent lines,<sup>46,47</sup> but they have high rates of revision.<sup>46–50</sup> At a 12-years timepoint, Boileau et al.<sup>51</sup> demonstrated a survival of 46%, with an important increase in revision rate after the fourth year. Furthermore, polyethylene wear was an important issue, affecting half of the examined patients.<sup>51</sup> Finally, exchange of polyethylene without metal back revision has proven to be a rarely befitting option.<sup>51</sup> The weakness of this implant design is not in the metal back itself, but in the excess polyethylene wear. It brings biologic problems, as wear debris causes bone resorption, mechanical problems, as bone resorption causes loosening of the glenoid component, and clinical problems, as loose implant causes pain and decreased motion.<sup>51</sup> Wear of the polyethylene component is caused by a combination of the following: reduced thickness of the modular polyethylene; over-tensioning of soft tissues, causing increased loading on polyethylene, that is due to the increased thickness of the glenoid component, sum of metal-back and polyethylene modular components; increased stresses at the polyethylene-metal-back-bone interfaces, caused by the increased and mismatched stiffness of the metal back; eccentric loading and asymmetric wear of the



polyethylene surface.<sup>46–48,51,52</sup> This led most of the surgeons to abandon metal-backed implants. However, some authors<sup>53</sup> obtained substantially different results: at a mean follow-up of 75.4 months, they reported 22.9% of radiolucent lines and no glenoid failure. They attributed the good results to the design of the implanted glenoid component, that was curved-back and non-conforming and had a thick metal-back, that decreased stress on the polyethylene; it relied on two screws, for initial fixation, and on an hollow peg, covered in hydroxyapatite, for long-term fixation.<sup>54</sup> Anyway, further proof is needed to overturn common judgement on metal backed implants.

Trying to solve the problems of modular metal-back components, trabecular metal components were developed. In these components, polyethylene is moulded on the metal back, creating a monoblock design. They have multiple theoretical advantages, such as bone preservation, stable fixation due to osteointegration, implant longevity and reduced operative time.<sup>55</sup> The monoblock design would grant diminished backside polyethylene wear, eliminating micromotions between modular components.<sup>55</sup> Furthermore, the metallic portion is made of tantalum. Tantalum is a biomaterial with structure similar to that of trabecular bone; it shows a modulus of elasticity comparable to that of bone and a porosity that allows osteointegration, reducing stress at the interfaces.<sup>56</sup> First generation tantalum glenoid components showed unacceptable failure rate and their production was discontinued.<sup>57</sup> Second generation provided more promising results: at a 3-years follow-up good clinical results were obtained, with 77% return to previous working activities, 47% return to sport and no revision required.<sup>38</sup> However, other reports showed that, at a 2 years follow-up, 8–34% of glenoid components had radiolucent lines and 11–44% showed metal debris formation.<sup>55,58</sup> A recent study,<sup>59</sup> with a minimum 5-years follow-up, compared cemented and uncemented tantalum components; it showed better ROM results with uncemented components, that, on the other hand, produced more metal debris and more radiolucent lines. Overall, no patient needed revision, 26% had metal debris and 46% had radiolucent lines.<sup>59</sup>

#### 2.4. Hybrid components

In the effort to develop glenoid component that can overcome fixation issues of cemented APGCs, hybrid prostheses were produced. In these components, fully-moulded polyethylene glenoid is connected to a central porous-titanium cage, and porous titanium caps all the pegs, creating a monoblock hybrid design. A comparison with APGC showed no clinical differences at a short-term follow-up, with less than half the rate of radiolucent lines.<sup>60</sup> However, this finding was not confirmed by a similar study, that could not find any significant difference between an hybrid glenoid and an APGC.<sup>61</sup> Longer follow-up studies were afterwards performed: at a mean follow-up of 4 years, hybrid glenoid demonstrated better ROM, clinical and radiographic results compared to a pegged APGC.<sup>62</sup> At minimum five-years follow-up, Nelson et al.<sup>63</sup> reported 42% of radiolucencies but only 2.2% of failure.

#### 2.5. Inlay components

Inlay components are designed to be implanted flush with the glenoid surface. Proposed advantages of inlay components are preservation of glenoid bone stock, requiring less reaming, and diminished edge loading, because component edges are protected by surrounding glenoid bone.<sup>64</sup> Biomechanical studies enforced the theoretical superiority of inlay glenoids over onlay glenoids in resistance to rocking horse phenomenon.<sup>65,66</sup> Preliminary clinical reports were obtained from patients with severe glenoid bone deficiency and retroversion.<sup>67,68</sup> Cvetanovich et al.<sup>64</sup> reported

clinical results after a 3 years follow-up, showing functional improvement with good ROM recovery, no revision surgery, no component loosening, 85% of high patient satisfaction and return to preoperative occupational level in 76% of cases. Egger et al.,<sup>69</sup> after a similar follow-up reported good functional recovery, marked diminution of VAS score and no need for revision, despite all of the examined patients exhibited on radiographic analysis, radiolucent lines. At a minimum 6 years follow-up, in patients with a mean glenoid retroversion of 18°, 28% of patients had evidence of radiolucent lines on X-ray, but no revision was required,<sup>70</sup> suggesting suitability of this implant for replacement of retroverted glenoids. The published results are promising, but all the reported cohorts were small; larger groups are needed to evenly evaluate the outcomes of these implants.

#### 2.6. Posteriorly-augmented components

Posterior glenoid wear increases the technical challenge of implanting a TSA and increases post-operative complications.<sup>71</sup> A retroverted glenoid component decreases compressive glenohumeral forces, thus reducing joint stability.<sup>72</sup> Rotator cuff muscles, when glenoid surface is not perpendicular to their axis, create a posteriorly directed force vector,<sup>73</sup> causing a progressive humeral posterior translation.<sup>74</sup> Every degree of retroversion causes a posterior displacement of the centre of rotation of 0.5 mm.<sup>75</sup> As a result, there is a posterior migration of the gleno-humeral contact point, with an increased stress of the posterior glenoid and of the posterior cement mantle, creating micromotion at the bone-cement interface, initiating rocking horse phenomenon and predisposing to glenoid component loosening.<sup>73</sup> To obtain a stable and long-lasting implant, it is advisable to restore native glenoid version; to achieve this, eccentric reaming and augmented components are the main possible choices. Both techniques showed effectiveness,<sup>76</sup> yet, compared to eccentric reaming, the use of an augmented component seems advantageous, allowing to preserve up to 70% more bone stock, with the wedged design being the most conservative.<sup>77</sup> Furthermore, augmented glenoid components allows joint line restoration, improvement in backside bony contact<sup>78</sup> and recovery of rotator cuff muscles length.<sup>77</sup> Posteriorly-augmented glenoid components demonstrated excellent recovery of glenohumeral version.<sup>78,79</sup> Available implants can be divided in 3 categories: full-wedged implants, when the augment is a complete wedge from anterior to posterior, half-wedged, when the wedged augment is positioned on the posterior half of the implant, and stepped implants, when the augment arises perpendicularly to the vector of the joint loading in the posterior half of the implant.<sup>80</sup> At a minimum 2-years follow-up of full-wedged glenoids, satisfactory clinical results were obtained, with a 4% revision rate and a 54% radiolucent lines.<sup>81</sup> Interestingly, radiolucent lines were clustered in patients with more preoperative retroversion, who needed the thicker augments.<sup>81</sup> Grey et al.<sup>78</sup> reported, at a mean 4 years follow-up, 97% of patients satisfied with their implant, 2.9% revision rate and 36.8% incidence of radiolucent lines. Good clinical results were demonstrated with stepped glenoids after two years follow-up, with no revisions and 15% peg radiolucency. Worse radiographic results were associated with incomplete retroversion correction.<sup>82</sup> Half-wedged glenoids, at 1 year follow-up, required no surgical revision and demonstrated excellent version correction.<sup>79</sup> Reported results are, overall, extremely promising, but no long-term follow-up is available for these implants.

### 3. Glenoid failure

Glenoid loosening is the most common complication after TSA and can happen through multiple mechanisms.<sup>8–10</sup> Modes of

failure include: failure of the component itself (distortion of the prosthetic surface, fracture or delamination of the component, separation of the polyethylene from the metal-back), failure of the component seating (inadequate preparation of the bone surface, prosthesis not fully seated on the prepared bone, loss of cement interposed between the body of the component and the glenoid bone surface, fracture or bone deficiency, resorption of bone at the prepared surface), failure of initial component fixation (suboptimal cement technique, fixation in bone of limited quantity and poor quality), failure of bone (progression of radiolucent lines, immunological response to polyethylene, osteolysis) and prosthetic loading (conforming joint surfaces, rim loading, weight-bearing shoulder prosthesis, glenoid component version, glenohumeral instability, rotator cuff insufficiency).<sup>83</sup>

Glenoid bone is subject to joint reaction forces that are variable in magnitude and direction through the articular range of motion; their peak is at 90° of abduction, when they reach 0.89 times body weight.<sup>84–86</sup> The shearing component of this force at the glenoid peaks at 60° of abduction and reaches 0.4 times body weight.<sup>84</sup> Considering the relatively small glenoid surface, high stress is generated at the glenoid component-bone interface.<sup>87</sup> Whenever compressive loads are applied eccentrically, the high joint reaction forces generated promote the tipping of the glenoid: the so-called rocking horse phenomenon.<sup>88</sup> While superior edge undergoes compressive stress, the inferior edge is subject to tensile stress.<sup>89</sup> Tensile stress during edge loading exceeds the implant-cement interface strength, while cement-bone interface strength can be reached only very close to the edge.<sup>89</sup> As a consequence, loosening typically occurs at the implant-cement interface and starts at the inferior edge of the glenoid, subsequently propagating superiorly.<sup>89,90</sup> In keeled implants, the crack propagates at the periphery of the fixation keel, while, in pegged implants, cracks propagate across the bone between the tips of the pegs.<sup>89</sup> Consistently, inferior radiolucent lines tend to grow over time, while superior lines tend not to propagate.<sup>91</sup> Fixation stability is affected by bone mineral density of the glenoid, with less glenoid displacement shown in denser bone.<sup>92,93</sup> Furthermore, the thickness of the cement mantle may influence the mechanism of loosening: loosening follow different macroscopic patterns with different mantle thickness; with a cement mantle <2 mm, cement-implant interface is the weakest link, while with thicker cement mantles, failure occurs at the bone-cement interface.<sup>94</sup>

Uneven loads leading to rocking horse phenomenon may be generated by unbalanced muscle forces, caused by rotator cuff insufficiency<sup>10,88</sup> or by capsuloligamentous imbalance leading to instability.<sup>95–97</sup> Poor implantation can expose glenoid to uneven loads, as well. This can be caused by incorrect glenoid bone reaming,<sup>87</sup> non-anatomical positioning of the implant,<sup>98</sup> presence of a posteriorly eroded glenoid<sup>71</sup> or poor cementation technique.<sup>99</sup> Even the humeral head material plays a role in loosening: loosening occurs at a lower rate in ceramic heads compared to metallic heads,<sup>100</sup> because of the reduced wear and particle formation seen in the ceramic-polyethylene coupling,<sup>101</sup> which, in turn, reduces the inflammatory response and, thus, osteolysis.

The definition of loosening has been equivocal in literature, because of its variable presentation and clinical effect. A recent systematic review<sup>102</sup> identified 40 definitions of loosening. It has been defined according to clinical data, radiographic appearance, condition of the component, their variation over time or a combination of these parameters. Not surprisingly, the most commonly evaluated parameter in the provided definitions is the radiological one. The presence of radiolucent lines >2 mm between glenoid bone and glenoid prosthetic component is a common cut off to define loosening. Radiolucent lines are reported in a variable percentage ranging between 13.5% and 94% in different

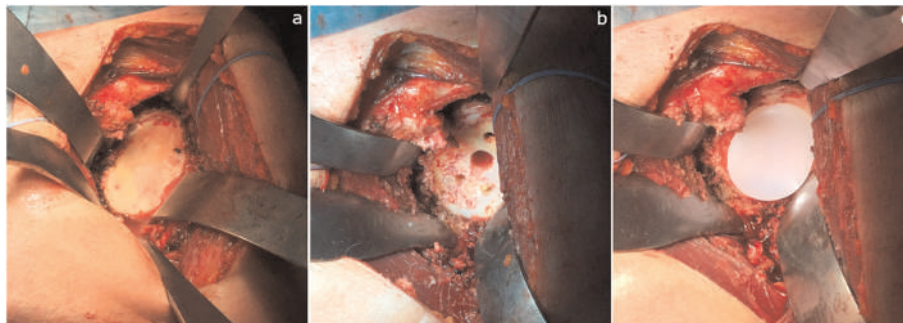
studies.<sup>12,14,24,25,103</sup> Anyway, the presence of radiolucent lines has equivocal clinical meaning, with failure rates ranging between 2% and 10%.<sup>12,14,24,25,103</sup>

Various classifications of radiolucent lines and consequent loosening have been proposed.<sup>25,88,104–107</sup> The most used in literature is probably the one proposed by Molè et al.<sup>104</sup> They subdivided the glenoid component in 6 areas: zones 1, 6 and 5 were the upper, middle and lower parts of the tray, while zones 2, 3 and 4 were the upper, middle and lower periphery of the keel. Presence of radiolucencies was assessed in each zone and graded as: 1, less than 1 mm, 2, between 1 and 2 mm, and 3, more than 2 mm. Summing up the score of each zone, the radiolucent line score was calculated. A score greater than 12 is arbitrarily considered as a loosening. This score was specifically designed for keeled components. The score proposed by Franklin et al.<sup>88</sup> divided keeled glenoid components in 5 classes: class 0, no lucency; class 1, lucency at the superior and/or inferior flange only; class 2, incomplete lucency at the keel; class 3, complete lucency of up to 2 mm around the component; class 4, complete lucency greater than 2 mm around the component; class 5a, component translated (eg, tipped or shifted); and class 5b, component dislocated from the bone. Based on this classification, Lazarus et al.<sup>25</sup> developed their classification of pegged components: grade 0, no radiolucency; grade 1; incomplete radiolucency around one or two pegs; grade 2, complete radiolucency ( $\leq 2$  mm wide) around one peg only, with or without incomplete radiolucency around one other peg; grade 3, complete radiolucency ( $\leq 2$  mm wide) around two or more pegs; grade 4, complete radiolucency (>2 mm wide) around two or more pegs; grade 5, gross loosening.


#### 4. Author's preference

Glenoid replacement is the weak link in TSA. It requires experience and technical skills to minimize complications. The main reasons for difficulty in glenoid implantation are: glenoid bone loss, anatomical variations among individuals and lack of intraoperative landmarks for the blade of the scapula.<sup>98</sup> Glenoid bone loss is related to the erosion and distorted version of arthritic shoulders.<sup>108</sup> Shape, version and dimension of the glenoid are variable.<sup>109–111</sup> Even though the blade of the scapula helps to choose central peg position, its direction should be presumed on the orientation of the exposed glenoid surface.<sup>98</sup> Biomechanical findings showed that even a few degrees of glenoid malposition can affect glenoid fixation and related clinical outcomes.<sup>98</sup> Glenoid exposure is, then, of paramount importance in glenoid component placement, as it helps to correctly align and size the glenoid component.<sup>112</sup>

Regarding the choice of the glenoid component, our experience began with fully cemented APGC.<sup>113</sup> We reported significant increase in ROM and Constant score postoperatively, with radiolucent lines present in 63.3% of glenoids and 6.7% of loose glenoids at 60 months follow up.<sup>113</sup> APGCs provide the most predictable fixation and outcomes, being available more than acceptable long-term survivorship data.<sup>12,13</sup> The choice between pegged and keeled components is still debated. Recent research findings demonstrated superior survival<sup>28</sup> and superior fixation in low density, osteoporotic bone<sup>92</sup> of pegged components over keeled components. These findings were not confirmed by all authors: in a large series, keeled glenoid demonstrated superior results,<sup>16</sup> therefore, light has not been definitively shed on this topic. From 2011, we decided to use central peg bone-ingrowth APGCs (Fig. 1). This design, first proposed by Wirth in 2001<sup>114</sup>, is a further refinement of the pegged APGC (Fig. 2). We obtained reasonable mid-term clinical outcomes and satisfactory radiological results (Fig. 3): central peg bone



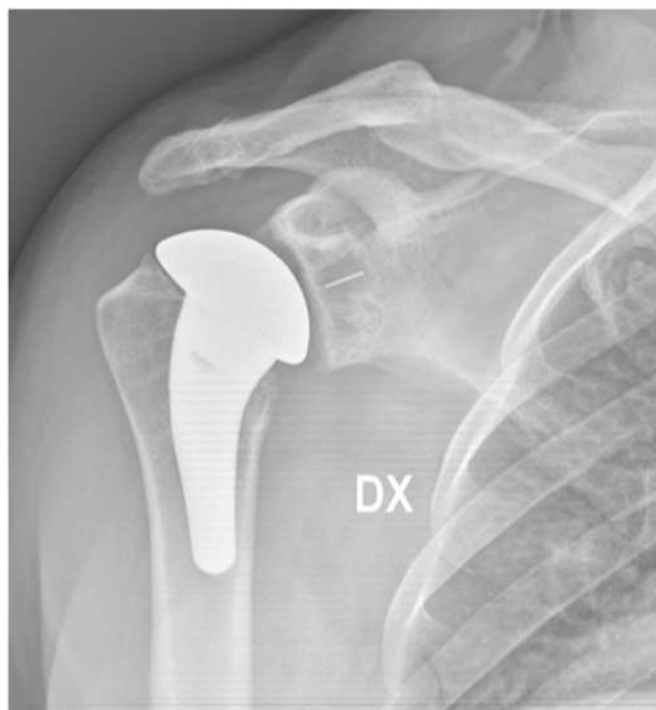**Fig. 1.** Glenoid replacement with central peg bone-ingrowth APGC. **a.** Glenoid exposure. **b.** Glenoid preparation. **c.** Implanted glenoid component.



**Fig. 2.** Central peg bone-ingrowth APGC.

ingrowth was detected on CT scan in 93% of patients, with bone in a median of 7/10 compartments around the central peg.<sup>36</sup> Afterwards, we participated to a multicentre study,<sup>37</sup> comprising 1270 individuals from 11 centres: average improvement in comfort and function achieved by these patients exceeded the published values for the minimal clinically important difference and provided well over 30% of the maximum possible improvement.

We are aware that glenoid preparation, reaming and appropriate cementation are the key points for a successful fixation. Appropriate reaming extent and direction foster an optimal bone-prosthesis seating and reduce eccentric loading and related risk of loosening.<sup>87</sup> Modern cementing techniques have been developed with the aim to reduce radiolucent lines around the glenoid.<sup>115,116</sup> Prior to cementation, accurate cleaning and drying of the glenoid with pulsatile lavage is a mandatory step.<sup>117</sup> Cement should be prepared with vacuum devices to reduce its porosity. Syringe pressurization of the cement followed by compression with an instrument improve its penetration in cancellous bone and



**Fig. 3.** Long term radiological follow-up of central peg bone-ingrowth APGC.

integrity of the mantle around pegs.<sup>23</sup>

Correctly addressing glenoid retroversion is another key point in TSA. Biconcave glenoid (Walch B2<sup>118</sup>) is extremely challenging to treat due to asymmetric posterior glenoid wear and posterior humeral head subluxation. Glenoid components implanted in retroversion may have a higher risk of loosening<sup>71,73</sup> and care should be taken in choosing the implant version. Eccentric reaming has been proposed to restore normal version, but it requires the sacrifice of significant amount of anterior glenoid bone<sup>77</sup>; correction  $>15^\circ$  leads to excessive bone loss and medialization.<sup>119</sup> Anyway, restoration of neutral version is not always mandatory: theoretical implant tolerance to retroversion before perforation of glenoid vault cortex is  $19.3 \pm 7.7^\circ$ <sup>120</sup> and obtaining an 80% seating of the implant and  $10\text{--}15^\circ$  of retroversion could be enough to obtain acceptable outcomes,<sup>121,122</sup> so eccentric reaming could be a suitable option in B2 glenoids with  $<30^\circ$  of retroversion. APGCs were implanted in retroverted glenoid without version correction, with a concentric reaming, obtaining acceptable results in patients with moderate deformities.<sup>123</sup> Another option is the use of posteriorly-augmented APGCs, that can fill the gap left by the eroded bone and restore



glenoid version.<sup>78,79</sup> We have limited experience with posteriorly-augmented APGC; we had unfavourable results with thicker augmentations, necessary to correct severe deformities. Priddy et al.<sup>81</sup> reported similar finding with thicker augmentations: they showed 100% presence of glenoid lines, higher Lazarus score and increased risk of reoperation. The last option to treat severe deformities is shifting towards a RTSA. Results of RTSA in B2 glenoids were low rate of revision, high patient satisfaction and functional improvement independent of preoperative glenoid retroversion.<sup>124–126</sup> Because of the inferior clinical outcomes of RTSA compared to TSA in patients with retroverted glenoid,<sup>125</sup> it is advisable to reserve this therapeutic option to older patients. Another clinical scenario where RTSA could be useful is in case of low bone quality, markedly reduced bone stock or presence of geodes that would not guarantee adequate fixation for an APGC.

## 5. Conclusion

Despite many advancements in glenoid component engineering, glenoid loosening is still the most frequent and terrible complication of TSA. Currently, no component provides clearly superior results compared to the others. However, advances in biomechanics and design led to an improvement in duration and outcomes of glenoid components. Various glenoid components have been produced in order to enhance fixation and reduce radiolucencies and loosening, providing the surgeon with a wider choice when performing TSA.

## References

- Flurin PH, Marczuk Y, Janout M, Wright TW, Zuckerman J, Roche CP. Comparison of outcomes using anatomic and reverse total shoulder arthroplasty. *Bull Hosp Jt Dis.* 2013;71(Suppl 2):101–107.
- Kiet TK, Feeley BT, Naimark M, et al. Outcomes after shoulder replacement: comparison between reverse and anatomic total shoulder arthroplasty. *J Shoulder Elbow Surg.* 2015;24(2):179–185. <https://doi.org/10.1016/j.jse.2014.06.039>.
- Cox RM, Padegimas EM, Abboud JA, et al. Outcomes of an anatomic total shoulder arthroplasty with a contralateral reverse total shoulder arthroplasty. *J Shoulder Elbow Surg.* 2018;27(6):998–1003. <https://doi.org/10.1016/j.jse.2017.12.005>.
- Rasmussen JV, Amundsen A, Sørensen AKB, et al. Increased use of total shoulder arthroplasty for osteoarthritis and improved patient-reported outcome in Denmark, 2006–2015: a nationwide cohort study from the Danish Shoulder Arthroplasty Registry. *Acta Orthop.* 2019;90(5):489–494. <https://doi.org/10.1080/17453674.2019.1633759>.
- Lübbecke A, Rees JL, Barea C, Combesure C, Carr AJ, Silman AJ. International variation in shoulder arthroplasty. *Acta Orthop.* 2017;88(6):592–599. <https://doi.org/10.1080/17453674.2017.1368884>.
- Harjula JNE, Paloneva J, Haapakoski J, Kukkonen J, Äärämaa V, Finnish Shoulder Arthroplasty Registry Group. Increasing incidence of primary shoulder arthroplasty in Finland – a nationwide registry study. *BMC Musculoskel Disord.* 2018;19(1):245. <https://doi.org/10.1186/s12891-018-2150-3>.
- Simovitch RW, Friedman RJ, Cheung EV, et al. Rate of improvement in clinical outcomes with anatomic and reverse total shoulder arthroplasty. *J Bone Joint Surg Am.* 2017;99(21):1801–1811. <https://doi.org/10.2106/JBJS.16.01387>.
- Bohsali KI, Wirth MA, Rockwood CA. Complications of total shoulder arthroplasty. *J Bone Joint Surg Am.* 2006;88(10):2279–2292. <https://doi.org/10.2106/JBJS.F.00125>.
- Parada SA, Flurin P-H, Wright TW, et al. Comparison of complication types and rates associated with anatomic and reverse total shoulder arthroplasty. *J Shoulder Elbow Surg.* 2020. <https://doi.org/10.1016/j.jse.2020.07.028>. Published online August 4.
- Somerson JS, Hsu JE, Neradilek MB, Matsen FA. Analysis of 4063 complications of shoulder arthroplasty reported to the US Food and Drug Administration from 2012 to 2016. *J Shoulder Elbow Surg.* 2018;27(11):1978–1986. <https://doi.org/10.1016/j.jse.2018.03.025>.
- Neer CS, Watson KC, Stanton FJ. Recent experience in total shoulder replacement. *J Bone Joint Surg Am.* 1982;64(3):319–337.
- Fox TJ, Cil A, Sperling JW, Sanchez-Sotelo J, Schleck CD, Cofield RH. Survival of the glenoid component in shoulder arthroplasty. *J Shoulder Elbow Surg.* 2009;18(6):859–863. <https://doi.org/10.1016/j.jse.2008.11.020>.
- Torchia ME, Cofield RH, Settergren CR. Total shoulder arthroplasty with the neer prosthesis: long-term results. *J Shoulder Elbow Surg.* 1997;6(6):495–505. [https://doi.org/10.1016/S1058-2746\(97\)90081-1](https://doi.org/10.1016/S1058-2746(97)90081-1).
- Walch G, Young AA, Melis B, Gazielly D, Loew M, Boileau P. Results of a convex-back cemented keeled glenoid component in primary osteoarthritis: multicenter study with a follow-up greater than 5 years. *J Shoulder Elbow Surg.* 2011;20(3):385–394. <https://doi.org/10.1016/j.jse.2010.07.011>.
- Denard PJ, Raiss P, Sowa B, Walch G. Mid- to long-term follow-up of total shoulder arthroplasty using a keeled glenoid in young adults with primary glenohumeral arthritis. *J Shoulder Elbow Surg.* 2013;22(7):894–900. <https://doi.org/10.1016/j.jse.2012.09.016>.
- McLendon PB, Schoch BS, Sperling JW, Sánchez-Sotelo J, Schleck CD, Cofield RH. Survival of the pegged glenoid component in shoulder arthroplasty: part II. *J Shoulder Elbow Surg.* 2017;26(8):1469–1476. <https://doi.org/10.1016/j.jse.2016.12.068>.
- Schoch BS, Wright TW, Zuckerman JD, et al. Glenoid component lucencies are associated with poorer patient-reported outcomes following anatomic shoulder arthroplasty. *J Shoulder Elbow Surg.* 2019;28(10):1956–1963. <https://doi.org/10.1016/j.jse.2019.03.011>.
- Szabo I, Buscayret F, Edwards TB, Nemoz C, Boileau P, Walch G. Radiographic comparison of flat-back and convex-back glenoid components in total shoulder arthroplasty. *J Shoulder Elbow Surg.* 2005;14(6):636–642. <https://doi.org/10.1016/j.jse.2005.05.004>.
- Lacroix D, Murphy LA, Prendergast PJ. Three-dimensional finite element analysis of glenoid replacement prostheses: a comparison of keeled and pegged anchorage systems. *J Biomech Eng.* 2000;122(4):430–436. <https://doi.org/10.1115/1.1286318>.
- Pomwenger W, Entacher K, Resch H, Schuller-Götzburg P. Multi-patient finite element simulation of keeled versus pegged glenoid implant designs in shoulder arthroplasty. *Med Biol Eng Comput.* 2015;53(9):781–790. <https://doi.org/10.1007/s11517-015-1286-7>.
- Becks L, Gaydos C, Stroud N, Roche CP. Optimization of cemented glenoid peg geometry. A comparison of resistance to axial distraction. *Bull Hosp Jt Dis.* 2015;73(Suppl 1):S33–S36.
- Raiss P, Sowa B, Bruckner T, et al. Pressurisation leads to better cement penetration into the glenoid bone: a cadaveric study. *J Bone Joint Surg Br.* 2012;94(5):671–677. <https://doi.org/10.1302/0301-620X.94B5.28831>.
- Choi T, Horodyski M, Struk AM, Sahajpal DT, Wright TW. Incidence of early radiolucent lines after glenoid component insertion for total shoulder arthroplasty: a radiographic study comparing pressurized and unpressurized cementing techniques. *J Shoulder Elbow Surg.* 2013;22(3):403–408. <https://doi.org/10.1016/j.jse.2012.05.041>.
- Edwards TB, Labriola JE, Stanley RJ, O'Connor DP, Elkousy HA, Gartsman GM. Radiographic comparison of pegged and keeled glenoid components using modern cementing techniques: a prospective randomized study. *J Shoulder Elbow Surg.* 2010;19(2):251–257. <https://doi.org/10.1016/j.jse.2009.10.013>.
- Lazarus MD, Jensen KL, Southworth C, Matsen FA. The radiographic evaluation of keeled and pegged glenoid component insertion. *J Bone Joint Surg Am.* 2002;84(7):1174–1182. <https://doi.org/10.2106/00004623-200207000-00013>.
- Kilian CM, Press CM, Smith KM, et al. Radiographic and clinical comparison of pegged and keeled glenoid components using modern cementing techniques: midterm results of a prospective randomized study. *J Shoulder Elbow Surg.* 2017;26(12):2078–2085. <https://doi.org/10.1016/j.jse.2017.07.016>.
- Favard L, Katz D, Colmar M, Benkalfate T, Thomazeau H, Emily S. Total shoulder arthroplasty - arthroplasty for glenohumeral arthropathies: results and complications after a minimum follow-up of 8 years according to the type of arthroplasty and etiology. *Orthop Traumatol Surg Res.* 2012;98(4 Suppl):S41–S47. <https://doi.org/10.1016/j.otsr.2012.04.003>.
- Welsler A, Gohal C, Madden K, et al. A comparison of pegged vs. keeled glenoid components regarding functional and radiographic outcomes in anatomic total shoulder arthroplasty: a systematic review and meta-analysis. *JSES Open Access.* 2019;3(3):136–144. <https://doi.org/10.1016/j.jses.2019.04.002>. e1.
- Wirth MA, Loredo R, Garcia G, Rockwood CA, Southworth C, Iannotti JP. Total shoulder arthroplasty with an all-polyethylene pegged bone-ingrowth glenoid component: a clinical and radiographic outcome study. *J Bone Joint Surg Am.* 2012;94(3):260–267. <https://doi.org/10.2106/JBJS.J.01400>.
- Ho JC, Ricchetti ET, Iannotti JP. Central peg radiolucency progression of an all polyethylene glenoid with hybrid fixation in anatomic total shoulder arthroplasty is associated with clinical failure and reoperation. *J Shoulder Elbow Surg.* 2020. <https://doi.org/10.1016/j.jse.2020.07.039>. Published online August 10.
- Vidil A, Valenti P, Guichoux F, Barthas JH. CT scan evaluation of glenoid component fixation: a prospective study of 27 minimally cemented shoulder arthroplasties. *Eur J Orthop Surg Traumatol.* 2013;23(5):521–525. <https://doi.org/10.1007/s00590-012-1126-5>.
- Groh GI. Survival and radiographic analysis of a glenoid component with a cementless fluted central peg. *J Shoulder Elbow Surg.* 2010;19(8):1265–1268. <https://doi.org/10.1016/j.jse.2010.03.012>.
- Arnold RM, High RR, Grosshans KT, Walker CW, Fehring EV. Bone presence between the central peg's radial fins of a partially cemented pegged all poly glenoid component suggest few radiolucencies. *J Shoulder Elbow Surg.* 2011;20(2):315–321. <https://doi.org/10.1016/j.jse.2010.05.025>.
- Parks DL, Casagrande DJ, Schrupf MA, Harmsen SM, Norris TR, Kelly JD. Radiographic and clinical outcomes of total shoulder arthroplasty with an all-polyethylene pegged bone ingrowth glenoid component: prospective short- to medium-term follow-up. *J Shoulder Elbow Surg.* 2016;25(2):246–255.



- https://doi.org/10.1016/j.jse.2015.07.008.
35. Wijeratna M, Taylor DM, Lee S, Hoy G, Evans MC. Clinical and radiographic results of an all-polyethylene pegged bone-ingrowth glenoid component. *J Bone Joint Surg Am.* 2016;98(13):1090–1096. <https://doi.org/10.2106/JBJS.15.00475>.
  36. Merolla G, Ciaramella G, Fabbri E, Walch G, Paladini P, Porcellini G. Total shoulder replacement using a bone ingrowth central peg polyethylene glenoid component: a prospective clinical and computed tomography study with short- to mid-term follow-up. *Int Orthop.* 2016;40(11):2355–2363. <https://doi.org/10.1007/s00264-016-3255-7>.
  37. Matsen FA, Iannotti JP, Churchill RS, et al. One and two-year clinical outcomes for a polyethylene glenoid with a fluted peg: one thousand two hundred seventy individual patients from eleven centers. *Int Orthop.* 2019;43(2):367–378. <https://doi.org/10.1007/s00264-018-4213-3>.
  38. Merolla G, Chin P, Sasyniuk TM, Paladini P, Porcellini G. Total shoulder arthroplasty with a second-generation tantalum trabecular metal-backed glenoid component: clinical and radiographic outcomes at a mean follow-up of 38 months. *Bone Joint J.* 2016;98-B(1):75–80. <https://doi.org/10.1302/0301-620X.98B1.36620>.
  39. Noyes MP, Meccia B, Spencer EE. Five- to ten-year follow-up with a partially cemented all-polyethylene bone-ingrowth glenoid component. *J Shoulder Elbow Surg.* 2015;24(9):1458–1462. <https://doi.org/10.1016/j.jse.2015.02.018>.
  40. Geraldes DM, Hansen U, Jeffers J, Amis AA. Stability of small pegs for cementless implant fixation. *J Orthop Res.* 2017;35(12):2765–2772. <https://doi.org/10.1002/jor.23572>.
  41. Giori NJ, Beaupré GS, Carter DR. The influence of fixation peg design on the shear stability of prosthetic implants. *J Orthop Res.* 1990;8(6):892–898. <https://doi.org/10.1002/jor.1100080615>.
  42. Geraldes DM, Hansen U, Amis AA. Parametric analysis of glenoid implant design and fixation type. *J Orthop Res.* 2017;35(4):775–784. <https://doi.org/10.1002/jor.23309>.
  43. Frich LH, Jensen NC, Odgaard A, Pedersen CM, Søjbjerg JO, Dalstra M. Bone strength and material properties of the glenoid. *J Shoulder Elbow Surg.* 1997;6(2):97–104. [https://doi.org/10.1016/s1058-2746\(97\)90029-x](https://doi.org/10.1016/s1058-2746(97)90029-x).
  44. De Wilde L, Dayerizadeh N, De Neve F, Basamania C, Van Tongel A. Fully uncemented glenoid component in total shoulder arthroplasty. *J Shoulder Elbow Surg.* 2013;22(10). <https://doi.org/10.1016/j.jse.2013.01.036>. e1–7.
  45. Jaxsens M, Dayerizadeh N, Vandenbosch D, Van Tongel A, De Wilde L. Clinical and radiographic outcomes of an all-polyethylene fluted central peg glenoid component, implanted utilizing an off-label, uncemented technique, at a minimum 5-year follow-up. *J Shoulder Elbow Surg.* 2020;29(11):2292–2298. <https://doi.org/10.1016/j.jse.2020.02.027>.
  46. Boileau P, Avidor C, Krishnan SG, Walch G, Kempf J-F, Molé D. Cemented polyethylene versus uncemented metal-backed glenoid components in total shoulder arthroplasty: a prospective, double-blind, randomized study. *J Shoulder Elbow Surg.* 2002;11(4):351–359. <https://doi.org/10.1067/mse.2002.125807>.
  47. Papadonikolakis A, Matsen FA. Metal-backed glenoid components have a higher rate of failure and fail by different modes in comparison with all-polyethylene components: a systematic review. *J Bone Joint Surg Am.* 2014;96(12):1041–1047. <https://doi.org/10.2106/JBJS.M.00674>.
  48. Katz D, Kany J, Valenti P, Sauzières P, Gleyze P, El Kholi K. New design of a cementless glenoid component in unconstrained shoulder arthroplasty: a prospective medium-term analysis of 143 cases. *Eur J Orthop Surg Traumatol.* 2013;23(1):27–34. <https://doi.org/10.1007/s00590-012-1109-6>.
  49. Vuillermin CB, Trump ME, Barwood SA, Hoy GA. Catastrophic failure of a low profile metal-backed glenoid component after total shoulder arthroplasty. *Int J Shoulder Surg.* 2015;9(4):121–127. <https://doi.org/10.4103/0973-6042.167952>.
  50. Magosch P, Lichtenberg S, Tauber M, Martetschläger F, Habermeyer P. Prospective midterm results of a new convertible glenoid component in anatomic shoulder arthroplasty: a cohort study. *Arch Orthop Trauma Surg.* 2020. <https://doi.org/10.1007/s00402-020-03454-y>. Published online April 23.
  51. Boileau P, Moineau G, Morin-Salvo N, et al. Metal-backed glenoid implant with polyethylene insert is not a viable long-term therapeutic option. *J Shoulder Elbow Surg.* 2015;24(10):1534–1543. <https://doi.org/10.1016/j.jse.2015.02.012>.
  52. Bicknell RT, Liew ASL, Danter MR, et al. The influence of implant articular thickness and glenohumeral conformity on stability of an all-metal glenoid component. *J Shoulder Elbow Surg.* 2007;16(5):631–639. <https://doi.org/10.1016/j.jse.2006.10.014>.
  53. Castagna A, Randelli M, Garofalo R, Maradei L, Giardella A, Borroni M. Mid-term results of a metal-backed glenoid component in total shoulder replacement. *J Bone Joint Surg Br.* 2010;92(10):1410–1415. <https://doi.org/10.1302/0301-620X.92B10.23578>.
  54. Castagna A, Garofalo R. Journey of the glenoid in anatomic total shoulder replacement. *Shoulder Elbow.* 2019;11(2):140–148. <https://doi.org/10.1177/1758573218790119>.
  55. Endrizzi DP, Mackenzie JA, Henry PDG. Early debris formation with a porous tantalum glenoid component: radiographic analysis with 2-year minimum follow-up. *J Bone Joint Surg Am.* 2016;98(12):1023–1029. <https://doi.org/10.2106/JBJS.15.00410>.
  56. Bobyn JD, Stackpool GJ, Hacking SA, Tanzer M, Krygier JJ. Characteristics of bone ingrowth and interface mechanics of a new porous tantalum biomaterial. *J Bone Joint Surg Br.* 1999;81(5):907–914. <https://doi.org/10.1302/0301-620X.81B5.9283>.
  57. Budge MD, Nolan EM, Heisey MH, Baker K, Wiater JM. Results of total shoulder arthroplasty with a monoblock porous tantalum glenoid component: a prospective minimum 2-year follow-up study. *J Shoulder Elbow Surg.* 2013;22(4):535–541. <https://doi.org/10.1016/j.jse.2012.06.001>.
  58. Watson ST, Gudger GK, Long CD, Tokish JM, Tolan SJ. Outcomes of Trabecular Metal-backed glenoid components in anatomic total shoulder arthroplasty. *J Shoulder Elbow Surg.* 2018;27(3):493–498. <https://doi.org/10.1016/j.jse.2017.09.036>.
  59. Chen RE, Brown AM, Greenstein AS, Miller RJ, Mannava S, Voloshin I. Cemented versus uncemented fixation of second generation trabecular metal glenoid components: minimum 5-year outcomes. *J Shoulder Elbow Surg.* 2020. <https://doi.org/10.1016/j.jse.2020.07.025>. Published online August 1.
  60. Grey SG, Wright TW, Flurin P-H, Zuckerman JD, Friedman R, Roche CP. Preliminary results of a novel hybrid cage glenoid compared to an all-polyethylene glenoid in total shoulder arthroplasty. *Bull Hosp Jt Dis.* 2015;73(Suppl 1):S86–S91.
  61. Gulotta LV, Chambers KL, Warren RF, Dines DM, Craig EV. No differences in early results of a hybrid glenoid compared with a pegged implant. *Clin Orthop.* 2015;473(12):3918–3924. <https://doi.org/10.1007/s11999-015-4558-5>.
  62. Friedman RJ, Cheung E, Grey SG, et al. Clinical and radiographic comparison of a hybrid cage glenoid to a cemented polyethylene glenoid in anatomic total shoulder arthroplasty. *J Shoulder Elbow Surg.* 2019;28(12):2308–2316. <https://doi.org/10.1016/j.jse.2019.04.049>.
  63. Nelson CG, Brolin TJ, Ford MC, Smith RA, Azar FM, Throckmorton TW. Five-year minimum clinical and radiographic outcomes of total shoulder arthroplasty using a hybrid glenoid component with a central porous titanium post. *J Shoulder Elbow Surg.* 2018;27(8):1462–1467. <https://doi.org/10.1016/j.jse.2018.01.012>.
  64. Cvetanovich GL, Naylor AJ, O'Brien MC, Waterman BR, Garcia GH, Nicholson GP. Anatomic total shoulder arthroplasty with an inlay glenoid component: clinical outcomes and return to activity. *J Shoulder Elbow Surg.* 2020;29(6):1188–1196. <https://doi.org/10.1016/j.jse.2019.10.003>.
  65. Gunther SB, Lynch TL, O'Farrell D, Calyore C, Rodenhouse A. Finite element analysis and physiologic testing of a novel, inset glenoid fixation technique. *J Shoulder Elbow Surg.* 2012;21(6):795–803. <https://doi.org/10.1016/j.jse.2011.08.073>.
  66. Gagliano JR, Helms SM, Colbath GP, Przestrzelski BT, Hawkins RJ, Desjardins JD. A comparison of onlay versus inlay glenoid component loosening in total shoulder arthroplasty. *J Shoulder Elbow Surg.* 2017;26(7):1113–1120. <https://doi.org/10.1016/j.jse.2017.01.018>.
  67. Gunther SB, Lynch TL. Total shoulder replacement surgery with custom glenoid implants for severe bone deficiency. *J Shoulder Elbow Surg.* 2012;21(5):675–684. <https://doi.org/10.1016/j.jse.2011.03.023>.
  68. Davis DE, Acevedo D, Williams A, Williams G. Total shoulder arthroplasty using an inlay mini-glenoid component for glenoid deficiency: a 2-year follow-up of 9 shoulders in 7 patients. *J Shoulder Elbow Surg.* 2016;25(8):1354–1361. <https://doi.org/10.1016/j.jse.2015.12.010>.
  69. Egger AC, Peterson J, Jones MH, Miniaci A. Total shoulder arthroplasty with nonspherical humeral head and inlay glenoid replacement: clinical results comparing concentric and nonconcentric glenoid stages in primary shoulder arthritis. *JSES Open Access.* 2019;3(3):145–153. <https://doi.org/10.1016/j.jses.2019.07.009>.
  70. Gunther SB, Tran SK. Long-term follow-up of total shoulder replacement surgery with inset glenoid implants for arthritis with deficient bone. *J Shoulder Elbow Surg.* 2019;28(9):1728–1736. <https://doi.org/10.1016/j.jse.2019.01.020>.
  71. Walch G, Moraga C, Young A, Castellanos-Rosas J. Results of anatomic non-constrained prosthesis in primary osteoarthritis with biconcave glenoid. *J Shoulder Elbow Surg.* 2012;21(11):1526–1533. <https://doi.org/10.1016/j.jse.2011.11.030>.
  72. Shapiro TA, McGarry MH, Gupta R, Lee YS, Lee TQ. Biomechanical effects of glenoid retroversion in total shoulder arthroplasty. *J Shoulder Elbow Surg.* 2007;16(3 Suppl):S90–S95. <https://doi.org/10.1016/j.jse.2006.07.010>.
  73. Farron A, Terrier A, Büchler P. Risks of loosening of a prosthetic glenoid implanted in retroversion. *J Shoulder Elbow Surg.* 2006;15(4):521–526. <https://doi.org/10.1016/j.jse.2005.10.003>.
  74. Bryce CD, Davison AC, Okita N, Lewis GS, Sharkey NA, Armstrong AD. A biomechanical study of posterior glenoid bone loss and humeral head translation. *J Shoulder Elbow Surg.* 2010;19(7):994–1002. <https://doi.org/10.1016/j.jse.2010.04.010>.
  75. Nyffeler RW, Sheik R, Atkinson TS, Jacob HAC, Favre P, Gerber C. Effects of glenoid component version on humeral head displacement and joint reaction forces: an experimental study. *J Shoulder Elbow Surg.* 2006;15(5):625–629. <https://doi.org/10.1016/j.jse.2005.09.016>.
  76. Wang T, Abrams GD, Behn AW, Lindsey D, Giori N, Cheung EV. Posterior glenoid wear in total shoulder arthroplasty: eccentric anterior reaming is superior to posterior augment. *Clin Orthop.* 2015;473(12):3928–3936. <https://doi.org/10.1007/s11999-015-4482-8>.
  77. Roche CP, Diep P, Grey SG, Flurin P-H. Biomechanical impact of posterior glenoid wear on anatomic total shoulder arthroplasty. *Bull Hosp Jt Dis.* 2013;71(Suppl 2):S5–S11.
  78. Grey SG, Wright TW, Flurin P-H, Zuckerman JD, Roche CP, Friedman RJ. Clinical and radiographic outcomes with a posteriorly augmented glenoid for

- Walch B glenoids in anatomic total shoulder arthroplasty. *J Shoulder Elbow Surg.* 2020;29(5):e185–e195. <https://doi.org/10.1016/j.jse.2019.10.008>.
79. Das AK, Wright AC, Singh J, Monga P. Does posterior half-wedge augmented glenoid restore version and alignment in total shoulder arthroplasty for the B2 glenoid? *J Clin Orthop Trauma.* 2020;11(Suppl 2):S275–S279. <https://doi.org/10.1016/j.jcot.2020.02.005>.
  80. Ghorraishian M, Abboud JA, Romeo AA, Williams GR, Namdari S. Augmented glenoid implants in anatomic total shoulder arthroplasty: review of available implants and current literature. *J Shoulder Elbow Surg.* 2019;28(2):387–395. <https://doi.org/10.1016/j.jse.2018.08.017>.
  81. Priddy M, Zarezadeh A, Farmer KW, et al. Early results of augmented anatomic glenoid components. *J Shoulder Elbow Surg.* 2019;28(6S):S138–S145. <https://doi.org/10.1016/j.jse.2019.04.014>.
  82. Ho JC, Amini MH, Entezari V, et al. Clinical and radiographic outcomes of a posteriorly augmented glenoid component in anatomic total shoulder arthroplasty for primary osteoarthritis with posterior glenoid bone loss. *J Bone Joint Surg Am.* 2018;100(22):1934–1948. <https://doi.org/10.2106/JBJS.17.01282>.
  83. Matsen FA, Clinton J, Lynch J, Bertelsen A, Richardson ML. Glenoid component failure in total shoulder arthroplasty. *J Bone Joint Surg Am.* 2008;90(4):885–896. <https://doi.org/10.2106/JBJS.G.01263>.
  84. Poppen NK, Walker PS. Forces at the glenohumeral joint in abduction. *Clin Orthop.* 1978;135:165–170.
  85. Apreleva M, Parsons IM, Warner JJ, Fu FH, Woo SL. Experimental investigation of reaction forces at the glenohumeral joint during active abduction. *J Shoulder Elbow Surg.* 2000;9(5):409–417. <https://doi.org/10.1067/mse.2000.106321>.
  86. Buechel FF, Pappas MJ, DePalma AF. “Floating-socket” total shoulder replacement: anatomical, biomechanical, and surgical rationale. *J Biomed Mater Res.* 1978;12(1):89–114. <https://doi.org/10.1002/jbm.820120109>.
  87. Collins D, Tencer A, Sidles J, Matsen F. Edge displacement and deformation of glenoid components in response to eccentric loading. The effect of preparation of the glenoid bone. *J Bone Joint Surg Am.* 1992;74(4):501–507.
  88. Franklin JL, Barrett WP, Jackins SE, Matsen FA. Glenoid loosening in total shoulder arthroplasty. Association with rotator cuff deficiency. *J Arthroplasty.* 1988;3(1):39–46. [https://doi.org/10.1016/s0883-5403\(88\)80051-2](https://doi.org/10.1016/s0883-5403(88)80051-2).
  89. Sarah J, Sanjay G, Sanjay S, et al. Failure mechanism of the all-polyethylene glenoid implant. *J Biomech.* 2010;43(4):714–719. <https://doi.org/10.1016/j.jbiomech.2009.10.019>.
  90. Gregory T, Hansen U, Taillieu F, et al. Glenoid loosening after total shoulder arthroplasty: an in vitro CT-scan study. *J Orthop Res.* 2009;27(12):1589–1595. <https://doi.org/10.1002/jor.20912>.
  91. Nagels J, Valstar ER, Stokdijk M, Rozing PM. Patterns of loosening of the glenoid component. *J Bone Joint Surg Br.* 2002;84(1):83–87. <https://doi.org/10.1302/0301-620x.84b1.11951>.
  92. Chamseddine M, Breden S, Pietschmann MF, Müller PE, Chevalier Y. Peri-prosthetic bone quality affects the fixation of anatomic glenoids in total shoulder arthroplasty: in vitro study. *J Shoulder Elbow Surg.* 2019;28(1):e18–e28. <https://doi.org/10.1016/j.jse.2018.07.012>.
  93. Terrier A, Obrist R, Becce F, Farron A. Cement stress predictions after anatomic total shoulder arthroplasty are correlated with preoperative glenoid bone quality. *J Shoulder Elbow Surg.* 2017;26(9):1644–1652. <https://doi.org/10.1016/j.jse.2017.02.023>.
  94. Clavert P, Bouchaïb J, Kling A, Kempf J-F. Does the cement mantle thickness influence the glenoid loosening in anatomic total shoulder arthroplasty? An experimental study. *J Orthop Sci.* 2019;24(1):81–86. <https://doi.org/10.1016/j.jjos.2018.07.009>.
  95. Sperling JW, Antuna SA, Sanchez-Sotelo J, Schleck C, Cofield RH. Shoulder arthroplasty for arthritis after instability surgery. *J Bone Joint Surg Am.* 2002;84(10):1775–1781. <https://doi.org/10.2106/00004623-200210000-00006>.
  96. Antuna SA, Sperling JW, Cofield RH, Rowland CM. Glenoid revision surgery after total shoulder arthroplasty. *J Shoulder Elbow Surg.* 2001;10(3):217–224. <https://doi.org/10.1067/mse.2001.113961>.
  97. Green A, Norris TR. Shoulder arthroplasty for advanced glenohumeral arthritis after anterior instability repair. *J Shoulder Elbow Surg.* 2001;10(6):539–545. <https://doi.org/10.1067/mse.2001.118007>.
  98. Gregory TM, Sankey A, Augereau B, et al. Accuracy of glenoid component placement in total shoulder arthroplasty and its effect on clinical and radiological outcome in a retrospective, longitudinal, monocentric open study. *PLoS One.* 2013;8(10):e75791. <https://doi.org/10.1371/journal.pone.0075791>.
  99. Norris BL, Lachiewicz PF. Modern cement technique and the survivorship of total shoulder arthroplasty. *Clin Orthop.* 1996;328:76–85. <https://doi.org/10.1097/00003086-199607000-00014>.
  100. Bell SN, Christmas MUSI, Coghlan JA. Proximal humeral osteolysis and glenoid radiolucent lines in an anatomic shoulder arthroplasty: a comparison of a ceramic and a metal humeral head component. *J Shoulder Elbow Surg.* 2020;29(5):913–923. <https://doi.org/10.1016/j.jse.2019.09.032>.
  101. Mueller U, Braun S, Schroeder S, et al. Influence of humeral head material on wear performance in anatomic shoulder joint arthroplasty. *J Shoulder Elbow Surg.* 2017;26(10):1756–1764. <https://doi.org/10.1016/j.jse.2017.05.008>.
  102. Jaxsens M, Walz T, Durchholz H, et al. Towards standardised definitions of shoulder arthroplasty complications: a systematic review of terms and definitions. *Arch Orthop Trauma Surg.* 2017;137(3):347–355. <https://doi.org/10.1007/s00402-017-2635-9>.
  103. Levy JC, Berglund D, Vakharia R, et al. Midterm results of anatomic total shoulder arthroplasty with a third-generation implant. *J Shoulder Elbow Surg.* 2019;28(4):698–705. <https://doi.org/10.1016/j.jse.2018.08.049>.
  104. Molè D, Roche O, Riand N, Levigne C, Walch G. Cemented glenoid components: results in osteoarthritis and rheumatoid arthritis. In: Walch G, Boileau P, eds. *Shoulder Arthroplasty*. Springer; 1999:163–171.
  105. Sperling JW, Cofield RH, Rowland CM. Neer hemiarthroplasty and Neer total shoulder arthroplasty in patients fifty years old or less. Long-term results. *J Bone Joint Surg Am.* 1998;80(4):464–473. <https://doi.org/10.2106/00004623-199804000-00002>.
  106. Sperling JW, Cofield RH, O'Driscoll SW, Torchia ME, Rowland CM. Radiographic assessment of ingrowth total shoulder arthroplasty. *J Shoulder Elbow Surg.* 2000;9(6):507–513. <https://doi.org/10.1067/mse.2000.109384>.
  107. Gruen TA, McNeice GM, Amstutz HC. “Modes of failure” of cemented stem-type femoral components: a radiographic analysis of loosening. *Clin Orthop.* 1979;141:17–27.
  108. Walch G, Badet R, Boulahia A, Khoury A. Morphologic study of the glenoid in primary glenohumeral osteoarthritis. *J Arthroplasty.* 1999;14(6):756–760. [https://doi.org/10.1016/s0883-5403\(99\)90232-2](https://doi.org/10.1016/s0883-5403(99)90232-2).
  109. Coskun N, Karaali K, Cevikol C, Demirel BM, Sindel M. Anatomical basics and variations of the scapula in Turkish adults. *Saudi Med J.* 2006;27(9):1320–1325.
  110. Khan R, Satyapal KS, Lazarus L, Naidoo N. An anthropometric evaluation of the scapula, with emphasis on the coracoid process and glenoid fossa in a South African population. *Heliyon.* 2020;6(1):e03107. <https://doi.org/10.1016/j.heliyon.2019.e03107>.
  111. Ohl X, Billuart F, Lagacé P-Y, Gagey O, Hagemester N, Skalli W. 3D morphometric analysis of 43 scapulae. *Surg Radiol Anat.* 2012;34(5):447–453. <https://doi.org/10.1007/s00276-012-0933-z>.
  112. Lovse LJ, Culliton K, Pollock JW, Derome P, Louati H, Lapner P. Glenoid exposure in shoulder arthroplasty: the role of soft tissue releases. *JSES Int.* 2020;4(2):377–381. <https://doi.org/10.1016/j.jseint.2020.01.008>.
  113. Merolla G, Paladini P, Campi F, Porcellini G. Efficacy of anatomical prostheses in primary glenohumeral osteoarthritis. *Chir Organi Mov.* 2008;91(2):109–115. <https://doi.org/10.1007/s12306-007-0019-y>.
  114. Wirth MA, Korvick DL, Basamania CJ, Toro F, Aufdemorte TB, Rockwood CA. Radiologic, mechanical, and histologic evaluation of 2 glenoid prosthesis designs in a canine model. *J Shoulder Elbow Surg.* 2001;10(2):140–148. <https://doi.org/10.1067/mse.2001.112021>.
  115. Kasten P, Pape G, Raiss P, et al. Mid-term survivorship analysis of a shoulder replacement with a keeled glenoid and a modern cementing technique. *J Bone Joint Surg Br.* 2010;92(3):387–392. <https://doi.org/10.1302/0301-620X.92B3.23073>.
  116. Young AA, Walch G. Fixation of the glenoid component in total shoulder arthroplasty: what is “modern cementing technique”? *J Shoulder Elbow Surg.* 2010;19(8):1129–1136. <https://doi.org/10.1016/j.jse.2010.07.010>.
  117. Nyffeler RW, Meyer D, Sheikh R, Koller BJ, Gerber C. The effect of cementing technique on structural fixation of pegged glenoid components in total shoulder arthroplasty. *J Shoulder Elbow Surg.* 2006;15(1):106–111. <https://doi.org/10.1016/j.jse.2005.05.002>.
  118. Bercik MJ, Kruse K, Yalozis M, Gauci M-O, Chaoui J, Walch G. A modification to the Walch classification of the glenoid in primary glenohumeral osteoarthritis using three-dimensional imaging. *J Shoulder Elbow Surg.* 2016;25(10):1601–1606. <https://doi.org/10.1016/j.jse.2016.03.010>.
  119. Gillespie R, Lyons R, Lazarus M. Eccentric reaming in total shoulder arthroplasty: a cadaveric study. *Orthopedics.* 2009;32(1):21. <https://doi.org/10.3928/01477447-20090101-07>.
  120. Ting FSH, Poon PC. Perforation tolerance of glenoid implants to abnormal glenoid retroversion, anteversion, and medialization. *J Shoulder Elbow Surg.* 2013;22(2):188–196. <https://doi.org/10.1016/j.jse.2011.12.009>.
  121. Orvets ND, Chamberlain AM, Patterson BM, et al. Total shoulder arthroplasty in patients with a B2 glenoid addressed with corrective reaming. *J Shoulder Elbow Surg.* 2018;27(6S):S58–S64. <https://doi.org/10.1016/j.jse.2018.01.003>.
  122. DeVito P, Agyeman KD, Judd H, et al. Outcomes of anatomic total shoulder arthroplasty in patients with excessive glenoid retroversion: a case-control study. *J Shoulder Elbow Surg.* 2019;28(10):1948–1955. <https://doi.org/10.1016/j.jse.2019.03.012>.
  123. Grantham WJ, Dekker TJ, Lacheta L, et al. Total shoulder arthroplasty outcomes after noncorrective, concentric reaming of B2 glenoids. *JSES Int.* 2020;4(3):644–648. <https://doi.org/10.1016/j.jseint.2020.04.006>.
  124. Mizuno N, Denard PJ, Raiss P, Walch G. Reverse total shoulder arthroplasty for primary glenohumeral osteoarthritis in patients with a biconcave glenoid. *J Bone Joint Surg Am.* 2013;95(14):1297–1304. <https://doi.org/10.2106/JBJS.L00820>.
  125. Alemtorn-Geli E, Wanderman NR, Assenmacher AT, Sperling JW, Cofield RH, Sánchez-Sotelo J. Anatomic total shoulder arthroplasty with posterior capsular plication versus reverse shoulder arthroplasty in patients with biconcave glenoids: a matched cohort study. *J Orthop Surg.* 2018;26(2). <https://doi.org/10.1177/2309499018768570>, <https://doi.org/10.2309499018768570>.
  126. McFarland EG, Huri G, Hyun YS, Petersen SA, Srikanth U. Reverse total shoulder arthroplasty without bone-grafting for severe glenoid bone loss in patients with osteoarthritis and intact rotator cuff. *J Bone Joint Surg Am.* 2016;98(21):1801–1807. <https://doi.org/10.2106/JBJS.15.01181>.



Contents lists available at ScienceDirect

## Journal of Arthroscopy and Joint Surgery

journal homepage: [www.elsevier.com/locate/jajs](http://www.elsevier.com/locate/jajs)

Review article

## Navigation in Shoulder Arthroplasty

Andrew P. Dekker\*, Amol A. Tambe

Royal Derby Hospital, Uttoxeter Road, Derby, DE22 3NE, United Kingdom



## ARTICLE INFO

## Article history:

Received 30 October 2020

Received in revised form

3 December 2020

Accepted 6 December 2020

Available online 9 December 2020

## Keywords:

Shoulder

Arthroplasty

Computer aided surgery

## ABSTRACT

Proper component positioning is a critical and challenging step in shoulder arthroplasty. Novel computer-assisted surgical techniques have been shown to improve the accuracy and reliability of surgical results. However, the long-term clinical benefits of navigated surgery are yet to be proven.

*Level of evidence:* 3a; Review of case-control studies.

© 2020 International Society for Knowledge for Surgeons on Arthroscopy and Arthroplasty. Published by Elsevier, a division of RELX India, Pvt. Ltd. All rights reserved.

## 1. Introduction

Proper component positioning is a critical and challenging step in shoulder arthroplasty. The operating surgeon must use their knowledge of the patients' anatomy and orientation from bony landmarks as reference points. Similar to a "global positioning system" based car navigation providing visual instructions to a driver by displaying the location of their car on a map, a computer-assisted navigation system provides the surgeon with real-time feedback about the instrument and component position through a virtual scene. The ultimate aim is to improve the ability to produce accurate and reproducible results.

## 2. Development of navigation systems

Following the development of computed tomography (CT) scanning and computer processing, by the 1990s image-guided spinal pedicle screw placement<sup>1</sup> as well as knee arthroplasty systems<sup>2</sup> were being published. If a CT scan is our map, then it is logical that novel systems are developed to provide a means to navigate this map. Without such a system, the surgeon has to rely on their experience to match the intraoperative findings with preoperative imaging. The surgeon must use their own internal compass and rely on their knowledge of anatomy and understanding of deformity. Jigs and guides can be used, or simply palpating and 'eyeballing'. Bony landmarks may be missing in deformed joints and difficult to

visualise with limited exposure. Traditional techniques rely on surgeon experience and intuition, which takes years of experience to develop.

The principles of navigation are for a specialised computer to correlate cross-sectional imaging with the orientation of the patient in space. Systems involve the use of markers (which in some cases are electronic) placed on anatomic landmarks and either referenced to intraoperative CT or fluoroscopy-based imaging or recognised by an optical camera. This data is computed in conjunction with a preoperative or intraoperative CT scan to generate a virtual model.<sup>3</sup> The resulting feedback can be used to guide the surgical instruments or place restraint on positioning within a predetermined trajectory; for example, when placing navigated pedicle screws in the field of spinal surgery, some systems physically prevent the surgeon from placing hardware outside of the pedicle bone. Feedback is displayed on a monitor (Fig. 1).

## 3. benefits of Navigation in Shoulder Arthroplasty

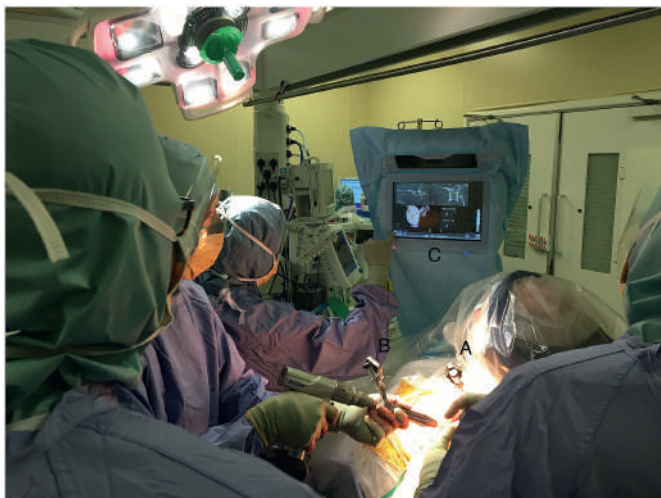
As early as 2008, the merits of navigation in shoulder surgery were being discussed in shoulder journals. The real-time feedback on instrument angulation, bony geometry and calculated resection was found to be accurate and safe with regard to the possibility of iatrogenic fracture or neurovascular injury caused by navigation trackers.<sup>4</sup>

Realistically, it is only possible to have one good shot at placing the implant pegs or screws on the glenoid; thus, navigation lends itself very nicely to shoulder arthroplasty. It allows the best part of the glenoid vault to be harnessed for a primary fixation, thus

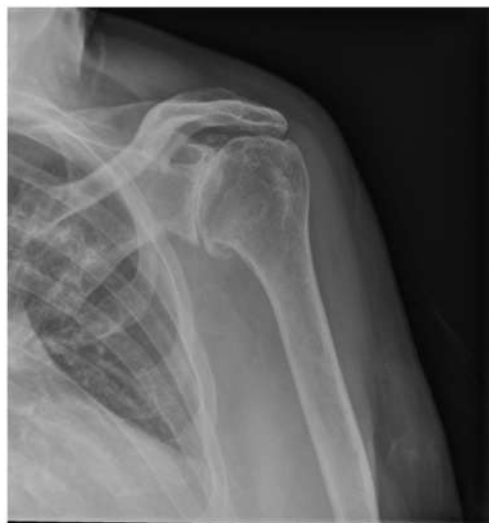\* Corresponding author.

E-mail address: [andrew.dekker@nhs.net](mailto:andrew.dekker@nhs.net) (A.P. Dekker).





**Fig. 1.** An intraoperative photograph. A = Navigation tracker registered to patient. B = Navigation tracker registered to drill. C = Monitor displaying instrument position and three-dimensional target.



**Fig. 2.** Preoperative radiograph for case 1.

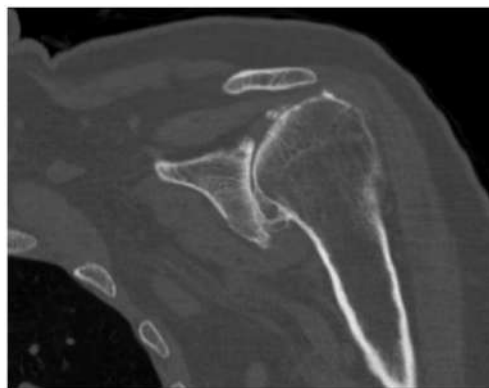
reducing the chances of glenoid side failure. This was highlighted by Parsons et al., in 2009 and DiStefano in 2011.<sup>56</sup> In the setting of reverse shoulder arthroplasty, fixing the baseplate with the longest screw lengths possible within the thickest cortical regions of the glenoid vault is critical, especially during revision surgery and cases of poor bone stock.

Malpositioning of the glenoid component during implantation is a risk factor for glenoid failure. Glenoid placement in total shoulder replacement is complicated by the often poor bone stock and as a consequence the altered anatomy of the glenoid, the lack of reliable static anatomic landmarks and the limited exposure of the shoulder. The proper insertion of the glenoid component is crucial in total shoulder arthroplasty. Malalignment leads to eccentric loading, shift of vector forces, increased contact pressure and rim-loading, increased stress at the implant-bone or bone-cement interface and the glenoid bone stock, and in the long-term, to an increased rate of glenoid failure. An additional risk with posterior and superior drilling is extraosseous screw placement causing injury to the suprascapular nerve.<sup>7</sup> Venne et al. found similar entry points for screws and baseplate but greater accuracy of screw and baseplate endpoints with navigation in a comparative study.<sup>8</sup>

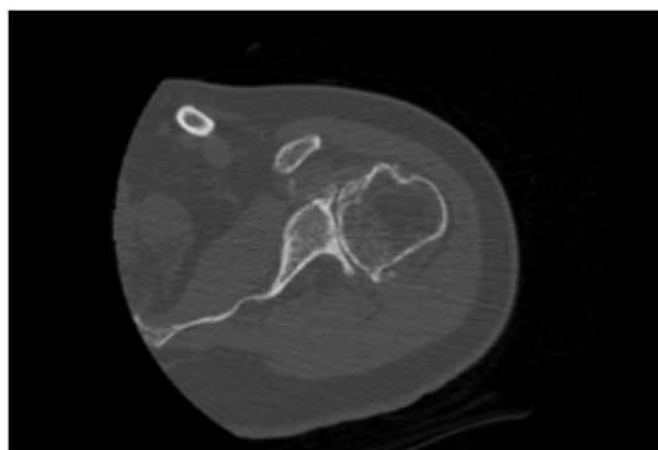
#### 4. Evidence for Navigation in Shoulder Arthroplasty

Preoperative planning using cross-sectional imaging is commonly used and routine in some centres as it is considered best practice. No additional radiation exposure is therefore incurred by using navigation.<sup>9</sup> Without intraoperative feedback however, surgeons are less likely to be able to consistently implement the planned position of components.<sup>10</sup> Intraoperative navigation was developed using cross-sectional imaging to improve implant positioning and therefore, hopefully improve implant survival.

Very few comparative studies are available within the published literature. With regard to reverse shoulder arthroplasty, Verborgt et al compared the positioning of the glenoid baseplate in 14 paired cadaveric specimens using CT and macroscopic dissection.<sup>11</sup> Those specimens in the navigated group had a more accurate and precise version than the standard instrumentation group (3.1° versus 8.7°) with a reduced range of error (8° versus 12°). Additionally, the navigated group had no central peg perforations or malpositioned inferior screws. Nashikkar et al. conducted a case-control study of



**Fig. 3.** Preoperative coronal computed tomography image for case 1.



**Fig. 4.** Preoperative axial computed tomography image for case 1.

27 navigated and 23 conventional reverse shoulder arthroplasty cases.<sup>12</sup> A longer screw purchase length was seen navigated cases (20 mm versus 15 mm for anterior screws and 20 mm versus 13 mm for posterior screws). There was also a reduced incidence of inadequate screw purchase and central cage perforation (17.7% versus



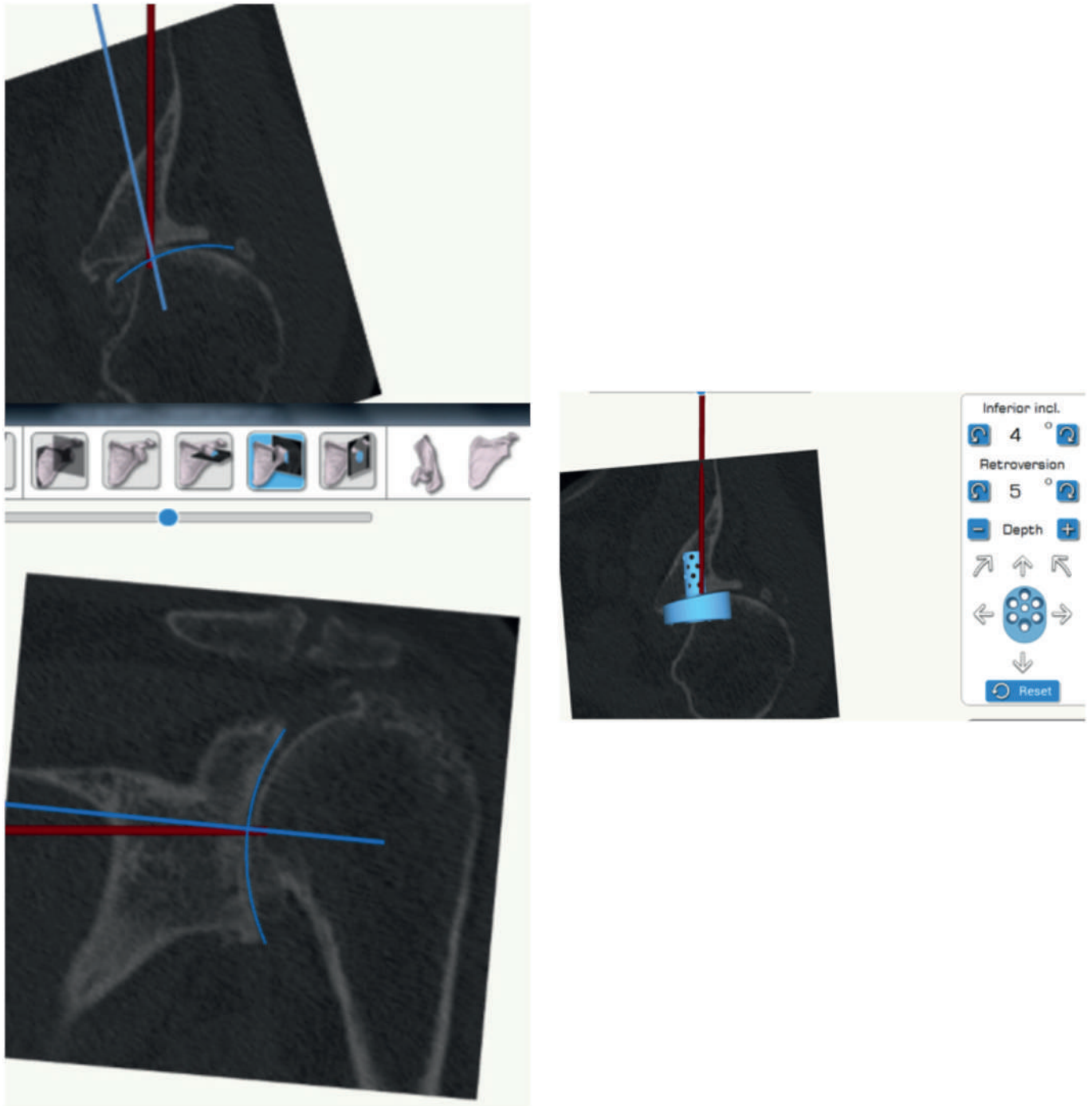


Fig. 5. a–d. Preoperative planning for case 1.

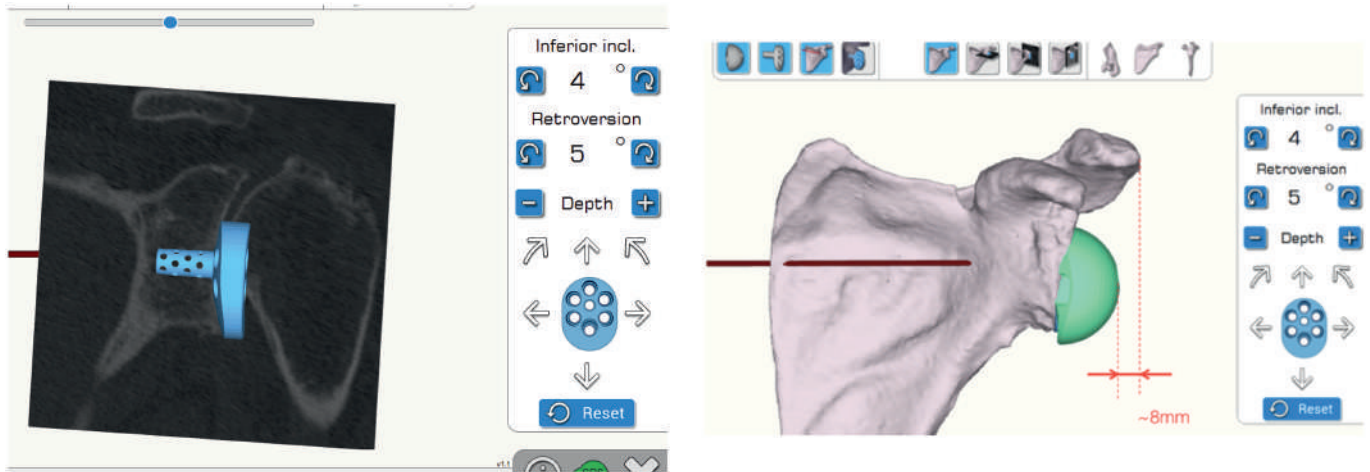


Fig. 5. (continued).

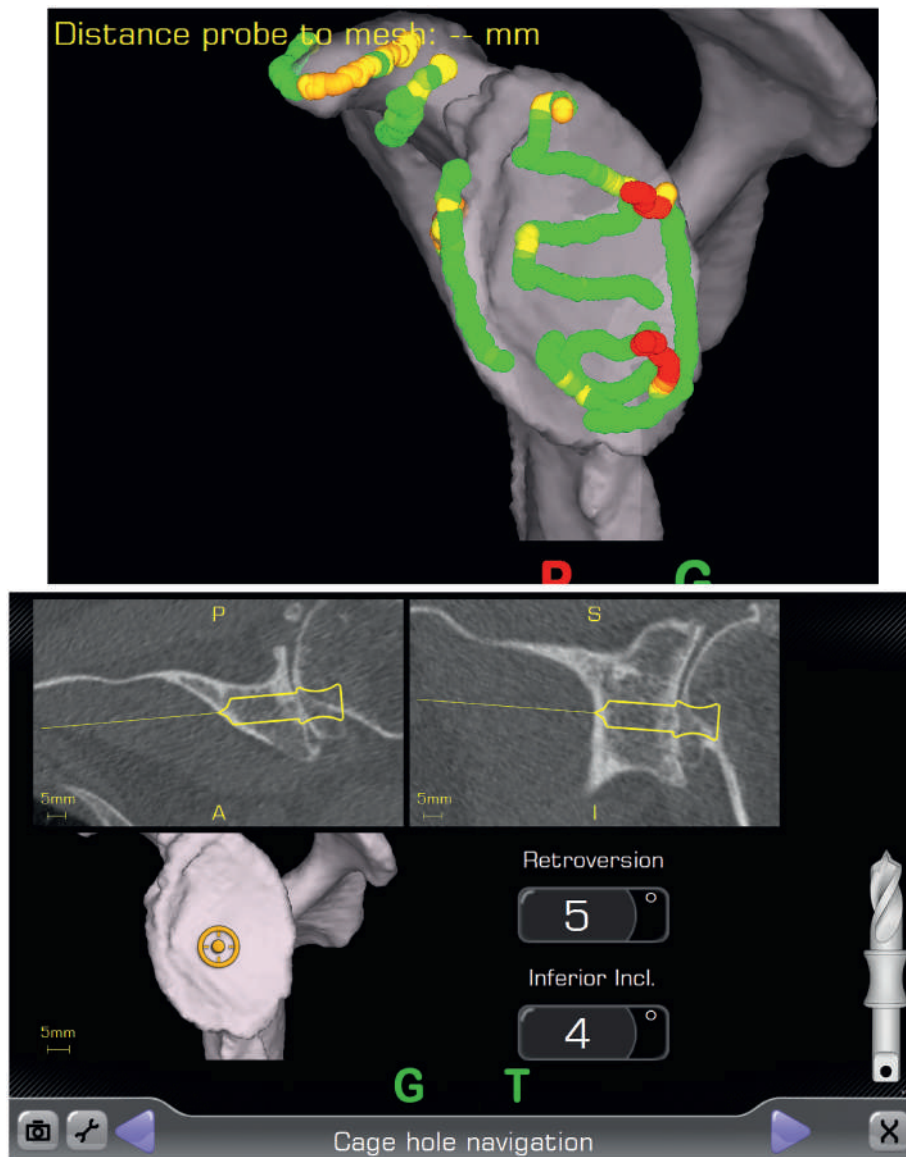
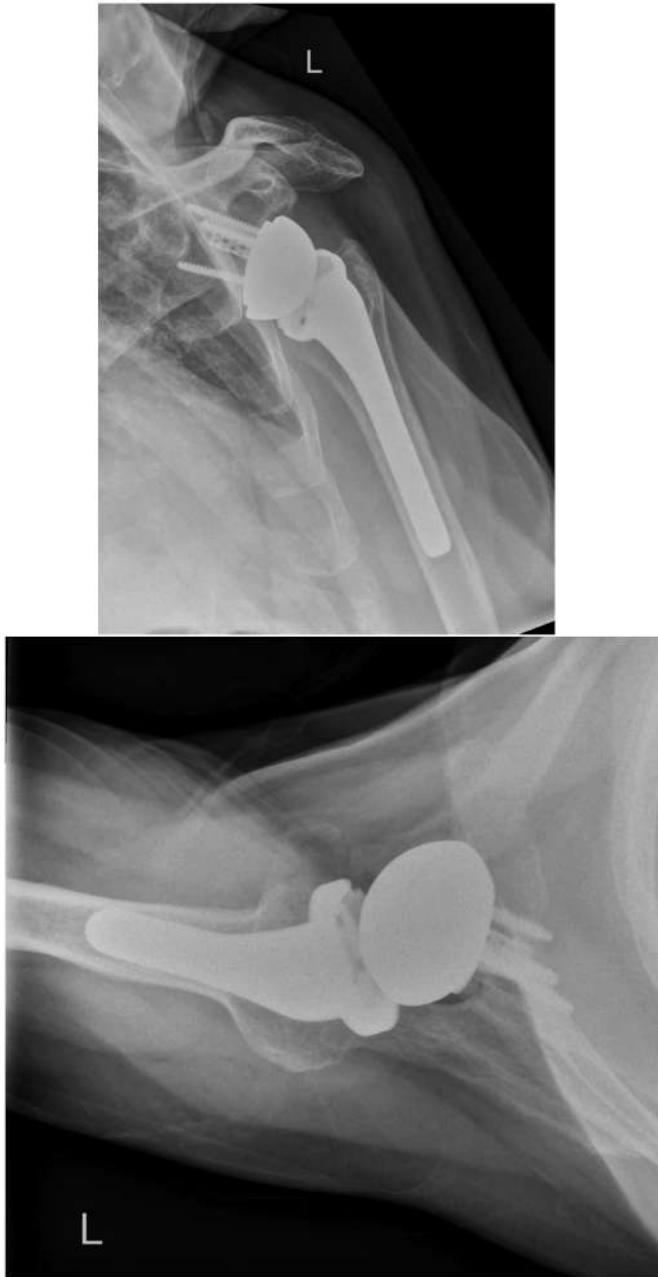

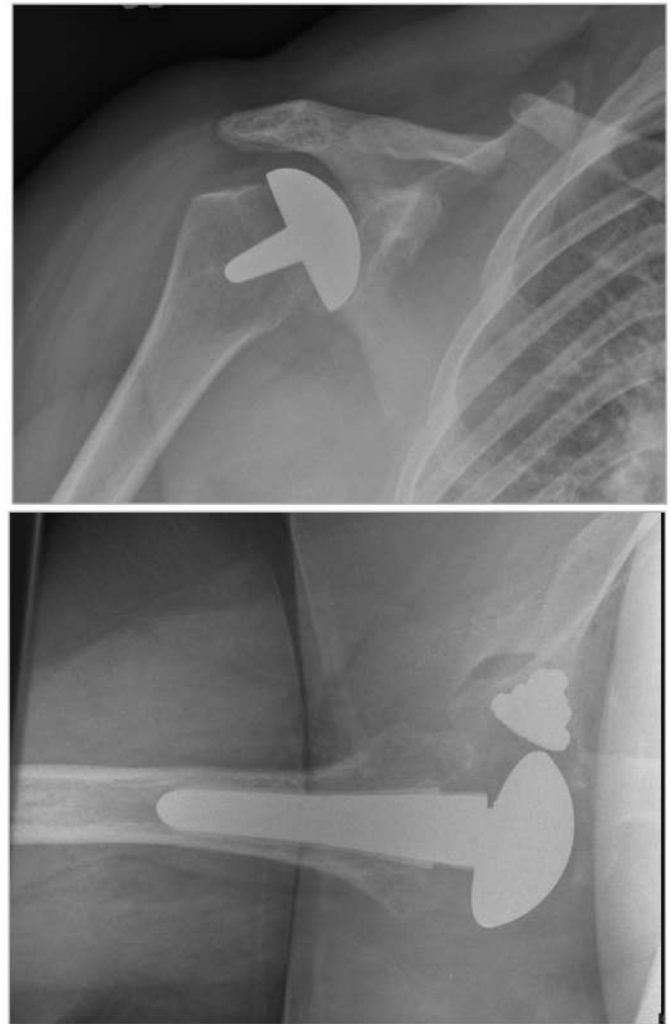Fig. 6. a. Intraoperative image for case 1. The face of the glenoid is registered to the navigation software by the operating surgeon (feedback displayed by coloured dots).6 b. Intraoperative image for case 1. The drill tip position and projected depth within the glenoid vault is displayed to the operating surgeon in real time.



**Fig. 7.** a. Postoperative radiograph for case 1; anteroposterior view. 7 b. Postoperative radiograph for case 1; axillary view.

52.4%). In a separate study by these authors, navigated cases were found to utilize more than twice as many augmented glenoid components and had a greater proportion of components positioned in neutral alignment with respect to inclination and version than the conventional group.<sup>13</sup> The authors concluded that navigation allowed a greater capacity to replicate the surgical plan than conventional techniques.

With regard to anatomic shoulder arthroplasty, we are aware of only one comparative study. Kircher et al. compared two randomised groups of 10 patients with osteoarthritis of the shoulder with or without navigation using the Praxim nano station system (Praxim Grenoble, France) and Arthrex Eclipse implant. The authors



**Fig. 8.** a. Preoperative radiograph for case 2; anteroposterior view. b. Preoperative radiograph for case 2; axillary view.

found the navigated group had a longer operation time ( $169.5 \pm 15.2$  min versus  $138 \pm 18.4$  min in the control group). However, improved accuracy of glenoid positioning in the transverse plane was seen in the navigated patients, with postoperative retroversion  $3.7^\circ \pm 6.3^\circ$  versus  $10.9^\circ \pm 6.8^\circ$  in the control group as measured by CT.<sup>14</sup>

Greene et al. conducted a study of 94 sawbones models with artificial soft tissues and compared the perceived neutral axis of the glenoid and ability to reproduce a preoperative plan to implant a radio-opaque PEEK implant using postoperative CT imaging.<sup>15</sup> The variability in the perception of the neutral axis of the glenoid relative to preoperative planning was significantly lower in the navigated group ( $\pm 1.9^\circ$  and  $\pm 1.2^\circ$  for version and inclination, respectively, versus  $\pm 5.5^\circ$  and  $\pm 4.8^\circ$ ).

We are not aware of any published studies reporting use of navigation in revision arthroplasty, although this technology has clear applications in these challenging cases. This may be due to the difficulty in conducting a comparative study due to heterogeneity of these cases as well as the difficulty in accurately preoperatively planning due to the metal artefact created by in-situ implants.

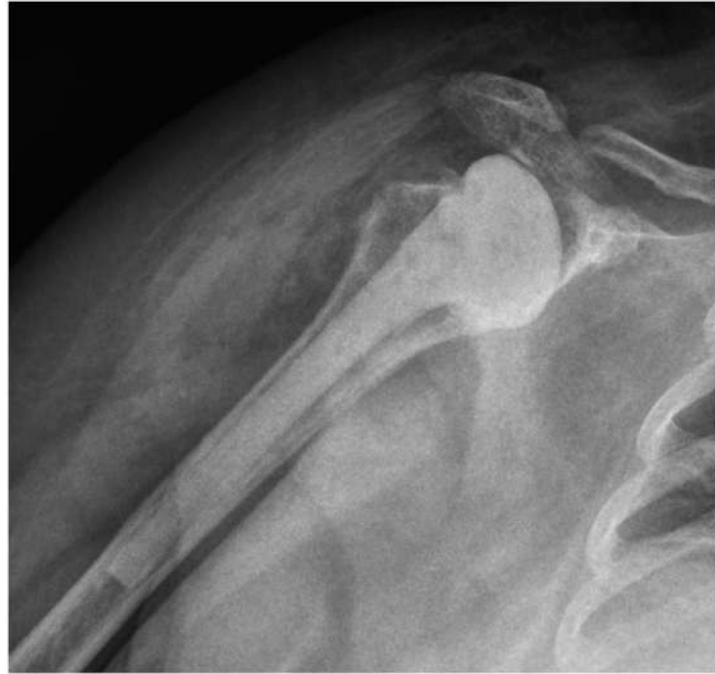

Fig. 9. Preoperative radiograph for case 2; cement spacer.

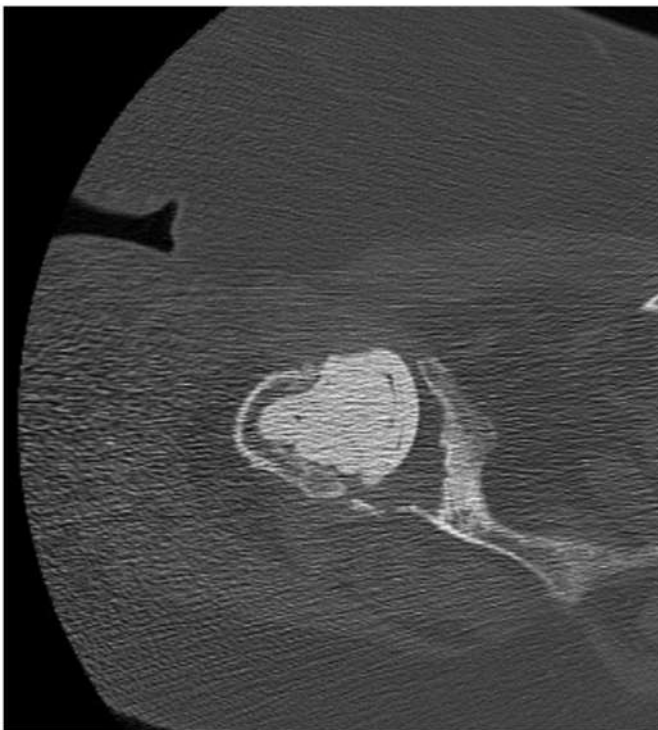


Fig. 10. Preoperative axial computed tomography image for case 2; cement spacer.

## 5. Indications

Navigation improves the accuracy of placement of the glenoid in reverse shoulder arthroplasty. Glenoid component version, tilt, peg position and screw placement have been proven to be more accurate by several studies. Selection for use in cases of abnormal glenoid anatomy and bone loss, especially in the revision setting might

avoid the need for augmenting with bone graft or patient specific implants. Navigation has also been shown to be useful as a teaching tool without being detrimental to the trainees' learning curve,<sup>16</sup> as well as helping develop an awareness of surgical errors.<sup>17</sup>

## 6. Case example 1

A 76-year-old male with a biconcave glenoid, 17° retroverted and 5° inferior inclined. Preoperative imaging can be seen in Figs. 2–4. The navigation system 'GPS' (Exactech, Gainesville, FL), was used. By reaming the glenoid by 2 mm from the anterior cortex and using a posteriorly augmented baseplate, were able to correct the retroversion from 17° to 5° and the inferior inclination was accepted, as seen in the planning stages (Fig. 5) and intraoperative stages (Fig. 6). The postoperative radiographs are seen in Fig. 7.

## 7. Case example 2

A 69-year-old female with an anatomic shoulder arthroplasty in situ with prosthetic joint infection and failed subscapularis tendon evidenced by anterior subluxation of the humeral component on the glenoid (Fig. 8). This was treated initially with removal of the implant, washout, cement spacer implantation and a course of antibiotics (Fig. 9). Following eradication of infection, a CT scan revealed a severe combined defect as per the Antuna classification (Fig. 10).<sup>18</sup> 3D planning using the Exactech software revealed severe bone loss and glenoid medialisation requiring an extended glenoid cage and bone graft (Fig. 11, Fig. 12). Intraoperative navigation allowed calculation of the bone graft size and appropriate lateral positioning of the baseplate as well as permitting screw placement within the best native glenoid bone. This facilitated good screw hold and stable baseplate implantation. Postoperative functional range of movement was excellent in this complex case. Radiographs can be seen in Fig. 13.



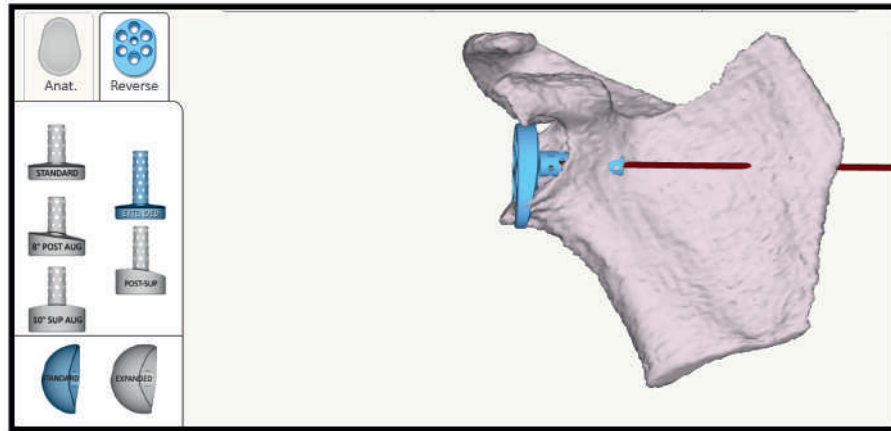


Fig. 11. Preoperative planning for case 2; extended cage +10 mm displayed.



Fig. 12. Intraoperative photograph for case 2; glenoid implant with bone graft.

## 8. Limitations

Despite the appeal of improved component positioning, there are some disadvantages to using navigation. Operating time has been shown to be longer,<sup>14</sup> however, a recent study by Wang et al. found the learning curve flattened rapidly, with similar times with and without navigation after 8 procedures in a single surgeon series.<sup>19</sup> The navigation system relies on accurately registered anatomic landmarks, therefore if a tracking device is malpositioned, malregistered or becomes loosened then there is a risk of the surgeon being displayed incorrect data. There is therefore a learning curve and the surgeon must compare the feedback being displayed by the technology to their own internal compass just as one can be led astray by satellite navigation when driving if attention is not paid to the surroundings.

## 9. Navigation versus patient specific instrumentation

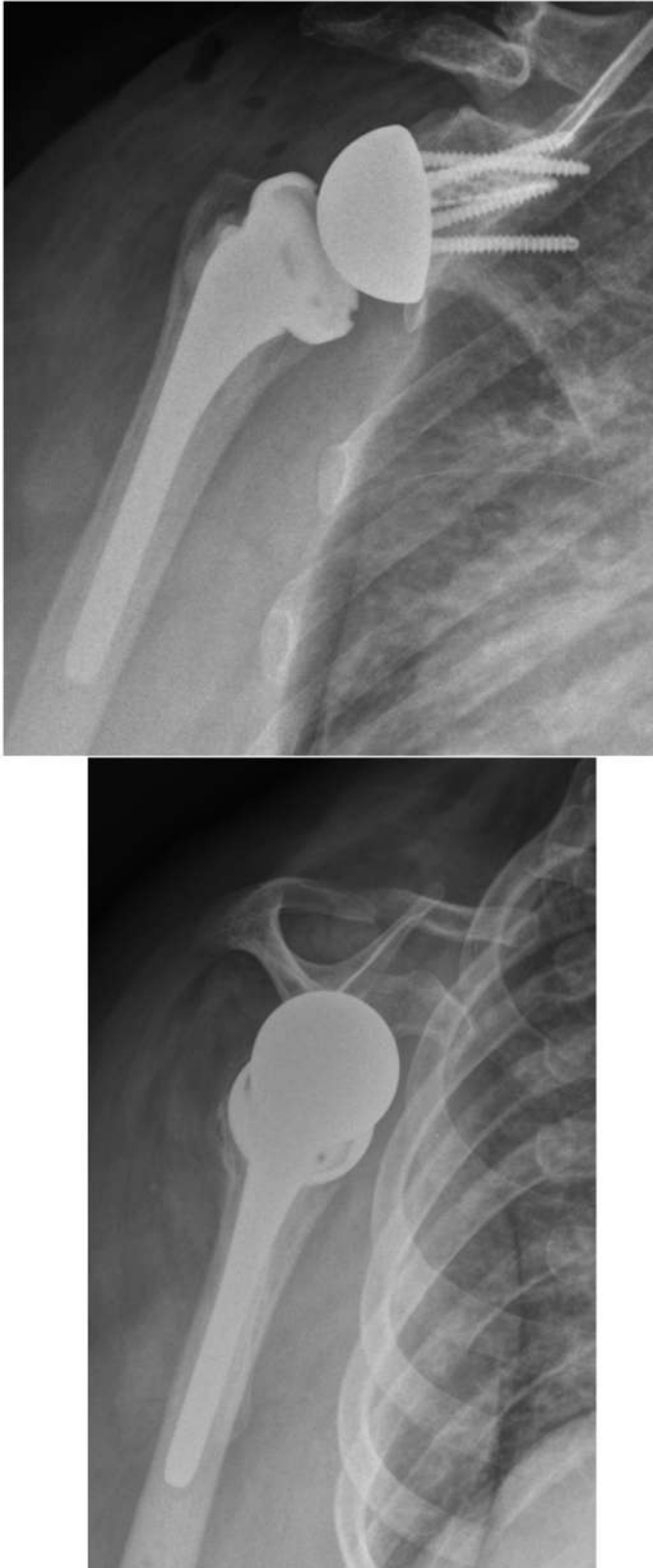
An alternative solution to improve component positioning both in anatomic and reverse total shoulder arthroplasty is the use of patient-specific instrumentation (PSI). This technique involves the production of bespoke guides based on preoperative CT imaging. A three-dimensional model of the patient's glenoid is created and the corresponding guides are then placed on the bone surface during the surgical procedure to position the central guide pin for drilling and reaming. Depending on the implant system, the length and orientation of screws may also be guided. These systems do however have pitfalls; the guides must be placed accurately on the bony surface with adequate soft tissue clearance so that they sit on the glenoid in the exact same orientation as planned. Additionally, if the patient anatomy changes since the time of the preoperative CT scan; for example, due to worsening of the destructive arthritic change during the time taken to template, manufacture and acquire the custom device, the guides may not fit and therefore may mislead the surgeon. Although more simplistic than navigation in its implementation during the surgical procedure therefore, vigilance is essential to confirm the suggested positioning is consistent with the preoperative plan.

PSI has been shown to aid the accurate placement of glenoid components for both anatomic and reverse shoulder arthroplasty in non-comparative studies.<sup>20–22</sup> Improved accuracy was reported in randomised studies by Throckmorton et al.<sup>23</sup> (5° deviation from the intended position with PSI versus 8° with standard instrumentation) and Hendel et al. (4.3° deviation from the intended position with PSI versus 6.9° with standard instrumentation).<sup>24</sup> PSI also comes at increased cost and complexity, although no studies have quantified this.

A recent meta analysis of navigation and PSI by Burns et al., in 2019 showed no superiority of one technique over the other.<sup>25</sup>

## 10. The future

Navigation in shoulder arthroplasty may not be commonplace; however, it has been available for over a decade. Navigation is even being developed for use in the placement of suture anchors for rotator cuff repair.<sup>26</sup> The technology is evolving and novel



**Fig. 13.** a. Postoperative radiograph for case 2; anteroposterior view. b. Postoperative radiograph for case 2; axillary view.

implementations in the future include augmented reality headsets to replace computer monitors.<sup>27</sup> Use as a teaching tool is another application.

## 11. Summary

The long-term clinical benefits of navigated surgery are yet to be proven; however, the proven benefits of accuracy and precision are appealing. The operating surgeon must balance potential clinical benefit against the possible increased operating time and need for additional resources.

## Funding

Not funded.

## Declaration of competing interest

No conflicts of interest to declare.

## Acknowledgements

Special thanks to Danielle Lavender for providing writing assistance and proofreading this article. We acknowledge that there has been no funding for this project in any form.

## References

1. Kalfas IH, Kormos DW, Murphy MA, et al. Application of frameless stereotaxy to pedicle screw fixation of the spine. *J Neurosurg.* 1995;83(4):641–647.
2. Saragaglia D, Picard F, Leitner F. An 8- to 10-year follow-up of 26 computer-assisted total knee arthroplasties. *Saragaglia D. Orthopedics.* 2007;30:121–123.
3. Karkenny AJ, Mendelis JR, Geller DS, Gomez JA. The role of intraoperative navigation in orthopaedic surgery. *J Am Acad Orthop Surg.* 2019;27(19):e849–e858.
4. Edwards TB, Gartsman GM, O'Connor DP, Sarin VK. Safety and utility of computer-aided shoulder arthroplasty. *J Shoulder Elbow Surg.* 2008;17(3):503–508.
5. Parsons BO, Gruson KI, Accousti KJ, Klug RA, Flatow EL. Optimal rotation and screw positioning for initial glenosphere baseplate fixation in reverse shoulder arthroplasty. *J Shoulder Elbow Surg.* 2009;18(6):886–891.
6. DiStefano JG, Park AY, Nguyen TQ, Diederichs G, Buckley JM, Montgomery 3rd WH. Optimal screw placement for base plate fixation in reverse total shoulder arthroplasty. *J Shoulder Elbow Surg.* 2011;20(3):467–476.
7. Leschinger T, Hackl M, Buess E, et al. The risk of suprascapular and axillary nerve injury in reverse total shoulder arthroplasty: an anatomic study. *Injury.* 2017;48(10):2042–2049.
8. Venne G, Rasquinha BJ, Pichora D, Ellis RE, Bicknell R. Comparing conventional and computer-assisted surgery baseplate and screw placement in reverse shoulder arthroplasty. *J Shoulder Elbow Surg.* 2015;24(7):1112–1119.
9. Werner BS, Hudek R, Burkhart KJ, Gohlke F. The influence of three-dimensional planning on decision-making in total shoulder arthroplasty. *J Shoulder Elbow Surg.* 2017;26(8):1477–1483.
10. Schoch BS, Haupt E, Leonor T, Farmer KW, Wright TW, King JJ. Computer navigation leads to more accurate glenoid targeting during total shoulder arthroplasty compared with 3-dimensional preoperative planning alone. *J Shoulder Elbow Surg.* 2020;29(11):2257–2263. <https://doi.org/10.1016/j.jse.2020.03.014>.
11. Verborgt O, De Smedt T, Vanhees M, Clockaerts S, Parizel PM, Van Glabbeek F. Accuracy of placement of the glenoid component in reversed shoulder arthroplasty with and without navigation. *J Shoulder Elbow Surg.* 2011;20(1):21–26.
12. Nashikkar PS, Scholes CJ, Haber MD. Role of intraoperative navigation in the fixation of the glenoid component in reverse total shoulder arthroplasty: a clinical case-control study. *J Shoulder Elbow Surg.* 2019;28(9):1685–1691.
13. Nashikkar PS, Scholes CJ, Haber MD. Computer navigation re-creates planned glenoid placement and reduces correction variability in total shoulder arthroplasty: an in vivo case-control study. *J Shoulder Elbow Surg.* 2019;28(12):e398–e409.
14. Kircher J, Wiedemann M, Magosch P, Lichtenberg S, Habermeyer P. Improved accuracy of glenoid positioning in total shoulder arthroplasty with intraoperative navigation: a prospective-randomized clinical study. *J Shoulder Elbow Surg.* 2009;18(4):515–520.
15. Greene AT, Jones RB, Hamilton MA, et al. Accuracy of glenoid version and inclination determination using computer navigated versus non navigated shoulder arthroplasty techniques. *Orthopaedic Research Society.* 2017.
16. Saithna A, Dekker AP. The influence of computer navigation on trainee learning in hip resurfacing arthroplasty. *Comput Aided Surg : official journal of the International Society for Computer Aided Surgery.* 2009;14(4-6):117–122.
17. Schnurr C, Eysel P, König DP. Do residents perform TKAs using computer

- navigation as accurately as consultants? *Orthopedics*. 2011;34(3):174.
18. Antuna SA, Sperling JW, Cofield RH, Rowland CM. Glenoid revision surgery after total shoulder arthroplasty. *J Shoulder Elbow Surg*. 2001;10(3):217–224.
  19. Wang AW, Hayes A, Gibbons R, Mackie KE. Computer navigation of the glenoid component in reverse total shoulder arthroplasty: a clinical trial to evaluate the learning curve. *J Shoulder Elbow Surg*. 2020;29(3):617–623.
  20. Gauci MO, Boileau P, Baba M, Chaoui J, Walch G. Patient-specific glenoid guides provide accuracy and reproducibility in total shoulder arthroplasty. *The bone & joint journal*. 2016;98-b(8):1080–1085.
  21. Dallalana RJ, McMahon RA, East B, Geraghty L. Accuracy of patient-specific instrumentation in anatomic and reverse total shoulder arthroplasty. *Int J Shoulder Surg*. 2016;10(2):59–66.
  22. Suero EM, Citak M, Lo D, Krych AJ, Craig EV, Pearle AD. Use of a custom alignment guide to improve glenoid component position in total shoulder arthroplasty. *Knee Surg Sports Traumatol Arthrosc*. 2013;21(12):2860–2866.
  23. Throckmorton TW, Gulotta LV, Bonnarens FO, et al. Patient-specific targeting guides compared with traditional instrumentation for glenoid component placement in shoulder arthroplasty: a multi-surgeon study in 70 arthritic cadaver specimens. *J Shoulder Elbow Surg*. 2015;24(6):965–971.
  24. Hendel MD, Bryan JA, Barsoum WK, et al. Comparison of patient-specific instruments with standard surgical instruments in determining glenoid component position: a randomized prospective clinical trial. *The Journal of bone and joint surgery. American volume*. 2012;94(23):2167–2175.
  25. Burns DM, Frank T, Whyne CM, Henry PD. Glenoid component positioning and guidance techniques in anatomic and reverse total shoulder arthroplasty: a systematic review and meta-analysis. *Shoulder Elbow*. 2019;11(2 Suppl): 16–28.
  26. Micic I, Kholinne E, Hong H, et al. Navigation-assisted suture anchor insertion for arthroscopic rotator cuff repair. *BMC Musculoskel Disord*. 2019;20(1):633.
  27. Kriechling P, Roner S, Liebmann F, Casari F, Fürnstahl P, Wieser K. Augmented reality for base plate component placement in reverse total shoulder arthroplasty: a feasibility study. *Arch Orthop Trauma Surg*. 2020.



Contents lists available at ScienceDirect

## Journal of Arthroscopy and Joint Surgery

journal homepage: [www.elsevier.com/locate/jajs](http://www.elsevier.com/locate/jajs)

## Total elbow arthroplasty: Evolution and biomechanics

Parag Kirit Shah <sup>a,\*</sup>, Chittaranjan Parimal Patel <sup>b</sup><sup>a</sup> Fracture Orthopaedic Hospital, Ahmedabad, India<sup>b</sup> Krupa Orthopaedic Hospital, Surat, India

## ARTICLE INFO

## Article history:

Available online 12 February 2021

Over the last 50 years, arthroplasties of the lower limb are widely accepted, and in contrast upper limb arthroplasties have gained popularity relatively recently. Elbow arthroplasty is a field which has been in development since quite some time. Historically, as early as the sixteenth century, Ambroise Pare had performed the first surgery to salvage the elbow and avoid amputation of the limb, by excising the humeral and ulnar ends of an infected elbow joint.<sup>1</sup> Dating back to the 1780's, H. Park from Liverpool and P.F. Moreau from France had begun successful excision of diseased joints, particularly the knee and elbow, paving the way for resection arthroplasty of elbow.

Till about 1930's, resections, interposition arthroplasties, arthrodesis and excisions, formed the main stay of treatment for various elbow pathologies. Resection arthroplasty resulted in a pain free elbow but the resulting instability led to a decrease in overall limb function. Sir Defontaine introduced interposition arthroplasty of the elbow in 1887. Interposition arthroplasty of elbow involves interposition of fat, fascia, tendoachilles or skin between the articulation surfaces, with or without elbow distraction. Interposition arthroplasty showed good outcomes in the subset of cases with secondary post traumatic arthritis. Stiffness and ankylosis limited the long term functional results of interposition arthroplasty in many cases.<sup>2</sup> Interposition Arthroplasty has the advantage of bone conservation and conversion to total elbow arthroplasty at a later stage if required.<sup>3</sup> Arthrodesis completes the list of pre replacement-era options, but is not favored currently due to lack of robust fixations options, high rate of non unions and poor functional utility of the fused elbow with a few exceptions.

Robineau's attempt in 1925 is the first documented attempt to replace an elbow joint with prosthetic materials. His anatomical

design utilized metal and vulcanized rubber. In 1941, Boerema used a metal hinged non-anatomical prosthesis.<sup>1,4</sup>

In the early attempts at elbow arthroplasty, the prosthesis were fixed by tantalum wires and vitalium screws. It was only in the 1940's, that an impetus was found in the development of elbow arthroplasty. Two methods of elbow replacements were beginning to develop. Hemi replacement arthroplasty and total elbow replacement. Hemi arthroplasty of the elbow was introduced by Mellen and Phalen in 1947. They used custom acrylic implants at a US Army hospital for young active duty soldiers with complex intra-articular fractures of the distal humerus.<sup>5</sup> An advantage of hemiarthroplasty, as reviewed by Dunn et al. was a far lower rate of loosening of the components. In total elbow arthroplasty, loosening occurred almost equally in the humeral and ulnar components, but only two of the 134 hemiarthroplasty cases reviewed showed loosening. In addition, ulnar bone stock is preserved making distal humeral replacement a more suitable choice in younger patients with unreconstructable distal humerus fractures.<sup>6</sup> The background for the modern era of total elbow arthroplasty was ushered by the American surgeon, R. Dee, in 1972 and was based on the 'constrained' design concept, which provided the best inherent stability by virtue of its rigid hinge, but this was associated with the highest reported rates of loosening, especially in conditions when the soft tissues were deficient. Around the same time in 1972, an unlinked elbow prosthesis, the Kudo was also introduced, where there was no linkage between the humeral and the ulnar components, but that also had a very high rate of humeral loosening and had to be redesigned to include a humeral stem.<sup>2,4</sup> Implants which utilize this design are the Capitulocondylar, Kudo (1–5 series), Instrumented Bone Preserving Design (iBP) and Souter-Strathclyde.<sup>15</sup> Which incorporated an unlinked concept along with a relatively constrained design. This design has been widely implanted and followed up as per the review of literature performed by Welsink et al. However due to its shorter survival rates and high incidences of humeral component loosening, probably attributed to the short

\* Corresponding author. Fracture orthopaedic hospital, Opp. Unnati School, Paldi, Ahmedabad, Gujarat, 380007, India.

E-mail addresses: [shoulder.centre@gmail.com](mailto:shoulder.centre@gmail.com) (P.K. Shah), [cphp912@gmail.com](mailto:cphp912@gmail.com) (C.P. Patel).



humeral stems in this design, it has been discontinued.<sup>16</sup>

The most widely studied linked elbow was first introduced in the year 1973, as the Coonrad Type I total elbow. (Zimmer, Warsaw, IN). This design had high density polyethylene bushings and a limited coronal laxity of 2–3°. A modification of this design was introduced in 1978, the Coonrad Type II. This design had an increase in the coronal laxity to 7°, with the aim to help reduce aseptic loosening. The Coonrad- Morrey Type III elbow was introduced in 1981, with the addition of an anterior flange with associated bone graft and porous coating of the components. This design modification helped in better anchoring of the humeral component and allowed easy restoration of the axis of rotation, even in the absence of humeral epicondyles or distal humeral bone stock.<sup>12 13 14</sup> Convertible prosthesis have also been developed where an unlinked prosthesis to begin with but can be converted into a linked prosthesis, intraoperatively or during revision surgery. (E.g. LATITUDE, ACCLAIM, K-NOW total elbow system).

on its ability to successfully transfer the load to its surrounding soft tissues. This has been largely successful in hip and knee Arthroplasty with 96% survival at 10 years; in contrast to 79% in case of total elbow Arthroplasty.<sup>23</sup> Biomechanically, the native elbow is a very complex joint with an intricate balance between the bony articulations and ligaments to provide stable motion. There are two main prosthetic designs of a total elbow: unlinked, where there is no mechanical connection between the ulnar and the humeral component, and linked, where the ulnar and humeral components have a captured articulation.<sup>24</sup> Most linked implants are considered semi constrained, however unlinked total elbow arthroplasty (TEA) is not synonymous with “unconstrained”, as highly conforming designs can be unlinked, yet constrained. Both have distinct advantages and disadvantages. Early implants failed due to high degree of constraint and rigidity which caused high degrees of force transfer to the implant bone interface leading to loosening, fracture of the stem or bone and broken hinges.

Total elbow Arthroplasty, distinctive types of designs, a historic perspective		
Year	Inventor	Design characteristics
1954	Prevo	Screwed attachments
1970	Stevens	Slide on self locking resurfacing arthroplasty
1974	Schlein	Smooth cemented stems
1974	Dee	Smooth cemented stems
1975	Roper	Cemented humeral component
1976	Pritchard	Smooth cemented stems
1978	Harmon	Radiocapitellar joint used as two rings
1981	Amis	Screw fixation for ulnar components

Prkić A, van Bergen CJA, The B, Eygendaal D. Total elbow arthroplasty is moving forward: Review on past, present and future. *World J Orthop* 2016; 7(1): 44-49.

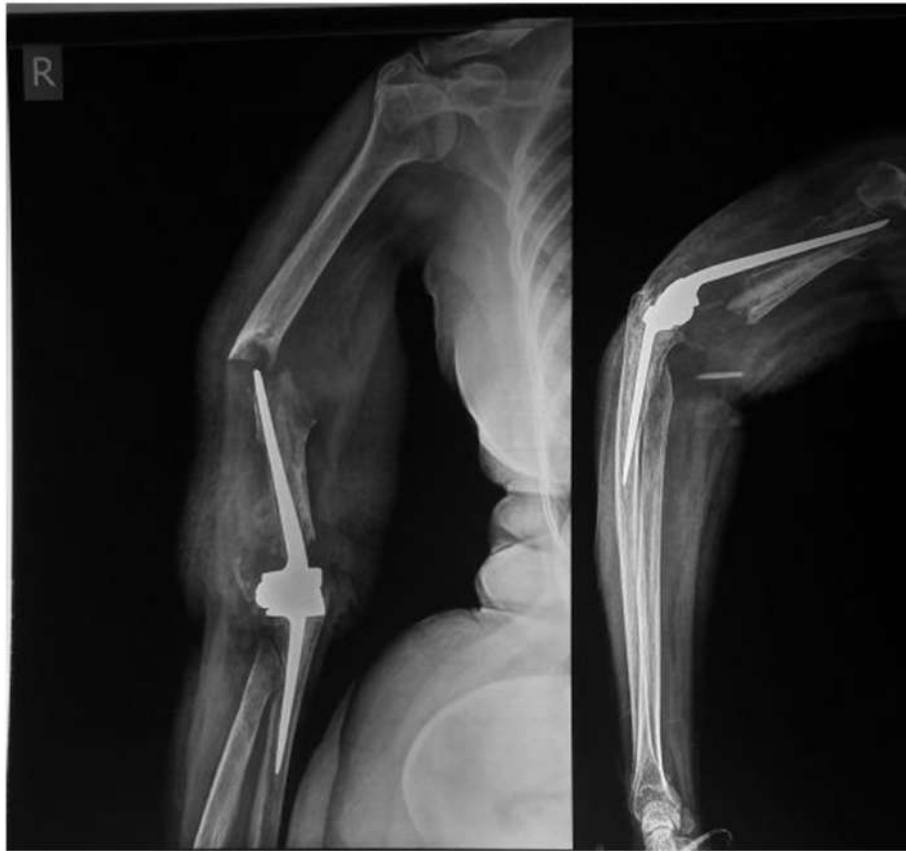Meanwhile, in India, a noteworthy development in elbow arthroplasty took place with the development of a “sloppy hinge” type of implant popularly known as Baksi’s sloppy hinge elbow arthroplasty, after the name of the inventor Dr. DP Baksi. The original prosthesis was designed and put in clinical use in 1977 as a rigid hinge metal on metal articulation, and later modified in 1983 to a sloppy hinge allowing 7–10 deg of varus –valgus laxity at the hinge section to better replicate the normal kinematics of the elbow. This was believed to in turn reduce the metal dust liberation and prevent loosening at cement bone interface. This implant was further modified nearly 20 years later to incorporate 2 flanges on either side of the shank of the humeral stem to improve rotational stability. Published results of this prosthesis by the originator of the early design implant suggested at 2.5 years to 16 year follow up, (average 11.5 years) a 12.5% radiolucency in post traumatic ankylosed elbows and 18.75% incidence of radiolucency in unstable elbows and a loosening rate between 3.4 and 6.25% in a predominantly younger population, with a myriad indications. Results were generally considered good with a potential of easy revision if needed.<sup>18–20</sup>

In recent years, the senior author (PS) has had occasions to revise this prosthesis at medium term due to severe aseptic loosening and osteolysis with presentation of pain, loss of function and pathological fracture. At revision, severe metallosis and catastrophic long segment bone necrosis have been found, which need revision to a tumour type prosthesis (Figs. 1–3) or removal of the implant and an excisional arthroplasty.

The long term success and survival of any arthroplasty depends

The unlinked TEA has the theoretical advantages based on its near normal elbow kinematics and preservation of bone stock, with the ultimate goal of transferring the stress to the surrounding soft tissue. Unfortunately, the use of unlinked TEA is limited to situations with minimal bone loss, limited deformity and well functioning ligaments, as post operative instability is a major concern in unlinked prosthesis.

The linked TEA are considered semi constrained as they allow some degree of varus valgus motion to occur. The biomechanics of the native elbow, is not a pure hinge. It allows for about 7° of varus and valgus motion in the coronal plane and also some rotational movement. The semi-constrained or linked elbow design incorporates a sloppy hinge to allow for the additional degrees of freedom at the hinge articulation. The “sloppy hinge” allows the soft tissues to partially absorb the external stresses that would normally be concentrated at the bone prosthetic interface. The implants are coupled together with pins or snap-fit polyethylene bushings to provide some inherent stability. This stability, in turn, allows these implants to be used for a wide variety of situations requiring an arthroplasty. They have gained popularity in the past decade as the use of TEA has increased in trauma and its sequelae as the link provides immediate post op stability. Most designs have an anterior flange on the humeral component to resist torsional forces and aid in force transfer as well. However the force transmission in linked TEA is non anatomic with significant stress shielding of the humeral condyles and olecranon and stress concentration at the shafts of the humerus and ulna. This may be accentuated by collateral ligament deficiency by disease or design and radial head



**Fig. 1.** A 65 year old lady who had a Baski sloppy hinge prosthesis implanted for a sequelae of trauma presented 8 years later with a pathological fracture.

excision. Condylar bone resorption has been seen over time in linked TEA. This leads to a creation of a longer moment arm between the hinge and the point of load transfer, and the likelihood of failure increases with longer moment arms due to hinge dissociation, breakage and stem fatigue. This also leads to more difficult revisions as longer stems are required.<sup>23</sup>

The current rate of loosening of both unlinked and linked TEA is pegged at about 5%, with higher radiological loosening in linked TEA. Bushing wear and disassociation are unique complications of the linked TEA.<sup>22,23</sup>

## 1. Conclusion

The total elbow Arthroplasty is a complex surgical procedure, which in trained hands can give excellent clinical outcome in well indicated situations. The overall complication rate has dropped from 49% in 1993 to about 25% in 2009, which is still significant.<sup>22,23</sup> Post elbow replacement lifestyle modifications are a must to ensure optimum longevity of the implant. Patients are advised never to lift 10 pounds or more. Repeated lifting of weights of 2 pounds or more is also discouraged.<sup>11,12</sup> It is imperative to choose the implant and patient wisely to optimize the results of Total Elbow arthroplasty.

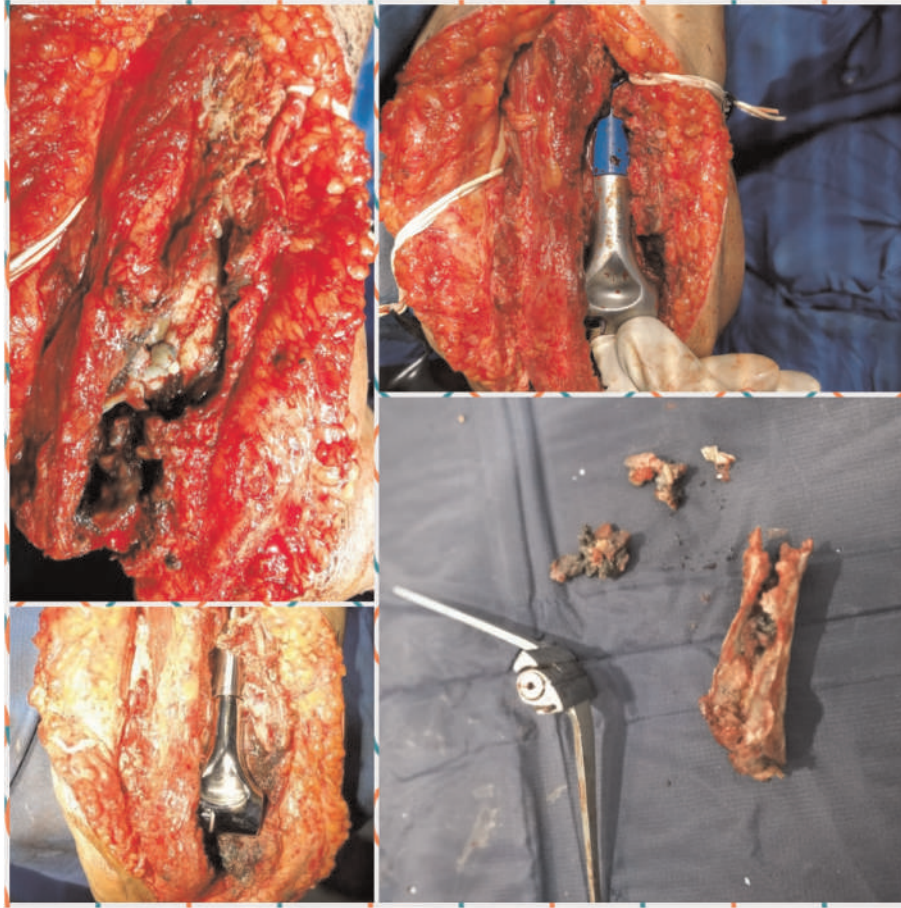


Fig. 2. Intraoperatively extensive metallosis was encountered with segmental necrosis of the distal shaft.

**Disclosures**

None.

**References**

1. Prkić Ante, et al. Total elbow arthroplasty is moving forward: review on past, present and future. *World journal of orthopedics* 7.1. 2016:44–49.
2. <https://www.cedars-sinai.edu/Patients/Programs-and-Services/Imaging-Center/For-Physicians/Musculoskeletal-Radiology/Exhibits-and-Presentations/Elbow-Arthroplasty/Elbow-Arthroplasty-Historical-Perspective.aspx>.
3. Blaine TA, Adams R, Morrey BF. Total elbow arthroplasty after interposition arthroplasty for elbow arthritis. *J Bone Joint Surg Am.* 2005 Feb;87(2), 286-92.
4. Wadsworth TG. Surgery of arthritis. In: Wadsworth TG, ed. *The Elbow*. Churchill Livingstone; 2008:303.
5. Mellen R, Phalen G. Arthroplasty of the elbow by replacement of the dial portion of the humerus with an acrylic prosthesis. *J Bone Joint Surg.* 1947;29(2): 348–353.
6. Dunn John, Kusnezov Nicholas, Pirela-Cruz Miguel. Distal humeral hemiarthroplasty: indications, results, and complications. A systematic review (N Y) *Hand.* 2014 Dec;9(4):406–412. <https://doi.org/10.1007/s11552-014-9681-3>. Published online 2014 Oct 2.
11. Fajardo M, Kwon YW. The rise of the metal elbow. *Bull Hosp Jt Dis.* 2013;71(1): 24–31. *Bulletin of the Hospital for Joint Diseases* 2013;71(1):24-31.
12. Elbow Arthroplasty: From normal to failure, elizabeth S. Levin, MD benjamin plotkin, MD.
13. Lightdale Aldridge, et al. *J Bone Joint Surg [Br].* 2006:509–514, 88-B.
14. 21 Bennett JB, Mehlhoff TL. Totalelbowarthroplasty: surgical technique. *J Hand Surg Am.* 2009;34(5):933–939.
15. Iwamoto T, et al: Unlinked total elbow arthroplasty.
16. Welsink Chantal, Lambers Kaj TA. *JBJS Reviews.* July 2017. <https://doi.org/10.2106/JBJS.RVW.16.00089>.

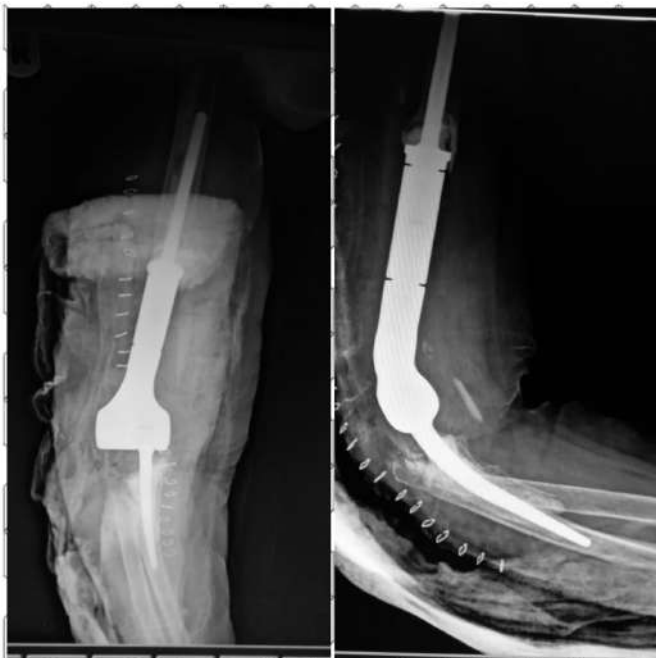

Fig. 3. Final revision to a tumour prosthesis after excision of the necrotic distal bone.

18. Baksi DP. Results of Baksi's Sloppy Hinge Compared to Rigid Hinge Elbow Arthroplasty *Indian Journal of Arthroplasty*. vol. 29. 1995:56–66.
19. Baksi DP. Total Replacement of the Elbow Joint *Indian Journal of Orthopaedics*. vol. 14. 1980:129–142.
20. Baksi DP. Sloppy hinge prosthetic elbow replacement for post traumatic ankylosis or instability. *JBJS (B)*. 1998;80:614–619.
22. Voloshin I, schippert DW, Kakar S, Kaye EK, Morrey BF. Complications of total elbow Arthroplasty. a systematic review. *JSES*. 2011;20(1):158–168.
23. Kaufmann Robert A, D'Auria Jennifer L, Schneppendahl Johannes. Total elbow Arthroplasty:elbow biomechanics and failure. *JHS(A)*. 2019 Aug;44(8): 687–692. <https://doi.org/10.1016/j.lhsa.2018.11.020>.
24. Iwamoto Takuji, Lkegami Hiroyasu, Suzuki Taku, et al. The history and future of unlinked total elbow arthroplasty. *Keio J Med*. 2017.





## Research paper

# Total elbow arthroplasty: Potential problems and technical considerations – Case studies



Sudhakar Rao Challagundla\*, Scott Barker, Kapil Kumar

Woodend Hospital, NHS Grampian, Eday Road, Aberdeen, AB15 6XS, UK

## ARTICLE INFO

## Article history:

Received 15 December 2020

Accepted 18 December 2020

Available online 23 December 2020

## Keywords:

Elbow  
Replacement  
Arthroplasty  
Trauma  
Arthritis

## ABSTRACT

Total elbow arthroplasty is a challenging procedure with complications and revision rates higher than those after hip or knee arthroplasty. With the overall numbers for Elbow arthroplasty being significantly smaller as compared to lower limb arthroplasty there are limited opportunities for training and accumulating significant clinical experience.

In this paper we have highlighted the technical challenges of Elbow arthroplasty in different clinical scenarios, along with tips to address these challenges to ensure satisfactory outcomes.

© 2021 International Society for Knowledge for Surgeons on Arthroscopy and Arthroplasty. Published by Elsevier, a division of RELX India, Pvt. Ltd. All rights reserved.

## 1. Introduction

Use of Total Elbow Arthroplasty (TEA) is on the rise.<sup>1</sup> Rheumatoid arthritis, Trauma (acute trauma and trauma sequelae) and Osteoarthritis account for over 95% of all elbow replacements.<sup>2</sup> It improves elbow function in all indications with significant improvement in mean Mayo Elbow Performance Score.<sup>3</sup> However long term survivorship remains a concern with data from Australian joint registry showing implant survival rate of 81% at 9 years.<sup>4</sup> The associated complication rates too are high, with 19.1% for linked TEAs and 26.5% for unlinked TEAs.<sup>5</sup>

While TEA is a versatile procedure that can be performed in both elective and trauma situations, limitations with weight bearing capability of the implant precludes extensive use of this implant. Other issues like narrow medullary canals, osteoporotic bone, extensor mechanism reconstruction add to the technical challenge.

While advances in the design and materials continue to improve the success of the implant, awareness of the potential problems and knowledge of the ways to overcome these could improve the outcome of the operation. We look at such technical considerations in TEA with case examples. We also discuss a case of elbow hemiarthroplasty in managing elbow trauma.

## 2. Case studies

### 2.1. Rheumatoid arthritis with ipsilateral reverse shoulder replacement in situ

#### 2.1.1. Case details

Fifty eight year old, known rheumatoid arthritis patient presented with pain and stiffness of her left elbow (Fig. 1). Elbow flexion was from 30 to 100°. Both pronation and supination were also painful and restricted. She had left reverse shoulder replacement in situ on the same side (Fig. 2). Her medication included Sulfasalazine and Hydroxychloroquine.

#### 2.1.2. Potential problems

- Management of DMARDs and Biologic medication in the perioperative period.
- Presence of reverse shoulder replacement on the same side interfering with elbow humeral component.

#### 2.1.3. Technical considerations

- Nonbiologic disease-modifying antirheumatic drugs may be continued throughout the perioperative period. Biologic medications should be withheld as close to 1 dosing cycle as scheduling permits prior to elective surgery. They can be restarted after evidence of wound healing, typically 14 days after surgery.<sup>6</sup>

\* Corresponding author.

E-mail address: [Sudhakar.Challagundla@nhs.scot](mailto:Sudhakar.Challagundla@nhs.scot) (S.R. Challagundla).

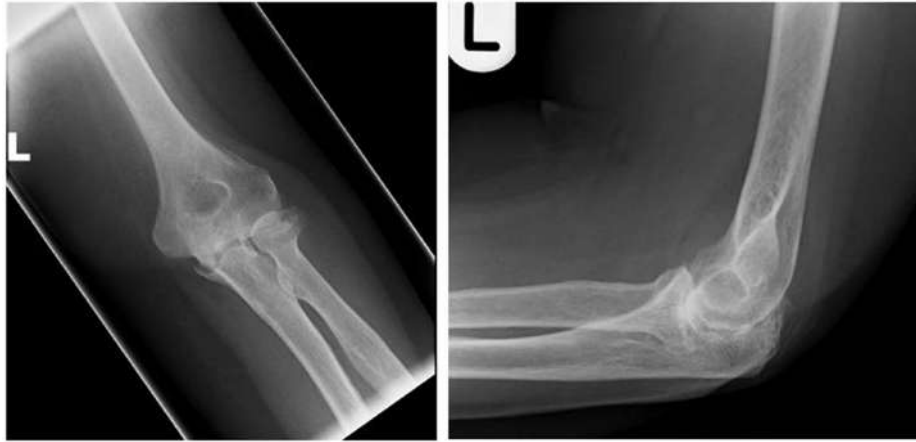

Fig. 1. Anteroposterior and lateral view of left elbow showing reduced joint space in patient with rheumatoid arthritis.

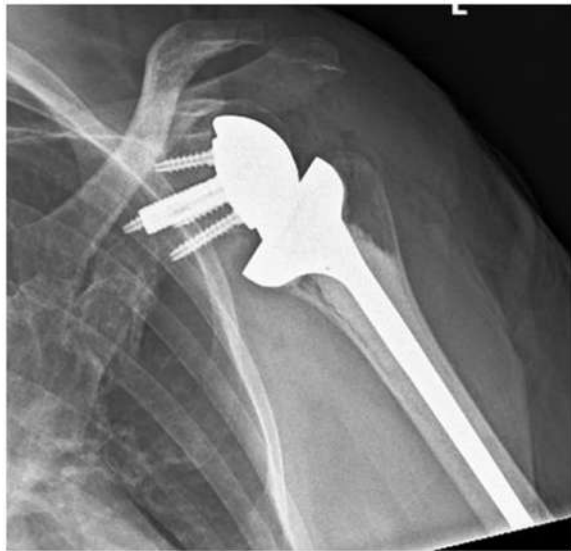

Fig. 2. Anteroposterior view of shoulder showing ipsilateral cemented, stemmed reverse shoulder replacement.

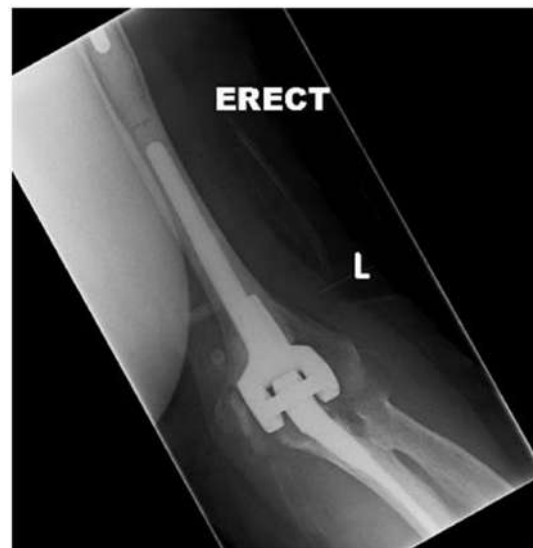

Fig. 3. Anteroposterior view of left elbow in the same patient showing cement column bridging the humeral components of the two joint replacements.

- In patients needing ipsilateral (stemmed) shoulder and elbow replacement stress riser in the humerus can be a potential problem.<sup>7</sup>
- Preoperative planning should include measurement of the length of humerus distal to humeral component. Check the length of humeral component in the elbow replacement system that is being used. Too long prevents implantation of the prosthesis or lowers the joint level. Too short could potentially cause stress riser between the two humeral stems. Cement column is recommended to bridge both the humeral components.<sup>8</sup>
- In our case there was 14 cm of humerus distal to prosthesis (11 cm distal to humeral component cement). A 4-inch (approx 10 cm) length humeral component (Zimmer® Coonrad/Morrey Total Elbow) was used. Bone cement column was used to bridge a short segment between the two humeral stems to prevent this stress riser effect (Fig. 3).

## 2.2. TEA with intraoperative fracture

### 2.2.1. Case details

Seventy three year old man presented with pain and stiffness of his left elbow. He previously had undergone left wrist arthrodesis

and right total wrist replacement. His left elbow flexion was from about 30 to 90°. Supination and pronation were restricted. Radiographs confirmed Osteoarthritis of the elbow (Fig. 4). During the total elbow arthroplasty procedure there was an intraoperative fracture of lateral condyle of the humerus.

### 2.2.2. Potential problems

- Intraoperative fractures

### 2.2.3. Technical considerations

- The patient underwent semiconstrained Coonrad Morrey total elbow replacement. Intraoperative fracture of lateral condyle of humerus was fixed with cancellous screws (Fig. 5).
- The risk of intraoperative fractures in a study of 35 elbow replacements was 6%. Intraoperative condyle fractures were fixed with screws. Fractures united and the outcome of TEA was good to excellent.<sup>9</sup>

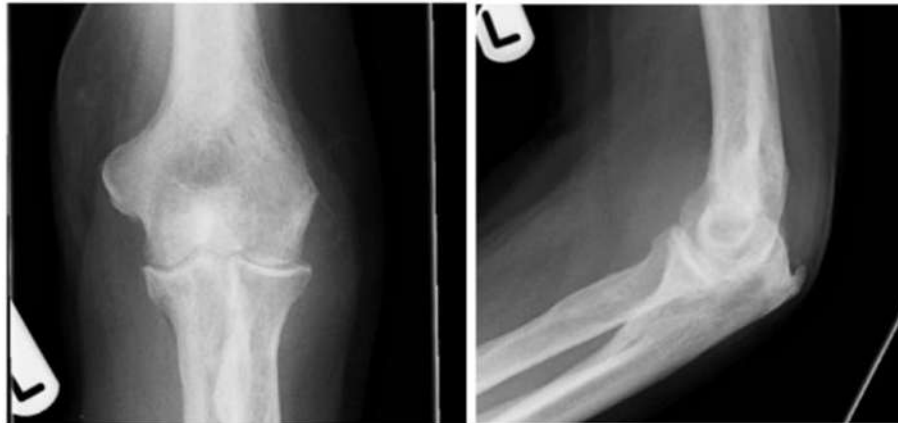

Fig. 4. Anteroposterior and lateral view of left elbow with osteoarthritis.

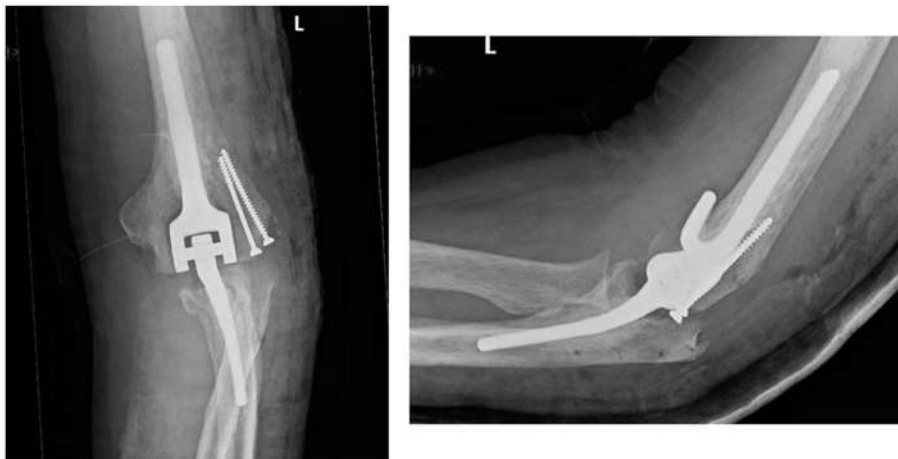


Fig. 5. Anteroposterior and lateral view of left elbow replacement showing intraoperative fracture fixed with cancellous screws.

- Sloppy hinge prosthesis with anterior flange has been associated with reduction in the incidence of radiological lucencies and secure fixation even in the presence of bone loss.<sup>10</sup>
- Preservation of the condyles helps judge rotation and alignment and preserves bone stock for revision.

### 2.3. TEA for fracture distal humerus in elderly

#### 2.3.1. Case details

Eighty five year old man presented after a trivial fall on to his elbow. He was fully independent and living at home. He was on Apixaban for atrial fibrillation and Bisoprolol for hypertension. His American Society of Anesthesiologists (ASA) score was 2. Radiographs showed comminuted intraarticular distal humerus fracture (Fig. 6).

#### 2.3.2. Potential problems

- Challenges of fixation – Comminution and poor bone stock. Locking compression plates and precontoured anatomical distal humeral plates have been shown to overcome these problems to certain extent.<sup>11,12</sup>
- Challenges in performing total elbow arthroplasty due to loss of bony landmarks.

#### 2.3.3. Technical considerations

- 25% of cases allocated for open reduction and internal fixation were not amenable to fixation in a Randomised Control Trial of open reduction and internal fixation versus total elbow arthroplasty for displaced intraarticular distal humeral fractures in elderly patients.<sup>13</sup> If considering fixation, systems (equipment and skills) should be in place for on table conversion to total elbow arthroplasty when required.
- In the absence of distal humerus in more complex fractures, orientation can be difficult and malrotation of components can lead to edge loading.<sup>14</sup> Humeral component should be placed in 15° internal rotation to the posterior surface of distal humerus.<sup>15</sup> Ulnar component should be placed perpendicular to the flat subcutaneous surface of the olecranon.<sup>16</sup> With Triceps-On approach there is a tendency to place ulnar component in a flexed position.<sup>17</sup>
- In this case, the less comminuted medial condyle was reconstructed (Fig. 7) for assessment of length, rotation and alignment of humeral component.

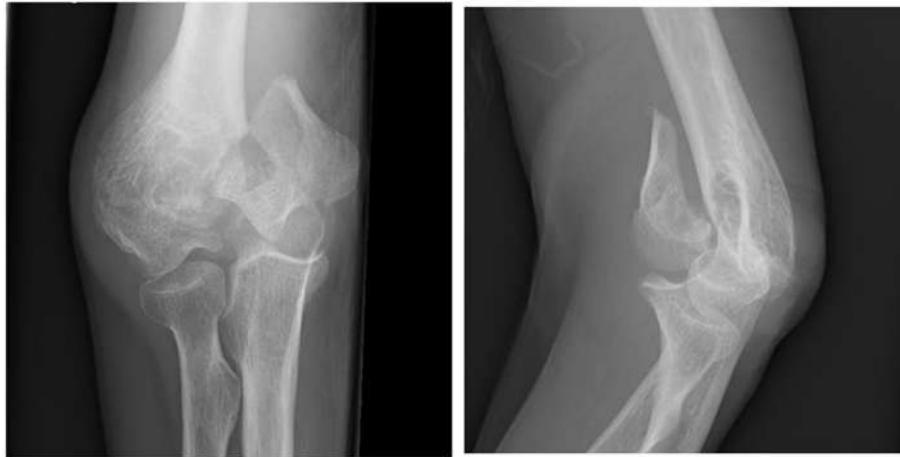

Fig. 6. Anteroposterior and lateral view of left elbow with intraarticular fracture of distal humerus.

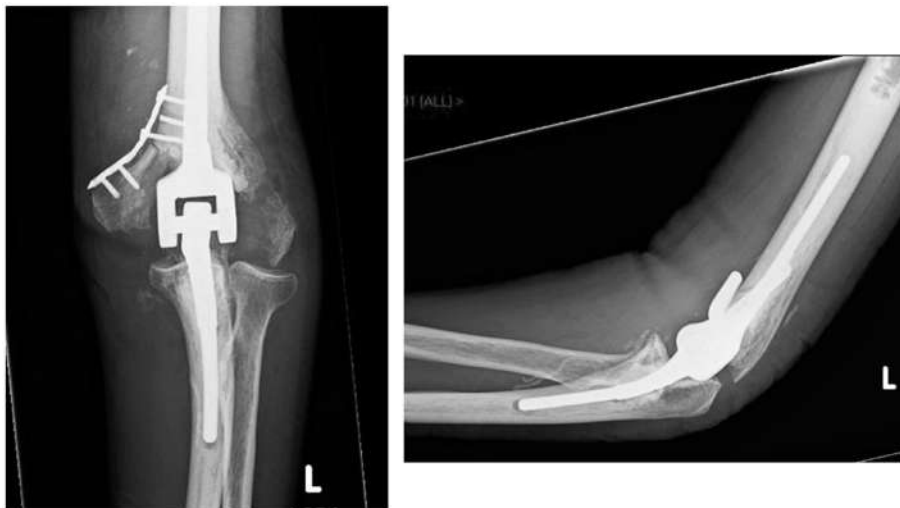

Fig. 7. Anteroposterior and lateral view of left elbow replacement with internal fixation of medial condyle of distal humerus.

#### 2.4. TEA for non union of olecranon fracture in transolecranon fracture dislocation

##### 2.4.1. Case details

Sixty eight year old lady was treated more than 20 years ago for trans-olecranon fracture dislocation of the elbow with tension band wiring of Olecranon fracture and radial head excision. The metalwork was subsequently removed. Olecranon fracture failed to unite and she developed post traumatic arthritis of the elbow (Fig. 8).

##### 2.4.2. Potential problems

- Non union of olecranon fracture.
- Potential triceps insufficiency after TEA.

##### 2.4.3. Technical considerations

- A long ulnar component was used to bridge the fracture non union site with good distal fixation (Fig. 9).

- Olecranon non-union and thereby the triceps function reconstructed with FiberTape® in a tension band wiring construct. No metalwork was used due to potential loosening (Tension band wiring with K wires) or screw interference with ulna component (plate fixation).

#### 2.5. Infected TEA

##### 2.5.1. Case details

- Sixty year old man had undergone left TEA 7 years prior to presentation for Rheumatoid arthritis in his elbow. 3 months post index uncemented TEA, elbow had to be revised to a cemented TEA due to pain from pistoning and movement of the prosthesis. He presented with increasing pain and stiffness from his left elbow for over a year. There were no overt signs of infection since his primary procedure. At presentation white cell count and neutrophil count were within normal limits. C-reactive protein was raised at 58 mg/L. Radiographs showed significant osteolysis, cortical thinning and expansion of the humerus at the tip of the prosthesis (Fig. 10).



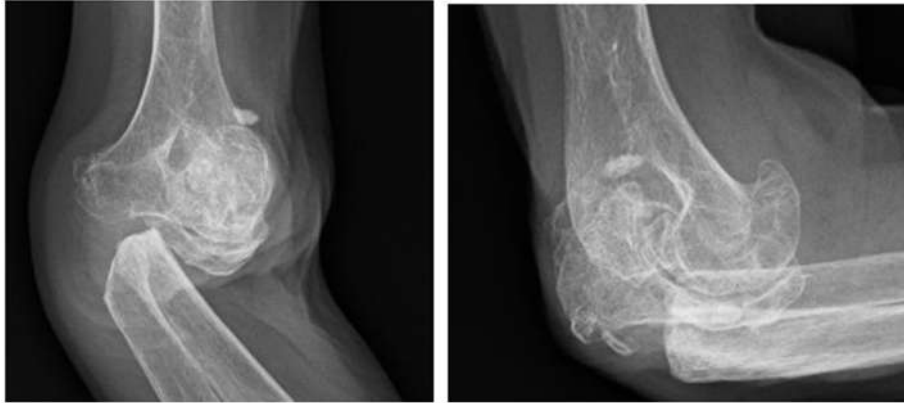


Fig. 8. Anteroposterior and lateral view of right elbow showing arthritis with non union of olecranon fracture and previous radial head excision.

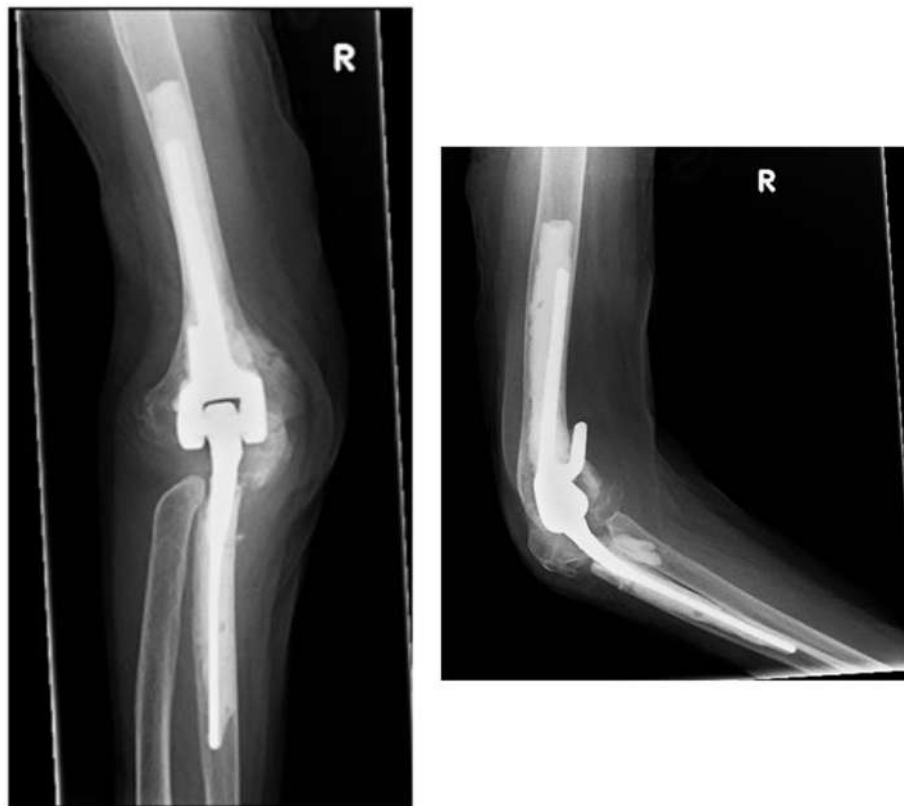


Fig. 9. Anteroposterior and lateral view of right elbow showing TEA with fixation of olecranon nonunion with Fibretape.

### 2.5.2. Potential problems

- Infection despite no clinical or haematological evidence
- Cement proximal to implant in humerus
- Well fixed ulnar component
- Difficulties in implant removal with risk of periprosthetic fracture

### 2.5.3. Technical considerations

- Diagnosis: Diagnosis of Prosthetic Joint infection (PJI) is usually made based on a combination of clinical, radiographic and intraoperative findings alongside blood results and

microbiological cultures. It can sometimes be difficult, as low-grade infections may present with non-specific and vague symptoms such as pain and stiffness. Our patient presented with pain and stiffness but had significant radiological changes. Musculoskeletal Infection Society (MSIS) have published a criteria for diagnosing PJI.<sup>18</sup>

- Single stage vs two stage revision: One-stage revision may be potentially as clinically effective as two-stage revision, but due to lack of sufficient evidence in the literature British Shoulder and Elbow Society recommends two stage revision.<sup>19,20</sup> Our patient underwent two-stage revision.
- Intraoperative sampling: Five separate tissue samples for culture and two further samples for histology are the minimum

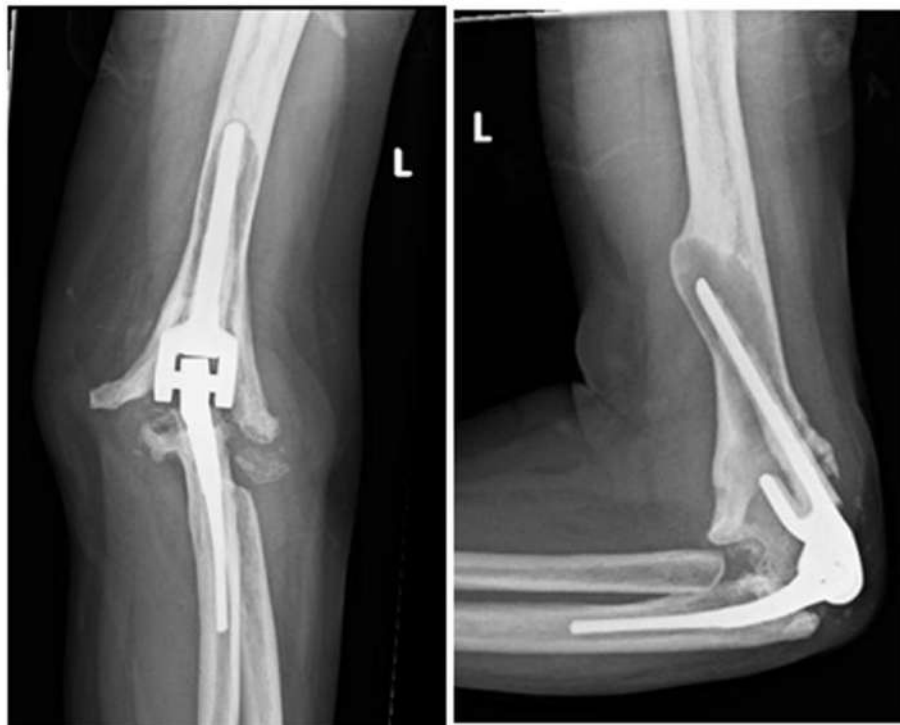

Fig. 10. Anteroposterior and lateral view of left TEA with osteolysis around humeral component, thinning of cortices and expansion of the humerus.

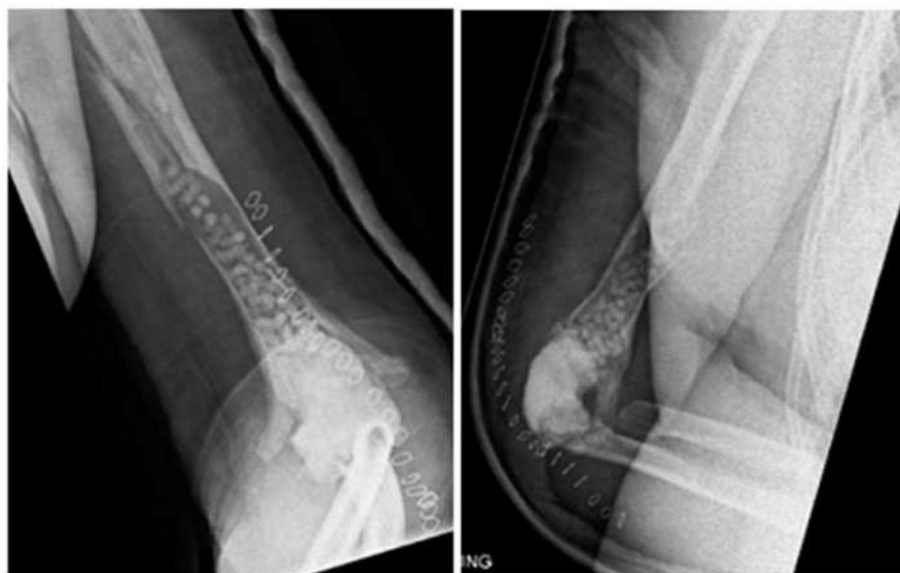

Fig. 11. Anteroposterior and lateral views of left elbow with cement spacer and absorbable calcium sulfate antibiotic carrier in situ with periprosthetic fracture of left humerus.

- recommended.<sup>20</sup> *Brevibacillus* species and *Staphylococcus epidermidis* were isolated on enrichment culture in our patient.
- Cemented component retrieval techniques and instruments: While general techniques described in lower limb revision surgery are still applicable in and around the elbow, knowledge of specific techniques like humeral window helps to minimise the risk of periprosthetic fractures.<sup>21,22</sup> Intraoperative fracture of the humerus occurred during stage 1 procedure (Fig. 11).
  - Bone loss management: Bypassing the area of bone deficiency by a longer stem, impaction allografting, allograft-prosthesis

composite and cortical strut allograft techniques have been described to manage bone deficiency.<sup>23–26</sup> We used an allograft prosthesis composite along with internal fixation of the periprosthetic fracture with a locking plate (Fig. 12).

## 2.6. Elbow hemiarthroplasty

### 2.6.1. Case details

Sixty five year old active woman presented with postero-lateral fracture dislocation of the right elbow. Radiographs and CT scan

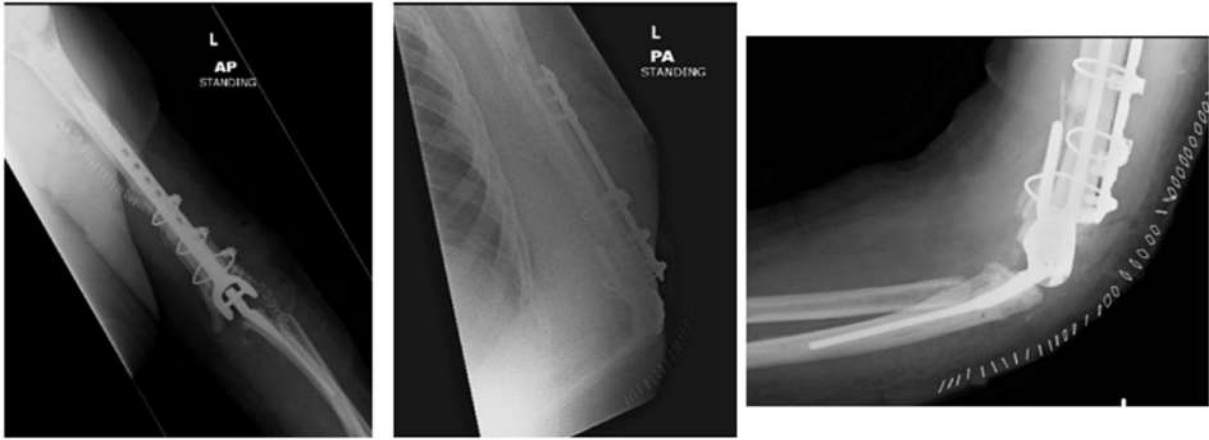

Fig. 12. Anteroposterior and lateral views of left elbow post second stage revision replacement.

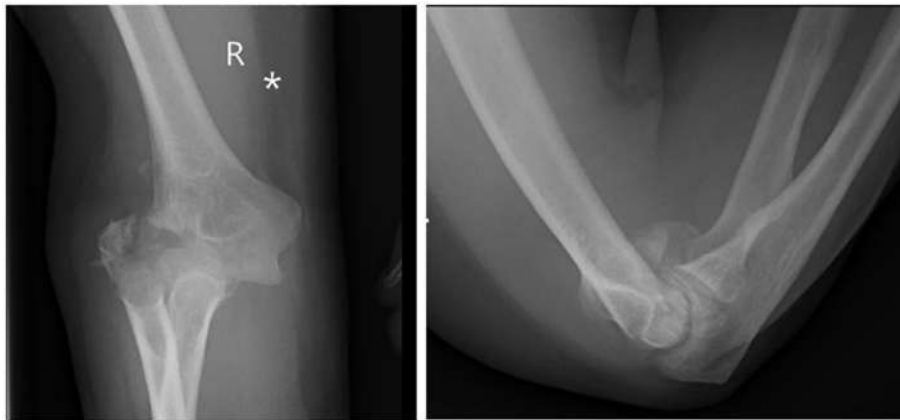

Fig. 13. Anteroposterior and lateral view of right elbow showing fracture dislocation.

showed a complex comminuted intra-articular fracture of the distal humerus mainly involving the capitellum but extending into trochlea (Fig. 13). There was no evidence of arthritis either clinically or radiologically, prior to injury.

#### 2.6.2. Potential problems

- Young age, no pre-existing arthritis, limited weight bearing capability with TEA.

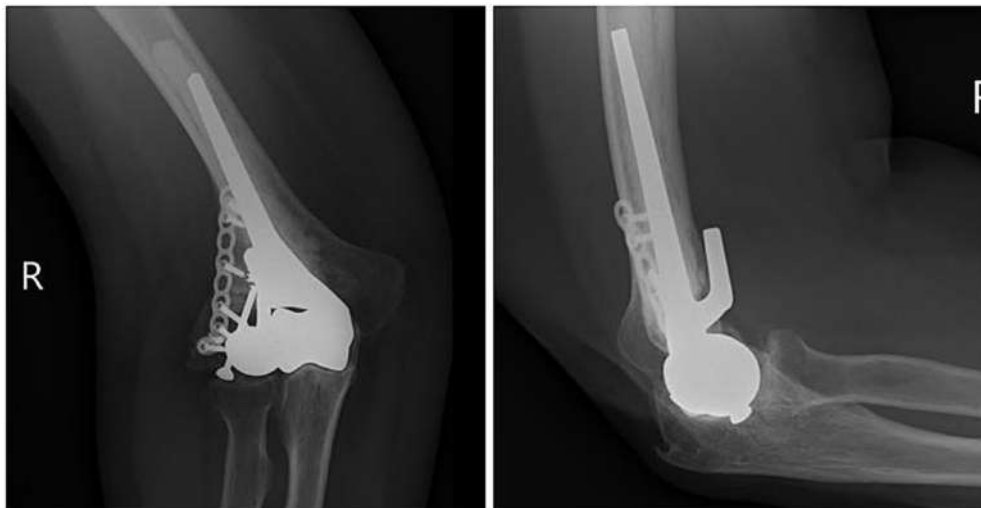

Fig. 14. Anteroposterior and lateral view of right elbow with elbow hemiarthroplasty in situ and stabilisation of lateral condyle.

### 2.6.3. Technical considerations

- Elbow hemiarthroplasty acts like an unlinked prosthesis. Implant should be placed such that it replicates the native flexion–extension axis of the elbow.<sup>27</sup> Restoration of the collateral ligaments to the flexion–extension axis of the implant and support from condyles are essential for function and stability.
- Lateral column was stabilised with partially threaded cancellous screw and a locking plate (Fig. 14).
- The Lateral ulnar collateral ligament was repaired.
- The intact medial column was used to assess length, alignment and rotation.

### 3. Conclusion

Total elbow arthroplasty though a challenging procedure, when performed for the right indication in the right patient has been shown to be an effective treatment option. There are specific technical challenges for the common indications, and these need appropriate preoperative planning, and intraoperative strategies to prevent or manage complications.

### Author statement file

**Sudhakar Rao Challagundla:** Writing - Original Draft, Writing - Review & Editing, Visualization. **Scott Barker:** Writing - Review & Editing, Supervision. **Kapil Kumar:** Conceptualization, Writing - Review & Editing, Supervision.

### Declaration of competing interest

None.

### References

- Klug A, Gramlich Y, Buckup J, et al. Trends in total elbow arthroplasty: a nationwide analysis in Germany from 2005 to 2014. *Int Orthop*. 2018;42:883–889. <https://doi.org/10.1007/s00264-018-3818-x>.
- National joint registry for england wales and northern Ireland. 17th annual report. <https://reports.njrcentre.org.uk/Portals/0/PDFdownloads/NJR%2017th%20Annual%20Report%202020.pdf>; 2020. Accessed November 24, 2020.
- Samdanis V, Manoharan G, Jordan RW, et al. Indications and outcome in total elbow arthroplasty: a systematic review. *Shoulder Elbow*. 2020 Oct;12(5):353–361. <https://doi.org/10.1177/1758573219873001>.
- Viveen J, van den Bekerom MPJ, Doornberg JN, et al. Use and outcome of 1,220 primary total elbow arthroplasties from the Australian orthopaedic association national joint arthroplasty replacement registry 2008–2018. *Acta Orthop*. 2019 Dec;90(6):511–516. <https://doi.org/10.1080/17453674.2019.1657342>.
- Kwak JM, Koh KH, Jeon IH. Total elbow arthroplasty: clinical outcomes, complications, and revision surgery. *Clin Orthop Surg*. 2019 Dec;11(4):369–379. <https://doi.org/10.4055/cios.2019.11.4.369>.
- Goodman SM, Springer B, Guyatt G, et al. American college of rheumatology/ American association of hip and knee surgeons guideline for the perioperative management of antirheumatic medication in patients with rheumatic diseases undergoing elective total hip or total knee arthroplasty. *J Arthroplasty*. 2017;32(9):2628–2638. <https://doi.org/10.1016/j.arth.2017.05.001>, 2017 Sep.
- Inglis AE, Inglis Jr AE. Ipsilateral total shoulder arthroplasty and total elbow replacement arthroplasty: a caveat. *J Arthroplasty*. 2000 Jan;15(1):123–125. [https://doi.org/10.1016/s0883-5403\(00\)91441-4](https://doi.org/10.1016/s0883-5403(00)91441-4).
- Gill DR, Cofield RH, Morrey BF. Ipsilateral total shoulder and elbow arthroplasties in patients who have rheumatoid arthritis. *J Bone Joint Surg Am*. 1999 Aug;81(8):1128–1137. <https://doi.org/10.2106/00004623-199908000-00008>.
- Szyluk K, Widuchowski W, Jasiński A, Koczy B, Widuchowski J. Comparison of short- to medium-term results of Coonrad-Morrey elbow replacement in patients with rheumatoid arthritis versus patients after elbow injuries. *Med Sci Mon Int Med J Exp Clin Res*. 2013 Jan 7;19:18–27. <https://doi.org/10.12659/msm.883725>.
- Morrey BF, Adams RA, Bryan RS. Total replacement for post-traumatic arthritis of the elbow. *J Bone Joint Surg Br*. 1991 Jul;73(4):607–612. <https://doi.org/10.1302/0301-620X.73B4.2071644>.
- Schuster I, Korner J, Arzendorf M, Schwieger K, Diederichs G, Linke B. Mechanical comparison in cadaver specimens of three different 90-degree double-plate osteosyntheses for simulated C2-type distal humerus fractures with varying bone densities. *J Orthop Trauma*. 2008 Feb;22(2):113–120. <https://doi.org/10.1097/BOT.0b013e3181632cf8>.
- Gupta RK, Gupta V, Marak DR. Locking plates in distal humerus fractures: study of 43 patients. *Chin J Traumatol*. 2013;16(4):207–211.
- McKee MD, Veillette CJ, Hall JA, et al. A multicenter, prospective, randomized, controlled trial of open reduction–internal fixation versus total elbow arthroplasty for displaced intraarticular distal humeral fractures in elderly patients. *J Shoulder Elbow Surg*. 2009;18:3–12. <https://doi.org/10.1016/j.jse.2008.06.005>.
- Brownhill JR, Pollock JW, Ferreira LM, Johnson JA, King GJ. The effect of implant malalignment on joint loading in total elbow arthroplasty: an in vitro study. *J Shoulder Elbow Surg Am*. 2012;21:1032–1038. <https://doi.org/10.1016/j.jse.2011.05.024>.
- Sabo MT, Athwal GS, King GJ. Landmarks for rotational alignment of the humeral component during elbow arthroplasty. *J Bone Joint Surg Am*. 2012 Oct 3;94(19):1794–1800. <https://doi.org/10.2106/JBJS.J.01740>.
- Duggal N, Dunning CE, Johnson JA, King GJ. The flat spot of the proximal ulna: a useful anatomic landmark in total elbow arthroplasty. *J Shoulder Elbow Surg*. 2004 Mar-Apr;13(2):206–207. <https://doi.org/10.1016/j.jse.2003.11.003>.
- King A, Booker SJ, Thomas WJ, Smith CD. Triceps on, alignment off? A comparison of total elbow arthroplasty component positioning with a triceps-on and a triceps-off approach. *Ann R Coll Surg Engl*. 2018 Aug 16;100(8):1–6. <https://doi.org/10.1308/rcsann.2018.0117>.
- Parvizi J, Zmistowski B, Berbari EF, et al. New definition for periprosthetic joint infection: from the workgroup of the musculoskeletal infection society. *Clin Orthop Relat Res*. 2011 Nov;469(11):2992–2994. <https://doi.org/10.1007/s11999-011-2102-9>.
- Kunutsor SK, Beswick AD, Whitehouse MR, Blom AW. One- and two-stage surgical revision of infected elbow prostheses following total joint replacement: a systematic review. *BMC Musculoskel Disord*. 2019 Oct 22;20(1):467. <https://doi.org/10.1186/s12891-019-2848-x>.
- Rangan A, Falworth M, Watts AC, et al. Investigation and management of periprosthetic joint infection in the shoulder and elbow: evidence and consensus based guidelines of the British elbow and shoulder society. *Shoulder Elbow*. 2018 Jul;10(1 Suppl):S5–S19. <https://doi.org/10.1177/1758573218772976>.
- M.J. Kraay. Cemented component removal: tricks of the trade. *Orthopaedic Proceedings Vol. 97-B, No. SUPP\_1, 52*.
- Peach CA, Salama A, Stanley D. Humeral windows in revision total elbow arthroplasty. *Shoulder Elbow*. 2016 Apr;8(2):130–133. <https://doi.org/10.1177/1758573216630946>.
- Ehrendorfer S. Elbow revision arthroplasty in the situation of bone loss using an unlinked long-stem prosthesis. *J Hand Surg Am*. 1999 Nov;24(6):1337–1343. <https://doi.org/10.1053/jhsu.1999.1337>.
- Tsiridis E, Indar R, Narvani AA, Bayley JJ. Revision total elbow arthroplasty with impaction allografting and uncemented partially hydroxyapatite-coated custom-made prostheses. *Am J Orthoped*. 2004 Aug;33(8):393–396.
- Mansat P, Adams RA, Morrey BF. Allograft-prosthesis composite for revision of catastrophic failure of total elbow arthroplasty. *J Bone Joint Surg Am*. 2004 Apr;86(4):724–735. <https://doi.org/10.2106/00004623-200404000-00009>.
- Kamineni S, Morrey BF. Proximal ulnar reconstruction with strut allograft in revision total elbow arthroplasty. *J Bone Joint Surg Am*. 2004 Jun;86(6):1223–1229. <https://doi.org/10.2106/00004623-200406000-00015>. PMID: 15.
- Yamaguchi K. Advanced reconstruction elbow. In: Yamaguchi K, King G, McKee M, O'Driscoll S, eds. *American Academy of Orthopaedics*; 2007.





## Review article

# Functional outcomes are improved after rotator cuff repair in the Indian population: A systematic review



Manit Arora, Sidhartha Sohan\*, Avinash K. Sinha

Department of Orthopaedics &amp; Sports Medicine, Fortis Hospital, Mohali, India

## ARTICLE INFO

## Article history:

Received 28 September 2020

Received in revised form

1 December 2020

Accepted 8 December 2020

Available online 14 December 2020

## Keywords:

Outcomes

Function

Rotator cuff

Rotator cuff repair

Review

Indians

## ABSTRACT

**Introduction:** The vast Indian population represents a potential case load of rotator cuff (RC) tears in the millions and repair options include both open and arthroscopic techniques. Indian shoulders are different from Western shoulders both in terms of morphology and functional demand. Despite this, the uptake of shoulder surgery in India has been extremely slow, due to various factors.

**Aims/objective:** The purpose of this review is to better understand functional outcomes of rotator cuff repair (RCR) in the Indian population. This will help Indian surgeons to discuss outcomes with their patients in an evidence based manner and provide for cross study comparisons of new data.

**Methods:** A search of online databases (Cochrane, Embase, Medline and Google Scholar) was performed for the period of January 2001–March 2020. Specific inclusion and exclusion criteria were adopted for the purposes of systematic review according to PRISMA guidelines. The primary outcome was assessment of functional outcome using validated instruments (such as UCLA score, ASES score etc.).

**Results:** A total of fourteen studies representing a pooled patient population set of 785 patients were included in this review. Of the fourteen studies included in this review, a total of three studies evaluated functional outcomes after mini-open repair whereas eleven studies evaluated outcomes after arthroscopic rotator cuff repair (ARCR). The pooled mean outcome measured showed significant improvement (pre-operative vs post-operative; average follow-up); C&M score (29 (+/- 17) vs 85 (+/- 5); 12 months), UCLA (11 (+/- 5) vs 31 (+/- 1); 26 months), ASES (25 (+/- 5) vs 84 (+/- 4); 12 months), and VAS (8 (+/- 1) vs 1.0; 22 months).

**Conclusion:** Overall the studies included in this systematic review show a significant improvement in functional outcomes. Both mini-open and arthroscopic repair offer favourable outcomes for RCR in the Indian population, and there appears to be no difference in outcome measures between single and double row repairs. Most of the studies included in this systematic review offer weak evidence and are underpowered, hence further studies with more patients and better design are needed to validate these findings.

**Level of Evidence:** Systematic review Level III.

© 2020 Published by Elsevier, a division of RELX India, Pvt. Ltd on behalf of International Society for Knowledge for Surgeons on Arthroscopy and Arthroplasty.

## 1. Introduction

India, with its 1.3 billion population, represents a potential caseload of rotator cuff (RC) tears in the millions. Globally there is a

RC tear prevalence of approximately 40% in asymptomatic individuals which increases to about 65% in symptomatic individuals.<sup>1</sup> Surgical repair of RC tears is a cost-effective solution for all populations and reduces the social burden of the disease.<sup>2</sup> Surgical techniques have evolved from open to arthroscopic rotator cuff repairs (ARCR),<sup>3</sup> with ARCR numbers showing a 600% increase in the United States over the last decade,<sup>4</sup> however the country specific data for the Indian surgeon community is lacking.

Despite the potential high caseload of RC tears in India and the perceived increasing number of arthroscopies being performed in the country, various challenges specific to the Indian setting inhibit

*Abbreviations:* ARCR, arthroscopic rotator cuff repair; ASES, American Shoulder and Elbow Society; C&M, Constant & Murley; OSS, Oxford Shoulder Score; RC, rotator cuff; RCR, rotator cuff repair; UCLA, University of California Los Angeles.

\* Corresponding author. Dept. of Orthopaedic, Fortis Hospital, Mohali, India.

*E-mail addresses:* [manit.arora@fortishealthcare.com](mailto:manit.arora@fortishealthcare.com) (M. Arora), [drsiddharthasohan@gmail.com](mailto:drsiddharthasohan@gmail.com) (S. Sohan).

the rapid uptake of ARCR. These include infrastructure issues (lack of capital arthroscopy equipment in most hospitals and lack of maintenance chains), training issues (lack of adequate shoulder training in most government and private colleges in India, lack of shoulder fellowship/training opportunities in-land and lack of shoulder specific faculty), and patient issues (lack of acceptance for shoulder procedures, societal stigma of shoulder surgeries due to infrequency and suggested varied outcomes, and lack of patient education with regards to shoulder pathology).

From an anatomical point of view, Indian shoulders are different to Western shoulders. Glenoid and humeral head dimensions of Indian patients, especially females, tend to be smaller than Western counterparts.<sup>5–7</sup> With a reduced head size, the biological footprint of the rotator cuff should also be reduced; however, there is a paucity of literature on Indian cuff morphology. The potential of the reduced head dimensions and possible reduction in cuff dimensions on the type of repair should be explored in future studies.

The purpose of this systematic review is to review is to summarize the available Indian data on RC repairs (RCR) and to provide insights for functional outcome measures specific to the Indian population. This will provide validated outcome data that Indian surgeons can use for shared decision making with patients, provide reference data for future studies in the field and address the general conceptions/misconceptions about shoulder surgery amongst Indian orthopaedic surgeons.

## 2. Method

### 2.1. Criteria for considering studies for this review

A scoping search was initially undertaken in March 2020 to inform the definition used in the final search strategy and corresponding inclusion criteria, which was then used to search for and identify relevant studies. The finalised criteria applied to address the research question were as follows: “rotator cuff repair” AND/OR “India” AND/OR “Indian” AND/OR “arthroscopic rotator cuff” AND/OR “mini-open rotator cuff” AND/OR “cuff repair”. Various synonyms of the above terms were used during the scoping searches.

### 2.2. Types of participants

Studies evaluating Indian adults (18 years and above of age) who underwent surgical repair of rotator cuff tears were included. No restrictions were applied to comorbidities, type of tear, tendon involvement, or based on whether the tear is a first occurrence or a re-tear. Studies in which there was a mixed population set including patients undergoing RCR were also included.

### 2.3. Types of interventions

All studies where at least one treatment arm included cuff repair were included. Studies had either a single intervention group or two or more intervention groups. There was no restriction with regards to any comparison arm (physiotherapy, medications etc). There was no restriction with regard to any technique of RCR –open, mini-open and ARCR were all included. There was no exclusion based on the type of ARCR done (ie. Single row versus double row). There was no restriction on the grade or experience of the surgeon completing the surgery.

Studies reporting on non-relevant interventions only, such as drug therapy or physiotherapy, were excluded; however if these interventions represent a comparator arm they were included. This means that studies which only assessed medications or physiotherapy for the treatment of RC tears were excluded, however any study that compared these treatment to RCR surgery was included.

### 2.4. Types of outcome measures

The primary outcomes of interest included, but were limited to shoulder-specific function scores measured using a validated scale such as Oxford Shoulder Score (OSS), American Shoulder and Elbow Surgeon Score (ASES). Disabilities of Arm Shoulder and Hand (DASH) questionnaire, Constant and Murley Score (C&M) and University of California at Los Angeles scale (UCLA). The aforementioned scores are the only scores that were included as validated outcome measures in the review. Secondary outcomes included pain, re-tear rate, revision rate, complications and patient satisfaction were included if mentioned in the respective studies.

### 2.5. Types of studies

This review planned to consider only randomized controlled trials. However, due to the lack of studies in this category for the Indian population, the scoping search was expanded to all studies regardless of level of evidence. These included non-randomized studies (comparative and single intervention groups) involving greater than 5 patients. No language restrictions were applied and methods of translation were to be explored for any non-English included studies that were identified.

In vitro and animal studies were excluded in addition to review articles, editorials and single case studies. Initial scoping results did not identify any economic or cost evaluation studies relating to RCR in the Indian population and therefore were not included in this review.

### 2.6. Search methods for the identification of studies

A search strategy was developed in Embase and was adapted for other electronic databases. The searches were conducted between the dates of January 2001 to March 2020, representing 20 years of knowledge. The following electronic databases were searched via the OVID and Cochrane Library platforms using the predefined search strategy:

- (i) The Cochrane Library
- (ii) Ovid Medline, 1946 to present
- (iii) Ovid Embase, 1980 to present
- (iv) Google Scholar, 2001 to present

Reference lists of available studies and any reviews were scanned in addition to identify further studies.

### 2.7. Selection of studies

Two lead researchers (MA and SS) screened all titles and abstracts identified from the search strategy independently. Full reports were obtained if the initial screening indicated that the identified studies were potentially relevant. Full reports that meet the inclusion criteria were to be included in this review. Reasons for exclusion were recorded at each stage and detailed in a PRISMA flow diagram (Fig. 1). A third independent reviewer (AKS) was kept on standby to resolve any disputes between the primary two reviewers if they were to occur. The search methodology and study selection was conducted in accordance with PRISMA guidelines.

### 2.8. Data extraction, management and evidence synthesis

A standard data extraction table was used to extract all relevant data from studies including study design, patient population and functional outcomes.

Due to the paucity of available studies, a standard meta-analysis

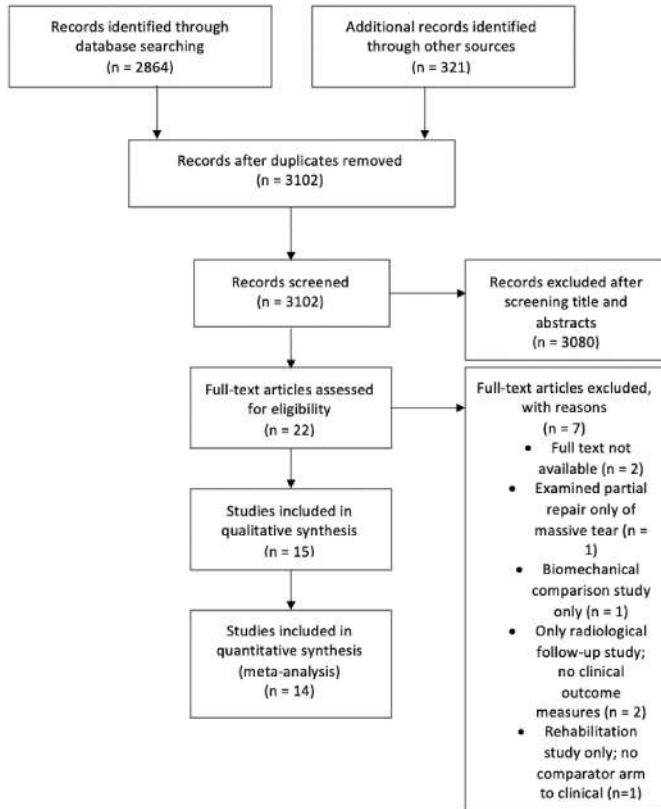


Fig. 1. PRISMA flow diagram of study methodology for this systematic review on functional outcome of rotator cuff repair in the Indian population.

was not possible; hence, the methods and results of this review were written in a qualitative manner. A narrative summary of the evidence was produced and where appropriate tables reported the study design, patient population, and functional outcomes of included papers. An overall pooled comparison was undertaken.

### 2.9. Pooled data comparison

As many studies used common functional outcome measures, it was possible to do a pooled analysis of average means across studies using the following formula:

$$\text{Average mean} = \frac{\sum\{(n_1 \times \text{mean}_1) + (n_2 \times \text{mean}_2) + \dots + (n_n \times \text{mean}_n)\}}{\sum(n_1 + n_2 + \dots + n_n)}$$

$n$  = study population (study 1, study 2 etc)

mean = overall mean of the study population

Pooled means and standard deviations were generated with 95% confidence intervals and Mann-Whitney Test was done to compare grouped data. Further, pre and post-operative means were presented as grouped data and compared using Wilcoxon signed rank test with SPSS version 16 software. A definition of statistical significance was used with a p-value less than 0.05.

## 3. Results

### 3.1. General data

A total of fourteen studies (Tables 1 and 2) were included in this review representing a pooled population of 785 patients – three mini-open studies and eleven ARCR studies. Two of these latter studies compared single row to double row repairs. Most studies used UCLA, Constant and ASES scores for comparison of functional outcomes.

The pooled average means for the Indian population are presented in (Table 3 & Fig. 2). UCLA was assessed across nine studies, C&M score across six studies, ASES across five studies and OSS in only one study. Secondary outcome measure of pain VAS was assessed across four studies. The mean C&M score changed from  $29 \pm 17$  in the pre-operative period to  $85 \pm 5$  at an average follow-up of 12 months, the UCLA from a pre-operative of  $11 \pm 5$  to a post-operative of  $31 \pm 1$  at an average follow-up of 26 months, the ASES from a pre-operative of  $25 \pm 5$  to a post-operative of  $84 \pm 4$  at an average follow-up of 12 months, and the VAS from a pre-operative of  $8 \pm 1$  to a post-operative of 1.0 at an average follow-up of 22 months. 95% Confidence intervals were charted for CM and UCLA scores as they had high pooled number of studies compared to other scores (Table 3).

Of these changes in functional outcome measures across the study durations (Table 4), the difference in pooled mean scores for ASES, UCLA and C&M scores assume statistical significance with p-values of 0.043, 0.008 and 0.027 respectively. The change in VAS pooled mean scores, although sizeable, was not statistically significant with p-value of 0.066. Pooled mean changes for OSS could not be calculated as only one study examined OSS.

Further, pooled data comparisons for mini-open vs arthroscopic and other sub-analysis were not done as there was low number of pooled studies in the various arms which would underpower the analysis.

### 3.2. Mini-open cuff repair

All three mini-open studies<sup>8–10</sup> (Tables 1 and 2) show significant improvement in functional outcome measures over their respective study durations. Vaidyar et al. (2015) included both partial thickness (which were converted to full thickness tears for repair) and full thickness tears and found no significant difference in functional outcomes in either group at end of follow-up period; with both groups showing significant functional improvement from base-

line.<sup>8</sup> These results were supported by Sharma et al. (2018) in their twenty patient cohort study of mini-open repairs for full thickness tears only.<sup>9</sup> Both studies are severely limited by being underpowered and with short follow-ups. A more recent and larger study by Bashir et al. (2018) of non-massive full thickness tears compared outcomes between degenerative and traumatic tears and found significant improvement in both groups from baseline.<sup>10</sup> They found no significant difference in outcomes with respect to tear

**Table 1**

Study characteristics of included studies in the review. C&M = Constant Murley Score; UCLA – University of California Los Angeles Score; ASES – American Shoulder and Elbow Society score; VAS – Visual Analogue Scale; and OSS – Oxford Shoulder Score.

Study Name (Author and Year)	Type of Study (Prospective/Retrospective)	Number of Patients	Study Duration (months)	Scoring System Used
VAIDYAR et al. 2015	PROSPECTIVE	30	24	C&M
VORA et al.2017	PROSPECTIVE	25	12	UCLA and ASES
KUMAR and JADHAV 2014	PROSPECTIVE	25	21	UCLA and VAS
BASHIR et al. 2018	PROSPECTIVE	50	58	UCLA
KARAN et al. 2018	RETROSPECTIVE	40	6	CC&M
MENON et al. 2014	PROSPECTIVE	30	20	UCLA
BHABHULKAR et al. 2019	RETROSPECTIVE	97	24	VAS,OSS
SHARMA et al., 2018	PROSPECTIVE	20	6	C&M and UCLA
KAMAT et al.2019	PROSPECTIVE	32	12	C&M AND UCLA
DESHMUKH et al.2017	PROSPECTIVE	25	13	ASES,VAS
PANDEY et al., 2016	RANDOMIZED CONTROLLED TRIAL	102	24	VAS, UCLA, ASES AND C&M
PANDEY et al., 2019	RETROSPECTIVE COMPARATIVE	233	45	ASES and C&M
VAMSINATH et al. (2018)	PROSPECTIVE	22	12	UCLA and ASES
BHANDARY et al. (2019)	RETROSPECTIVE	54	29	UCLA

**Table 2**

Functional outcomes descriptive statistics for studies included in this systematic review. Significance in each study was defined by the authors as a net significant change between pre-operative score and score at the end of average follow-up. This significance was based on the respective authors assessment. C&M = Constant Murley Score; UCLA – University of California Los Angeles Score; ASES – American Shoulder and Elbow Society score; VAS – Visual Analogue Scale; and OSS – Oxford Shoulder Score.

Study Name (Author and Year)	Scoring System Used	Mean Pre-operative Score	Mean Post-operative Score	Significant Change (Yes/No)	Complications and Failures
VAIDYAR et al. 2015	C&M	C&M-60	C&M-92	YES	No retear; no other complications mentioned
VORA et al.2017	UCLA and ASES	UCLA-12,ASES-31	UCLA-31,ASES-77	YES	36% patients had severe pain or were unable to use limb
KUMAR and JADHAV 2014	UCLA and VAS	UCLA-16,VAS-7	UCLA-30,VAS-1	YES	3 patients had complications; 1 retear and 2 superficial infections
BASHIR et al. 2018	UCLA	UCLA-11	UCLA-31	YES	2 patients had post-operative stiffness
KARAN et al. 2018	CC&M	C&M – 23	C&M 80	Yes	3 patients had post-operative stiffness
MENON et al. 2014	UCLA	UCLA-14	UCLA-32	YES	2 possible retears not investigated
BHABHULKAR et al. 2019	VAS,OSS	VAS-8,OSS-11	VAS-1,OSS-44	YES	3 patients had post-operative stiffness and 2 had infections
SHARMA et al., 2018	C&M and UCLA	CC&M-8,UCLA-5	C&M-86,UCLA30	YES	No complications
KAMAT et al.2019	C&M AND UCLA	C&M-21,UCLA-9	C&M-81,UCLA-32	YES	1 patient had anchor failure and 1 had infection
DESHMUKH et al.2017	ASES,VAS	ASES-18,VAS-9	ASES-83,VAS-1	YES	3 patients had post-operative stiffness and 1 had infection
PANDEY et al., 2016	VAS, UCLA, ASES AND C&M	C&M – 30; UCLA – 6; ASES – 24; VAS - 8	C&M – 90; UCLA – 33; ASES – 87; VAS - 1	YES	7 patients had retear
PANDEY et al., 2019	ASES and C&M	C&M – 31; ASES - 29	C&M – 82; ASES - 86	YES	25% non complete healing rate
VAMSINATH et al., 2018	UCLA and ASES	UCLA – 9; ASES - 23	UCLA – 29; ASES - 87	YES	4 patients had post-operative stiffness
BHANDARY et al., 2019	UCLA	UCLA - 19	UCLA - 32	YES	Zero complications

**Table 3**

Descriptive statistics for UCLA and CM scores using pooled mean analysis. ASES 95% CI intervals are not calculated due to low number of studies. CI = Confidence Interval; UCLA = University of California Los Angeles; CM = Constant and Murley; ASES = American Shoulder and Elbow Society.

Score	N (number of studies)	Mean	Standard Deviation	95% CI lower bound	95% CI upper bound
UCLA Pre-operative	9	11.22	4.58	7.70	14.74
UCLA Post-operative	9	31.11	1.27	30.14	32.09
CM Pre-operative	6	28.83	17.46	10.62	47.05
CM Post-operative	6	85.17	5.00	79.92	90.41
ASES Pre-operative	5	25.00	5.15	18.61	31.39
ASES Post-operative	5	84.00	4.24	78.73	89.27

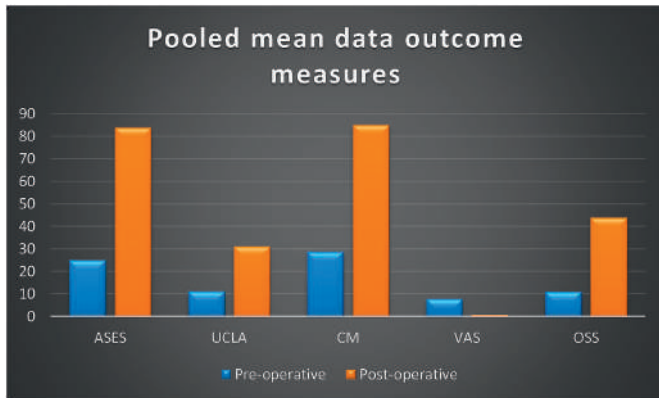
aetiology (traumatic vs degenerative) but did find that tear size does correlate with functional outcomes after RCR, with smaller tears having better outcomes than larger tears after a mini-open repair.

A direct statistical comparison of mini-open to ARCR studies was performed and found no statistically significant difference in pre-operative and post-operative average means for ASES, UCLA and C&M scores (Table 5).

### 3.3. Arthroscopic rotator cuff repair (ARCR)

All Indian studies of ARCR showed significant improvement in functional outcomes (Tables 1 and 2). A number of Indian studies<sup>11–15</sup> have used a single row construct with a minimal complication rate. Two of the studies<sup>11,12</sup> are severely limited by being underpowered, having a short follow-up duration (six months) and using a single row construct even for larger tears, which the authors justified was due to cost issues. Menon and Sheikh (2014), despite





**Fig. 2.** Pooled review mean data for functional outcome measures (C&M, UCLA and ASES scores) comparing net yield average pre-operative score and average post-operative score with varied average follow-ups as defined in text. ASES = American Shoulder and Elbow Society; UCLA = University of California Los Angeles; CM = Constant and Murley; VAS = Visual Analogue Scale.

having a longer follow-up still remains underpowered and used only a single anchor construct placed in the lateral cortex with multiple suture limbs passed through the cuff. Kamat et al. (2019) also studied single row ARCR with good improvement in functional outcomes for their cohort when testing the addition of a microfracture to improve healing, as per the Southern California Orthopaedic Institute technique.<sup>15</sup> The study was both underpowered and also did not have a comparator arm for assessment of the microfracture technique versus non-microfracture. Additionally, it included only small and medium sized tears in the study population. One of the larger studies on ARCR using single row repair, Bhandary et al. (2019) had a two year follow-up period but used a retrospective analysis model with only a single outcome measure in UCLA.<sup>14</sup> Further, the authors descriptively noted various confounding factors (such as tear aetiology, smoking history etc.) but did not include them into a subgroup analysis to identify potential impact on outcomes.

The above five studies demonstrate good functional outcomes for single row ARCR in the Indian population however they do not assess factors influencing outcomes. Vora et al. (2018) studied age,

gender and tear aetiology as a confounding factors. They found that a younger age (less than 40 years) and traumatic tears (versus degenerative tears) had better outcomes. Gender did not influence outcomes.<sup>16</sup> However, 20% of patients complained of functional disability at the end of follow-up and 16% complained of severe pain at the end of follow-up.<sup>16</sup> The influence of age as a confounding factor on functional outcomes was also studied by Babhulkar et al. (2019) who found significant functional improvement in the elderly population (over 70 years of age).<sup>17</sup> The authors however did not compare their study cohort to a younger population with significant patient selection bias. This bears importance in the Indian setting as with the large patient population there is a high case load of degenerative cuff tears in the elderly in addition to the traumatic tears in younger individuals.

Another interesting study in the field of ARCR looked at the results for augmentation of repairs with PRP in the Indian population through a randomized controlled trial. Pandey et al. (2016) studied medium to large degenerative tears and found that UCLA and C&M scores were better in the PRP group in the mid-term (12 months) however there was no difference in ASES score.<sup>18</sup> Further they found that the retear rate was 5 times higher in the control arm when compared to PRP at the end of the study period, however it was significant only for the larger tears. Thus for larger tears undergoing ARCR in the Indian setting, supplementation with PRP may reduce retear rates and provide some improvement in functional scores in the mid-term.

### 3.4. Single row versus double row ARCR

The majority of the above studies used a single row technique for ARCR, showing good functional outcomes. Two studies in this review examined the outcomes of single row versus double row ARCR. Ravi and John (2018) compared those undergoing single row (n = 43) and those undergoing double row ARCR (n = 30) over a 12 month period using UCLA and VAS scores. They found no significant differences in either outcome measure between the two groups at the end of the study period.<sup>19</sup> Wade and Salgar (2017) evaluated retear rates in 56 full thickness cuff tears repaired using single row (n = 28) or double row (n = 28) technique over a 6 month period. They found similar functional outcomes between both groups but retear rates in the single row group were about 5 times higher than

**Table 4**

Wilcoxon signed rank tests data comparing functional outcome measures for pre and post-operative mean pooled data. P-value defined as statistical significance at probability of <5% (<0.05). ASES = American Shoulder and Elbow Society; VAS = Visual Analogue Scale; UCLA = University of California Los Angeles; OSS = Oxford Shoulder Score; CM = Constant and Murley; Pre = pre-operative; Post = post-operative.

		N	Mean Rank	Sum of Ranks	Wilcoxon Signed Ranks (z)	p-value
ASES-Post - ASES-Pre	Negative Ranks	0	0.00	0.00	2.023	.043*
	Positive Ranks	5	3.00	15.00		
	Ties	0				
	Total	5				
UCLA-Post - UCLA-Pre	Negative Ranks	0	0.00	0.00	2.668	.008**
	Positive Ranks	9	5.00	45.00		
	Ties	0				
	Total	9				
VAS-Post - VAS-Pre	Negative Ranks	4	2.50	10.00	1.841c	.066
	Positive Ranks	0	0.00	0.00		
	Ties	0				
	Total	4				
OSS-Post - OSS-Pre	Negative Ranks	0	0.00	0.00		
	Positive Ranks	1	1.00	1.00		
	Ties	0				
	Total	1				
CM-Post - CM-Pre	Negative Ranks	0	0.00	0.00	2.207	.027*
	Positive Ranks	6	3.50	21.00		
	Ties	0				
	Total	6				

**Table 5**

Mann-Whitney *U* test was performed to compare the pre and post-operative average means for all mini-open studies (Group A) and all arthroscopic studies (Group B). *p*-value assumes statistical significance at < 0.05. ASES = American Shoulder and Elbow Society; UCLA = University of California Los Angeles; CM = Constant and Murley; VAS = Visual Analogue Scale.

Group	N	Mean Rank	Sum of Ranks	Mann-Whitney U (z)	<i>p</i> -value
ASES-Pre	A 1	2.00	2.00	.480	0.8
	B 4	3.25	13.00		
UCLA-Pre	A 3	4.63	18.50	.712	0.73
	B 6	5.30	26.50		
VAS-Pre	A 0	0.00	0.00	1.000	1
	B 4	2.50	10.00		
CM-Pre	A 2	3.50	7.00	.277	0.4
	B 4	3.50	14.00		
ASES-Post	A 1	4.50	4.50	.209	0.286
	B 4	2.63	10.50		
UCLA-Post	A 3	3.75	15.00	.165	0.267
	B 6	6.00	30.00		
VAS-Post	A 0	0.00	0.00		
	B 4	2.50	10.00		
CM-Post	A 2	5.00	10.00		
	B 4	2.75	11.00		

in the double row group.<sup>20</sup> However, this latter study has a very high retear rate in general for the single row group (approximately 39%) which may have been standardized against the surgeon's preferred technique and suffers from a very short duration follow-up. Further when compared to similar Indian studies using only a single row technique, the high retear trend appears not to be validated.<sup>12,21</sup>

Two studies<sup>22,23</sup> included both single and double row repairs in their study population but did not do a direct comparison of both groups statistically. While both studies showed significant improvements in functional outcomes for ARCR over their respective study durations, the former study<sup>22</sup> suffers from both a small sample size and short follow-up duration, whereas the latter study<sup>23</sup> was adequate powered and with sufficiently large follow-up to determine end points. Interestingly, Pandey et al. (2019) found that there was no difference in healing rates or outcome measures between delaminated and non-delaminated tears. This is important to the Indian setting as patients tend to present later rather than earlier to seek medical care.

## 4. Discussion

### 4.1. Mini-open rotator cuff repair

The last two decades have witnessed a global trend towards ARCR and away from mini-open cuff repairs. In the Indian scenario, lack of trained arthroscopy surgeons, high capital equipment costs for arthroscopy, lack of government sector arthroscopy practice, and various other factors control the expansion of the ARCR market. Consequently, both mini-open cuff repair and ARCR continue to thrive in the Indian shoulder ecosystem.

Despite a global trend towards ARCR, systematic reviews comparing mini-open to ARCR have found no significant differences for function and pain.<sup>24,25</sup> These systematic reviews have their own limitation due to the small pooled sample size of the collective studies and the short follow-up duration. However, they do show that both techniques can produce similar outcomes when done in good hands.

Our systematic review of Indian patients mirrored these findings. We found significant improvement for functional outcome measures for mini-open repairs and found no significant difference for mini-open studies compared to ARCR studies. Our review's

limitation is that only three studies have analysed mini-open techniques and most of these have examined short term outcomes only with small sample sizes. There is a need for higher level of evidence studies of larger sample size and with longer follow-ups than previous studies to validate the above trends and also provide more functional outcome data of mini-open repairs with respect to the Indian population. There is a need for mini-open studies to analyse factors and variables associated with better outcomes. Glaringly, there is lack of any randomized controlled trial or lower level of evidence study comparing mini-open to ARCR directly in the Indian population.

### 4.2. Arthroscopic rotator cuff repair

In the Indian setting, the uptake of ARCR has been slow due to a plethora of reasons, as detailed above. However over the last decade there has been much interest in India for arthroscopic techniques which is witnessed by the rising trend in arthroscopic research originating from India.<sup>26</sup> Despite systematic reviews and meta-analyses showing the equivocal results of mini-open and arthroscopic RCR, ARCR in the twenty first century continues to be defined as the 'gold standard' for the management of rotator cuff tears. There are many known benefits of ARCR over mini-open including smaller incision, faster recovery, and earlier rehabilitation, however the short, mid and long term outcomes remain the same as mini-open.<sup>24,25</sup>

Our systematic review of Indian studies validates these global outcome studies with similar functional outcomes for mini-open and arthroscopic cuff repairs. More specifically for ARCR, it appears that both the young and elderly population have functional benefits and that gender does not influence outcomes. A common conception among Indian surgeons is that elderly patients and Indian females do poorly after ARCR. This systematic review provides an anti-dote to the misconception. However, a recent cohort study by our centre (under review for publication) does show a trend towards slower return to function for Indian females as compared to Indian males after ARCR. One study included in this review did find that degenerative tears have poorer functional outcomes compared to traumatic tears however further work is required to understand the role of tear aetiology on functional outcomes post RCR in Indian population.

Interestingly, single row ARCR, even for medium and large tears appears to do well in the Indian setting. Cost of implants plays a role in decision making in the Indian scenario (especially in Tier II and III cities) and the ability to provide equivocal outcomes with a single row technique may be a game changer. The global trend for double row repairs stems from the belief that it provides a greater coverage area for healing and perhaps a stronger construct, an idea reinforced by a recent biomechanical review,<sup>27</sup> however multiple reviews have found no clinical differences between single and double row repairs.<sup>28</sup> It appears that despite providing a better interface for healing and a stronger construct, double row does not actually translate to better outcomes. Randomized controlled trials are needed to study the functional outcomes of single versus double row repairs for medium and large tears in the Indian population.

The limitations of our systematic review of ARCR includes only eleven studies with poor level of evidence. Only one of these studies was a randomized controlled trial. The majority of studies are cohort studies which were prospective in nature. However, they do suffer from short follow-ups and small sample sizes, with most of them being underpowered. Additionally, there is a lack of subgroup analysis to determine the role of cofactors and variables on study outcomes. Further studies in this field should focus on subgroup analysis and there is a need for higher level of evidence studies with longer follow-ups and larger sample sizes to examine

both ARCR outcomes and compare single row with double row repairs. Additionally, based on our scoping searches, further studies in the Indian population should add comparator arms including non-operative interventions, such as physiotherapy and oral medications.

#### 4.3. Key findings of the study applicable to the Indian population

- Mini-open and arthroscopic RCR provide equivalent functional outcomes in the short and mid term
- Single and double row ARCR provide equivalent functional outcomes in the short term
- There does not appear to be any age bias on functional outcomes. Elderly patients undergoing ARCR can expect good functional outcomes
- There does not appear to be any gender bias on functional outcomes
- There is a need for larger and longer studies with more standardized functional measures to allow for cross-study and cross-country comparisons

## 5. Conclusion

The pooled study data of this systematic review shows that ARCR achieves good functional outcomes in the Indian population, and that mini-open techniques offer comparable outcomes to ARCR in the Indian setting. Single and double row repair constructs appear to have equivocal functional outcomes. There is a need for higher level of evidence studies with larger sample sizes and longer follow-ups to validate these findings. Further, subgroup analysis to identify variables associated with better functional outcomes need to be better understood.

## Conflict of interest and financial disclosures

There are no financial disclosures from any authors or conflict of interest pertaining to this review.

## Ethics

Ethics approval was granted by the Institutional Ethics Review Committee Board of Fortis Mohali.

## Acknowledgements

We would like to thank Mr. Rajesh Kumar, statistician, for helping with the statistical analysis of data.

## References

1. Sambandam SN, Khanna V, Gul A, Mounasamy V. Rotator cuff tears: an evidence based approach. *World J Orthoped.* 2015 Dec 18;6(11):902–918.
2. Mather RC, Koenig L, Acevedo D, et al. The societal and economic value of rotator cuff repair. *J Bone Joint Surg Am.* 2013 Nov 20;95(22):1993–2000.
3. Randelli P, Cucchi D, Ragone V, de Girolamo L, Cabitza P, Randelli M. History of rotator cuff surgery. *Knee Surg Sports Traumatol Arthrosc Off J ESSKA.* 2015 Feb;23(2):344–362.
4. Colvin AC, Egorova N, Harrison AK, Moskowitz A, Flatow EL. National trends in rotator cuff repair. *J Bone Joint Surg Am.* 2012 Feb 1;94(3):227–233.
5. Kate DR, Chandanwale A, Bahetee B. Study of glenoid and humerus head version in adult human skeleton. *Indian J Clin Anat Physiol.* 2016;3(3):291.
6. Meshram P, Pawaskar A, Kekatpure A. 3D CT scan-based study of glenoid morphology in Indian population: clinical relevance in design of reverse total shoulder arthroplasty. *J Clin Orthop Trauma [Internet];* 2020;36–39. Mar 6 [cited 2020 Jun 9]; Available from: <http://www.sciencedirect.com/science/article/pii/S0976566220300825>.
7. Somesh MS, Prabhu LV, Shilpa K, Pai MM, Krishnamurthy A, Murlimanju BV. Morphometric study of the humerus segments in Indian population. *Int J Morphol.* 2011 Dec;29(4):1174–1180.
8. Vaidyar JM, Kassim Shabir, Shibli Sandeep, Safwan UH. Functional outcome of shoulder following mini open repair for rotator cuff injuries. *Int J Curr Res Rev.* 2015;7(7).
9. Sharma V, Udupadi SV, Sanikop ST, Haveri SM, Patil MY. In: *Assessment of Functional Outcome of Mini-Open Rotator Cuff Repair: A Hospital Based Prospective Study.* 2018.
10. Bashir A, Seth S, Wani IH, Farooq M. Mini-Open Rotator Cuff Tear Repair: An Institutional Experience with a Midterm Follow-Up. :6.
11. Kumar R, Jadhav U. Functional evaluation of patient after arthroscopic repair of rotator cuff tear. *J Clin Orthop Trauma.* 2014 Jun;5(2):84–90.
12. Sangada DK, Pravinkumar J. Single Row Rotator Cuff Repair: A Retrospective Study of 40 Cases [Internet] [cited 2020 Mar 29]. Available from: <https://www.semanticscholar.org/paper/Single-Row-Rotator-Cuff-Repair%3A-A-Retrospective-of-Sangada-Pravinkumar/72a15b35841eb6734b9c3fb29f955f7418731e04>; 2018.
13. Menon A, Sheikh IA. Evaluation of the results of arthroscopic repair of rotator cuff tears: a prospective study [Internet] [cited 2020 Mar 29]. Available from: <https://www.semanticscholar.org/paper/Evaluation-of-the-results-of-arthroscopic-repair-of-Menon-Sheikh/f3f4021c324ba936c540ff27bbf985c2f19c5682>; 2014.
14. Vasu Bangera V, Orthopaedics, Bhandary B, et al. Evaluation of clinical and functional outcomes of arthroscopic single row rotator cuff repair in our institution; a retrospective study. *Indian J Orthop Surg.* 2019 Apr 28;5(1): 15–20.
15. Kamat N, Parikh A, Agrawal P. Evaluation of functional outcome of arthroscopic rotator cuff repair using southern California orthopedic Institute technique. *Indian J Orthop.* 2019;53(3):396–401.
16. Vora DrP, Shah DrV, Patel DrN, Chudasama DrC, Shah DrM, Prabhakar DrM. Results of arthroscopic rotator cuff repair. *Int J Orthop Sci.* 2018 Jan 1;4(1j): 652–655.
17. Babhulkar As MSR, Patil P, Kumar V. In: *CLINICAL OUTCOME OF ARTHROSCOPIC ROTATOR CUFF REPAIR IN PATIENTS 2 AGED 70 YEARS AND OLDER.* 2019.
18. Pandey V, Bandi A, Madi S, et al. Does application of moderately concentrated platelet-rich plasma improve clinical and structural outcome after arthroscopic repair of medium-sized to large rotator cuff tear? A randomized controlled trial. *J Shoulder Elbow Surg.* 2016 Aug 1;25(8):1312–1322.
19. Ravi C, John J. Single-row versus double-row arthroscopic rotator cuff repair: a retrospective study of clinical and functional outcome. *Indian J Sci Res.* 2018;8(2):131–136.
20. Wade R, Salgar S. Clinico-radiological evaluation of retear rate in arthroscopic double row versus single row repair technique in full thickness rotator cuff tear. *J Orthop.* 2017 Jun 1;14(2):313–318.
21. Singh S, Dave PK. Clinical and MR arthrogram evaluation: single verses double-row arthroscopic rotator cuff repair. *J Clin Orthop Trauma.* 2015 Mar 1;6(1):63.
22. V P, Ballal M, Prakashappa TH, Kumar S. A study of functional outcome of arthroscopic rotator cuff repair in rotator cuff tear patients. *Indian J Orthop Surg.* 2018 Jun 15;4(2):204–208.
23. Pandey V, Joseph CJ, Mathai NJ, Acharya KKV, Karegowda LH, Willems WJ. Clinical and structural outcomes after arthroscopic repair of medium- to massive-sized delaminated and nondelaminated rotator cuff tears. *Indian J Orthop.* 2019;53(3):384–391.
24. Huang R, Wang S, Wang Y, Qin X, Sun Y. Systematic review of all-arthroscopic versus mini-open repair of rotator cuff tears: a meta-analysis. *Sci Rep [Internet];* 2016. Mar 7 [cited 2020 Mar 30];6. Available from: <https://www.ncbi.nlm.nih.gov/pmc/articles/PMC4780011/>.
25. Nazari G, MacDermid JC, Bryant D, Dewan N, Athwal GS. Effects of arthroscopic vs. mini-open rotator cuff repair on function, pain & range of motion. A systematic review and meta-analysis. *PLoS One.* 2019 Oct 31;14(10), e0222953.
26. Vaishya R, Patralekh M, Vaish A, Agarwal AK, Vijay V. The top 10 most cited Indian articles in arthroscopy in last 10 years. *Indian J Orthop.* 2017;51(5): 505–515.
27. Wall LB, Keener JD, Brophy RH. Double-row vs single-row rotator cuff repair: a review of the biomechanical evidence. *J Shoulder Elbow Surg.* 2009 Nov 1;18(6): 933–941.
28. Chen M, Xu W, Dong Q, Huang Q, Xie Z, Mao Y. Outcomes of single-row versus double-row arthroscopic rotator cuff repair: a systematic review and meta-analysis of current evidence. *Arthrosc J Arthrosc Relat Surg Off Publ Arthrosc Assoc N Am Int Arthrosc Assoc.* 2013 Aug;29(8):1437–1449.



Contents lists available at ScienceDirect

## Journal of Arthroscopy and Joint Surgery

journal homepage: [www.elsevier.com/locate/jajs](http://www.elsevier.com/locate/jajs)

## The balloon spacer improves outcomes in only a minority of patients with an irreparable rotator cuff tear



Eshan N.H. Oderuth\*, Daniel L.J. Morris, Paul A. Manning, John M. Geoghegan, Ben W. Gooding, Malin D. Wijeratna

Trauma and Orthopaedics, Nottingham University Hospital NHS Trust, Hucknall Rd, Nottingham, NG5 1PB, UK

### ARTICLE INFO

#### Article history:

Received 18 November 2020

Received in revised form

4 January 2021

Accepted 18 January 2021

Available online 23 January 2021

#### Keywords:

Balloon spacer

Rotator cuff tear

### ABSTRACT

**Background:** We report our medium-term outcomes of the balloon spacer in treating irreparable massive rotator cuff tears (MRCT).

**Methods:** Twenty-two patients (17 male:5 female; mean age 68.2 years) had a balloon spacer arthroscopically inserted between September 2013–May 2017 after failing non-surgical management or rotator cuff repair. Oxford Shoulder Scores (OSS) were collected prospectively at baseline and prior to reverse total shoulder replacement (rTSR) or at most recent follow up for those with the balloon spacer still in-situ.

**Results:** A significant OSS improvement at mean follow-up 31.4 months (5–63) was found analysing all patients who had a balloon inserted (23.6 vs 29.6;  $p < 0.02$ ). However, 6 patients (27%) converted to rTSR at a mean time of 11 months post balloon insertion with a mean OSS deterioration of 1.1. Six patients with the balloon still in-situ demonstrated either a deterioration or an OSS improvement less than the minimal clinically important difference (MCID). Three patients had an OSS improvement greater than the MCID but remained symptomatic. Seven patients (32%) had a successful clinical outcome. Patients converting to rTSR or with poor clinical outcomes were significantly older with significantly lower baseline OSS compared to those with the best outcomes.

**Conclusion:** The balloon spacer is effective in a minority of patients in the medium term. The majority either convert to rTSR or remain symptomatic with the risk of failure higher in those who are older with a low baseline OSS.

© 2021 International Society for Knowledge for Surgeons on Arthroscopy and Arthroplasty. Published by Elsevier, a division of RELX India, Pvt. Ltd. All rights reserved.

### 1. Introduction

Managing irreparable massive rotator cuff tears (MRCT) presents a challenging prospect for the orthopaedic surgeon. MRCTs are defined as rotator cuff tears with detachment of 2 or more tendons. This is thought to be an acute on chronic or chronic phenomenon in the majority of cases as the quality of the tendons and muscle belly declines. The tendon further retracts over time making repair success less likely with probable failure if repair is achieved.<sup>1</sup>

Treatment options for irreparable MRCTs have been previously reviewed.<sup>1,2</sup> These options currently range from non-operative (physical therapy/subacromial corticosteroid injection), arthroscopic cuff debridement and subacromial decompression, biceps tenotomy, suprascapular nerve block, superior capsule reconstruction, rotator cuff repair, patch augmentation, latissimus dorsi/pectoralis major transfers and reverse total shoulder arthroplasty. Non-operative management can be an option in low demand patients, while biceps tenotomy has been shown to improve pain and function.<sup>3–5</sup> Subacromial debridement and decompression seem to have a limited role. Suprascapular nerve block (SSNB) is a pain-relieving option at least in the short term, especially if the patient does not want surgery or is not fit.<sup>6</sup> Rotator cuff repair is advocated if the tear is deemed repairable although a re-tear rate between 29 and 52% has been reported.<sup>7–10</sup> Superior capsule reconstruction has been reported to restore superior glenohumeral joint stability and

\* Corresponding author. 30 Hickling Road, Nottingham, NG3 6GW, UK.

E-mail addresses: Eshan786@msn.com (E.N.H. Oderuth), Daniel.morris1@nhs.net (D.L.J. Morris), Paul.manning@circlehealth.co.uk (P.A. Manning), John.geoghegan@nhs.net (J.M. Geoghegan), bgooding@doctors.net.uk (B.W. Gooding), Malinwijeratna@doctors.org.uk (M.D. Wijeratna).



function.<sup>11</sup> Patch repair augmentation in rotator cuff repair has demonstrated promising results, but this depends on the augment material used and seems more suited to higher demand patients with good quality tendons and some mobility of the torn cuff.<sup>12–16</sup> Latissimus dorsi and pectoralis major transfers are more extensive non-arthroplasty options, with the latter more applicable to a patient with a torn subscapularis.<sup>2,17,18</sup> The superiority of one treatment over another is ill-defined for irreparable MRCTs. Once the disease process has progressed to pseudoparalysis/rotator cuff arthropathy then reverse arthroplasty surgery may be the only option. This has shown good early results in patients with pseudoparalysis and/or rotator cuff arthropathy.<sup>1,2</sup>

The balloon spacer is a simple arthroscopic treatment that has been available over the past few years. This seems suited for patients with pain and functional impairment with irreparable MRCTs who have failed non-operative management or previous surgery prior to being considered for joint replacement surgery. The first results of this device were published in 2012. The spacer is a biodegradable synthetic balloon made of poly(L-lactide-co-caprolactone). It is thought to degrade within 12 months but has been reported radiologically via MRI imaging to degrade within 3 years.<sup>19,20</sup> Fibrosis in the space left by the degraded balloon spacer has been reported following MRI analysis.<sup>21</sup> The mode of action of the balloon spacer is postulated to improve shoulder biomechanics by aiding contraction of the deltoid as it lies between the acromion and the humeral head and helping shoulder movement by improving gliding and reducing friction. The long-term mode of action after degradation may be in consequence to the inflammatory response to the spacer forming a capsule which reduces pain by providing a barrier between the humeral head and acromion.<sup>20</sup> The literature is currently lacking in quality comparative studies evaluating the effect of the balloon spacer in MRCTs with 9 case series and 2 non-randomised comparative studies currently available, however all but two studies report good results in the short and medium term respectively.<sup>20–30</sup>

The purpose of this case series is to report the outcomes of 22 patients with irreparable MRCTs treated with the balloon spacer. We assess whether this simple treatment modality would be a viable option in patients with irreparable MRCTs who have failed conservative treatments who have pain and functional symptoms but may not be suitable for more extensive surgical options such as reverse total shoulder replacement (rTSR).

## 2. Materials and methods

### 2.1. Study design

Twenty-two patients who had a balloon spacer arthroscopically inserted for irreparable MRCTs between September 2013–May 2017 were identified. They all had previous arthroscopies either confirming the presence of an irreparable MRCTs or had previous failed rotator cuff repair. All patients failed conservative measures including analgesia, physiotherapy and steroid injections.

Our indications for using the balloon spacer were inclusive of all the following criteria: massive rotator cuff tears of the supraspinatus/infraspinatus not amenable to repair, an intact subscapularis tendon attachment and the absence of significant rotator cuff arthropathy/glenohumeral joint arthritis and active infection. Oxford Shoulder Scores (OSS) were collected at baseline pre-balloon insertion and prior to reverse total shoulder replacement (rTSR) or at their most recent follow-up for those with the balloon spacer still in situ.

### 2.2. Operative technique

All patients had routine pre-operative assessment to assess their fitness for surgery. Anaesthesia was achieved with an interscalene block with or without sedation. Antibiotic prophylaxis as per local guidelines was administered intravenously. Patients were placed in a beach chair position. Diagnostic glenohumeral joint arthroscopy was performed via the posterior portal to confirm the presence of an irreparable MRCT while also assessing the subscapularis attachment and articular surfaces. Via the posterior portal the subacromial space was entered and bursectomy/acromioplasty performed through a lateral portal as required to create space for the balloon spacer. The balloon was then sized according to the subacromial space judged from the width of the acromion anterior to posterior and distance from the greater tuberosity to just medial to the supraglenoid rim. The balloon comes in three sizes small (40 × 50mm), medium (50 × 60mm) and large (60 × 70mm). The balloon was introduced via the lateral portal advancing over the glenoid rim to cover the rotator cuff stump. The protective sheath of the delivery system was pulled back and the balloon exposed. Appropriate positioning of the balloon was confirmed. The balloon was inflated with normal saline to its recommended inflation volume via a Luer-Lock connector. This was done cautiously under direct vision with the camera from the posterior portal to ensure the balloon was inflating while maintaining its position. We ensured the camera was progressively withdrawn as heat from the light source can burst the balloon. The balloon was sealed and the delivery system disengaged. The shoulder was then passively taken through its range of movement checking the balloon position. It is important to check that the balloon has not subluxed/dislocated from its position otherwise it should be replaced. Wounds were closed, dressed and the patient's arm placed in a sling. Patients went home the same day and underwent physiotherapy as per local protocols.

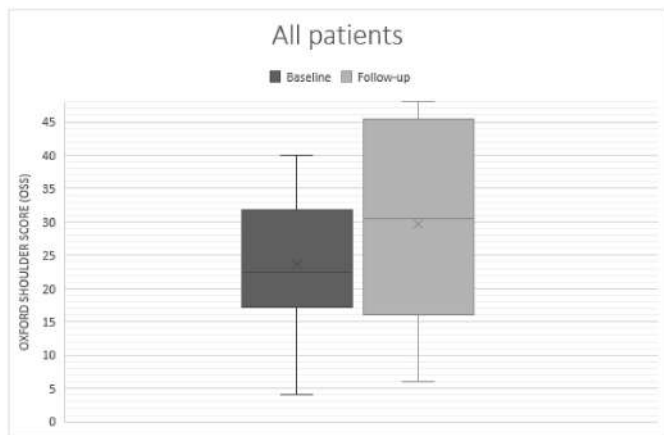
Patients were followed up in a clinic led by a senior physiotherapist with direct access to adjacent orthopaedic clinics run by a surgeon. OSSs were obtained at variable time points in their physiotherapy follow ups and patients were subsequently discharged once their rehabilitation potential had been reached. Those who were not progressing satisfactorily were reviewed by a surgeon for further assessment and management.

The outcome measures used were the OSS and conversion rate to rTSR. We report pre-operative and follow-up scores collected via clinic appointment, phone call or postal questionnaire. Data on the patients' general clinical outcome was also documented.

The OSS is a patient-reported outcome measure (PROM) therefore minimising bias from clinicians.<sup>31</sup> It has been validated against other shoulder scoring systems for assessment of surgical intervention in shoulders.<sup>32</sup> The minimal clinically important difference (MCID) has been reported as 6.0 for the OSS to detect a clinically relevant change.<sup>33</sup>

Statistical analysis of Oxford Shoulder Score results was performed using SPSS (SPSS Inc. SPSS for Windows, Version 17.0. Chicago: SPSS Inc.). Baseline and differential comparative analyses were performed with a two-sample two-tailed Student's T-test assuming unequal variances. Comparative analysis of baseline and follow-up OSS was performed with a paired, two-tailed Student's T-test. Analysis of age differences between the groups was performed using a two-sample T-test assuming unequal variances. Statistical significance was set at 5%. Mean values are reported with standard deviation.

This study was registered with and authorised by our local institution.



**Fig. 1.** Box and whisker plot comparing Oxford Shoulder Scores (OSS) at baseline up to time most recent follow up or pre-reverse total shoulder replacement (rTSR) for all patients.

### 3. Results

Our 22 patients had a mean age of 68.2 years (range 56–81) and mean Hamada staging was  $1.5 \pm 0.5^{1,2}$  pre-balloon insertion. Seventeen patients were male (77%). The mean baseline OSS of all 22 patients was  $23.6 \pm 10.2$  (4–40) and follow up OSS was  $29.6 \pm 14.1$  at 31.4 months (5–63 months) (Fig. I). A significant mean OSS improvement of 6.0 ( $p < 0.02$ ) was demonstrated (Table 1). Three patients had concurrent procedures performed at the time of balloon insertion; 2 biceps tenotomies and 1 ACJ excision. Those who had biceps tenotomies (Patient 12 and 16) had improved OSS and minimal pain. However, the patient that had ACJ excision (Patient 14) had ongoing significant pain despite OSS improvement. However, 27% (6/22) (mean age  $74 \pm 3$  years, range 69–77 years, 50% male) converted to reverse total shoulder replacement at a mean time of 11 months (5–24 months) following balloon spacer surgery. This cohort had a mean deterioration in OSS of 1.1 (baseline  $18.4 \pm 8.9$  vs pre-rTSR  $17.3 \pm 7.4$ ). Two patients had incomplete data (Table I).

In addition to the rTSR patients, 6 patients demonstrated either a deterioration or an OSS improvement of less than the MCID of 6 points. Three patients had an OSS improvement greater than the MCID but remained symptomatic. Seven patients (32%) had a successful clinical outcome.

The patients were split into two groups depending on their clinical outcome for further analysis. Group 1 had a successful clinical outcome defined by having an OSS improvement greater than MCID and having minimal or no pain. Group 1 included 7 patients (6 male [86%], mean age 63 years [56–73] and mean pre-balloon Hamada staging of 1.4 [1–2]). Group 2 was deemed to have had an unsuccessful clinical outcome as they either were in significant pain, had been offered a rTSR but they declined or converted to rTSR. The remaining 15 patients entered this group. Eleven were male (73%). Mean age was 71 years (57–81) and mean Hamada staging was 1.5.<sup>1,2</sup> (Table II).

Group 1 demonstrated a significant mean OSS improvement of 14.6 (baseline  $30.9 \pm 8.4$  vs follow up  $45.4 \pm 3.2$ ,  $p < 0.002$ ) at mean follow up 41.4 months (20–63 months) (Fig. II). All patients in this group had an OSS differential equal to or greater than the MCID of 6.

At mean follow up 26.7 months (5–59 months), Group 2 demonstrated a non-significant OSS improvement of 1.3 (baseline  $19.9 \pm 8.4$  vs follow up/pre rTSR  $21.1 \pm 9.3$ ,  $p < 0.62$ ) which is below the MCID for the OSS (Fig. III). All but four patients (patients 1, 3, 14 and 17) had an OSS differential less than the MCID. Of those four patients one converted to rTSR, two were in significant pain but declined surgery. The final patient of the four persevered in pain which was not deemed severe enough at clinical review to be offered surgery. (Table II).

Inter-group analysis demonstrated that Group 1 were significantly younger compared to Group 2 ( $63.3 \pm 6.5$  years vs  $70.5 \pm 7.7$  respectively,  $p < 0.04$ ) and had significantly higher baseline OSS ( $30.9 \pm 8.4$  vs  $19.9 \pm 8.4$  respectively,  $p < 0.02$ ). The OSS differentials were  $14.6 \pm 6.6$  in Group 1 and  $1.3 \pm 9.2$  in Group 2 (Table II).

A stitch abscess is our only reported complication; this was treated with oral antibiotics.

### 4. Discussion

Our case series has demonstrated inconsistent results for the

**Table 1**

Results for all patients at baseline and at most recent follow up/pre-rTSR. Oxford Shoulder Score (OSS), reverse total shoulder replacement (rTSR).

Patient	Sex	Age	Hamada	Follow-up (months)	Baseline OSS	Follow-up OSS	OSS Baseline vs follow-up differential	Clinical Outcome
1	M	60	2	17	14	32	18	Pain but persevering
2	F	64	1	20	33	44	11	Painfree, doing well
3	M	81	2	27	24	31	7	Significant pain, declined rTSR
4	M	70	1	27	40	30	-10	Pain but persevering
5	M	67	2	28	40	48	8	Painfree, playing cricket
6	M	58	2	28	32	47	15	Pain free
7	M	78	1	32	24	10	-14	Significant pain, declined rTSR
8	M	60	1	38	20	19	-1	Significant pain, declined rTSR
9	M	57	1	39	20	25	5	Significant pain, declined rTSR
10	F	60	2	41	6	6	0	Significant pain, declined rTSR
11	M	73	1	44	31	48	17	Pain free
12	M	56	1	48	40	46	6	Pain free
13	M	76	1	57	22	19	-3	Pain but persevering
14	M	73	1	59	17	33	16	Significant pain, declined rTSR
15	M	68	1	59	23	46	23	Mild pain, plays golf
16	M	57	2	63	17	39	22	Mild pain, working as bricklayer
17	F	75	2	6	4	11	7	Conversion to rTSR
18	M	75	2	11	20	15	-5	Conversion to rTSR
19	F	77	2	6	22	n/a	n/a	Conversion to rTSR
20	F	73	1	12	28	28	0	Conversion to rTSR
21	M	69	1	24	18	15	-3	Conversion to rTSR
22	M	74	2	6	n/a	n/a	n/a	Conversion to rTSR
<b>Mean</b>		<b>68.2</b>	<b>1.5</b>	<b>31.5</b>	<b>23.6</b>	<b>29.6</b>	<b>6.0</b>	

**Table 2**  
Results of Groups 1 (successful clinical outcome) vs Group 2 (unsuccessful clinical outcome). Oxford Shoulder Score (OSS), reverse total shoulder replacement (rTSR).

Patient	Sex	Age	Hamada	Follow-up (months)	Baseline OSS	Follow-up OSS	OSS Baseline vs follow-up differential	Clinical Outcome
<b>Group 1</b>								
2	F	64	1	20	33	44	11	Painfree, doing well
5	M	67	2	28	40	48	8	Painfree, playing cricket
6	M	58	2	28	32	47	15	Pain free
11	M	73	1	44	31	48	17	Pain free
12	M	56	1	48	40	46	6	Pain free
15	M	68	1	59	23	46	23	Mild pain, plays golf
16	M	57	2	63	17	39	22	Mild pain, working as bricklayer
<b>Mean</b>		<b>63.3</b>	<b>1.4</b>	<b>41.4</b>	<b>30.9</b>	<b>45.4</b>	<b>14.6</b>	
<b>Group 2</b>								
1	M	60	2	17	14	32	18	Pain but persevering
3	M	81	2	27	24	31	7	Significant pain, declined rTSR
4	M	70	1	27	40	30	-10	Pain but persevering
7	M	78	1	32	24	10	-14	Significant pain, declined rTSR
8	M	60	1	38	20	19	-1	Significant pain, declined rTSR
9	M	57	1	39	20	25	5	Significant pain, declined rTSR
10	F	60	2	41	6	6	0	Significant pain, declined rTSR
13	M	76	1	57	22	19	-3	Pain but persevering
14	M	73	1	59	17	33	16	Significant pain, declined rTSR
17	F	75	2	6	4	11	7	Conversion to rTSR
18	M	75	2	11	20	15	-5	Conversion to rTSR
19	F	77	2	6	22	n/a	n/a	Conversion to rTSR
20	F	73	1	12	28	28	0	Conversion to rTSR
21	M	69	1	24	18	15	-3	Conversion to rTSR
22	M	74	2	6	n/a	n/a	n/a	Conversion to rTSR
<b>Mean</b>		<b>70.5</b>	<b>1.5</b>	<b>26.8</b>	<b>19.9</b>	<b>21.1</b>	<b>1.3</b>	

balloon spacer in terms of its efficacy as a treatment for irreparable MRCTs. When analysing all patients collectively, they demonstrated a significant mean OSS improvement. However, incorporating OSS MCID and persistent pain into our analysis reveals a medium-term failure of the balloon spacer in 68% (15/22 patients) due to either conversion to rTSR, deterioration in OSS, change in OSS below the MCID or persistent pain. Our experience suggests that those with a poor outcome will convert to rTSR early or will opt to persevere with their significant symptoms and decline further surgery. Those that do well will continue to do so, albeit this cohort is in the minority.

Patients with the best outcomes (Group 1) were significantly younger and had a significantly higher baseline OSS than those in the unsuccessful cohort (Group 2). Given the significant difference between the baseline OSS between the groups this suggests that a higher baseline OSS may be predictive of a better outcome.


However, exceptions were observed with outliers in age and baseline OSS noted in both groups. Consequently, other factors may contribute to this apparent discrepancy in balloon interposition success. We would recommend this be a focus of future research.

However, our experience suggests that the OSS should be used as an adjunct with clinical assessment to determine outcome. All patients in Group 2 were deemed to have had poor clinical outcomes. However, four patients demonstrated OSS improvements above the MCID despite experiencing ongoing intrusive pain. Consequently, one converted to rTSR and two were offered a rTSR.


It should be noted that in group 2 there was a total of six patients in our series who declined further surgery when offered a rTSR despite reporting significant pain.

This data casts scrutiny upon our patient selection given that many patients in Group 1 had a high baseline OSS. However, pre-operative clinical assessment demonstrated that these patients were sufficiently symptomatic to consider this intervention. This cohort experienced the best outcomes in our case series, reinforcing our treatment choice.

Our results reflect those of two case series which have drawn



**Fig. 2.** Box and whisker plot comparing Oxford Shoulder Scores (OSS) at baseline to most recent follow up in Group 1.



**Fig. 3.** Box and whisker plot comparing the Oxford Shoulder Score (OSS) at baseline to most recent follow up/pre-rTSR in Group 2.

**Table 3**  
Summary of results of published balloon spacer studies.

Author	Study	Comparative group	Number	Age (years)	Sex M:F	Follow up	Outcome measure 1	Change in outcome measure 1	Significance	Outcome Measure 2	Change in outcome measure 2	Significance
<b>Basat et al 2016</b> <sup>24</sup>	Case series	n/a	12	64.3±3.55	8:4	38.3 months (mean)	Constant Score	Baseline 25.8 vs 75.4	p = 0.001	Oxford Shoulder Score	Baseline 21.3 vs 42.9	p = 0.001
<b>Deranlot et al 2017</b> <sup>22</sup>	Case series	n/a	37	69.8 (53–84)	15:12	32 months (mean)	Constant Score	44.8 (SD±15.2) to 76.0 (SD±17.1)	p < 0.001			
<b>Gervasi et al 2016</b> <sup>23</sup>	Case series	n/a	15	74±6	7:8	1 and 2 years	Constant Score	Baseline 31.9, 1 year 69.8 and maintained at 2 years for 7/10 patients	p < 0.0001	American Shoulder and Elbow Society Score	Baseline 24.5, 1 year 76 and 2 years 72.5	p < 0.0001
<b>Holschen et al 2017</b> <sup>27</sup>	Case control study	MRCTs treated with conventional treatment of partial repair, debridement and biceps tenotomy (Group A) vs conventional treatment with Balloon Spacer insertion (Group B)	Group A 11 patients, Group B 12 patients	Group A 64.6, Group B 62.4	Group A 6:5, Group B 6:6	22 months	Constant Score	Group A 60.7 vs 77.6, Group B 36.8 vs 69.5	P < 0.001	American Shoulder and Elbow Society Score	Group A 59.1 vs 88.6, Group B 31.5 vs 85.7	P < 0.001
<b>Maman et al 2017</b> <sup>26</sup>	Comparative study	Concurrent Long head of biceps tenotomy	48	Not reported	Not reported	1 year	Constant Score	Baseline 36 vs 67 with LHB tenotomy, Baseline 35 vs 65 without LHB tenotomy	Reported as significant, no values given			
<b>Piekaar et al 2017</b> <sup>25</sup>	Case series	n/a	46	66 (63.7–68.3)	15:19	1 year	Constant Score	Mean improvement 21.58	p < 0.05	Oxford Shoulder Score	Mean increase 10.46	P < 0.002
<b>Prat et al 2018</b> <sup>29</sup>	Case Series	n/a	24	70.7 (57–83)	12:12	14.4 months	University of California at Los-Angeles Shoulder Score	Baseline 10.9 vs 15.9	P < 0.001			
<b>Ricci et al 2017</b> <sup>21</sup>	Case series	n/a	30	65.7	13:17	6, 12 and 24 months	Constant Score	6 months 39.89–62.33, 12 months 41.66–65.38, 24 months 41.8–66.8	6 months p = 0.0002, 12 and 24 months p < 0.0001			
<b>Ruiz et al 2018</b> <sup>30</sup>	Case series	n/a	15			2 years	Constant Score	Baseline 35 vs 53.5	p = 0.02	Conversion to rTSR	5 patients	n/a
<b>Senekovic et al 2016</b> <sup>20</sup>	Case Series	n/a	24	68.8 (54–85)	12:12	5 years	Constant Score	Change at 3 months 14.08, 6 months 17.44 and 5 years 29.85	p < 0.0001			
<b>Yallapragada et al 2018</b> <sup>28</sup>	Case Series	n/a	14	76.2 (70–85)	10:4	12.6 months	Constant Score	Baseline 22.5 vs 51.4 (30–64)	p < 0.001	Oxford Shoulder Score	Baseline 26 vs 48.2	Non-significant
<b>Bakti et al 2019</b> <sup>31</sup>	Case Series	n/a	54	67 (49–80)	19:7	60 months	VAS	Mean difference 2.69	P = 0.012	Oxford Shoulder Score	Mean Difference –8.37 at 24 months, 1.35 at 60 months	P = 0.006, p = 0.701



less favourable conclusions, although showing significant improvements in their outcomes measures.<sup>29,30</sup> (Table III). In Prat et al.'s study, despite the significant increase in the UCLA score, they dismissed this as a small increase and attributed this mainly to a change in the pain domain of the score. They reported 4 post-operative complications including balloon spacer migration, neural damage, superficial infection and deep infection.<sup>29</sup> Similarly, Iban et al. felt it was not appropriate that one third of patients converted to a rTSR and 40% had no perceived benefit.<sup>30</sup>

There are 9 published studies (7 case series and 2 comparative studies) reporting positive outcomes for the balloon spacer which reflects the outcomes of those who did well with the balloon spacer in our series<sup>20–28</sup> (Table III).

Interestingly, Ricci et al.'s MRI analysis at 24 months showed that the spacer was not detectable, instead replaced by a layer of fibrosis.<sup>21</sup> This gives an indication of how the balloon spacer may continue to be effective.

We accept our study is subject to limitations. The study has prospectively collected data, however it is a case series with no control/comparative group and two patients who converted to rTSR had incomplete data.

Our subgroup analysis is vulnerable to bias. Separation of our cohort using PROM scores and outcome reported pain levels may have been influenced by patient psychosocial factors. However, it allowed identification of baseline patient factors that are associated with an improved outcome.

Though this is a small case series, we had a sufficient number of patients to demonstrate significant changes and our patient numbers are comparable to other published studies. Longer term follow-up is needed to further evaluate outcomes and conversion to joint replacement, although our follow-up is relatively long compared to similar studies.

We note heterogeneity in a few patients who had concurrent procedures such as a biceps tenotomy or ACJ excision, therefore their outcomes may have been influenced by these additional procedures. We did not include objective functional measures such as range of motion.

Our only reported complication is a stitch abscess which was treated with antibiotics. Another patient had a repeat arthroscopy after approximately 6 months due to continuing pain and had the remainder of the balloon spacer removed. Other complications reported from other balloon studies include spacer revision, spacer migration and superficial/deep infection.<sup>22,29</sup>

On the whole we feel our case series provides valuable additional data to the current evidence base which is somewhat conflicting. Our data suggests a specific cohort in which the balloon spacer may be effective yet demographic and outcome outliers are evident. These unpredictable outcomes challenge whether the balloon spacer is a justifiable treatment option given its inevitable associated patient morbidity and cost. Given this, in our unit the balloon spacer is now only utilised within a research context utilising strict inclusion criteria.

## 5. Conclusion

There are many different treatment options available for patients with irreparable MRCTs. The utilisation of balloon spacers is a relatively novel option and is a simple alternative for patients wishing for pain relief and functional improvement. However, in our series the balloon spacer was clinically effective in a minority of patients. The risk of failure is higher in older patients and those with a low OSS at baseline. Despite poor outcomes, patients are subsequently reluctant to undergo joint replacement surgery.

However, some patients had a favourable outcome which may delay the need for major joint replacement surgery. These patients

appear to be younger and, despite being significantly symptomatic, have higher baseline outcome scores.

Patient expectations should be managed accordingly before insertion of the balloon spacer; whether for pain relief or to delay further surgery. From the clinician's perspective, patient selection is crucial in maximising their outcome as our case series suggests a specific cohort where a balloon spacer may be effective.

The important clinical question of whether the balloon spacer is appropriate treatment for irreparable massive rotator cuff tear remains. Randomised studies with higher patient numbers are required to provide qualitative comparisons in this patient group. Where possible, we would encourage clinicians to participate in robust research to definitively answer this question.

## Credit authorship statement

Eshan N.H Oderuth – Conceptualization, Methodology, Writing – original draft, Writing – review & editing, Visualization, Formal analysis. Daniel L.J Morris – Conceptualization, Methodology, Writing – original draft, Writing – review & editing, Visualization, Formal analysis. Paul A Manning – Supervision, John M Geoghegan – Supervision, Ben W Gooding – Supervision, Malin D Wijeratna – Conceptualization, Methodology, Writing – review & editing, Visualization, Formal analysis, Supervision

## Declaration of competing interest

All authors have no conflicts of interest to declare.

## Acknowledgements

Martin Scott and the Nottingham City Hospital physiotherapy department.

## References

- Gerber C, Wirth SH, Farshad M. Treatment options for massive rotator cuff tears. *J Shoulder Elbow Surg.* 2011;20(2 Suppl):S20–S29.
- Greenspoon JA, Petri M, Warth RJ, Millett PJ. Massive rotator cuff tears: pathomechanics, current treatment options, and clinical outcomes. *J Shoulder Elbow Surg.* 2015;24(9):1493–1505.
- Boileau P, Baque F, Valerio L, Ahrens P, Chuinard C, Trojani C. Isolated arthroscopic biceps tenotomy or tenodesis improves symptoms in patients with massive irreparable rotator cuff tears. *J Bone Joint Surg Am.* 2007;89(4):747–757.
- Walch G, Edwards TB, Boulahia A, Nove-Josserand L, Neyton L, Szabo I. Arthroscopic tenotomy of the long head of the biceps in the treatment of rotator cuff tears: clinical and radiographic results of 307 cases. *J Shoulder Elbow Surg.* 2005;14(3):238–246.
- Klinger HM, Spahn G, Baums MH, Steckel H. Arthroscopic debridement of irreparable massive rotator cuff tears—a comparison of debridement alone and combined procedure with biceps tenotomy. *Acta Chir Belg.* 2005;105(3):297–301.
- Chang KV, Hung CY, Wu WT, Han DS, Yang RS, Lin CP. Comparison of the effectiveness of suprascapular nerve block with physical therapy, placebo, and intra-articular injection in management of chronic shoulder pain: a meta-analysis of randomized controlled trials. *Arch Phys Med Rehabil.* 2016;97(8):1366–1380.
- Heuberger PR, Kolblinger R, Buchleitner S, et al. Arthroscopic management of massive rotator cuff tears: an evaluation of debridement, complete, and partial repair with and without force couple restoration. *Knee Surg Sports Traumatol Arthrosc.* 2016;24(12):3828–3837.
- Rockwood Jr CA, Williams Jr GR, Burkhead Jr WZ. Debridement of degenerative, irreparable lesions of the rotator cuff. *J Bone Joint Surg Am.* 1995;77(6):857–866.
- Berth A, Neumann W, Awiszus F, Pap G. Massive rotator cuff tears: functional outcome after debridement or arthroscopic partial repair. *J Orthop Traumatol.* 2010;11(1):13–20.
- Gerber C, Fuchs B, Hodler J. The results of repair of massive tears of the rotator cuff. *J Bone Joint Surg Am.* 2000;82(4):505–515.
- Mihata T, Lee TQ, Watanabe C, et al. Clinical results of arthroscopic superior capsule reconstruction for irreparable rotator cuff tears. *Arthroscopy.* 2013;29(3):459–470.
- Pandey R, Tafazzal S, Shyamsundar S, Modi A, Singh HP. Outcome of partial

- repair of massive rotator cuff tears with and without human tissue allograft bridging repair. *Shoulder Elbow*. 2017;9(1):23–30.
13. Petri M, Warth RJ, Horan MP, Greenspoon JA, Millett PJ. Outcomes after open revision repair of massive rotator cuff tears with biologic patch augmentation. *Arthroscopy*. 2016;32(9):1752–1760.
  14. Leuzinger J, Sternberg C, Smolen D, Jakob R. [Patch augmentation in rotator cuff repair surgery with elder patients]. *Z für Orthop Unfallchirurgie*. 2016;154(5): 504–512.
  15. Gupta AK, Hug K, Berkoff DJ, et al. Dermal tissue allograft for the repair of massive irreparable rotator cuff tears. *Am J Sports Med*. 2012;40(1):141–147.
  16. Kokkalis ZT, Mavrogenis AF, Scarlat M, et al. Human dermal allograft for massive rotator cuff tears. *Orthopedics*. 2014;37(12):e1108–e1116.
  17. El-Azab HM, Rott O, Irlenbusch U. Long-term follow-up after latissimus dorsi transfer for irreparable posterosuperior rotator cuff tears. *J Bone Joint Surg Am*. 2015;97(6):462–469.
  18. Gerber C, Maquieira G, Espinosa N. Latissimus dorsi transfer for the treatment of irreparable rotator cuff tears. *J Bone Joint Surg Am*. 2006;88(1):113–120.
  19. Savarese E, Romeo R. New solution for massive, irreparable rotator cuff tears: the subacromial "biodegradable spacer. *Arthrosc Tech*. 2012;1(1). e69–74.
  20. Senekovic V, Poberaj B, Kovacic L, et al. The biodegradable spacer as a novel treatment modality for massive rotator cuff tears: a prospective study with 5-year follow-up. *Arch Orthop Trauma Surg*. 2017;137(1):95–103.
  21. Ricci M, Vecchini E, Bonfante E, et al. A clinical and radiological study of biodegradable subacromial spacer in the treatment of massive irreparable rotator cuff tears. *Acta Biomed*. 2017;88(4-S):75–80.
  22. Deranlot J, Herisson O, Nourissat G, et al. Arthroscopic subacromial spacer implantation in patients with massive irreparable rotator cuff tears: clinical and radiographic results of 39 retrospective cases. *Arthroscopy*. 2017;33(9): 1639–1644.
  23. Gervasi E, Maman E, Dekel A, Cautero E. Fluoroscopy-guided biodegradable spacer implantation using local anesthesia: safety and efficacy study in patients with massive rotator cuff tears. *Musculoskelet Surg*. 2016;100(Suppl 1):19–24.
  24. Basat HC, Kircil C, Armangil M, Demirts M. Treatment alternative for irreparable rotator cuff ruptures: arthroscopic biodegradable balloon. *Niger J Clin Pract*. 2017;20(8):952–957.
  25. Piekaar RSM, Bouman ICE, van Kampen PM, van Eijk F, Huijsmans PE. Early promising outcome following arthroscopic implantation of the subacromial balloon spacer for treating massive rotator cuff tear. *Musculoskelet Surg*. 2018;102(3):247–255.
  26. Maman E, Safran O, Beyth S, et al. Biceps tenotomy does not affect the functional outcomes of patients treated with spacer implantation due to massive irreparable rotator cuff tears. *Open Orthop J*. 2017;11:1577–1584.
  27. Holschen M, Brand F, Agneskirchner JD. Subacromial spacer implantation for massive rotator cuff tears: clinical outcome of arthroscopically treated patients. *Obere Extrem*. 2017;12(1):38–45.
  28. Yallapragada RK, Apostolopoulos A, Katsougrakis I, Selvan TP. The use of a subacromial spacer-inspace balloon in managing patients with irreparable rotator cuff tears. *J Orthop*. 2018;15(3):862–868.
  29. Prat D, Tenenbaum S, Pritsch M, Oran A, Vogel G. Sub-acromial balloon spacer for irreparable rotator cuff tears: is it an appropriate salvage procedure? *J Orthop Surg*. 2018;26(2), 2309499018770887.
  30. Ruiz Iban MA, Lorente Moreno R, Ruiz Diaz R, et al. The absorbable subacromial spacer for irreparable posterosuperior cuff tears has inconsistent results. *Knee Surg Sports Traumatol Arthrosc*. 2018;26(12):3848–3854.
  31. Olley LM, Carr AJ. The use of a patient-based questionnaire (the Oxford Shoulder Score) to assess outcome after rotator cuff repair. *Ann R Coll Surg Engl*. 2008;90(4):326–331.
  32. Kirkley A, Griffin S, Dainty K. Scoring systems for the functional assessment of the shoulder. *Arthroscopy*. 2003;19(10):1109–1120.
  33. van Kampen DA, Willems WJ, van Beers LW, Castelein RM, Scholtes VA, Terwee CB. Determination and comparison of the smallest detectable change (SDC) and the minimal important change (MIC) of four-shoulder patient-reported outcome measures (PROMs). *J Orthop Surg Res*. 2013;8:40.



Contents lists available at ScienceDirect

## Journal of Arthroscopy and Joint Surgery

journal homepage: [www.elsevier.com/locate/jajs](http://www.elsevier.com/locate/jajs)

## Technical note

## Anatomical acromioclavicular joint reconstruction with conventional ACL tightrope: A novel technique

Sandeep K. Nema<sup>a</sup>, Jose Austine<sup>a,\*</sup>, Deepak Uppin<sup>a</sup><sup>a</sup> Department of Orthopaedic Surgery, Jawaharlal Institute of Post Graduate Medical Education and Research, Pondicherry, 605006, India

## ARTICLE INFO

## Article history:

Received 14 February 2020

Received in revised form

13 October 2020

Accepted 29 November 2020

Available online 7 December 2020

## Keywords:

Acromioclavicular joint

Tightrope

AC joint reconstruction

## ABSTRACT

The management of Acromioclavicular (AC) joint disruptions types IV, V and VI is operative. Over 60 procedures have been described for AC joint reconstruction. Recently, a trend towards anatomical methods for restoring horizontal (AC) and vertical (CC) stability in both acute and chronic AC joint disruptions has been reported. A special suspensory button device is available in the market for closed/open AC joint repair. We report a technique of anatomical AC joint reconstruction using conventional ACL tightrope with semitendinosus autograft in two cases with excellent functional (Constant and Murley score) and radiological (restoration of AC and CC distance) outcomes at one year. The described technique is simple, reproducible and is anticipated to reduce the cost of the operative procedure significantly.

© 2020 International Society for Knowledge for Surgeons on Arthroscopy and Arthroplasty. Published by Elsevier, a division of RELX India, Pvt. Ltd. All rights reserved.

## Credit author statement

Dr Sandeep Nema: Conceptualization, Investigation, Methodology, Resources, Supervision, Validation, Writing – original draft, Writing – review & editing. Dr Jose Austine: Investigation, Methodology, Writing – original draft, Writing – review & editing. Dr Deepak Uppin, Writing – original draft, Writing – review & editing

## 1. Introduction

Recently excellent outcomes have been reported in anatomic reconstruction of the acromioclavicular (AC) joint.<sup>1</sup> There is a trend for arthroscopic assisted reduction and fixation with a suspensory loop and a button each under the coracoid process and the superior surface of clavicle (tightrope device) for acute AC joint dislocations.<sup>2</sup> The repair technique relies on maintaining the AC and CC (coracoclavicular) space by the suspensory button to aid healing of the stretched AC joint capsule and CC ligaments. However, restoration to normal length of a stretched AC joint capsule and CC ligaments is debatable. Clavert et al. reported radiological failures and low functional scores in 41% and 27% percent of patients in AC

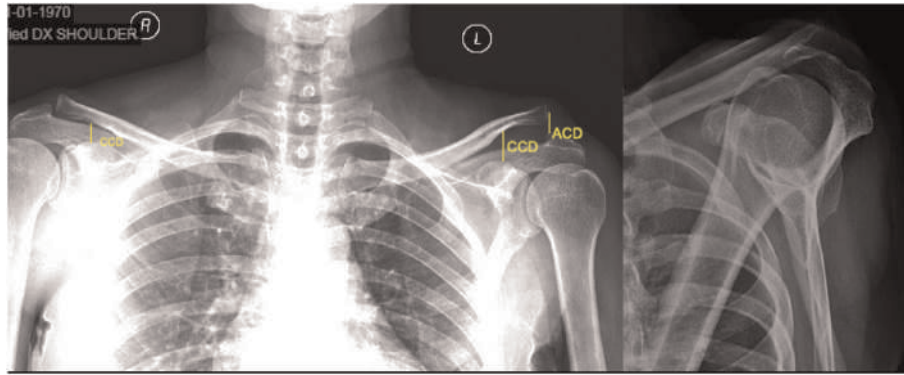
Joint disruptions treated with a suspensory button alone.<sup>3</sup> Reduction with autologous/allogenic tendon augmentation and protection with a screw, tape or a suspensory device has been described and is our favored technique because it is anatomical, simple and reproducible.<sup>4</sup> Suspensory devices are preferred over screws because the latter needs another operation for removal. A special AC Tightrope device/Twin -Tail tightrope device (Arthrex Naples Florida USA) is available for AC joint reconstruction, which has one button each for undersurface of the coracoid and the superior surface of clavicle connected by an adjustable loop.<sup>5</sup> However, its frequent use is limited because of cost constraints and availability. The purpose of this technical note is to report a modification in AC joint reconstruction by using conventional ACL tightrope.<sup>6</sup> We report the functional and radiological outcomes in two chronic AC joint dislocations operated using our technique with graphic representation of one of the cases (Fig. 1).

## 2. Surgical technique

With the patient in beach chair position and the injured shoulder supported by a beanbag, we performed an anatomical AC joint reconstruction in attempt to restore horizontal (AC) and vertical (coracoclavicular CC) stability. A standard 3 cm vertical incision, between the inferior edge of the clavicle and the coracoid process, was used to expose the delto-trapezial fascia that was incised and the deltoid was cut in T fashion with its base at the clavicle. The coracoid process was identified, and its medial and

\* Corresponding author. Department of Orthopaedic Surgery, JIPMER, Pondicherry, 605006, India.

E-mail addresses: [drsandeepnema@gmail.com](mailto:drsandeepnema@gmail.com) (S.K. Nema), [joseaustine10@gmail.com](mailto:joseaustine10@gmail.com) (J. Austine), [uppin009@gmail.com](mailto:uppin009@gmail.com) (D. Uppin).



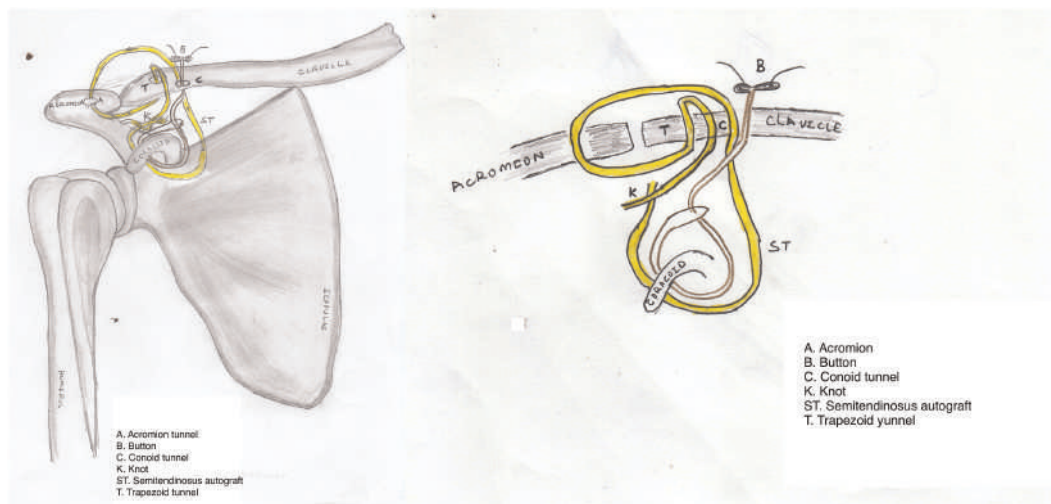
**Fig. 1.** Antero-posterior and scapular Y view radiograph of the shoulder showing increased Coraco-clavicular (CCD) and Acromio-clavicular (ACD) distance.

lateral surfaces were dissected to accommodate a Satinsky/right-angled clamp. A shuttling suture loop was then passed from medial to lateral through the undersurface of the coracoid. Care was taken to pass the suture loop from medial to lateral to protect the neurovascular bundle next to the coracoid. The superior surface of the lateral clavicle with the AC joint was dissected and the lateral 5 mm of the clavicle was excised to prevent iatrogenic AC joint arthritis. Two tunnels, anteromedial (conoid) and posterolateral (trapezoid) were drilled from superior to inferior in the lateral clavicle with a 4 mm drill bit in alignment with the coracoid process to accommodate the conoid and trapezoid part of coracoclavicular ligament reconstruction. Another hole was drilled from superior to inferior through the acromion adjacent to the AC joint for the reconstruction of the acromioclavicular ligament. Shuttling sutures were passed through each of the tunnels. Tightrope device meant for ACL reconstruction with an adjustable loop and single button and whip stitched autologous semitendinosus tendon were passed from medial to lateral under the coracoid process (Fig. 2). The tight rope device was looped on to itself and passed through the anteromedial (conoid) tunnel in the clavicle from inferior to superior with the semitendinosus tendon autograft. The suture button was flipped on the superior surface of the clavicle and its adjustable loop tightened to achieve the AC joint reduction (video supplement). A maneuver pushing the elbow upwards and pressure on the clavicle downwards was adopted to achieve AC joint reduction. The free end of the semitendinosus tendon graft emerging from the

conoid tunnel of the clavicle was then passed from superior to inferior through the tunnel in the acromion and inferior to superior through the posterolateral (trapezoid) tunnel in the lateral end of the clavicle. The free ends of the graft were sutured upon themselves. The flaps of deltoid were repaired, and the surgical incision was closed in layers. The shoulder was protected with an arm to chest bandage for 4 weeks following which a standard post-operative rehabilitation protocol was initiated for shoulder mobilization. Functional and radiological outcomes assessed at 1 year demonstrated excellent Constant and Murley shoulder scores (CMS) and a reduced AC joint (Figs. 3 and 4).

### 3. Discussion

Treatment of AC joint disruptions Rockwood types IV, V and VI is operative. Recent studies have demonstrated the importance of instability in horizontal component in the AC joint disruptions.<sup>7</sup> The autograft/allograft reconstructions for restoring horizontal and vertical stability in these studies were protected by a screw, suture, tape or a suspensory button fixed on the clavicle and the under surface of the coracoid (tightrope). We modified the technique by using the tightrope device meant for ACL reconstruction for the protection of semitendinosus autograft for 6–8 weeks. Spencer and colleagues compared different methods of ACJ reconstruction and reported least failure rates with combined suspensory button and looped allograft under the coracoid.<sup>8</sup> The



**Fig. 2.** Graphic illustration depicting the passage of the semitendinosus autograft and the tightrope device during the operation in coronal and sagittal views.



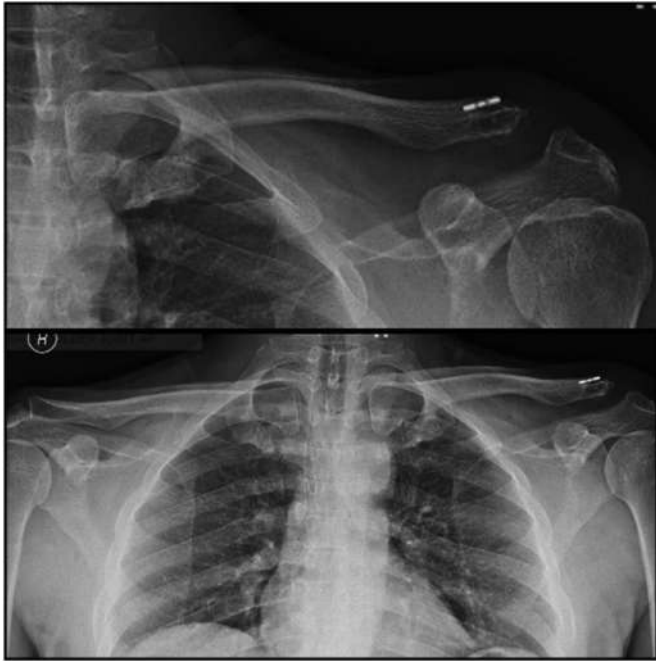


Fig. 3. Post-operative radiograph at 1 year showing a reduced AC joint.

likely reason for high radiologic failures could be slipping of suspension sutures in the button, single point of fixation of the button, fracture of the lateral clavicle, acromion and coracoid and failure of stretched AC and CC ligaments to heal. However, the modified technique described by us looped the button and the autograft under the coracoid negating the risk of its fracture. A systematic review which assessed 21 studies for the loss of reduction and complications in anatomic AC joint reconstruction reported no significant differences in loss of reduction between single and double clavicular tunnel technique.<sup>9</sup> In addition, more complications were noted with the double clavicular tunnel technique. Reconstruction of the AC joint using the excess auto/allograft were found to have better outcomes against no reconstruction. Some studies employed sutures while others used acromion tunnels for fixation of excess ligamentous graft. A few studies used interference screw or peek anchors for fixation of the graft in the tunnels while some opted not to. We believe that it is impossible for the AC and CC ligaments responsible for the maintenance of AC joint integrity to heal back to preinjury position when the plastic deformation from the injuring force is high. The cost of an ACL tight rope or a similar device with a suspensory loop and single suture button marketed in India is estimated between \$ 154 to \$ 176. The implant is readily available to the surgeons because of its frequent use in ligamentous reconstructions around the knee. Contrastingly, the special tightrope meant for AC joint fixation has limited

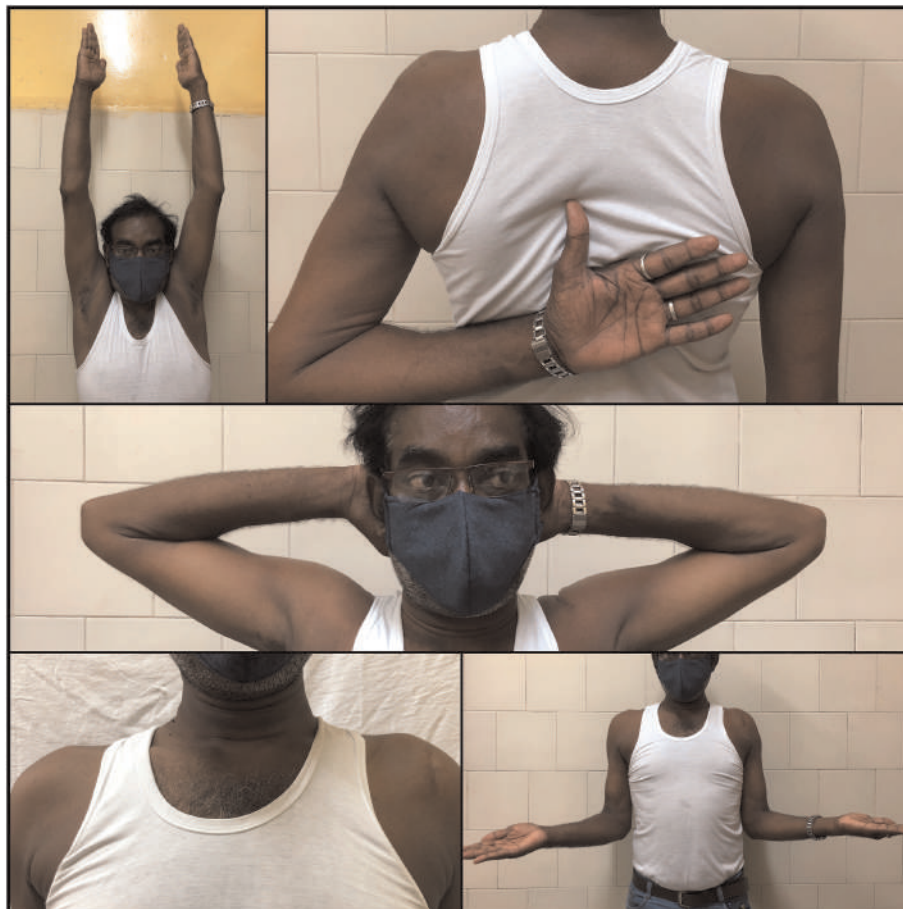

Fig. 4. Clinical photographs showing functional outcome at 1 year.

manufacturing and is available at \$ 391 to \$408, making our modification relevant in low-budget scenarios.

### Disclosures and Acknowledgements

The authors have not received any financial assistance or privileges from industry or other sources to conduct this study. The authors acknowledge Dr. Swati Nema MDS and G. Thirumalaiselvam for contributing towards graphic illustration and editing the video supplement.

### References

1. Carofino BC, Mazzocca AD. The anatomic coracoclavicular ligament reconstruction: surgical technique and indications. *J Shoulder Elbow Surg.* 2010;19:37–46.
2. Arirachakaran A, Boonard M, Piyapittayanun P, et al. Post-operative outcomes and complications of suspensory loop fixation device versus hook plate in acute unstable acromioclavicular joint dislocation: a systematic review and meta-analysis. *J Orthop Traumatol.* 2017;18:293–304. <https://doi.org/10.1007/s10195-017-0451-1>.
3. Clavert P, Meyer A, Boyer P, et al. Complication rates and types of failure after arthroscopic acute acromioclavicular dislocation fixation: prospective multi-center study of 116 cases. *Orthop Traumatol Surg Res.* 2015;101:S313–S316.
4. Borbas P, Churchill J, Ek ET. Surgical management of chronic high-grade acromioclavicular joint dislocations: a systematic review. *J Shoulder Elbow Surg.* 2019;28:2031–2038. <https://doi.org/10.1016/j.jse.2019.03.005>.
5. Fracture management: shoulder, hand, ankle and foot indications; Orthobiologics. Available from: <https://www.arthrex.com>. Accessed November 14, 2019.
6. TightRope Implant ACL/PCL graft fixation options simplified. Available from: <https://www.arthrex.com>. Accessed November 14, 2019.
7. Aliberti GM, Kraeutler MJ, Trojan JD, Mulcahey MK. Horizontal instability of the acromioclavicular joint: a systematic review. *Am J Sports Med.* 2019 Apr 23. <https://doi.org/10.1177/0363546519831013>, 363546519831013.
8. Spencer HT, Hsu L, Sodl J, Arianjam A, Yian EH. Radiographic failure and rates of re-operation after acromioclavicular joint reconstruction: a comparison of surgical techniques. *Bone Joint Lett J.* 2016;98-B:512–518.
9. Pill SG, Rush L, Arvesen J, et al. Systematic review of the treatment of acromioclavicular joint disruption comparing number of tunnels and graft type. *J Shoulder Elbow Surg.* 2020;29(7S):S92–S100. <https://doi.org/10.1016/j.jse.2020.04.008>.



# Management of intercondylar fractures of the humerus by triceps-reflecting anconeus pedicle (TRAP) and olecranon osteotomy approaches- A comparative study

Ankit Mittal\*, S.P.S. Gill, Manish Raj, Harish Kumar, Santosh K. Singh, Jitesh Arora

UPUMS, Saifai, Etawah, UP, India



## ARTICLE INFO

### Article history:

Received 14 October 2020

Accepted 15 October 2020

Available online 4 November 2020

### Keywords:

Intercondylar (intraarticular) humerus fractures

Triceps-reflecting anconeus pedicle approach

Olecranon osteotomy

Elbow reconstruction

## ABSTRACT

**Introduction:** Intercondylar fractures of distal humerus are uncommon and pose a considerable challenge to even the most experienced orthopaedic surgeon. Our study aimed at comparing one described surgical approach to fix them, the TRAP approach (Group TR), which involves elevation of a flap comprising of triceps and anconeus from distal to proximal, with the more popular olecranon osteotomy approach (Group O).

**Material and method:** In this study, 35 patients in Group O were compared with 32 patients in Group TR. Both the groups were comparable in terms of age, gender, duration of injury and degree of comminution of the fracture. Results were compared in terms of union, arc of motion, flexion contracture, overall flexion achieved and triceps strength. Functional evaluation was done using the Mayos' elbow performance score (MEPS).

**Results:** Patients were followed for a minimum of 18 months. Fracture union was seen at or before 6 months in all the patients of both the groups except in 3 cases of Group O and 2 of Group TR where it was seen at 9 months. Average time to union was comparable in both the groups. In all of them except 3 in group O and 4 in Group TR, the fractures united with intraarticular step off of less than 2 mm. In Group TR, the average arc of motion was 114.5 (SD 14.6) with a mean degree of flexion of 121.9 (SD 12.1) and extension of 7.3 (SD 5.6). In Group O, the arc of motion averaged 113.6 (SD 18.9) with a mean degree of flexion of 124.1 (SD 13.3) and extension of 10.6 (SD 7.3).

**Conclusion:** Although technically demanding, TRAP exposure can prove to be as effective as olecranon osteotomy approach and can be used as an approach of choice for fixation of these fractures.

© 2020 International Society for Knowledge for Surgeons on Arthroscopy and Arthroplasty. Published by Elsevier, a division of RELX India, Pvt. Ltd. All rights reserved.

## Author contribution

Ankit Mittal: Conceptualization, Methodology, Software SPS Gill: Data curation, Writing - original draft. Manish Raj: Visualization, Investigation. Harish Kumar: Supervision.: Santosh K Singh: Software, Validation.: Jitesh Arora: Writing- Reviewing and Editing.

## 1. Introduction

Intraarticular fractures of humerus are uncommon accounting for 2–6% of all fractures and about 30% of all elbow fractures and

typically occurring in young males due to high energy trauma.<sup>1</sup> They still pose a therapeutic challenge to surgeons owing to the complex anatomy of elbow, multiple fracture fragments and limited subchondral bone.<sup>2,3</sup> Anatomic reconstruction, rigid fixation and early mobilization is more important in intraarticular elbow fracture than in any other joint<sup>4–6</sup> and this led to operative fixation being chosen as a gold standard treatment modality for these fractures.<sup>7</sup>

Many aspects of operative fixation starting from the choice of implant to its placement and subsequent approach of choice have been debated. Literature is still inconclusive about the best approach for the management of these fractures.

Triangular fixation techniques for bicolumnar restoration are an effective and predictable way to treat these fractures<sup>8</sup> and so were selected for our study with 2 plates placed orthogonally.

\* Corresponding author. Dept Of Orthopaedics, UPUMS, Saifai, Etawah, UP, India.  
E-mail addresses: [ankitmittal1785@gmail.com](mailto:ankitmittal1785@gmail.com) (A. Mittal), [simmygill@gmail.com](mailto:simmygill@gmail.com) (S.P.S. Gill), [ankitkumar17855@gmail.com](mailto:ankitkumar17855@gmail.com) (M. Raj).

Ample exposure of the articular surface of the distal humerus and the elbow joint is necessitated for operative stabilization of these fractures. Posterior surgical approaches have been thought to provide a matchless exposure to this site and olecranon osteotomy has been contemplated as a gold standard approach to restore articular congruity<sup>9</sup> and against it other approaches have been compared. It offers a complete view of the distal humerus and is the most frequently employed approach.<sup>10</sup>

However, this approach has its own impediments. Delayed union, nonunion of osteotomy site and prominent hardware has been reported<sup>11</sup> Dissociation of the triceps from the olecranon entails a more voluminous dissection, triceps weakness and slow postoperative rehabilitation. This compelled the surgeons to search for surrogate methods of dealing with the extensor mechanism.

Newer approaches with the aim of providing an uncompromised access to the fracture surface and at the same time preventing any compromise with the extensor apparatus have been proposed. One such approach is the paratricipital posterior approach to the distal humerus via a midline posterior incision, as put forth by O'Driscoll et al.<sup>12</sup> It entails mobilization of triceps and anconeus off the posterior surface of distal humerus and the intermuscular septae, thereby affording an adequate exposure to these fractures without involving any osteotomy. Besides this, the neurovascular supply to the anconeus, a dynamic stabilizer of the elbow is undisturbed.<sup>12</sup> Zhang et al.<sup>13</sup> had observed reductions in procedure time, blood loss, complication rates and MEPS outcome with triceps sparing approach as compared to olecranon osteotomy. The intention of our study was to compare two different surgical exposure techniques, the widely used olecranon osteotomy and relatively new Triceps Reflecting Anconeus Pedicle (TRAP) exposure for fixation of these fractures.

The Aim of this randomized, prospective study was to analyze and compare the functional outcome of patients with intraarticular fracture of distal humerus in terms of triceps strength, postoperative ROM and MEPS score operated with either of the two surgical exposure techniques, olecranon osteotomy or TRAP approach.

## 2. Material and methods

Between July 2016 to January 2019, 74 consecutive patients falling in age group of 18–59 years with intraarticular fracture of humerus were managed with open reduction and internal fixation of the fracture. They were randomized on an odd/even date presentation basis into 2 groups: Group O (Olecranon Osteotomy

Group) and Group TR (TRAP Group). The study was approved by institutional research cell and ethical committee.

Standard AP and Lateral views were obtained in the Emergency department and fractures were classified according to the AO classification of humerus fractures.

The inclusion criteria were- Age 18–59 years; closed intercondylar humerus fractures; grade 1 open fractures and Type C as per AO/ASIF classification system.

Patients were excluded if they classify as a grade 2 & 3 open fracture; medically unfit for surgery; associated ipsilateral upper limb fractures and any associated neurovascular deficit and presenting >3 weeks after injury.

All patients were operated after obtaining informed consent and departmental permission. 7 patients could not be followed up for the prerequisite period and the remaining 67 patients constituted our study with Group O (35 patient) and Group TR (32 patient) [Table 1]. Student *t*-test was used to analyze the difference of means between the 2 groups. The test was referenced for a two-tailed *p* value and 95% confidence interval was constructed around sensitivity proportion using normal approximation method. The Fischer's exact test was used for the comparison of paired categorical variables. SPSS software was used to perform statistical analyses. A value of <0.05 was considered statistically significant. The sample size according to the incidence of events in 2 groups as per previous studies considering 0.05 alpha factor and 80% power was 2664 (1332 in each group). Power of the study was calculated to be 5.3.

After routine preoperative investigations and assuring fitness for anesthesia, patients were taken up for surgery. General anesthesia or regional block was employed to carry out the procedure.

Patients were placed in lateral decubitus position with the elbow resting over a side support attachment and the forearm hanging by the side. Digital pneumatic tourniquet was routinely employed over the proximal arm. A midline skin incision curving over the tip of olecranon extending 15 cm proximal and 5 cm distal to it was used and full thickness medial and lateral fasciocutaneous flaps were generated. Ulnar nerve was dissected and freed proximally from its emergence beneath the triceps tendon to distally up to its first motor branch to the flexor carpi ulnaris muscle.

In Group O, the interval between the triceps and the anconeus was incised to expose the joint. A distally oriented chevron (reverse V) osteotomy of olecranon using a sagittal oscillating saw and osteotome to complete the osteotomy near the cartilaginous part of olecranon was carried out and olecranon was raised with triceps off the posterior aspect of humerus extraperiosteally [Fig. 1].

**Table 1**  
Demographic profile of study.

Characteristics	Group O	Group TR
Age (in years), Mean(range)	38.14 years (SD 15.3)	35.21 years (SD 13.09).
Gender (Male: Female)	41:16	31:13
Side (Right: Left)	32:25	29:22
Fracture Type		
Closed	42	35
Grade 1	15	16
AO Classification		
C1	28	26
C2	19	17
C3	05	05
Mechanism of Injury		
Fall	18	21
RTA	09	06
Assault	02	01
Others	05	04
Duration of Injury	10.11 days (SD 4.24)	09.90 days (SD 4.29) ( <i>p</i> value = 0.841)
Preop ulnar nerve palsy	02	02



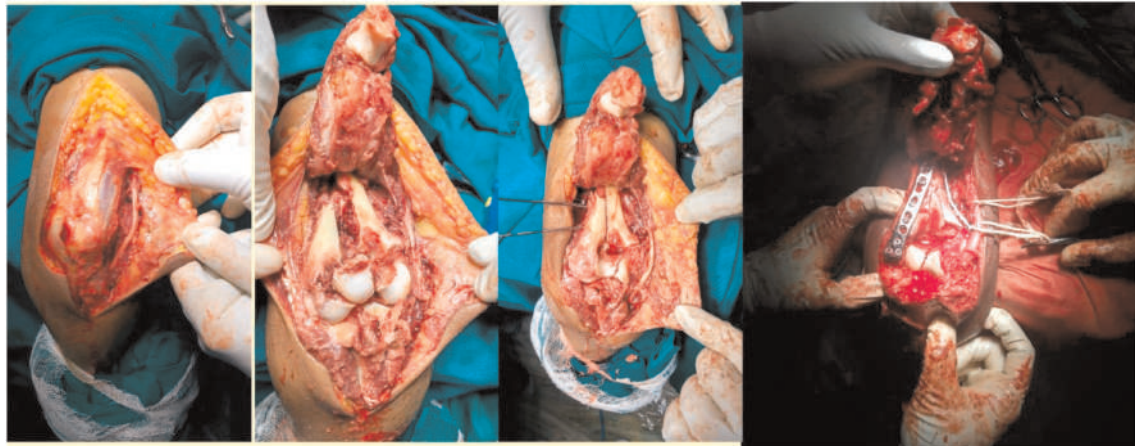


Fig. 1. Per-operative picture- Olecranon osteotomy and intercondylar fracture humerus fixation.

**Table 2**  
Duration of follow-up.

	Group O	Group TR	p value
<b>Mean duration of follow-up</b>	<b>23.49 (SD 4.80)</b>	<b>23.34 (SD 4.86)</b>	<b>0.900</b>

In Group TR, TRAP approach for exposure of the elbow as described by O Driscoll et al. was employed.<sup>12</sup> Distally ulnar nerve was exposed for 7 cm after the flexor pronator mass was entered. Laterally, flap was elevated with distal to proximal dissection comprising of anconeus and triceps. The flap was detached from its distal attachment (5–7 cms from tip of olecranon) and dissected off the lateral side of elbow taking care to preserve the integrity of lateral collateral ligament. The posterior capsule was then incised and triceps dissected off the posterior surface of the humerus.

For internal fixation, articular fixation was achieved with one 4 mm cannulated cancellous screw and medial and lateral columns were fixed with pre-contoured locking anatomical plates placed orthogonally. Dual plating has been shown to provide rigid fixation for these fractures and can provide improved functional results.<sup>14–16</sup>

In both the groups, provisional stabilization was first achieved with K wires and subsequently with the implants stated above. Lateral column was plated along its posterior surface and medial column along its medial surface. Care was taken to ensure proper fit of the plates to the bony surfaces. A subcutaneous transposition of ulnar nerve was carried out in all the cases.

**Table 3**  
MEPS score.

Criteria	Grading	Score
Pain	None	45
	Mild	30
	Moderate	15
	Severe	0
Motion	>100	20
	50–100	15
	<50	05
Stability	Stable	10
	Moderately unstable	05
	Grossly unstable	0
Function	Can comb hairs	5
	Can eat	5
	Can perform hygiene	5
	Can don Shirt	5
	Can don shoe	5

**Table 4**  
MEPS classified in scale of excellent to poor.

MEPS Score	Grading
>90	Excellent
75–89	Good
60–74	Fair
<60	Poor

In Group O, olecranon was secured via tension band wiring with 2 K wires and cerclage wire. In Group TR, triceps was reattached with interrupted no.2 braided polyester suture to olecranon using drill holes. The tourniquet was then released and homeostasis achieved before the wound closure in layers over a suction drain.

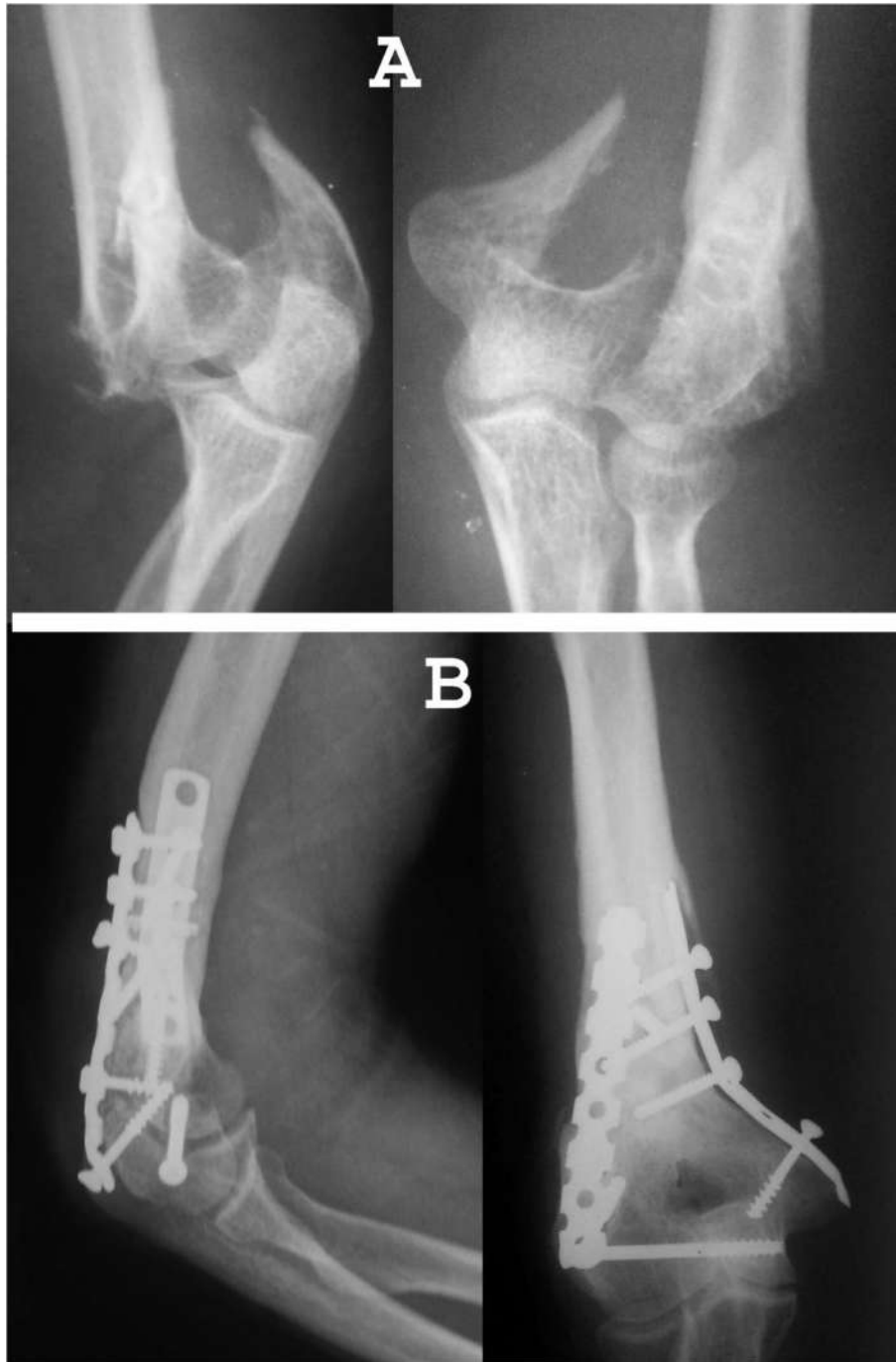
Intraoperative radiographs to confirm reduction and correct plate placement, varus/valgus stress test for collateral ligament integrity were routinely carried out. Fixation stability and motion arcs were assessed too prior to closure.

Postoperative care: Following surgery, elbow was splinted in 110° of flexion and elevated for 2 days to reduce edema. Active assisted ROM was started on 3rd day and splint was used intermittently for 2 weeks. Patients were discharged 5–7 days after surgery.

Follow up- Patients were followed at 2 weeks from the date of surgery when sutures and splint were removed, then at 4 weeks, then monthly for first 6 months and after that at every three monttill the last follow-up. At each follow-up, patients were encouraged to achieve maximum motion and appropriate functions. They were evaluated for any pain, swelling, and signs of infection and ROM at elbow. X rays (AP and lateral) of affected elbow) were done. A standard practice of measuring ROM with patient sitting and arm resting over the table was used.

**Table 5**  
Summary of results.

Name of Criteria	Mean in Group O	Group TR	p value
Time for union(months)	05.57(SD 01.31)	05.31(01.25)	0.409
Range of Motion(deg.)	113.57 (SD 18.88)	114.53 (SD 14.55)	0.818
Flexion(deg.)	124.14 (SD 13.31)	121.87 (SD 12.09)	0.470
Extension deficit(deg.)	10.57 (SD 7.3)	7.25 (SD 5.6)	0.048
Pronation(deg.)	75.71 (SD 8.84)	74.06 (SD 7.97)	0.426
Supination(deg.)	67.42 (SD 9.80)	70.31 (SD 6.94)	0.173
<b>MEPS Score</b>	<b>87.14 (SD 8.07)</b>	<b>85.46 (SD 8.16)</b>	<b>0.402</b>



**Fig. 2.** A-Case 1- Pre-operative Xray showing intercondylar fracture humerus. B-Case 1- TRAP; Follow up Xray picture showing union at fracture site.

At final follow-up visit at 18 months, parameters compared were: Elbow range of motion, Triceps strength and Mayos' elbow<sup>17</sup> performance score (MEPS) (see Tables 3 and 4).

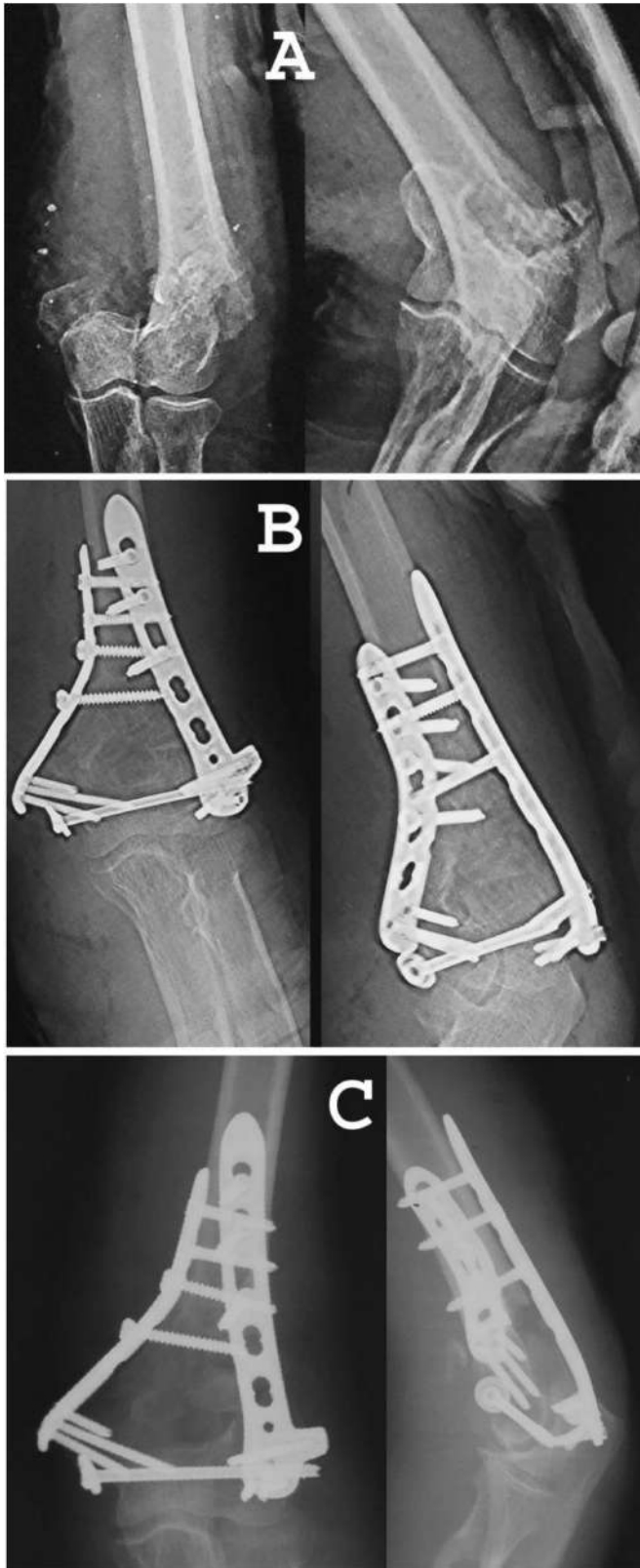
### 3. Results

The demographic profile of the patients in both the groups was comparable (Table 1). According to AO/ASIF classification, in Group O, C1, C2 and C3 fractures were 8, 7 and 10 respectively and they were 7, 14 and 11 respectively in Group TR. 4 patients in Group O had open injuries (Grade 1) and 5 in Group TR (Grade 1). The mean duration of interval between the injury and the presentation and

the mean duration of follow-up of the patients in the 2 groups were also comparable (Tables 1 and 2).

The time taken for fracture union was comparable between the groups and there was no statistically significant difference (Table 5). In all of the subjects, except 3 in group O and 4 in Group TR, the fracture united with intraarticular step off of less than 2 mm. Olecranon osteotomy too had an uneventful union in all Group O cases.

There were also no statistically significant differences with regard to the average arc of motion, mean degree of maximum flexion, range of pronation and supination between the two groups at 18 months. However, the extension deficit was significantly more



**Fig. 3.** A- Case 2- TRAP; Pre-operative Xray showing intercondylar fracture humerus. B- Case 2- TRAP; Post-operative follow up Xray 4 weeks. C- Case 3- TRAP; Post-operative Xray follow up at 12 weeks.

in Group O as compared to Group TR [Table 5] [Figs. 2–6].

5 patients in Group O and 3 patients in Group TR exhibited motion less than the functional arc of motion (100 deg.). Elbow arthrolysis was offered to all of them and 2 patients agreed to it (1 in either Group) and they achieved 110 deg. (Group O patient) and 115 deg. (Group TR patient) ROM at 18 months final follow-up after first surgery [Table 5]. The function evaluation utilizing average MEPS calculation at final follow-up revealed no statistically significant difference between the groups. [Tables 5 and 7] [Figs. 5 and 6].

The strength of the triceps muscle was also comparable between the 2 groups on completion of 18 months (Table 6).

Complications were tackled appropriately. Backing out of k wires and hardware prominence was seen in 2 cases of Group O and none in Group TR. All these 2 cases underwent implant removal between 6 and 8 months. In none of the cases was deep infection seen. Superficial infection, seen in 2 cases in Group O and 3 in Group TR in the first month after surgery subsided with regular dressings and antibiotics. Preoperative ulnar nerve symptoms seen in 4 patients (2 in each group) subsided completely within 2 months after surgery. Postoperatively, complete ulnar nerve palsy or any other neurological deficit was not reported in any patient of either group. Mild ulnar nerve neuropathy seen in 2 patients in each group subsided completely at 2 months in all without any operative intervention. Screw loosening was seen in 2 patients in Group O and 3 in Group TR. All of them subsequently needed implant removal after fracture union. Bullae formation and partial skin necrosis seen in 1 patient in Group O and 2 in Group TR, subsided conservatively. In none of the cases was loss of articular reduction, implant breakage or wire breakage was seen. No complications related to olecranon osteotomy like nonunion, malunion or heterotopic ossification was seen and no revision surgery was performed in our series. No evidence of AP or varus valgus instability was found [Table 8]. Overall, there was no statistically significant differences in the complication rates between the two groups.

#### 4. Discussion

Operative fixation for distal humerus fractures is essential to make the elbow stable and painless with satisfactory functions. To allow early and complete rehabilitation, near anatomic reconstruction of articular surface, restitution of both medial and lateral pillars and stable fixation of fracture fragments is paramount. Triceps spitting or -peeing approaches have been demonstrated to have a detrimental effect on muscle strength due of possibility of weakened reattachment, direct muscle injury with accompanying fibrosis and injury to intramuscular nerve branches.<sup>18</sup> In TRAP approach, the dissection is done in an internervous plane and hence chances of a compromise with triceps strength are avoided.

Although we did not quantify the surface area of distal humerus exposed in our study, we could achieve adequate exposure of the fracture site via TRAP approach even in AO type C3 fractures. The anterior articular surface can be visualized by extreme flexion of elbow. Wilkinson et al.<sup>19</sup> studied the median exposed articular surface for triceps splitting, triceps reflecting and olecranon osteotomy approaches and found that the total exposed articular area of distal humerus was 35%, 46%, and 57% respectively. Although olecranon osteotomy provides unparalleled exposure to the articular surface among them but it was not significantly greater than TR.

The olecranon osteotomy approach has been found difficult to be extended proximally.<sup>10,20,21</sup> Prominent K wires in 15 out of 20 (75%) cases and skin breakdown in 4 (20%) have been reported by Macko et al.<sup>22</sup> Horne et al.<sup>23</sup> reported 75% patients requiring wire



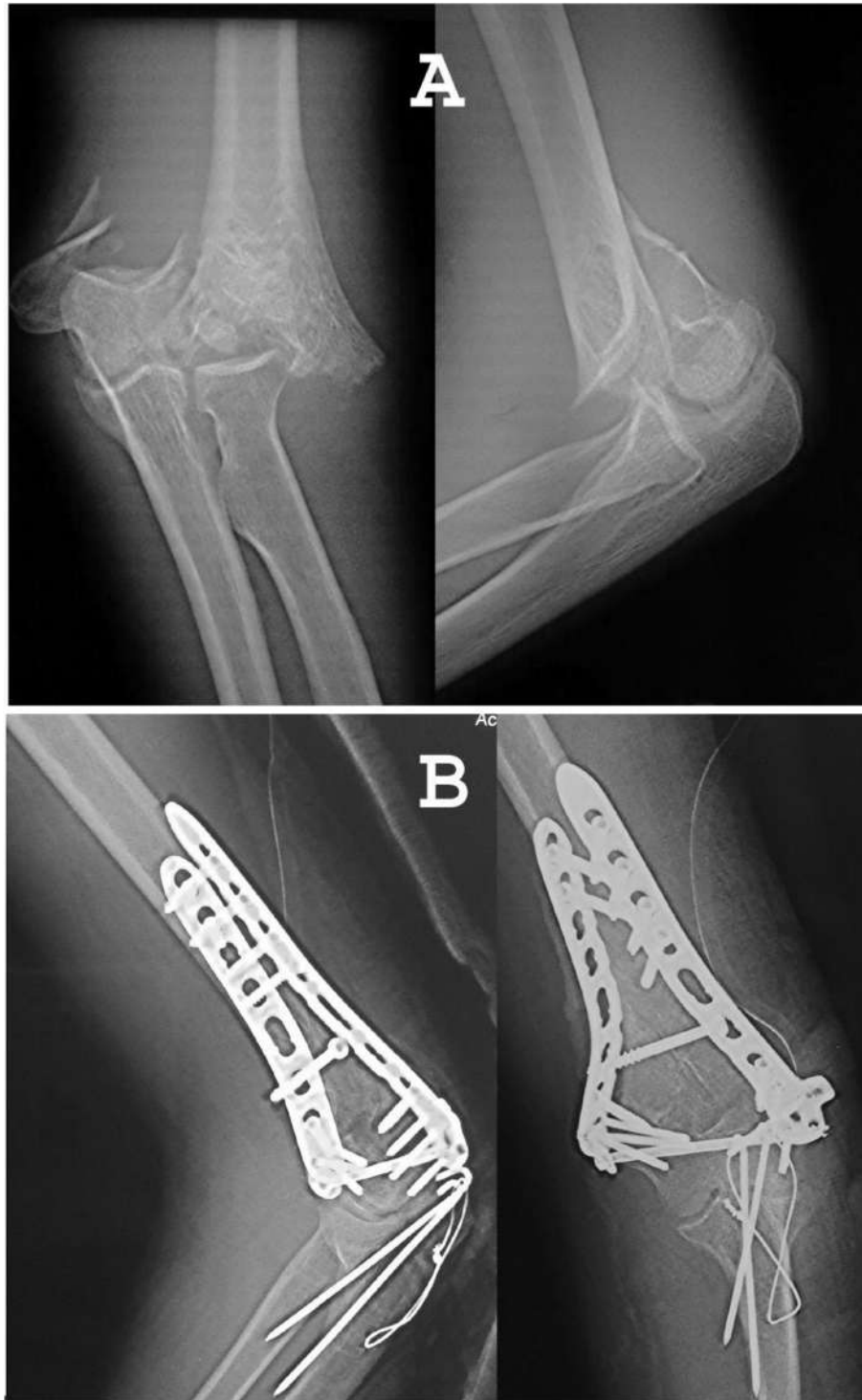


Fig. 4. A-Case 3- Pre-operative Xray showing intercondylar fracture humerus. B-Case 3- Olecranon osteotomy post-operative Xray after fracture fixation.

removal in 1 year due to pain and 7% nonunion incidence. Ring et al.<sup>24</sup> found the nonunion rate of *trans*-olecranon osteotomy to be as high as 30% with transverse olecranon osteotomy. In their series, Gainer et al.<sup>25</sup> reported need for hardware removal in 27% patients due to symptoms related to wire prominence and septic olecranon bursitis. In our study, we reported prominent K wires in 2 cases of Group O and no case of skin breakdown. All chevron osteotomies in our study had an uneventful union. Problem of nonunion is more

frequently encountered with transverse osteotomy.<sup>6</sup>

Significantly better elbow extension was discovered in the patients operated with TRAP approach than those with olecranon osteotomy approach while the differences in the arc of motion, mean overall flexion, range of pronation and supination movements between the two groups were not found to be statistically significant. Functional evaluation was done using MEPS score and there were no statistically significant differences in this regard also.



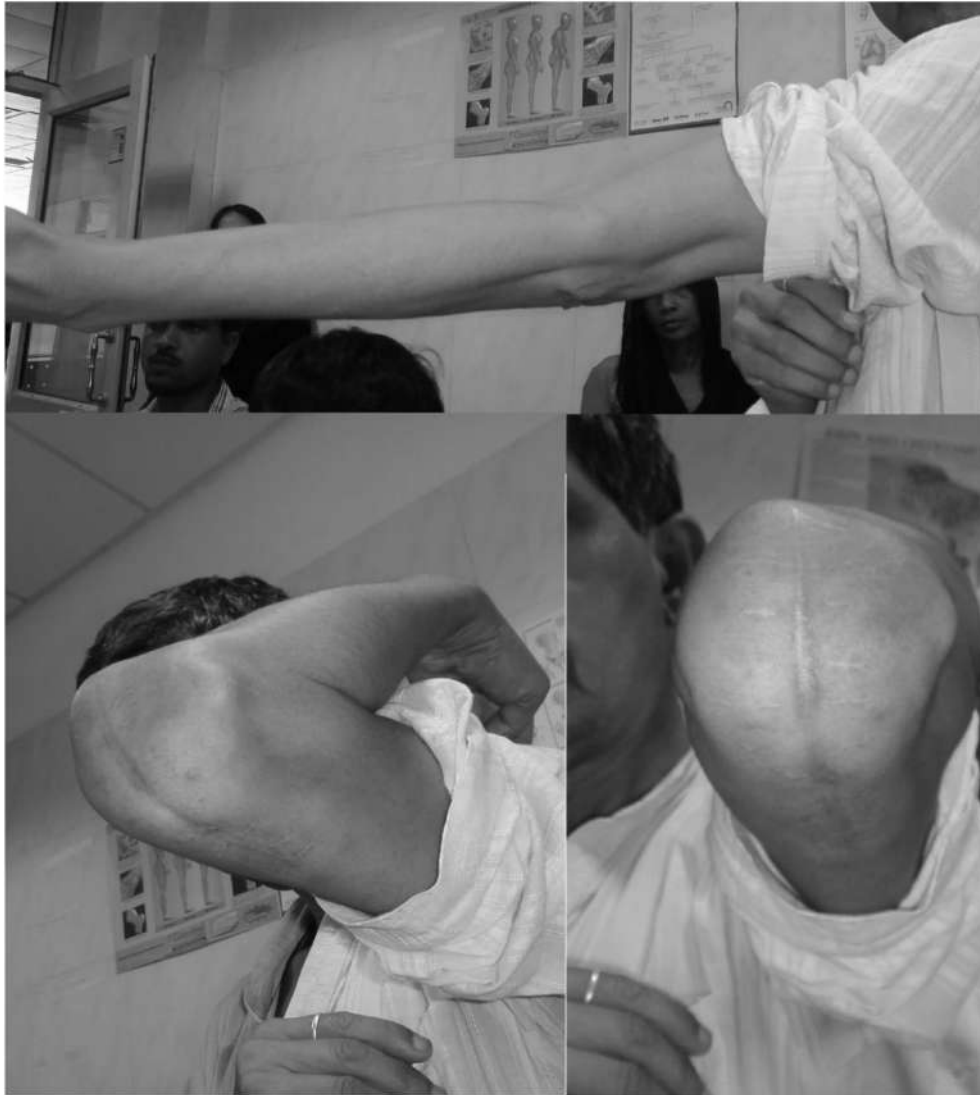

Fig. 5. Clinical Outcome of TRAP case 1.

Likewise, Chen et al.<sup>26</sup> found no overall statistically significant difference in average flexion, extension, arc of flexion/extension in the two groups, although patients >60yrs tended to have more extension loss with triceps sparing approach. Ibrahim et al.<sup>27</sup> observed that overall mean arc of elbow motion was 108° (range 70°–140°) in the TRAP group, whereas that of the olecranon osteotomy group was 98° (range 70°–115°). He noted a significant difference between the two groups in terms of overall mean arc of elbow motion but no significant differences between the two groups in terms of mean MEPS and DASH scores.

In contrast, significantly better motion arc values as well as functional outcome according to Mayo elbow score was seen in olecranon osteotomy group than triceps lifting group by Elmadag et al.<sup>28</sup> Khalid et al.<sup>29</sup> too found out better functional results with olecranon osteotomy than triceps sparing approach.

In our study, on evaluation of triceps strength at 18 months follow up, 91.4% (32 patients out of 35) in Group O and 87.5% (28 patients out of 32) in Group TR were found to have regained normal triceps strength when compared to opposite side. Our findings have been seconded by many previous studies. Ozer<sup>30</sup> found no

significant triceps weakness and dysfunction with TRAP approach. Lakhey et al.<sup>31</sup> too found grade 4 triceps strength in all their patients at 12 months follow-up with the triceps reflecting approach. In their study, Pankaj et al.<sup>32</sup> reported 87.5% of their patients to gain good triceps strength at final follow-up with the same approach.

Our study has a few limitations. Triceps strength was measured manually and this makes our results prone to observer bias. Objective testing of muscle strength is a better way to eliminate it. Post traumatic osteoarthritic changes take time to exhibit and need longer follow-up to become evident and so were not assessed by us. Further studies with larger group size and longer follow-up are necessary to provide complete information and validate the findings of the current study.

## 5. Conclusion

In conclusion, TRAP approach can provide elbow functions as good as or even better than olecranon osteotomy in management of these fractures. It obviates the need of an additional step of an osteotomy and provides ample exposure for intraarticular fractures

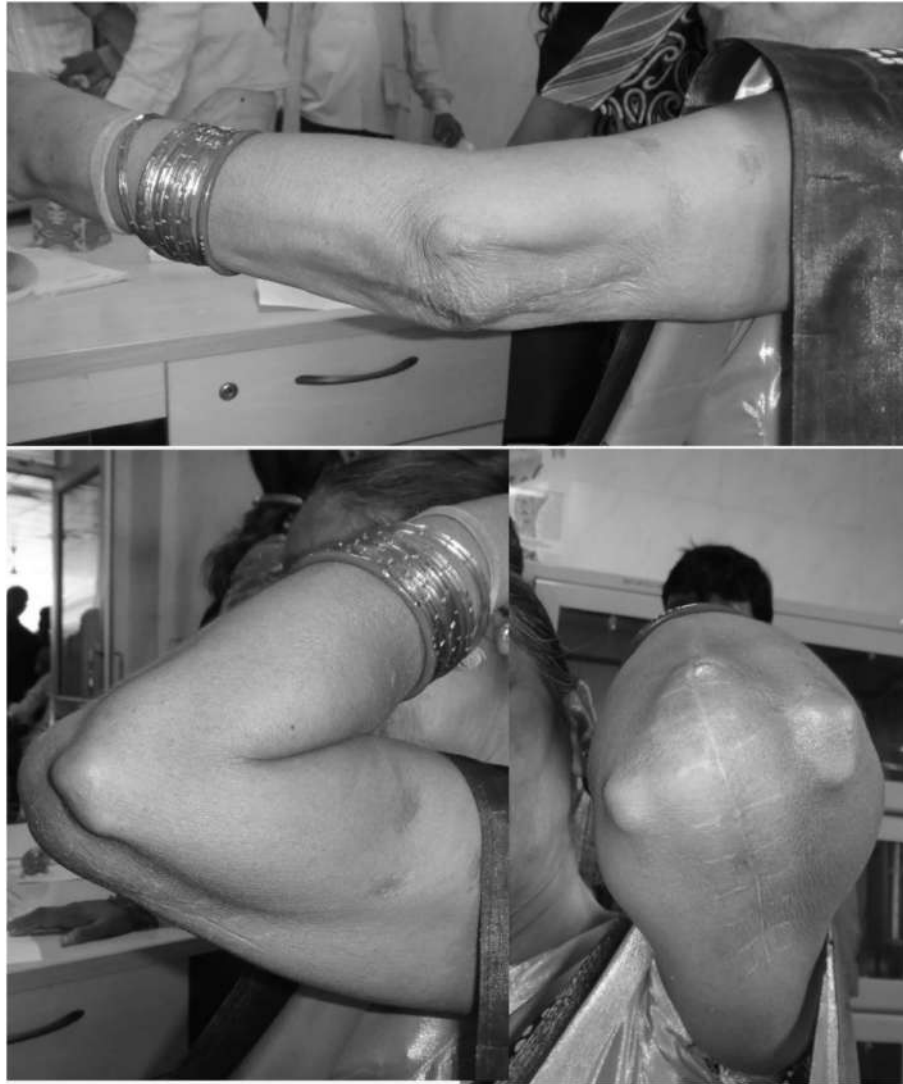

Fig. 6. Clinical Outcome of TRAP case 2.

**Table 6**  
Triceps strength.

	Group Op(n = 35)	Group TR (n = 32)	p value
<b>Number of patients regaining normal triceps strength</b>	<b>32</b>	<b>28</b>	<b>0.701</b>

**Table 7**  
Results of MEPS score.

MEPS grade	GROUP O	GROUP TR
Excellent	17	14
Good	16	16
Fair	2	2
Poor	0	0

of distal humerus without any detriment to the triceps strength, post-operative rehabilitation and final functions achieved and thus can prove to be a better substitute for the osteotomy obsessed surgeons.

**Table 8**  
Comparisons of complications of both groups.

Complications	Group O	Group TR
Superficial infection	2	3
Deep infection	0	0
Prominent K wires	2	0
Screw loosening	2	3
Nonunion/delayed union	0	0
Bullae and skin necrosis	1	2
Ulnar neuropathy	2	2
Radial neuropathy	0	0
Need for implant removal	2	3
Primary implant failure	0	0
<b>Total</b>	<b>11</b>	<b>13</b>

p = 0.457 for overall total complication rate.

## References

- Korner J, Lill H, Müller LP, Rommens PM, Schneider E, Linke B. The LCP-concept in the operative treatment of distal humerus fractures—biological, biomechanical and surgical aspects. *Injury*. 2003;34(2):B20–B30.
- Cannada L, Loeffler B, Zadnik MB, Eglseder AW. Treatment of high-energy supracondylar/intercondylar fractures of the distal humerus. *J Surg Orthop Adv*. 2011;20:230–235.
- Schmidt-Horlohé K, Wilde P, Bonk A, Becker L, Hoffmann R. One-third tubular-hook-plate osteosynthesis for olecranon osteotomies in distal humerus type-C fractures: a preliminary report of results and complications. *Injury*. 2012;43:295–300.
- Sanchez-Sotelo J, Torchia ME, O'Driscoll SW. Complex distal humeral fractures: internal fixation with a principle-based parallel-plate technique. *J Bone Joint Surg Am*. 2007;89(5):961–969.
- Doornberg JN, van Duijn PJ, Linzel D, et al. Surgical treatment of intraarticular fractures of distal part of humerus. Functional outcome after twelve to thirty years. *J Bone Joint Surg Am*. 2007;89:1524–1532.
- Eralp L, Kocaoğlu M, Sar C, Atalar AC. Surgical treatment of distal intraarticular humeral fractures in adults. *Int Orthop*. 2001;25:46–50.
- Ilyas AM, Jupiter. Treatment of distal humerus fractures. *Acta Chir Orthop Traumatol Cech*. 2008;75(1):6–15.
- Sung-Weon Jung MD, Seung-Hoon Kang MD, Min Jeong MD, Lim Hae-Seong. Triangular fixation technique for bicolour restoration in treatment of distal humerus intercondylar fracture. *Clin Orthop Surg*. 2016;8:9–18.
- Fodor M, Bekler H, Wolfe VM, McKean J, Ros-enwasser MP. Paratricipital-triceps splitting "two-window" approach for distal humerus fractures. *Tech Hand Up Extrem Surg*. 2011;15(3):156–161.
- Bryan SR, Morrey FB. Extensive Posterior approach to the elbow. *Clin Orthop*. 1982;166:188–192.
- Bass RL, Stern PJ. Elbow and forearm anatomy and surgical approaches. *Hand Clin*. 1994;10, 343–56.
- Driscoll SW. The triceps-reflecting anconeus pedicle (TRAP) approach for distal humeral fractures and nonunions. *Orthop Clin N Am*. 2000;31:91–101.
- Zhang Chi, Zhong Biao, Luo Cong-feng. Comparing approaches to expose type C fractures of the distal humerus for ORIF in elderly patients: six years clinical experience with both the triceps-sparing approach and olecranon osteotomy. *Arch Orthop Trauma Surg*. 2014;134(6):803–811. Epub 2014 Apr 29.
- Liu YK, Xu H, Liu F, et al. Treatment of type C intercondylar fractures of distal humerus using dual plating. *Zhonghua Wai Ke Za Zhi*. 2009;15;47(12):892–895.
- Greiner S, Haas NP, Bail HJ. Outcome after open reduction and angular stable internal fixation for supra-intercondylar fractures of the distal humerus: preliminary results with the LCP distal humerus system. *Arch Orthop Trauma Surg*. 2008;128(7):72–79. Epub 2007 Aug 23.
- Korner J, Diederichs G, Arzendorf M, et al. A biomechanical evaluation of methods of distal humerus fracture fixation using compression plates versus conventional reconstruction plates. *J Orthop Trauma*. 2004;18(5):286–293.
- Dawson Jill, Ray Fitzpatrick, Carr Andrew, Murray David. Questionnaire on the perceptions of patients about total hip replacement. *J Bone Joint Surg Br*. 1996;78(2):185–190.
- Kessler JR, Richards K, Millis M. The triceps-dividing approach to open reduction of complex distal humeral fractures in adolescents: a Cybex evaluation of triceps function and motion. *J Pediatr Orthop*. 1990;10:93–96.
- Wilkinson JM, Stanley D. Posterior surgical approaches to the elbow: a comparative anatomic study. *J Shoulder Elbow Surg*. 2001;10:380–382.
- Riseborough EJ, Radio EL. Intercondylar T fractures of the humerus in the adult. A comparison of operative and nonoperative treatment in twenty nine cases. *J Bone Joint Surg Am*. 1969;51(1):130–141.
- Crenshaw AH. *Campbells Operative Orthopaedics*. seventh ed. vol. 1. Washington, DC: C.V Mosby; 1987:88–93.
- Macko D, Szabo RM. Complications of tension band wiring of olecranon fractures. *J Bone Joint Surg Am*. 1985;67:1396–1401.
- Horne JG, Tanzer TL. Olecranon fractures: a review of 100 cases. *J Trauma*. 1981;21:469–472.
- Ring D, Gulotta L, Chin K, Jupiter JB. Olecranon osteotomy for exposure of fractures and nonunions of the distal humerus. *J Orthop Trauma*. 2004;18:446–449.
- Gainor BJ, Moussa F, Schott T. Healing rate of transverse osteotomies of the olecranon used in reconstruction of distal humerus fractures. *J South Orthop Assoc*. 1995;4:263–268.
- Chen G, Liao Q, Luo W, Li K, Zhao Y, Zhong D. Triceps-sparing versus olecranon osteotomy for ORIF: analysis of 67 cases of intercondylar fractures of the distal humerus. *Injury*. 2011;42(4):366–370. <https://doi.org/10.1016/j.injury.2010.09.004>. Epub 2010 Oct 6.
- Azboy Ibrahim, Bulut Mehmet, Ancar Cahit, et al. The comparison of triceps-reflecting anconeus pedicle and olecranon osteotomy approaches in the treatment of intercondylar fractures of the humerus. *Ulus Travma Acil Cerrahi Derg*. 2016;22(No. 1):58–65.
- Mehmet Elmadag T, Erdil Mehmet, Bilsel Kerem, Acar Mehmet Ali, Tuncer Nejat, Tuncay Ibrahim. The olecranon osteotomy provides better outcome than the triceps-lifting approach for the treatment of distal humerus fractures. *Eur J Orthop Surg Traumatol*. 2014 Jan 21;24(1):43–50. Epub 2012 Dec 2128.
- Usman Khalid Muhammad, Saeed Kazi Muhammad, Akhte Muhammad. A comparison of functional outcome of intercondylar fracture of distal humerus managed by olecranon osteotomy approach versus triceps sparing approach in adults. *J Pak Med Assoc J Pak Med Assoc*. 2015;65(11):S119–S122 [3].
- OzerH Solak S, Turanli S, Baltaci G, Colakoglu T, Bolukbası S. Intercondylar fractures of the distal humerus treated with the triceps-reflecting anconeus pedicle approach. *Arch Orthop Trauma Surg*. 2005;125(7):469–474.
- Lakhey S, Sharma S, Pradhan RL, Pandey BK, Manandhar RR, Rijal KP. Osteosynthesis of intercondylar humerus fracture using Bryan and Morrey approach. *Kathmandu Univ Med J*. 2010;8(30):154–157.
- Amite Pankaj, Mallinath G, Malhotra Rajesh, Bhan Surya. Surgical management of intercondylar fractures of the humerus using triceps-reflecting anconeus pedicle (TRAP) approach. *Indian J Orthop*. 2007;41(3):219–223.



Contents lists available at ScienceDirect

## Journal of Arthroscopy and Joint Surgery

journal homepage: [www.elsevier.com/locate/jajs](http://www.elsevier.com/locate/jajs)

Review article

## Evolution of augmented reality applications in Orthopaedics: A systematic review



Sagar Bagwe Dr., MBBS PG Student Orthopedics,  
 Keshave Singh Dr., MBBS, MS (Orthopaedics) Senior Resident \*,  
 Abhishek Kashyap Dr., MBBS, MS (Orthopaedics) Professor,  
 Sumit Arora Dr., MBBS, MS (Orthopaedics) Associate Professor,  
 Lalit Maini Dr., MBBS, MS (Orthopaedics) Director Professor

Department of Orthopedics, Maulana Azad Medical College, India

## ARTICLE INFO

## Article history:

Received 4 January 2021

Accepted 10 February 2021

Available online 15 February 2021

## Keywords:

Augmented reality  
 Orthopaedics  
 Advancement  
 Technology  
 Evolution

## ABSTRACT

**Introduction:** Augmented Reality (AR) provides a state-of-art yet simplified and comprehensive approach for medical education, surgical planning and patient management. The initial descriptions of incorporation of AR in orthopedics were given around the year 2000. Recent studies have shown smooth transition of AR technology from bone phantom models, animal and cadaver studies into clinical trials. However, there are still a few technological hurdles faced by orthopedic surgeons. Our aim is to systematically review clinical studies for advantages and disadvantages provided by AR assistance in orthopedic surgeries. **Materials and Methods:** A systematic review of the current literature was performed to find the state of knowledge and applicability of evolving AR in Orthopedic surgery. A systematic search of the PubMed, Google Scholar and SCOPUS databases was performed by two independent reviewers up to November 2020. Recent news-updates till December 2020 were also added to the cumulative collected database. The systematic review followed the Preferred Reporting Items on Systematic Reviews and Meta-analysis (PRISMA) guidelines. **Results:** Initially 329 relevant studies (103 in Google Scholar, 145 in PubMed and 81 in SCOPUS) were identified in all databases. After screening for relevant studies on the basis of our inclusion and exclusion criteria, a total of 10 publications were included in the review as full-text articles to which we added 3 recent news updates relevant to AR in orthopedics. The studies were classified according to classification based on AR display technology. **Conclusion:** We found this system of classification, easy-to-use and easy-to-comprehend from orthopedic view. It helps in better understanding the evolution of AR technology and its implementation in orthopedics. With the continuously evolving AR technology and preparedness of integrating it in current traditional system, AR will assist orthopedic surgeons in all subspecialties to endeavor complex interventions with enhanced safety, accuracy and lower radiological exposure.

© 2021 International Society for Knowledge for Surgeons on Arthroscopy and Arthroplasty. Published by Elsevier, a division of RELX India, Pvt. Ltd. All rights reserved.

## 1. Introduction

Augmented Reality (AR) provides a state-of-art yet simplified and comprehensive approach for medical education, surgical

planning and patient management. In AR, the visual information in real space is enhanced by superimposing virtual objects with the use of computer-generated cues (visual and haptic feedback), so the operator can intuitively interact with both in real time.<sup>1</sup> The potential of AR is being harnessed in several fields of medicine,<sup>2</sup> surgical workplace<sup>3,4</sup> robotic surgery,<sup>5</sup> neurosurgery<sup>6</sup> endoscope assisted microsurgery,<sup>7,8</sup> pediatric surgery<sup>9,10</sup> and obstetrics and gynecology.<sup>11</sup> The word AR and virtual reality (VR) are often used in same context but they have contrasting differences. In VR, computer generated simulations are used to create a virtual space

\* Corresponding author. Room no.609, Department of Orthopaedics, Maulana Azad Medical College, Bahadur Shah Zafar Marg, New Delhi, 110002, India.

E-mail addresses: [bagwesv@gmail.com](mailto:bagwesv@gmail.com) (S. Bagwe), [drkeshave27@gmail.com](mailto:drkeshave27@gmail.com) (K. Singh), [drabhishekkashyap8@gmail.com](mailto:drabhishekkashyap8@gmail.com) (A. Kashyap), [mamc\\_309@yahoo.co.in](mailto:mamc_309@yahoo.co.in) (S. Arora), [drlalitmaini@gmail.com](mailto:drlalitmaini@gmail.com) (L. Maini).



different from reality. VR is utilized currently in gaming platforms and academic purposes in different fields.<sup>12</sup>

Schmalstieg et al.<sup>13</sup> classified AR technologies according to position of display system into 3 spaces, namely, head, body and world. The Head space consists of wearable Head-Mounted Display (HMD) such as HoloLens® and AR augmented operating microscopes with Heads-Up Display (HUD) such as Pentero 900®. The Body space include hand-held displays like smartphones and tablets. The World space include displays located at a fixed point in distant place like desktop monitors and projector-based displays.

Blackwell et al.<sup>14</sup> and Nikou et al.<sup>15</sup> gave the initial descriptions of incorporation of AR in orthopedic Operating Room (OR) around the year 2000. Over past two decades several preclinical studies have stated that AR could enhance the accuracy and lower radiation dose during the surgical procedures.<sup>16,17</sup> In the field of orthopedic traumatology, AR has been successfully assessed for placing K-wires in plastic femur,<sup>18</sup> placing guide wire for dynamic hip screw implantation in simulation on femur bone models,<sup>19</sup> for distal locking in interlocking femur nails<sup>20,21</sup> and tibial nailing,<sup>22</sup> placing percutaneous sacroiliac screws,<sup>23</sup> thoracolumbar pedicle screws<sup>24,25</sup> in bone phantoms and cadaveric studies. AR based navigation system is also evaluated in wrist arthroscopy,<sup>26</sup> in assessment of mechanical axis to determine the alignment of lower limb<sup>27</sup> and in ortho-oncology for tumor resection in animal femurs.<sup>28</sup> In terms of arthroplasty, AR based systems are explored to improve accuracy of osteotomies in total knee arthroplasty (TKA),<sup>29</sup> hip resurfacing,<sup>30</sup> and precisepositioning of acetabular cup during total hip arthroplasty (THA).<sup>31,32</sup>

Recent studies have shown transition of AR technology from lab models, bone phantom models, animal and cadaver studies into clinical trials.<sup>33</sup> However, there are few technological hurdles faced by orthopedic surgeons with AR namely, intraoperative incoherence in marker based registration which causes changes the position of projected images over surgical field when soft tissue disruption occurs during surgery<sup>34</sup>; masking of surrounding surgically relevant structures leaving the scope of inadvertent errors and complications in close proximity<sup>35</sup>; overcrowding of surgical field with too many visual cues thereby hindering smooth surgical experience<sup>36</sup> and other issues pertaining to additional hardware use causing motion sickness<sup>34</sup> and metal markers causing skin allergies.<sup>37</sup>

Our aim is to systematically review clinical studies published till date and provide comprehensive view of evolving AR technologies in orthopedic surgeries. We have also included recent news-updates of AR in orthopedics which are promising successful outcomes. We realized that AR is evolving with the success translating from pre-clinical studies to clinical trials, but it has still many miles to go. This technology has the propensity for further expansion and may change the approach with which orthopedic ailments will be perceived in future.

## 2. Materials and Methods

A systematic review of the current literature was performed by two independent reviewers to find the state of knowledge and applicability of Augmented Reality in Orthopaedic surgery. A systematic search of the following three databases was performed: “PubMed”, “Google Scholar” and “SCOPUS”, up to 12th November, 2020 using the key words “AUGMENTED REALITY” AND (“ORTHOPAEDIC” OR “ORTHOPAEDICS” OR “ORTHOPEDIC” OR “ORTHOPEDICS”). The systematic review followed the preferred reporting items on systematic reviews and meta-analysis (PRISMA) guidelines (Fig. 1).

Inclusion criteria were: (1) studies in English language; (2) minimum level III and above of Evidence using Oxford Centre for

Evidence-Based Medicine 2011 Levels of Evidence; (3) AR was used in musculoskeletal surgery including patients as subjects, and (4) applicability was reported.

Exclusion criteria were: (1) review articles, oral presentations, case reports, animal trials and in vitro studies, cross sectional studies; (2) non-English/German articles; (3) articles lacking an available full-text; (4) AR was used outside of musculoskeletal surgery such as in sports medicine. An eligibility screening using titles and abstracts was performed with subsequent full-text review after screening using the above criteria.

## 3. Results

Initially 329 relevant studies (103 in Google Scholar, 145 in PubMed and 81 in SCOPUS) were identified in all databases. After screening for relevant studies on the basis of our inclusion and exclusion criteria, a total of 10 publications were included in the review as full-text articles (Table 1). In the end, we further added relevant news articles and recent updates pertaining to applications of Augmented Reality in Orthopedics. A total of 3 such news articles were added (Table 2). A comprehensive review of these 13 studies were analyzed for advantages and disadvantages provided by AR assistance.

## 4. Discussion

The potential of AR in orthopedics is being harnessed since 2000, when preclinical studies based on cadavers, bone phantoms and models were being performed.<sup>15</sup> From 2013 onwards, several AR systems have been utilized in the clinical setting in orthopaedic OR. We reviewed all the clinical studies in our database and classified them in a simplified manner according to AR interface utilized. We used the Classification system described by Schmalstieg et al.,<sup>13</sup> where they divided the AR systems according to the placement of the Display technologies into 3 Spaces, namely “head,” “body,” and “world”. We found this system easy-to-use and easy-to-comprehend from orthopedic view. It helps in better understanding the evolution of AR technology and its implementation in orthopedics.

### 4.1. World space

- Camera Augmented Mobile C-Arm (CamC) AR system: In 1998, Siemens developed a Camera Augmented Mobile C-Arm (CamC). This device has an in-built camera in the C-Arm apparatus. This device was used to superimpose C-Arm images over the camera pictures of the patient and assisted in more accurate approximation of the non-visible parts over the visible parts. In 2018, Von der Heide et al.,<sup>38</sup> conducted an AR assisted study with CamC system in orthopedic trauma surgeries. The X-ray images were taken once by the C-Arm and then using the camera projector system and visual markers which were superimposed over the patient. Of the total of 73 surgeries documented, 28 were carried out using the CamC and remaining 45 using traditional C-Arm. They found that the radiation exposure was reduced significantly and it was easy to integrate the system into the traditional OR. They concluded that CamC had a great potential in orthopaedic surgery. However, they also stated one pitfall associated with the CamC system that the overlay of X-ray image movement over operative field was delayed whenever soft tissue manipulation was done during surgeries. This was due to the fact that visual markers were placed over skin.
- Augmented Reality Surgical Navigation system (ARSN): ARSN is a new navigation system being utilized in spine surgeries. The

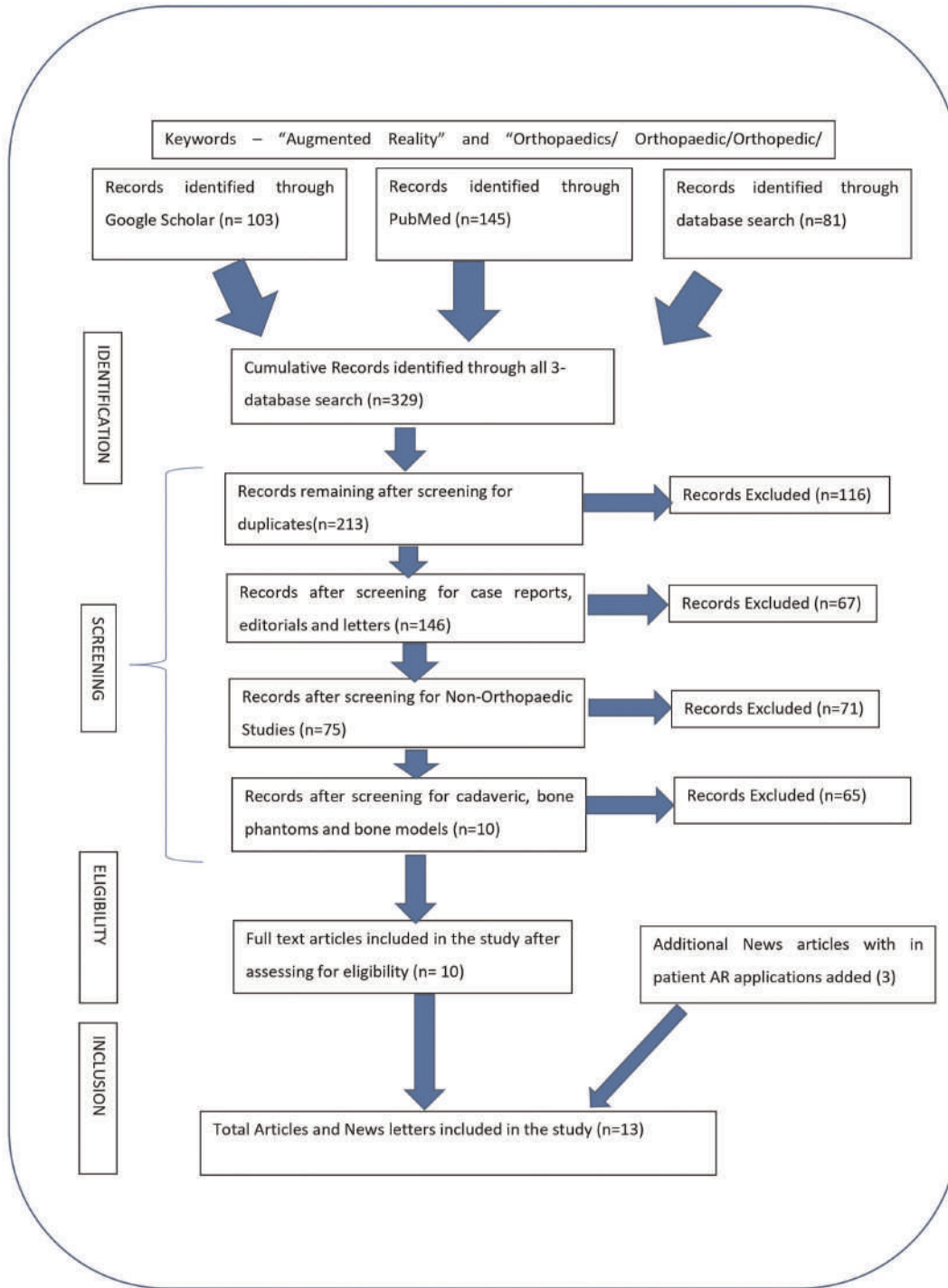


Fig. 1. Flowchart illustrating the selection of articles included in the systematic review.

navigation system was developed by Philips healthcare and consisted of a surgical table digitally integrated with a ceiling-mounted motorized C-arm with 2D/3D imaging capabilities and a medical grade monitor where intraoperative imaging is superimposed with the camera images. After initial cadaver studies, Elmi-Terander et al.<sup>39</sup> used ARSN technology in 21 patients to place 253 pedicle screws with high accuracy in acceptable operative time. There were no major limitations to the use of system except difficulty in obese patients. In another study by the same authors,<sup>40</sup> ARSN technology was compared

with free-hand fluoroscopy guided technique for pedicle screw insertion. The proportion of clinically accurate screws was significantly higher in the ARSN vs FH group ( $p < 0.05$ ) and the proportion of screws placed without a cortical breach was twice as high in the ARSN group compared to the FH group ( $p < 0.0001$ ).

- Augmented Reality Computer Assisted Spine Surgery (ARCASS): Wu et al.<sup>41</sup> used ARCASS system for Percutaneous Vertebroplasty (PVP) in three patients. The system was tested successfully on preoperative 3D models, dummy patients and animal models

**Table 1**  
Studies on the clinical use of augmented reality (AR) in Orthopaedics.

Study	Year	Sub-specialty	System used	Steps	Purpose	Results
1. Shen et al. <sup>44</sup>	2013	Trauma	Optical marker plate with depth camera.		To use AR based contouring of plate to reduce surgical time and invasiveness in acetabular fracture fixation.	AR-based reconstruction plate led to reduction of the intraoperative time, surgical invasiveness and blood loss.
2. Abe et al. <sup>47</sup>	2013	Spine	Virtual protractor with augmented reality (VIPAR) with HMD (Epson Moverio) and Markers.		To compare the precision of the insertion angle using AR assisted percutaneous vertebroplasty and free hand.	The AR-based system offered a remarkable help to surgeons to find the ideal needle trajectory and insertion point when performing percutaneous vertebroplasty
3. Ponce et al. <sup>48</sup>	2014	Arthroplasty	Google Glass (Google Inc, Mountain View, California) (Head Mounted device) with VIPAAR.		To analyze the feasibility of AR technology with a mobile videoconferencing platform in a surgical setting.	Postoperative range of motion and pain reduction in the patients was satisfactory as per guidelines and showed the feasibility of VIPAAR.
4. Wu et al. <sup>41</sup>	2014	Spine	ARCASS system consisting of industrial camera projector and metal markers.		To assess the decrease in surgical errors and radiation exposure using ARCASS for spinal surgery	The proposed AR system seems highly efficient and promising, with the reduction in time of finding a suitable entry point and reduced radiation dose to patients
5. von der Heide et al. <sup>38</sup>	2018	Trauma	Camera-augmented mobile C-arm (CamC)		To reduce the standard radiation exposure in orthopaedic surgery and make changes to C arm guidance.	The X ray shots were reduced to half of conventional requirement. surgical time remained the same.
6. Elmi-Terander et al. <sup>39</sup>	2019	Spine	ARSN integrated system based on video input from 4 optical cameras around the C-arm detector and optical markers.		To assess the quality of pedicle screw placement using ARSN.	AR-based surgical navigation could offer acceptable time of navigation and high accuracy of placement of pedicle screws
7. Carl et al. <sup>46</sup>	2019	Spine	HMD operating Microscope (Pentero 9000) with Marker		To implement a simplistic workflow that allows to use augmented reality (AR) support as routine in spine surgery.	A microscope-based AR environment was successfully implemented for spinal surgery which can be routinely used in future.
8. Elmi-Terander et al. <sup>40</sup>	2020	Spine	ARSN integrated system based on video input from 4 optical cameras around the C-arm detector.		To compare pedicle screw fixation using ARSN to conventional free hand technique.	AR assisted surgical navigation provided higher screw placement accuracy compared to free-hand.
9. Hu et al. <sup>37</sup>	2020	Spine	ARCASS system consisting of industrial camera projector and metal markers.		To assess feasibility of ARCASS system for Percutaneous Vertebroplasty.	The results indicated that the guidance of ARCASS system allowed more accurate placement of instruments during PVP with reduced operative time and unnecessary radiation exposure.
10. Ogawa et al. <sup>45</sup>	2020	Arthroplasty	Smart-phone camera with QR code.		To explore whether AR assisted acetabular component placement would have better angle as compared to free hand.	There was no clinically significant difference between AR assisted and Goniometer based measurement of the anteversion and inclination angles.

**Table 2**  
Under-study relevant recent literature on the clinical use of Augmented Reality in Orthopaedics.

Publisher name	Year	AR System used	Subspecialty	HMD used	Purpose	Remarks
Microsoft Devices Blog <sup>49</sup>	February 2017	Stryker Hybrid OR's	General Orthopaedics	Microsoft HoloLens	An attempt at creating a smart AR Integrated multipurpose OR	Work in progress
OrthoSpineNews <sup>50</sup>	December 2020	Pixee Knee+	Arthroplasty	Vuzix M400 Glasses	To provide real time navigation in a TKA by displaying essential AR information in the operating field.	FDA approval awaited 40 successful TKA's performed till date
OrthoSpineNews <sup>51</sup>	December 2020	Medacta Next AR Platform	Arthroplasty	AR Smart Glasses	To visualize the structures of the knee and track progress in real time directly on the operative field, without having to view the screen, providing better ergonomics.	FDA approved Used AR augmented Infrared Tracking system for TKA in the USA.

prior to using on real patients. It projects 3D images reconstructed from preoperative CT scans onto patient during intraoperative period via industrial camera and projector using the Visible Patient tool® (Research Institute against Digestive Cancer, France). The procedure includes initially calibrating the camera-projector with the metal markers using marker-based registration system. The marker-based registration system merges preoperative 3D images with intraoperative camera views of patient which were projected on the patient. This system was found to easy-to-use when judged with other available computer navigation system. The surgeons achieved high accuracy and marked reduction of surgical time and radiation exposure in finding the suitable entry points.

Hu et al.,<sup>37</sup> further verified the efficacy in terms of high accuracy, lower operative time and reduced radiation exposure in case control study over 18 patients with 9 in each group. They concluded that this system had an ergonomic advantage as the surgeon did not have to shift focus from the projected image on the patient's body to the monitor as required in other AR navigation systems like CamC and ARSN. However, they stated few limitations of system, namely, first the use of metal markers which can cause skin allergy. Second, the use of ARCASS system was only useful for identification of bony entry point and has limited effect on the process of setting trocar and cement injection. They highlighted the fact that real-time fluoroscopy is must to check cement leakage which cannot be replaced by any guidance or navigation system. Third, intrusion into the line of sight while operating blocks the projected area. Fourth, short working range (150–200 cm between the patient and projector).

Yoon et al.<sup>42</sup> commented that, use of head mounted devices in place of projector to overlay the images onto surgical field in future AR system will further enhance surgical experience by obviating major limitations. In the same regard use of HMD AR smart glasses (Caduceus® smart surgical glasses navigation system<sup>43</sup>) in ARCASS system is under consideration.

#### 4.2. Body space

- Depth camera with optical marker: This was one of the initial systems which was used by Shen et al.<sup>44</sup> in 2013. They used the system for patient specific acetabular contouring of plates in which they used basic tools such as a video camera, printed optical markers and a desktop to create a lightweight AR system. A virtual contoured plate was designed according to fracture pattern over which the actual plate was constructed. This pre-contoured plate with the use of light-weight AR system, was implanted in patients. They reported decreased surgical time, less invasive surgery and more accurate anatomical reduction. They realized the importance of stereoscopic cameras and HMD's in enhancing the depth perception of the AR

environment and further reducing the difficulty of contouring. This system required a preserved contralateral pelvis as a prerequisite for template design and hence, the system could not be used in more complex trauma involving bilateral acetabular fractures.

- Smartphone camera with QR code: Ogawa et al.<sup>45</sup> developed an AR-based portable navigation system where they used the smartphone display for viewing functional pelvic plane and placing acetabular cup during THA. They compared this system with traditional methods in randomized control study involving 46 patients undergoing THA with 23 in each group. The inclination and anteversion were measured by Vuforia® software-based application (Unity and Vuforia SDK software, Unity Technologies, San Francisco, CA, USA). Intraoperatively patient specific QR codes were used to guide the cup placement. This system resulted in using additional pins in ilium and increased surgical time with no significant difference in outcome ( $p = 0.009$  for radiographic measurement and  $p = 0.02$  for CT measurements). This also added to total cost of surgery and hence not recommended in its present state by the authors.

#### 4.3. Head space

- Augmented Reality with Heads Up Display Operating Microscope: Carl et al.<sup>46</sup> used HUD enabled operating microscope Pentero® 900 (Zeiss, Oberkochen, Germany) integrated with AR to perform 42 spinal surgeries. They utilized low dose intraoperative CT scans for automatic registration and nonlinear registration system for integration of cumulative preoperative data. The preoperative plan with specific targets and risk structures was superimposed by AR technology with anatomical mapping and additional manual segmentation into surgical field visualized in HUD of microscope. They further enhanced AR experience by using sequential video superimposition and selectively highlighting area of interest. They stated that the use of AR significantly improves anatomical orientation in the surgical field and enhance surgical accuracy. They also acknowledge the importance of AR as education tool for residents.
- Augmented Reality using wearable Head mounted Display (HMD): The technical advancements have brought in a variety of wearable HMD's by several companies like Epson (MOVERIO®), Google (Google Glass®), Microsoft (HoloLens®) and Vuzix (Smart Glasses M400®). The use of such devices promises intuitive and convenient use of Augmented Reality in surgical field.

In 2013, Abe et al.<sup>47</sup> used an AR construct called as VIPAR (Virtual Protractor with Augmented Reality) which consists of head-mount display (HMD) with a tracking camera and a marker sheet for PVP in 5 patients. The system was first evaluated in 40 spine



phantom models to check for viability and accuracy. The system utilized preoperative CT scans to plan the needle trajectory, and project it in surgical field to using AR technology to guide needle insertion. They found that the insertion angle precision was better with AR assistance than with free hand technique. However, the major fallback of this system was absence of intraoperative registration of AR system and hence, it could not adjust for postural difference and patient's intraoperative movement; neither it can assist significantly in complex anatomy like scoliosis.

Ponce et al.<sup>48</sup> in 2014, demonstrated the use of Google Glass® assisted AR system to remotely assist shoulder arthroplasty. They conducted a study in which they used a novel surgical technique for Shoulder arthroplasties where a remote surgeon was able to guide the intraoperative surgeon in real time with the use of Google Glass. The system has important skill training implications. However, further research is warranted to gather more evidence.

- Studies in-process- AR in Orthopaedics:

Stryker® in association with Microsoft HoloLens® are further developing hybrid ORs.<sup>49</sup> They are bringing the latest Augmented Reality systems in the field of orthopaedic surgery and have made promising claims. However, the validation of such techniques will be decided in future as more proper studies are conducted. In AR assisted arthroplasty, Pixee® Medical company has developed a Knee + AR system®50 using Vuzix M400® AR smart glasses. More than 40 Total Knee Replacement surgeries have been done in Europe using this technique. The system provided real time navigation throughout surgery, displaying essential AR information in the surgeon's field of view. More recently, Medacta® developed an FDA approved AR system known as NextAR™ TKA<sup>51</sup> which utilizes a preoperative CT scan of the patient's knee for surgical planning and AR augmented smart glasses with infrared tracking system during the surgery. The initial results are promising, but further studies and documentation are yet to be published.

## 5. Conclusion

The ability of AR devices to superimpose objects (trajectory and resection guides) and visual cues (soft tissue and bony anatomy) in operative field, provide real time intuitive workflow system to endeavor complex interventions with enhanced safety, accuracy and lower radiological exposure. With continuing technological advancement in AR and preparedness of integrating it in current traditional system, we hope more satisfactory results for patients in orthopedics.

## Financial aid

None.

## Declaration of competing interest

None.

## References

- Amin D, Govilkar S. Comparative study of augmented reality sdk's. *Int J Comput Sci Appl*. 2015;5(1):11–26. <https://doi.org/10.5121/ijcsa.2015.5102>.
- Eckert M, Volmerg JS, Friedrich CM. Augmented reality in medicine: systematic and bibliographic review. *JMIR MhealthUhealth*. 2019;7(4), e10967. <https://doi.org/10.2196/10967>.
- Khor WS, Baker B, Amin K, Chan A, Patel K, Wong J. Augmented and virtual reality in surgery—the digital surgical environment: applications, limitations and legal pitfalls. *Ann Transl Med*. 2016;4(23):454. <https://doi.org/10.21037/atm.2016.12.23>.
- Slade SJA, Veillette CJH. The application of wearable technology in surgery: ensuring the positive impact of the wearable revolution on surgical patients. *Front Surg*. 2014;1:39. <https://doi.org/10.3389/fsurg.2014.00039>.
- Moglia A, Ferrari V, Morelli L, Ferrari M, Mosca F, Cuschieri A. A systematic review of virtual reality simulators for robot-assisted surgery. *Eur Urol*. 2016;69(6):1065–1080. <https://doi.org/10.1016/j.eururo.2015.09.021>.
- Pelargos PE, Nagasawa DT, Lagman C, et al. Utilizing virtual and augmented reality for educational and clinical enhancements in neurosurgery. *J Clin Neurosci*. 2017;35:1–4. <https://doi.org/10.1016/j.jocn.2016.09.002>.
- Marcus HJ, Pratt P, Hughes-Hallett A, et al. Comparative effectiveness and safety of image guidance systems in surgery: a preclinical randomised study. *Lancet*. 2015;385(Suppl 1):S64. [https://doi.org/10.1016/S0140-6736\(15\)60379-8](https://doi.org/10.1016/S0140-6736(15)60379-8).
- Mahmud N, Cohen J, Tsourides K, Berzin TM. Computer vision and augmented reality in gastrointestinal endoscopy. *Gastroenterol Rep (Oxf)*. 2015;3(3):179–184. <https://doi.org/10.1093/gastro/gov027>.
- Kearns JT, Gundeti MS. Pediatric robotic urologic surgery—2014. *J Indian Assoc Pediatr Surg*. 2014;19(3):123–128. <https://doi.org/10.4103/0971-9261.136456>.
- Hamacher A, Kim SJ, Cho ST, et al. Application of virtual, augmented, and mixed reality to urology. *Int Neurourol J*. 2016;20(3):172–181. <https://doi.org/10.5213/inj.1632714.357>.
- Smith ML, Foley MR. Transforming clinical education in obstetrics and gynecology: gone is the day of the sage on the stage. *Obstet Gynecol*. 2016;127(4):763–767. <https://doi.org/10.1097/AOG.0000000000001356>.
- Azuma RT. A survey of augmented reality. presence: teleoperators and virtual environments. 1997;6(4):355–385. <https://doi.org/10.1162/pres.1997.6.4.355>.
- Schmalstieg D, Hollerer T. *Augmented Reality: Principles and Practice*. first ed. Boston: Addison-Wesley; 2016.
- Blackwell M, Morgan F, DiGioia AM. Augmented reality and its future in orthopaedics. *Clin Orthop Relat Res*. 1998;354:111–122.
- Nikou C, DiGioia AM, Blackwell M, Jaramaz B, Kanade T. Augmented reality imaging technology for orthopaedic surgery. *Operat Tech Orthop*. 2000;10(1):82–86. [https://doi.org/10.1016/S1048-6666\(00\)80047-6](https://doi.org/10.1016/S1048-6666(00)80047-6).
- Unberath M, Fotouhi J, Hajek J, et al. Augmented reality-based feedback for technician-in-the loop C-arm repositioning. *Healthc Technol Lett*. 2018;5(5):143–147. <https://doi.org/10.1049/htl.2018.5066>.
- Befrui N, Fischer M, Fuerst B, et al. 3D augmented reality visualization for navigated osteosynthesis of pelvic fractures. *Unfallchirurg*. 2018;121(4):264–270. <https://doi.org/10.1007/s00113-018-0466-y>.
- Hiranaka T, Fujishiro T, Hida Y, et al. Augmented reality: the use of the Pico-Linker smart glasses improves wire insertion under fluoroscopy. *World J Orthoped*. 2017;8(12):891–894. <https://doi.org/10.5312/wjo.v8.i12.891>.
- Van Duren BH, Sugand K, Wescott R, Carrington R, Hart A. Augmented reality fluoroscopy simulation of the guide-wire insertion in DHS surgery: a proof of concept study. *Med Eng Phys*. 2018;55(5):52–59. <https://doi.org/10.1016/j.medengphys.2018.02.007>.
- Londei R, Esposito M, Diotte B, et al. Intra-operative augmented reality in distal locking. *Int J Comput Assist Radiol Surg*. 2015;10(9):1395–1403. <https://doi.org/10.1007/s11548-015-1169-2>.
- Diotte B, Fallavollita P, Wang L, et al. Multi-modal intra-operative navigation during distal locking of intramedullary nails. *IEEE Trans Med Imag*. 2015;34(2):487–495. <https://doi.org/10.1109/TMI.2014.2361155>.
- Ma L, Zhao Z, Zhang B, et al. Three-dimensional augmented reality surgical navigation with hybrid optical and electromagnetic tracking for distal intramedullary nail interlocking. *Int J Med Robot*. 2018;14(4), e1909. <https://doi.org/10.1002/rcs.1909>.
- Wang H, Wang F, Leong APY, Xu L, Chen X, Wang Q. Precision insertion of percutaneous sacroiliac screws using a novel augmented reality-based navigation system: a pilot study. *Int Orthop*. 2016;40(9):1941–1947. <https://doi.org/10.1007/s00264-015-3028-8>.
- Elmi-Terander A, Skulason H, Söderman M, et al. Surgical navigation technology based on augmented reality and integrated 3d intraoperative imaging: a spine cadaveric feasibility and accuracy study. *Spine*. 2016;41(21):E1303–E1311. <https://doi.org/10.1097/BRS.0000000000001830>.
- Gibby JT, Swenson SA, Cvetko S, Rao R, Javan R. Head-mounted display augmented reality to guide pedicle screw placement utilizing computed tomography. *Int J Comput Assist Radiol Surg*. 2019;14(3):525–535. <https://doi.org/10.1007/s11548-018-1814-7>.
- Zemirline A, Agnus V, Soler L, Mathoulin CL, Obdeijn M, Liverneaux PA. Augmented reality-based navigation system for wrist arthroscopy: feasibility. *J Wrist Surg*. 2013;2(4):294–298. <https://doi.org/10.1055/s-0033-1359321>.
- Fallavollita P, Brand A, Wang L, et al. An augmented reality C-arm for intra-operative assessment of the mechanical axis: a preclinical study. *Int J Comput Assist Radiol Surg*. 2016;11(11):2111–2117. <https://doi.org/10.1007/s11548-016-1426-z>.
- Cho HS, Park YK, Gupta S, et al. Augmented reality in bone tumour resection. *Bone Joint Res*. 2017;6(3):137–143. <https://doi.org/10.1302/2046-3758.63.BJR-2016-0289.R1>.
- Pokhrel S, Alsadoon A, Prasad PWC, Paul M. A novel augmented reality (AR) scheme for knee replacement surgery by considering cutting error accuracy. *Int J Med Robot*. 2019;15(1), e1958. <https://doi.org/10.1002/rcs.1958>.
- Liu H, Auvinet E, Giles J, Rodriguez y Baena F. Augmented reality-based navigation for computer assisted hip resurfacing: a proof-of-concept Study. *Ann Biomed Eng*. 2018;46(10):1595–1605. <https://doi.org/10.1007/s10439-018-2055-1>.

31. Fotouhi J, Alexander CP, Unberath M, et al. Plan in 2-D, execute in 3-D: an augmented reality solution for cup placement in total hip arthroplasty. *J Med Imaging*. 2018;5(2):021205. <https://doi.org/10.1117/1.JMI.5.2.021205>.
32. Logishetty K, Western L, Morgan R, Iranpour F, Cobb JP, Auvinet E. Can an augmented reality headset improve accuracy of acetabular cup orientation in simulated THA? A randomized trial. *Clin Orthop Relat Res*. 2018;477(5):1190–1199. <https://doi.org/10.1097/CORR.0000000000000542>.
33. Chytas D, Malahias M-A, Nikolaou VS. Augmented reality in orthopedics: current state and future directions. *Front Surg*. 2019;6:38. <https://doi.org/10.3389/fsurg.2019.00038>.
34. Gavaghan K, Oliveira-Santos T, Peterhans M, et al. Evaluation of a portable image overlay projector for the visualisation of surgical navigation data: phantom studies. *Int J Comput Assist Radiol Surg*. 2012;7(4):547–556. <https://doi.org/10.1007/s11548-011-0660-7>.
35. Dixon BJ, Daly MJ, Chan H, et al. Surgeons blinded by enhanced navigation: the effect of augmented reality on attention. *Surg Endosc*. 2013;27(2):454–461. <https://doi.org/10.1007/s00464-012-2457-3>.
36. Moro C, Stromberga Z, Raikos A, Stirling A. The effectiveness of virtual and augmented reality in health sciences and medical anatomy. *Anat Sci Educ*. 2017;10(6):549–559. <https://doi.org/10.1002/ase.1696>.
37. Hu M-H, Chiang C-C, Wang M-L, Wu N-Y, Lee P-Y. Clinical feasibility of the augmented reality computer-assisted spine surgery system for percutaneous vertebroplasty. *Eur Spine J*. 2020;29(7):1590–1596. <https://doi.org/10.1007/s00586-020-06417-4>.
38. von der Heide AM, Fallavollita P, Wang L, et al. Camera-augmented mobile C-arm (CamC): a feasibility study of augmented reality imaging in the operating room. *Int J Med Robot*. 2018;14(2):1–8. <https://doi.org/10.1002/rcs.1885>.
39. Elmi-Terander A, Nachabe R, Skulason H, et al. Feasibility and accuracy of thoracolumbar minimally invasive pedicle screw placement with augmented reality navigation technology. *Spine*. 2018;43(14):1018–1023. <https://doi.org/10.1097/BRS.0000000000002502>.
40. Elmi-Terander A, Burström G, Nachabe R, et al. Pedicle screw placement using augmented reality surgical navigation with intraoperative 3D imaging: a first in-human prospective cohort study. *Spine*. 2019;44(7):517–525. <https://doi.org/10.1097/BRS.0000000000002876>.
41. Wu J-R, Wang M-L, Liu K-C, Hu M-H, Lee P-Y. Real-time advanced spinal surgery via visible patient model and augmented reality system. *Comput Methods Progr Biomed*. 2014;113(3):869–881. <https://doi.org/10.1016/j.cmpb.2013.12.021>.
42. Yoon JW, Chen RE, Han PK, Si P, Freeman WD, Pirris SM. Technical feasibility and safety of an intraoperative head-up display device during spine instrumentation. *Int J Med Robot*. 2017;13(3):e1770. <https://doi.org/10.1002/rcs.1770>.
43. Taiwan main orthopaedic biotechnology Co. Ltd. [Internet]. [cited 2020 Dec 27] <https://www.surglasses.com/>.
44. Shen F, Chen B, Guo Q, Qi Y, Shen Y. Augmented reality patient-specific reconstruction plate design for pelvic and acetabular fracture surgery. *Int J CARS*. 2013;8(2):169–179. <https://doi.org/10.1007/s11548-012-0775-5>.
45. Ogawa H, Hasegawa S, Tsukada S, Matsubara M. A pilot study of augmented reality technology applied to the acetabular cup placement during total hip arthroplasty. *J Arthroplasty*. 2018;33(6):1833–1837. <https://doi.org/10.1016/j.arth.2018.01.067>.
46. Carl B, Bopp M, Saß B, Pojskic M, Voellger B, Nimsky C. Spine surgery supported by augmented reality. *Global Spine J*. 2020;10(2\_suppl):415–555. <https://doi.org/10.1177/2192568219868217>.
47. Abe Y, Sato S, Kato K, et al. A novel 3D guidance system using augmented reality for percutaneous vertebroplasty. *J Neurosurg Spine*. 2013;19(4):492–501. <https://doi.org/10.3171/2013.7.SPINE12917>.
48. Ponce BA, Menendez ME, Oladeji LO, Fryberger CT, Dantuluri PK. Emerging technology in surgical education: combining real-time augmented reality and wearable computing devices. *Orthopedics*. 2014;37(11):751–757. <https://doi.org/10.3928/01477447-20141023-05>.
49. Blog MD. Stryker Chooses Microsoft HoloLens to Bring Operating Room Design into the Future with 3D [Internet]. *Microsoft Devices Blog*; 2017 [cited 2020 Dec 27] <https://blogs.windows.com/devices/2017/02/21/stryker-chooses-microsoft-hololens-bring-operating-room-design-future-3d/>.
50. PRNewswire. First Knee Replacement Surgery Successfully Completed Using Augmented Reality Technology from Pixee Medical AR Knee+ and Vuzix M400 Smart Glasses [Internet]. Rochester, N.Y.: OrthoSpineNews; 2020. <https://orthospinenews.com/2020/06/30/first-knee-replacement-surgery-successfully-completed-using-augmented-reality-technology-from-pixee-medical-ar-knee-and-vuzix-m400-smart-glasses/>.
51. PRNewswire. Seeing Is Believing: Hospital for Special Surgery First in U.S. To Use Augmented Reality Platform for Knee Replacement [Internet]. New York (USA): OrthoSpineNews; 2020 [cited 2020 Dec 27] <https://orthospinenews.com/2020/12/17/seeing-is-believing-hospital-for-special-surgery-first-in-u-s-to-use-augmented-reality-platform-for-knee-replacement/>.

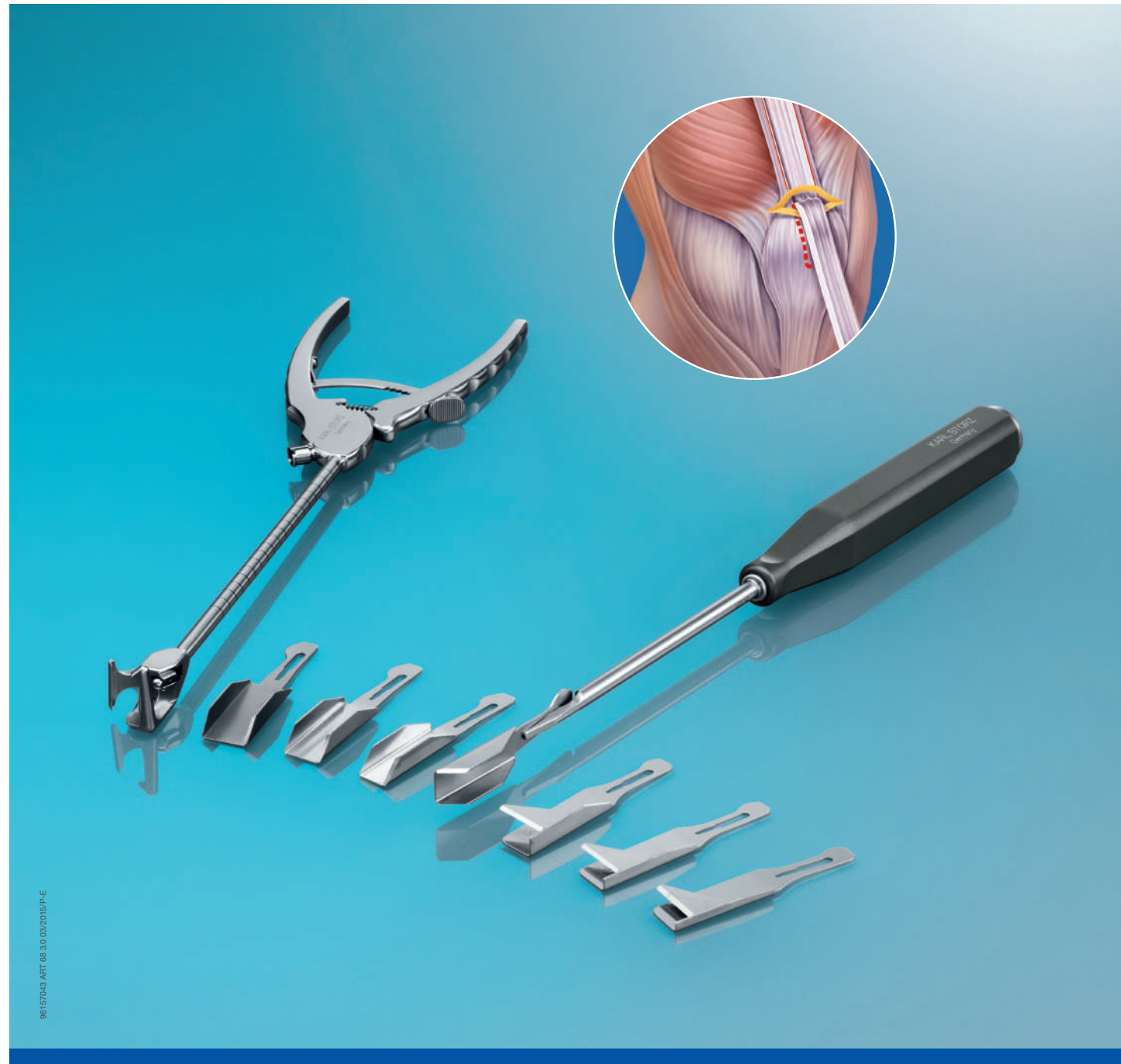


Embase®

Trusted resource  
for the most comprehensive  
biomedical information



ELSEVIER



98157043 ART. 68 3.0 03/2015/P-E

# QuadCut

Minimally Invasive Quadriceps Tendon Harvesting

**STORZ**  
KARL STORZ – ENDOSKOPE  
THE DIAMOND STANDARD

[www.karlstorz.com](http://www.karlstorz.com)

