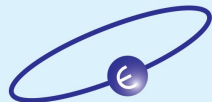

Now disperse away worries of compliance from your patient's life with a better and faster recovery with



## DISPERZYME<sup>®</sup>

Trypsin B.P. 96mg, Bromelain 180mg, Rutoside Trihydrate B.P. 200mg

**Dispersible tablets**

*The only brand with German Technology*

### Advanced technology

Each particle is enteric coated thus passes safely through stomach and gives maximum intestinal absorption and bioavailability

#### For edema and inflammation in<sup>1</sup>

Trauma
Post operative inflammation
Cellulitis
Wound healing

#### For soft tissue and sport injuries<sup>2,3</sup>

Reduces pain and inflammation and helps in faster recovery from

Tendonitis	Spondylopathies	Sprains
Frozen shoulder	Contusions	Bursitis


### From pioneers of systemic enzyme therapy in India

**Sources:**

[1] B.N.Savant, H.K.Parkh, G.V.Bafary, Efficacy and tolerability of phlogenzym in controlling postoperative inflammation in patients undergoing major surgical resection and reconstruction for head and neck malignancies, Prospective randomized, open phase III clinical trial, Tata Memorial Hospital, Mumbai-400012 [2] Rihan H. D., Treatment of ankle distortion with Phlogenzyme (1992) [3] Baumüller M., The use of hydrolytic enzymes in blunt soft tissue injuries and ankle distortion, General Medicine 19 (1990), 178.



Office:  
81/A, Mittal Chambers,  
Nariman Point, Mumbai 400 021  
Maharashtra.



JOURNAL OF ARTHROSCOPY AND JOINT SURGERY

# JAJ S

Official Journal of the International Society for Knowledge for Surgeons on Arthroscopy and Arthroplasty (ISKSAA)

**Indexed In Scopus & Embase**

**Volume 6 Number 1 January-April 2019**

**E-ISSN: 2214-9635  
P-ISSN: 2542-6001**

Available online at [www.sciencedirect.com](http://www.sciencedirect.com)

**ScienceDirect**


JAJ S

VOLUME 6

NUMBER 1

JANUARY-APRIL 2019

PAGES 1-78



ISKSAA (International Society for Knowledge for Surgeons on Arthroscopy and Arthroplasty) is a society of orthopaedic surgeons from around the world to share and disseminate knowledge, support research and improve patient care in Arthroscopy and Arthroplasty. We are proud to announce that ISKSAA membership has crossed the **1800** mark ( India & Overseas ) making it the **fastest growing Orthopaedic Association in the country** in just 5 years of its inception . With over **350000 hits from over 160 countries** on the website [www.isksaa.com](http://www.isksaa.com) & more and more interested people joining as members of ISKSAA, we do hope that ISKSAA will stand out as a major body to provide opportunities to our younger colleagues in training, education and fellowships.

#### Our Goals.....

- To provide health care education opportunities for increasing cognitive and psycho-motor skills in Arthroscopy and Arthroplasty
- To provide CME programs for the ISKSAA members as well as other qualified professionals.
- To provide Clinical Fellowships in Arthroscopy and Arthroplasty
- To provide opportunities to organise and collaborate research projects
- To provide a versatile website for dissemination of knowledge

#### ISKSAA Life Membership

The membership is open to Orthopaedic Surgeons, Postgraduate Orthopaedic students and Allied medical personal interested in Arthroscopy & Arthroplasty.

#### Benefits of ISKSAA Life membership include....

- **Free Subscription** of ISKSAA's official , SCOPUS INDEXED , EMBASE INDEXED peer reviewed , online scientific journal **Journal of Arthroscopy and Joint Surgery ( JAJIS )** .
- Eligibility to apply for **ISKSAA's Prestigious Fellowship Programme**. We have finalised affiliations with ESSKA , ISAKOS , BOA , BASK , BOSTAA , BESS , Edge Hill University at Wrightington and FLINDERS MEDICAL CENTRE , IMRI AUSTRALIA to provide more **ISKSAA Fellowships** in India , UK , USA , Australia and Europe . We have offered over **300 Clinical Fellowships as of date including 54 in ISKSAA 2014 , 40 in ISKSAA 2015 , 63 in ISKSAA 2016 , 55 in ISKSAA 2017 & 20 in ISKSAA 2018 and over 50 ISKSAA Wrightington MCh Fellowships from 2014 to 2018 .**
- We have initiated **ISKSAA JOD & ISKSAA WHA paid fellowship programs** from 2017 for 2 months based in Australia .
- **The next round of 100 ISKSAA fellowships interviews will be in ISKSAA BESS 2019 in March 2-3<sup>rd</sup> 2019 for 2019 and 2020 at New Delhi along with the ISKSAA Wrightington MCh Fellowships .**
- **We had offered 60 1 week ISKSAA certified Fellowships from 11<sup>th</sup> – 15<sup>th</sup> June & 25-29<sup>th</sup> June 2018 for ISKSAA members registered for ISKSAA LEEDS 2018 on a first come first basis .**
- Only as a life member , you can enjoy the benefit of **reduced Congress charges in ISKSAA BESS UK 2019 being held at New Delhi , India .**
- **Member's only section** on the website which has access to the conference proceedings and live surgeries of ISKSAA 2012 , 2013 , 2014 & 2016 along with a host of other educational material .
- Important opportunity for interaction with world leaders in Arthroscopy & Arthroplasty .
- Opportunity to participate in ISKSAA courses and workshops

**To enjoy all the benefits & privileges of an ISKSAA member, you are invited to apply for the Life membership of ISKSAA by going to the membership registration section of the website and entering all your details electronically. All details regarding membership application and payment options are available on the website ([www.isksaa.com](http://www.isksaa.com))**



Wrightington, Wigan and Leigh   
NHS Foundation Trust

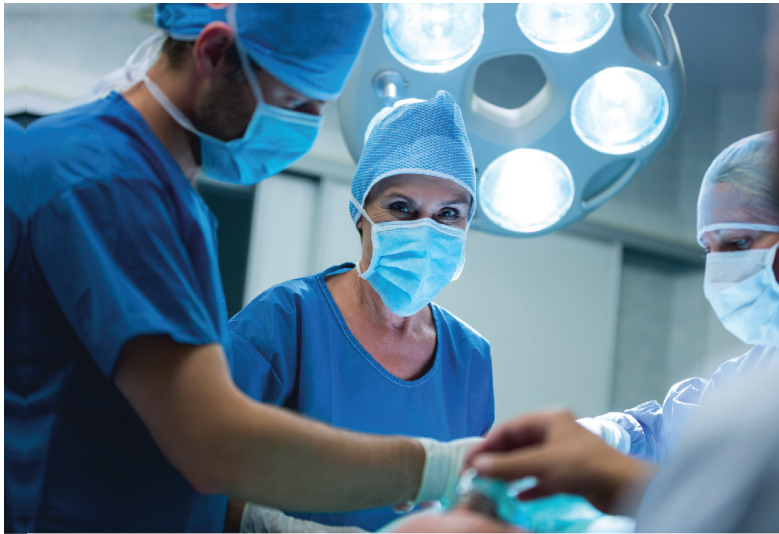

Edge Hill University

#### **ISKSAA – Wrightington International Training Fellowships leading to MCh degree ( 2019 ) .**

Interested candidates are invited to apply for a unique opportunity for post-graduate education and subspecialist training in the UK

1. The interested candidates are encouraged to look at the University website link . The programme is aimed at motivated candidates who wish to come to UK to obtain 2-3 years of clinical experience, specialist surgical training and an MCh degree from Wrightington Hospital and Edge Hill University.
2. Initial application should be via email. Just send updated CV , photo along with 2 satisfactory recommendation letters from current / recent trainer to ISKSAA president at [isksaafellowships@gmail.com](mailto:isksaafellowships@gmail.com). This will serve as an initial screening to judge eligibility. The last date for applications is **10<sup>TH</sup> February 2019 .**
3. **The interviews are slated for 3<sup>rd</sup> March 2019 during ISKSAA BESS UK 2019 in New Delhi .**
4. **Having cleared the IELTS exam** before the interviews will be of advantage for final selections .
5. The Clinical posts would start in August 2019 / 2020 although if candidates were to be interested for Aug 2020 and August 2021 start, they could still apply.
6. The MCh course is at the Edge Hill University and although most of the payment for the course can be made along the way in installments over the 2 years, there would be an initial Commitment of £17,500 to be made to secure the place before the formalities with Royal colleges and GMC are commenced at this End. The salary scales are detailed with the information sheet as well.
7. There will be two posts per year as the "Wrightington - ISKSAA MCh Fellowship". There would be an **assured Wrightington placement** during the 2-year UK rotation via this stream .**Only ISKSAA Life Members can apply for these posts .**

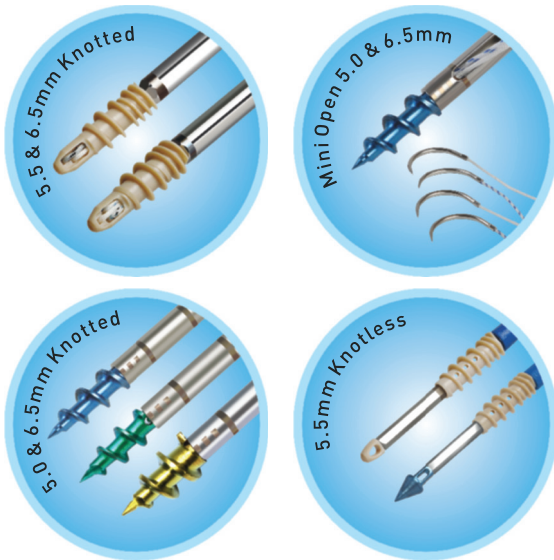


**BIOTEK**<sup>®</sup>  
we put life in metal

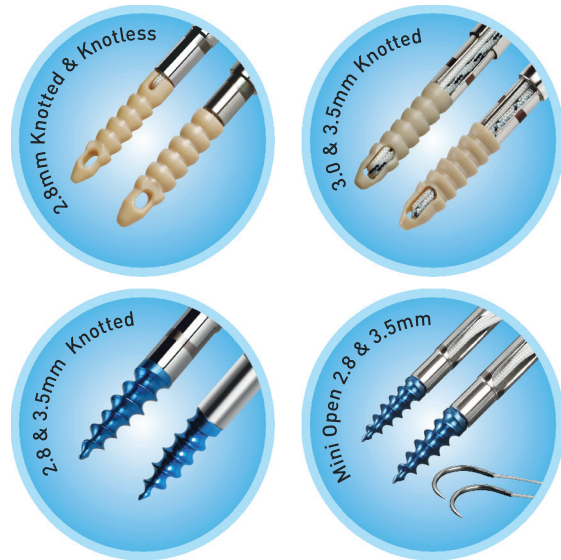
Technology that  
**touches** *life.*

## SHOULDER ARTHROSCOPY

### Suture Anchors for Rotator Cuff Repair




### Suture Anchors for Slap & Bankart Repair

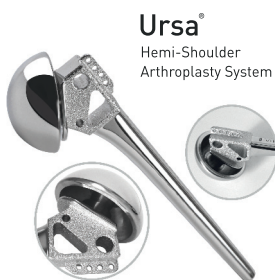

## OPEN LATARJET

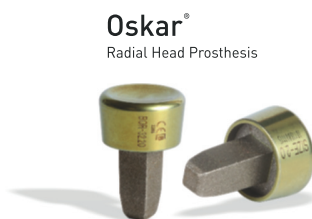### Latarjet / Coracoid Process Transfer



## EXTREMITIES



**Ursa**<sup>®</sup>  
Hemi-Shoulder  
Arthroplasty System



**Oskar**<sup>®</sup>  
Radial Head Prosthesis



**Texx**<sup>®</sup>  
Total Elbow  
Arthroplasty System




**BIOTEK**<sup>®</sup>  
we put life in metal

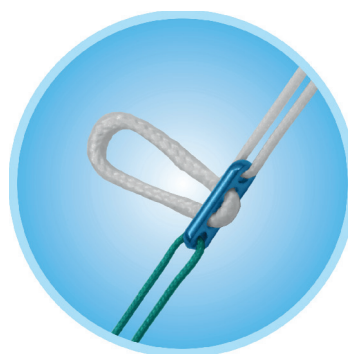
Technology that  
**touches** *life.*

## KNEE ARTHROSCOPY

**Buttonfix**  
Adjustable Loop Device



**Onbutton CL**  
Closed Loop Device



Offering two of the strongest soft tissue suspensory fixation devices for Cruciate Reconstruction.

**Softfix-PK**  
Interference Screws  
(PEEK)



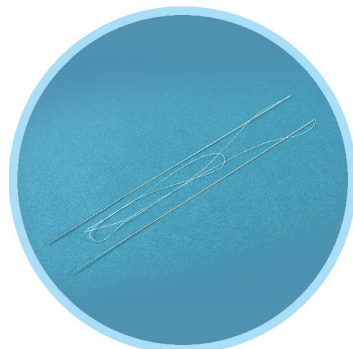
**Softfix**  
Interference Screws  
(Titanium)



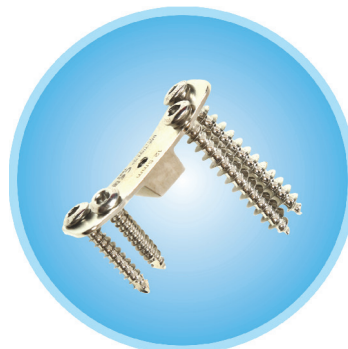**Osteotwin**  
Bio Composite Interference  
Screws



## Meniscus Repair (Inside-Out)



## Biddu HTO



Above all the products are CE Certified and Indian FDA.

**BIOTEK**<sup>®</sup>  
we put life in metal

### BIOTEK - Chetan Meditech Pvt. Ltd.

Opp. V. S. Hospital, Ellisbridge, Ahmedabad 380 006. Gujarat, INDIA.  
Phone: +91 79 2657 8092, 40098394, 79 2657 7639  
Email: info@biotekortho.com Website: www.biotekortho.com



# ACTIVE DEPLOYMENT UP TO 6X LESS DISPLACEMENT<sup>1</sup>

Compared to other all-suture anchors



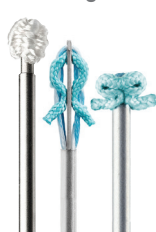**References** 1. Douglass NP, Behn AW, Safran MR. Cyclic and Load to Failure Properties of All-Suture Anchors in Synthetic Acetabular and Glenoid Cancellous Bone. *Arthroscopy*. 2017 May;33(5):977-985.e5. doi: 10.1016/j.arthro.2016.11.022. Epub 2017 Jan 26. 2. Data on file. Report P/N 49190-01 Rev. B. 3. Erickson J, Chiarappa F, Haskel J, Rice J, Hyatt A, Monica J, Dhawan A. Biomechanical Comparison of a First- and a Second-Generation All-Soft Suture Glenoid Anchor. *The Orthopaedic Journal of Sports Medicine*, 5(7) 1-7, 2017. 4. Data on file. Report 15002117 Rev. A. 5. Data on file. Report P/N 49193-02 Rev. A. 6. Data on file. Report P/N 51963-01 Rev. A. 7. Barber FA, Herbert MA. All-Suture Anchors: Biomechanical Analysis of Pullout Strength, Displacement, and Failure Mode. *Arthroscopy*. 2017 Jun;33 (6):1113-1121. doi: 10.1016/j.arthro.2016.09.031. Epub 2016 Dec 22.



Active deployment



High fixation strength<sup>5,6,7</sup>



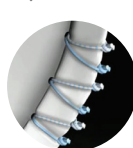Curved drill guides



Available in multiple sizes



Double-loaded options



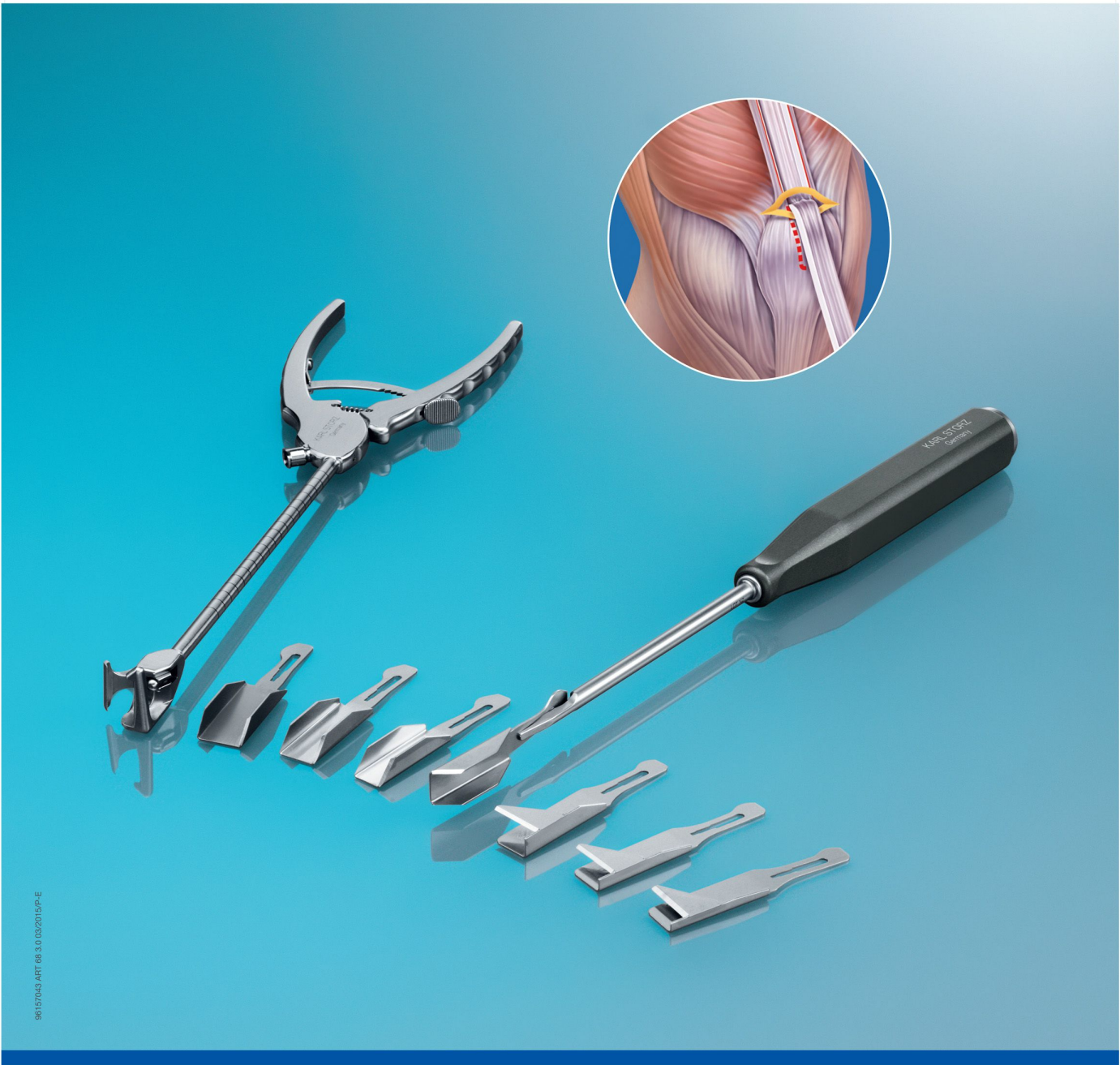
## SUTUREFIX and Q-FIX<sup>®</sup> All-Suture Anchors

Active Deployment delivery systems confirm successful deployment with audible and tactile cues.<sup>3,4</sup> They also provide the least displacement,<sup>1-3</sup> compared to other all-suture anchors. [Learn more at all-suture.com](http://all-suture.com).

Perform without compromise



Supporting healthcare professionals for over 150 years



96157043 ART 68 3.0.02/2016-PE

# QuadCut

Minimally Invasive Quadriceps Tendon Harvesting

**STORZ**  
KARL STORZ – ENDOSKOPE  
THE DIAMOND STANDARD

[www.karlstorz.com](http://www.karlstorz.com)





# Journal of Arthroscopy and Joint Surgery

An official publication of International Society for Knowledge for Surgeons on Arthroscopy and Arthroplasty

(ISSN: 2542-6001)

Volume 6, Number 1, January–April 2019

## Aims and Scope

*Journal of Arthroscopy and Joint Surgery* (JAJS) is committed to bring forth scientific manuscripts in the form of original research articles, current concept reviews, meta-analyses, case reports and letters to the editor. The focus of the Journal is to present wide-ranging, multi-disciplinary perspectives on the problems of the joints that are amenable with Arthroscopy and Arthroplasty. Though Arthroscopy and Arthroplasty entail surgical procedures, the Journal shall not restrict itself to these purely surgical procedures and will also encompass pharmacological, rehabilitative and physical measures that can prevent or postpone the execution of a surgical procedure. The Journal will also publish scientific research related to tissues other than joints that would ultimately have an effect on the joint function.

## Author inquiries

You can track your submitted article at <http://www.elsevier.com/track-submission>. You can track your accepted article at <http://www.elsevier.com/trackarticle>. You are also welcome to contact Customer Support via <http://support.elsevier.com>

## Copyright

© 2019, International Society for Knowledge for Surgeons on Arthroscopy and Arthroplasty. Published by Reed Elsevier India Pvt. Ltd. All rights reserved. Papers accepted for publication become the copyright of *International Society for Knowledge for Surgeons on Arthroscopy and Arthroplasty*, and authors will be asked to sign a transfer of copyright form, on receipt of the accepted manuscript by Elsevier. This enables the Publisher to administer copyright on behalf of the Authors, whilst allowing the continued use of the material by the Author for scholarly communication.

**This journal and the individual contributions contained in it are protected under copyright by Elsevier Ltd., and the following terms and conditions apply to their use:**

## Photocopying

Single photocopies of single articles may be made for personal use as allowed by national copyright laws. Permission of the Publisher and payment of a fee is required for all other photocopying, including multiple or systematic copying, copying for advertising or promotional purposes, resale, and all forms of document delivery. Special rates are available for educational institutions that wish to make photocopies for non-profit educational classroom use. For information on how to seek permission visit <http://www.elsevier.com/permissions> or call: (+44) 1865 843830 (UK) / (+1) 215 239 3804 (USA).

## Derivative Works

Subscribers may reproduce table of contents or prepare lists of articles including abstracts for internal circulation within their institutions. Permission of the Publisher is required for resale or distribution outside the institution. Permission of the Publisher is required for all other derivative works, including compilations and translations (please consult [www.elsevier.com/permissions](http://www.elsevier.com/permissions)).

## Electronic Storage or Usage

Permission of the Publisher is required to store or use electronically any material contained in this journal, including any article or part of an article (please consult [www.elsevier.com/permissions](http://www.elsevier.com/permissions)).

Except as outlined above, no part of this publication may be reproduced, stored in a retrieval system or transmitted in any form or by any means, electronic, mechanical, photocopying, recording or otherwise, without prior written permission of the Publisher.

## Notice

No responsibility is assumed by the Publisher for any injury and/or damage to persons or property as a matter of products liability, negligence or otherwise, or from any use or operation of any methods, products, instructions or ideas contained in the material herein. Because of rapid advances in the medical sciences, in particular, independent verification of diagnoses and drug dosages should be made.

Although all advertising material is expected to conform to ethical (medical) standards, inclusion in this publication does not constitute a guarantee or endorsement of the quality or value of such product or of the claims made of it by its manufacturer.

## Subscription information

The *Journal of Arthroscopy and Joint Surgery* (ISSN: 2542-6001) is published thrice a year. The annual price for **individual subscription** based in India is **INR 3600**; and for international subscribers, the annual price is **USD 60**. For **institutional subscription** within and outside India, please contact the Publishers office at [journals.india@elsevier.com](mailto:journals.india@elsevier.com).

Further information is available on this journal and other Elsevier products through Elsevier's website (<http://www.elsevier.com>). Subscriptions are accepted on a prepaid basis only and are entered on a calendar year basis. Issues are sent by standard mail. Priority rates are available upon request. Claims for missing issues should be made within six months of the date of dispatch.

**Orders, claims, advertisement and journal inquiries:** Please visit our Support Hub page <https://service.elsevier.com> for assistance.

**Editorial Office:** Dr Pushpinder Singh Bajaj, Bajaj Specialist Clinics, B-7/5 Safdarjung Enclave, New Delhi – 110029. Tel: 41057555 / 41057556 / 41057557. Email: [psbajaj@hotmail.com](mailto:psbajaj@hotmail.com).

**Publishing Office:** Elsevier, A division of Reed Elsevier India Pvt. Ltd., 14th Floor, Building No.10B, DLF Cyber City, Phase-II, Gurgaon-122002, Haryana, India. Email: [journals.india@elsevier.com](mailto:journals.india@elsevier.com)





# Journal of Arthroscopy and Joint Surgery

An official publication of International Society for Knowledge for Surgeons on Arthroscopy and Arthroplasty

(ISSN: 2542-6001)

Volume 6, Number 1, January–April 2019

MR SANJEEV ANAND UK

## Executive Editors

PROF LALIT MAINI Delhi  
PROF RAVI GUPTA Chandigarh

## Editors-in-Chief

DR AMOL TAMBE UK

## Managing Editor

DR PUSHPINDER BAJAJ Delhi

PROF HEMANT PANDIT UK

## Deputy Editor

MR KAPIL KUMAR UK

## Section Editors

### Trauma & Rehabilitation

DR ALEXANDER WOOD UK

### Hip

DR AJAY AGGARWAL USA

### Foot & Ankle

DR MUNEESH BHATIA UK

### Training & Education

DR JANAK MEHTA Australia

### Arthroplasty

DR MANOJ SOOD UK

### Pediatric Orthopaedics

DR PARMANAND GUPTA

### Orthopaedic Oncology

DR MANISH PARUTHI

### Elbow, Wrist & Hand

DR RAJ MURALI UK

### Shoulder

DR MANIT ARORA Mohali

## Associate Editors

DR DINESH PATEL USA  
DR PONKY FIRER South Africa

PROF JEGAN KRISHNAN Australia  
DR GURINDER BEDI Delhi

DR RAJESH SETHI UK  
DR DINSHAW PARDIWALA Maharashtra

## Editorial Board

PROF GIANNOUDIS UK  
PROF AMAR RANGAN UK  
DR KHALID MOHAMMAD New Zealand  
DR MAKARAM SRINIVASAN UK  
DR V BHALAIK UK

DR PUNEET MONGA UK  
DR TAOFEK ADEYEMI Nigeria  
DR M S DHILLON Chandigarh  
DR VIVEK PANDEY Karnataka  
DR SUNDARARAJAN Tamil Nadu

DR ASHISH DEVGAN Haryana  
DR RAJU EASWARAN Delhi  
DR RAHUL KHARE Delhi  
DR AMITE PANKAJ Delhi

## Advisory Board

DR ANDREAS SETTJE Germany  
DR ANANT JOSHI Maharashtra  
DR ASHOK RAJGOPAL Delhi  
DR ASHISH BABULKAR Pune  
DR ASIT SHAH USA  
DR ANIL BHAT Karnataka  
MR BINOD SINGH UK  
DR BINU THOMAS Tamil Nadu  
DR DAVID MARTIN Australia  
DR DAVID RAJAN Tamil Nadu  
DR DENNY LIE Singapore  
DR EDWARD T MAH Australia  
DR GRAHAM MERCER Australia  
DR H K WONG Hong Kong

DR HIROYUKI SUGAYA Japan  
DR HITESH GOPALAN Karnataka  
PROF J E MENDES Portugal  
DR JAAP WILLEMS Netherlands  
DR JOHN EBNEZAR Karnataka  
DR JVS VIDYASAGAR Andhra Pradesh  
PROF LENNARD FUNK UK  
DR MARIO PENTA Australia  
DR NICK WALLWORK Australia  
DR NIRBHAY SHAH Gujarat  
DR PAOLO PALADINI Italy  
DR PARAG SANCHETI Pune  
DR PETER CAMPBELL Australia  
PROF P P KOTWAL Delhi

PROF RAJASEKARAN Tamil Nadu  
MR RAM VENKATESH UK  
MR R PANDEY UK  
PROF RAJ BAHADUR Chandigarh  
MR ROBERT J GREGORY UK  
DR ROHIT ARORA Austria  
DR SACHIN TAPASVI Pune  
DR SANJAY DESAI Maharashtra  
DR SANJAY GARUDE Maharashtra  
DR SANJAY TRIVEDI Gujarat  
DR SRIPATHI RAO Karnataka  
PROF SUDHIR KAPOOR Delhi  
MR VED GOSWAMI UK  
DR YOUNG LAE MOON Korea

Copyright (C) 2019, International Society for Knowledge for Surgeons on Arthroscopy and Arthroplasty. All rights reserved.

Published by Reed Elsevier India Pvt. Ltd.

No part of the publication may be transmitted in any form or by any means, electronic or mechanical, without written permission from the Editor-in-Chief.

*Disclaimer: Although all advertising material is expected to conform to ethical (medical) standards, inclusion in the publication does not constitute a guarantee or endorsement of the quality or value of such product or of the claims made of it by its manufacturer. Please consult full prescribing information before issuing prescriptions for any products mentioned in this publication.*

Printed at EIH Limited-Unit Printing Press, IMT Manesar, Gurgaon







# Journal of Arthroscopy and Joint Surgery

An official publication of International Society for Knowledge for Surgeons on Arthroscopy and Arthroplasty

(ISSN: 2542-6001)

Volume 6, Number 1, January–April 2019

## Table of Contents

### Editorial

Stephen Copeland, a personal tribute  
*Cormac Kelly* 1

### Shoulder

The remplissage technique  
*Ram Chidambaram* 3

Management of glenohumeral arthritis in the young patient – A systematic review  
*Robert W. Jordan, Cormac P. Kelly* 9

The management of glenoid bone loss in shoulder arthroplasty  
*Steven Kyriacou, Sirat Khan, Mark Falworth* 21

Two portal technique with antegrade suture passer and knotless anchors for Arthroscopic Bankart repair: A technical note  
*Joong-Bae Seo, Kang Heo, Jong-Heon Yang, Jae-Sung Yoo* 31

Physiotherapy treatment for atraumatic recurrent shoulder instability: Updated results of the Derby Shoulder Instability Rehabilitation Programme  
*Marcus Bateman, Sally E. Osborne, Benjamin E. Smith* 35

### Elbow & Hand

Avoiding complications in elbow arthroscopy  
*William D. Harrison, Xenia Tonge, Vijay Bhalai* 42

Bipolar radial head arthroplasty for management of radial head fractures  
*B. Hari Krishnan, Tej Pratap Gupta* 48

Medical management of wrist and hand inflammatory conditions: A literature review  
*Meenakshi Jolly, Asha Patnaik, Courtney O'Brien, Anupam Basu, Augustine Manadan* 53

### Lower Limb

A comparative study on functional outcome of ACL reconstruction: Quadriceps versus hamstring tendon autograft  
*Sandeep Yadav Tirupathi, Divyanshu Goyal, Vidyasagar Jvs* 61

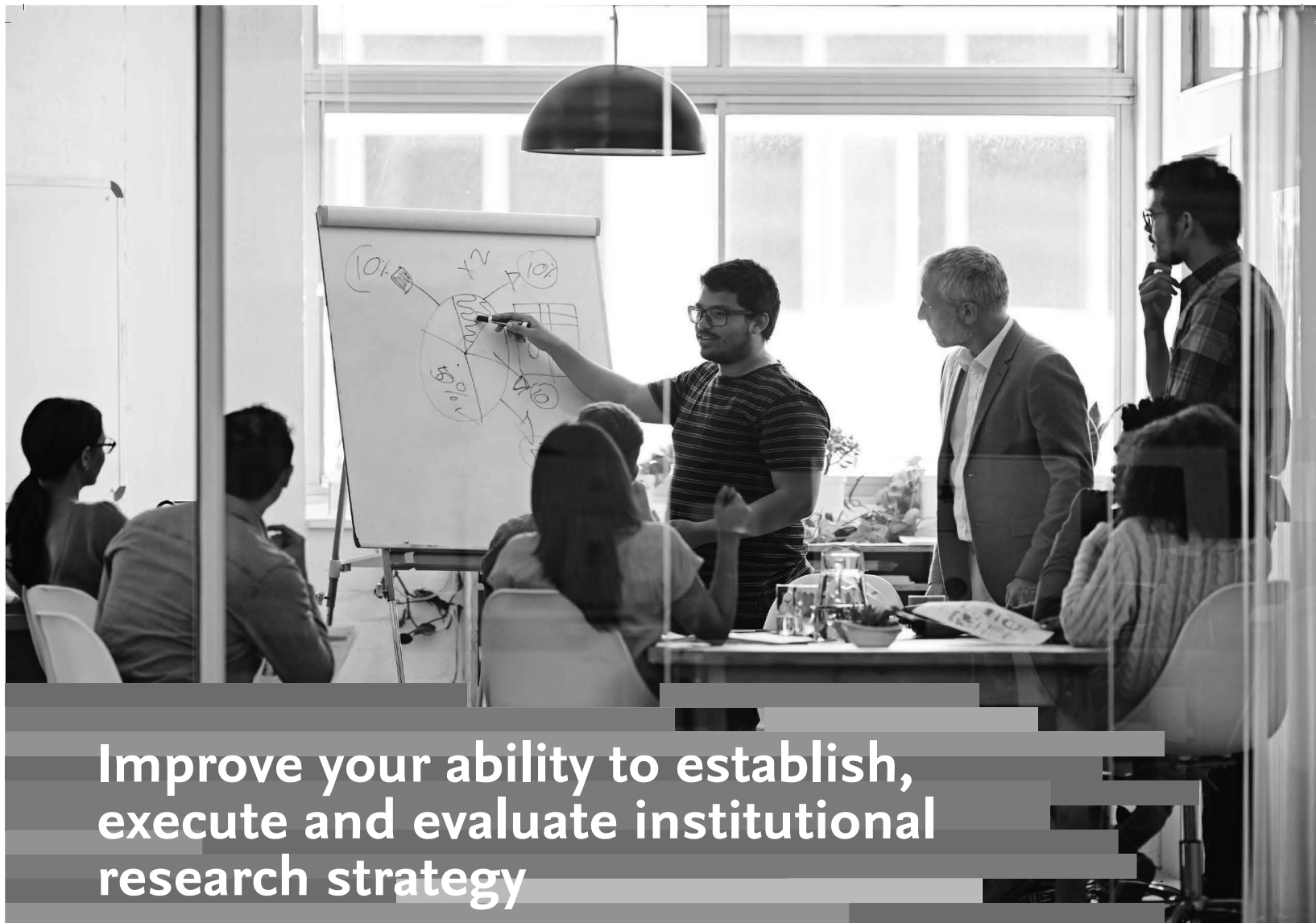Functional outcome of patellar resurfacing vs non resurfacing in Total Knee Arthroplasty in elderly: A prospective five year follow-up study  
*Lokesh Chawla, Shivanand M. Bandekar, Vivek Dixit, Ambareesh P, Arun Krishnamoorthi, Sushanth Mummigatti* 65

A prospective comparative study between intravenous and intraarticular tranexamic acid administration in decreasing the perioperative blood loss in total knee arthroplasty  
*Nitin Mehta, Naman Goel, Ankit Goyal, Deepak Joshi, Deepak Chaudhary* 70

A novel method for protecting the inter-menisal ligament during anterior cruciate ligament reconstruction  
*David R.W. MacDonald, Iain Stevenson* 74

Arthroscopy assisted steida process excision in a case of posterior ankle impingement  
*Clement Joseph, Shiva Reddy, Arjun Ballal* 76





# Improve your ability to establish, execute and evaluate institutional research strategy

Elsevier's Research Intelligence solutions provides answers to the most pressing challenges that research administrators face. Our suite of innovative software solutions improves your ability to establish, execute and evaluate research strategy and performance.

## Scopus

Track, analyze and visualize global research with our abstract and citation database of peer-reviewed literature, including scientific journals, books and conference proceedings covering the fields of science, technology, medicine, social sciences and arts and humanities.

## Mendeley

Organize your research, collaborate and connect with others online, and discover the latest research with our free reference manager and academic social network. Mendeley Institutional Edition includes premium user features and competency for researchers and librarians.

## SciVal

Visualize your institution's research performance, benchmark relative to peers, develop collaborative partnerships and explore research trends.

## Pure

Develop reports on research output, carry out performance assessments, and showcase your researchers' expertise, all while reducing administrative burden for researchers, faculty and staff.

For a FREE custom report on your institution's research strengths, visit: [elsevier.com/research-intelligence/ace](http://elsevier.com/research-intelligence/ace)





## Editorial

## Stephen Copeland, a personal tribute



Much has been written about Steve, the inventor, the Master shoulder surgeon, the teacher and most importantly the well respected and loved colleague, friend and family man.<sup>1–3</sup> I met Steve in 1993 at the Reading Shoulder Course after hearing he was considering setting up a shoulder Fellowship.

In July 1994 I arrived in Reading with my wife Ann and started with a trip to the Henley Boat regatta with Steve, Jenny, family and friends. Bought an appropriate striped jacket in Marks and Spencer's arriving by Range Rover to the members enclosure for drinks and fun. I remember well jumping from one wobbly boat to another (with drink) watching the fabulous fireworks at night. What a start to my Fellowship...

Steve enjoyed the mindless banter during surgery yet managed to get through 2 shoulder replacements, a couple of decompressions and maybe a small Paediatric case all on a morning list! His hands moved effortlessly, and the surgical exposure was an anatomy lesson in itself. He remained calm even when others (yes me too) lost their heads in the inefficiency that was the NHS. His patients loved him and always needed to know he was close at hand.

He entertained many visitors with enthusiasm and grace and just like his Fellows they left with a yearning to try and mimic the good surgical practice that Steve had developed over many years. Steve liked innovation and was always keen to know what was happening in the world of shoulder surgery. So after some research and discussion we together in Reading performed the first laser assisted arthroscopic capsular shift in the UK (as far as I know). His main interest as we know was in shoulder surface replacement and his prosthesis took off after several positive publications on its outcome. It had exponential growth and sales in the US despite the fact that prosthesis had a different coating when marketed in the States!! In recent years the prosthesis has fallen out of favour and many surgeons have now moved to "stemless" implants or short stems however we must remember the principles were established by Steve in the late 1980s. Also the ease of revision has made it possible for surgeons to achieve better outcomes with second surgery.

Ann and I regret not keeping closer contact with Steve and Jenny over the years as time, family commitment and distance prevented



Fig. 1. Bangalore 2004. From left to right: Mahesh Reddy, VJ Purushotham, Dr Manoj, Steve Copeland, Dr Nanjundappa, BN Muddu.

especially during the latter months of his life. Like many ex Reading Fellows, I often pause and think when faced with difficult surgical challenges ... ..“I wonder what Steve would do in this situation”.

I welcome the introduction of the Copeland Travelling Fellowship by the British Elbow and Shoulder Society (BESS) and delighted that the committee chose me to be part of the upcoming exciting trip to India in the Spring of 2019. I think Steve would have liked to come with us but I have no doubt his spirit of enquiry, friendship and education will be with us all the way. We know that Steve travelled to India on at least 3 occasions and really enjoyed the unique experience of that country. I thank Jenny for the photo and Kapil Kumar for helping to identify the smart group of Indian surgeons on his visit to Bangalore in 2004 (Fig. 1).

#### Conflicts of interest

Mr Kelly has a consultancy with Mathys.

#### References

1. Wallace WA, Thomas M. Stephen Andrew Copeland FRCS, FRCSEd the Master shoulder surgeon (1946-2015). *Shoulder Elbow*. 2015;7(3):151–152.
2. Levy O. Copeland, Stephen Andrew (1946 - 2015). In: *Memoriam. The Royal College of Surgeons of England, Plarr's Lives of the Fellows*. 2015.
3. Wallace A. Stephen Andrew Copeland , 17th May 1946 – 10th April 2015. *J Trauma Orthop*. 2015;3(3):69.

Cormac Kelly, Consultant Upper Limb Surgeon  
Robert Jones and Agnes Hunt Orthopaedic Hospital, Gobowen,  
Oswestry, SY10 7AG, UK  
E-mail address: [Cormac.kelly@nhs.net](mailto:Cormac.kelly@nhs.net).

13 December 2018  
Available online 1 February 2019



## The remplissage technique

Ram Chidambaram <sup>1</sup>

MIOT Centre of Sports Medicine, Shoulder and Upper Limb Surgery, MIOT International Hospitals, Chennai, 600089, Tamil Nadu, India



### ARTICLE INFO

#### Article history:

Received 27 May 2018

Received in revised form

16 September 2018

Accepted 6 January 2019

Available online 7 January 2019

#### Keywords:

Remplissage

Hill-Sachs lesion

Recurrent shoulder dislocation

Shoulder instability

### ABSTRACT

Remplissage is the procedure of filling the Hill-Sachs lesion of the humeral head with the infraspinatus tendon and posterior capsule. This is indicated as adjuvant procedure to Bankart repair in patients with recurrent dislocation of shoulder with large, engaging or off-track Hill-Sachs lesion. This helps to convert the intra articular lesion to an extra-articular one. Arthroscopic remplissage technique was originally described in 2008. Various modifications have been described since then. Over the last decade, case series and comparative studies have shown excellent results in terms of reducing recurrence rates and improving functional outcome. They have been reported with minimal or no complications. This article describes the technical aspects of performing remplissage and the author's preferred way of doing it.

© 2019 Published by Elsevier, a division of RELX India, Pvt. Ltd on behalf of International Society for Knowledge for Surgeons on Arthroscopy and Arthroplasty.

### 1. Hill Sachs defect

Hill and Sachs described the bony defect of the posterolateral humeral head as an unrecognised complication of shoulder dislocation in 1940.<sup>1</sup> The incidence of Hill-Sachs lesion increases with an increase in number of dislocations ranging from 65% to 67% after the initial dislocation and from 84% to 93% after recurrent dislocations.<sup>2,3</sup>

X-rays are not reliable for the assessment of Hill-Sachs lesion, though Anteroposterior view with arm in internal rotation may reveal the defect if it is significant. Sagittal and axial CT images are useful and reproducible in measuring the size of the Hill-Sachs lesion. 3D CT gives a much more impactful visual interpretation of the extent of the lesion and its relation to the glenoid track.

### 2. Hill- Sachs lesion as risk factor for recurrence

Humeral side Hill-Sachs defect has been reported to be one of the significant risk factors for recurrence after arthroscopic Bankart repair in patients with recurrent anterior shoulder instability.<sup>4–7</sup> Burkhart and Joe De Beer described 67% recurrence of dislocation in the presence of glenohumeral bone defect compared to 4% when there is no bony defect in their case series of arthroscopic Bankart repair.<sup>4</sup>

Whether the Hill-Sachs lesion engages with the glenoid depends on the size and location of the Hill-Sachs lesion relative to the width of the glenoid. Although the engaging Hill-Sachs lesion has been recognized as a risk factor for recurrent anterior instability, there has been no generally accepted method for quantifying the Hill-Sachs lesion.

Itoi et al. described a radiological method of quantifying bipolar bone loss, using the concept of the glenoid track.<sup>8–10</sup> When the shoulder is in abduction and external rotation and moves along the end range of motion, the glenoid shifts along the posterior margin of the humeral head. This contact zone of the glenoid created on the humeral head along the end range of motion is called the 'glenoid track'. A Hill-Sachs lesion that is located more medially than the medial margin of the glenoid track is defined as an off track Hill-Sachs lesion.

Di Giacomina et al. have described this measurement as follows<sup>10,11</sup>: First Glenoid Track (GT) is calculated. The diameter of the inferior glenoid (D) is measured, from 3DCT scan en face view of contralateral glenoid. 83% of this normal glenoid width is taken and the width of glenoid bone loss (d) from affected side is subtracted from this value to give the width of glenoid track ( $GT = 0.83 D - d$ ). Next, the Hill-Sachs Interval (HIS) is calculated. The HIS is the distance from the rotator cuff attachments to the medial rim of the Hill-Sachs lesion and is equal to the width of the Hill-Sachs lesion (HS) plus the width of the intact bone bridge (BB) between the rotator cuff and the Hill-Sachs lesion. ( $HIS = HS + BB$ ). If the width of Hill-Sachs Interval is less than the width of Glenoid Track ( $HIS < GT$ ), it is an on track or non-engaging lesion. If the width of

E-mail address: [drramchidambaram@gmail.com](mailto:drramchidambaram@gmail.com).

<sup>1</sup> Present/Permanent address: First Floor, New No 183/Old No 79, TTK Road, Alwarpet, Chennai, 600018, Tamil Nadu, India.

Hill-Sachs Interval is more than the width of Glenoid Track (HIS > GT), it is an off track or engaging lesion. In this group, Di Giacomo and Itoi suggested remplissage or Latarjet procedure, depending on the glenoid defect size and risk of recurrence.

### 3. Ways to address the engaging Hill-Sachs lesion

In presence of large, engaging or off-track Hill-Sachs lesion, there is a high risk of recurrence if one plans to perform only soft tissue labral/capsular repair. Traditionally, several techniques have been described to avoid engagement between the Hill-Sachs lesion and the anterior glenoid rim. This can be achieved by either reducing the range of motion in external rotation or filling the humeral head defect. The former includes anterior soft tissue shortening or rotational osteotomy of the humerus.<sup>6,12</sup> The latter includes filling the lesion with a bone graft or soft tissue.<sup>13</sup>

### 4. Open remplissage

The transfer of the infraspinatus tendon with or without the greater tuberosity has been used to successfully fill defects smaller than 40% of the articular surface. Weber initially described a combined deltopectoral and posterior approach.<sup>14</sup> The posterior deltoid is split to reveal the infraspinatus tendon. For smaller defect <25% of the articular surface, the infraspinatus tendon is dissected off from its attachment, then mobilised and sutured into the Hill-Sachs defect. For larger defects measuring 25–40% of the articular surface, the greater tuberosity can be osteotomized and secured into the defect with screws. Connolly further described an open procedure of infraspinatus tenodesis into the humeral head defect.<sup>15</sup>

### 5. Arthroscopic remplissage: the original technique

Wolf et al. first described the arthroscopic variation of infraspinatus tenodesis, which they termed 'Remplissage'.<sup>16,17</sup> Remplissage is derived from the root verb 'remplir', which translates to 'filling' in French. This is because the humeral head defect was filled with the infraspinatus tendon. Following preparation of the glenoid neck and labrum for Bankart repair, visualization of the bony defect was done through the anterosuperior portal. A bone bed was prepared. Two single loaded suture anchors were placed at the superomedial and inferomedial aspects of the Hill-Sachs lesion through a posterior or posterior accessory portal. Mattress sutures were placed on the infraspinatus and posterior capsule and sutures were tied in a blind fashion in the subdeltoid space. This was followed by anterior labral repair. Postoperatively, the arm was kept immobilized for 6 weeks, succeeded by gradual mobilization.

Arthroscopic remplissage has become very popular with shoulder surgeons in the present era, and various modifications have been described. Many clinical papers have demonstrated an excellent outcome of remplissage combined with Bankart repair with reported recurrence rate between 0 and 15% (See Table 1).<sup>18–31</sup>

No recurrent dislocation was observed in the remplissage group when remplissage with Bankart repair was compared with Bankart repair alone, though no significant difference in Rowe score or UCLA score was revealed among the 2 groups.<sup>22</sup>

Better functional score and lower risk of recurrence have been observed in remplissage combined with arthroscopic Bankart repair when compared with osteochondral substitute grafting for engaging Hill-Sachs lesion.<sup>32</sup>

Regarding the range of motion and return to sports, Boileau et al. reported that the reduction in external rotation after the remplissage was 8° in adduction and 9° in abduction in their series of 42 patients with large engaging Hill-Sachs lesion.<sup>23</sup> In their series, return to sports at the preinjury level was only 68%. Therefore, usage of remplissage in overhead sports athlete with large, engaging or off-track Hill-Sachs lesion should be carefully considered.

Recently, Domos et al. reported their results of remplissage and Bankart repair in 20 high risk collision athletes with non-engaging Hill-Sachs lesion.<sup>30</sup> They reported good outcome, lowered recurrence rate and only a mean difference of external rotation in adduction by 10°. In their series, they reported a 100% return to sports. Therefore, usage of remplissage in collision athletes with small non-engaging Hill-Sachs lesion is recommended, seeing as it improves their ability to return to pre-injury level of sport.

### 6. Indications for arthroscopic remplissage

1. Recurrent shoulder dislocation with large engaging or off-track Hill-Sachs lesion with <25% anterior glenoid bone loss.
2. In revision procedures for failed instability surgery.

### 7. Author's preferred technique

Under general anaesthesia, the patient is placed in lateral decubitus position with arm suspended with 6–8 pounds of distal traction to keep the shoulder at approximately 30 degrees of abduction and 15 degrees of forward flexion.

After sterile preparation and draping, a posterior viewing portal is made 2 cm inferior and 2 cm medial to the posterolateral corner of the acromion in the posterior soft spot. A thorough diagnostic arthroscopy is performed. The glenoid, humeral bone loss and

**Table 1**  
Results of arthroscopic remplissage and technique.

Author	year	Sample No	mean follow/up	number of anchors	knot tying	Recurrence rate
Haviv et al. <sup>18</sup>	2011	11	30 m	1 or 2 anchors	Blind	0%
Zhu et al. <sup>19</sup>	2011	49	29 m	1 or 2 anchors	Subacromial	8.2%
M J Park et al. <sup>20</sup>	2011	20	29 m	1 or 2 double loaded anchors	Blind	15%
Nourissat et al. <sup>21</sup>	2011	15	27 m	2 anchors	subacromial	1/15 failure
Franceschi et al. <sup>22</sup>	2012	25	24 m	1 or 2 double loaded anchors	Blind	0%
Boileau et al. <sup>23</sup>	2012	47	24	2 single loaded anchors	Blind	2%
Sang-Hun Ko et al. <sup>24</sup>	2013	12		two anchors	Blind	
Wolf et al. <sup>25</sup>	2014	45	58 m	2 single loaded anchors	—	4.4%
Garcia et al. <sup>26</sup>	2015	10	40 m		—	20%
Brilake et al. <sup>27</sup>	2016	48	37 m			
Nam Su Cho et al. <sup>28</sup>	2016	37	25 m	1 or 2 double loaded anchors	Blind	6.3%
Morsy et al. <sup>29</sup>	2017	51	31 m	2 double loaded	Blind	5.4%
P Domos et al. <sup>30</sup>	2017	20	26 m	One double loaded anchor	Blind	4%
P Domos et al. <sup>30</sup>	2017	20	26 m	One double loaded anchor	Blind	5%
Bonneyvialle et al. <sup>31</sup>	2017	34	35 m	Two single loaded anchors	Blind	14.7%

labral tear is evaluated. The arm is removed from traction in order to perform a dynamic arthroscopic assessment. Shoulder is moved from neutral to external rotation at 45 and 90 degrees of abduction. If the Hill-Sachs lesion is seen to engage the anterior glenoid rim during this dynamic assessment, the decision is taken to carry out remplissage procedure. Strong indications for remplissage are preoperatively measured off track Hill-Sachs lesions and revision surgery.

Under direct vision and using outside in technique, an antero-inferior portal is made in the apex of the rotator interval, lateral to coracoid and above the subscapularis tendon. This is the primary working portal for repair of anterior labral tear.

A viewing anterosuperior portal is then made at the anterior margin of the acromion using outside in technique, entering the joint immediately behind the biceps tendon.

The arthroscope is then switched to anterosuperior portal. The extent of labral tear, anterior glenoid bone loss, extent and location of Hill-Sachs lesion are assessed.

Now, an accessory posterolateral portal is made about 1.5 cm–2 cm lateral to posterior viewing portal under direct vision using a spinal needle aiming at the centre of Hill-Sachs defect (Fig. 1).

A size 8 mm cannula is inserted through this portal. The surface of Hill-Sachs lesion is denuded of all cartilage using curette, shaver and burr in reverse mode until punctate bleeding is observed. This is an important step which will help in good healing of the capsule (Fig. 2).

Remplissage repair is akin to repair of partial articular surface tear of the rotator cuff, the aim here being fixation of the infraspinatus tendon and adjacent posterior capsule to the abraded surface of the Hill-Sachs lesion.

Number and nature of anchors used depends on the size of Hill-Sachs defect and quality of bone. Author's preference is double loaded anchor. One double loaded anchor is enough for a smaller defect. Two double loaded anchors would be needed for a larger defect (Fig. 5). If 2 anchors are used, the first anchor is placed in the inferior aspect of the Hill-Sachs lesion followed by the second one in the superior aspect. Bio-composite anchors would hold well in good bone. If the bone is weak and soft, 5 mm Titanium cuff anchor is inserted.

The location of the anchor is important. It should be adjacent (usually within 5 mm) from articular cartilage margin of the Hill-Sachs defect. This is in order to achieve the tenodesis effect. If it

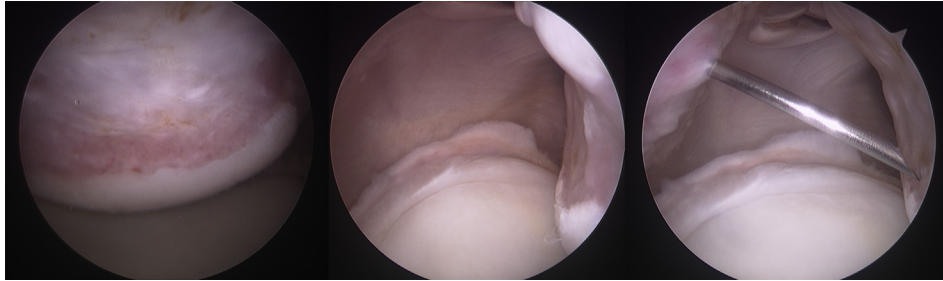


Fig. 1. Hill Sach as viewed from posterior portal & anterosuperior portal. Needle points the direction of posterolateral portal.

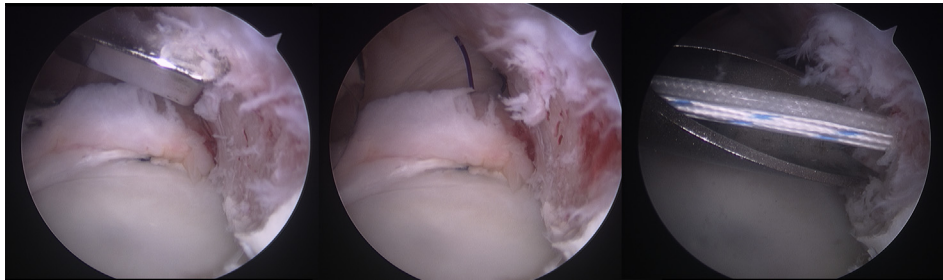


Fig. 2. Preparation of Hill Sach lesion and insertion of anchor.

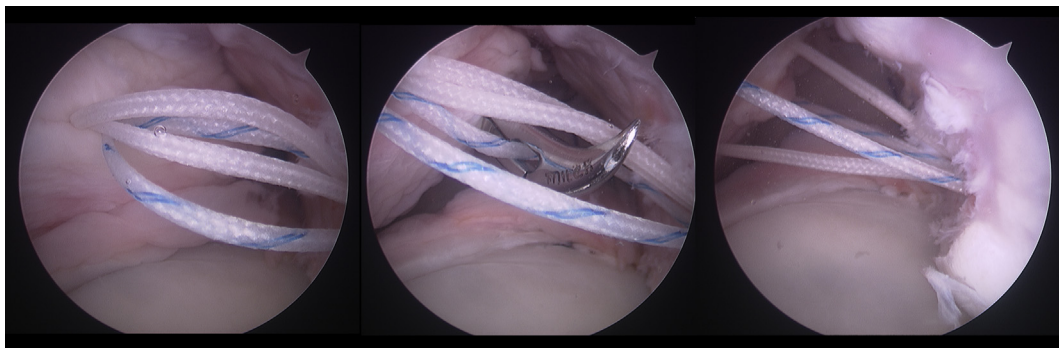


Fig. 3. Part withdrawal of cannula and placement of sutures.

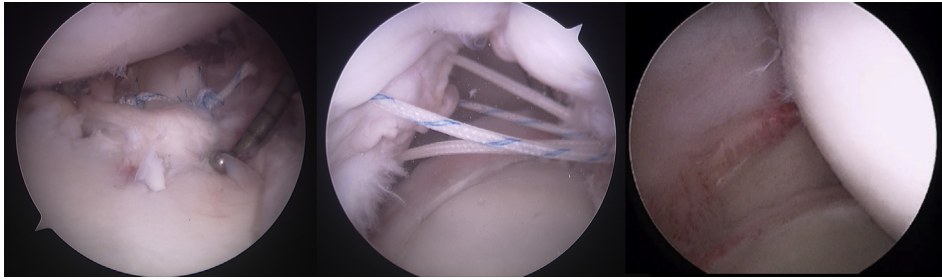


Fig. 4. Labral repair and Hill Sach Remplissage completed.

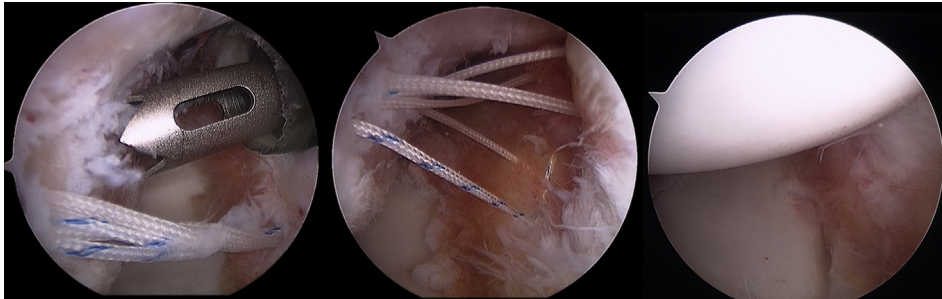


Fig. 5. Hill Sach repair with two double loaded anchors.

is located away from the articular margin, it is not likely to achieve the remplissage effect of tenodesis. If it is done too medial, it may cause limitation of internal rotation of humeral head. Attention should be taken to direct the anchor away from the articular surface to avoid joint penetration.

The cannula is now withdrawn in gradual fashion so that it lies just outside the capsule and infraspinatus muscle. At this level, a penetrating type of suture grasper is utilized to pierce just the infraspinatus muscle and posterior capsule in appropriate points to achieve cross or box mattress configuration using the two pre-loaded sutures (Fig. 3). Care should be taken to avoid taking bite into the muscular portion of infraspinatus as it may cause posterior shoulder pain.

If two anchors are used, the sutures from the inferior anchor is taken first. All sutures are placed in this fashion and left untied.

Through anteroinferior working portal, anterior labral repair is completed from inferior to superior direction with two to three all-suture or labral PEEK/Biocomposite anchors achieving inferior

capsular shift and recreating bumper effect of labrum.

Finally, the remplissage sutures are tied consecutively with the viewing scope still in anterosuperior portal providing an excellent view of the soft tissue reduction to Hill-Sachs defect (Fig. 4). Sutures are tied in a blind fashion over the infraspinatus muscle in the subdeltoid space using sliding knot. These sutures can also be visualised in the subacromial space and tied under direct vision. However, the author does not think it necessary as far as the cannula tip is correctly placed in the sub-deltoid level.

This procedure will convert the intra-articular Hill-Sachs lesion to stay extra-articular and also keep the humeral head centred over the glenoid (Fig. 6).

## 8. Post-operative rehabilitation

In author's practise, postoperative regime is similar to arthroscopic Bankart repair alone. Cold compression therapy is given for the first twelve hours. Active elbow and hand movements are

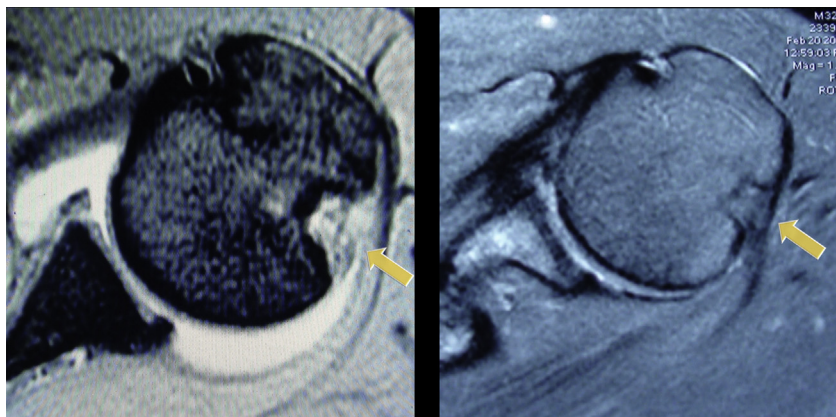


Fig. 6. MRI before and after remplissage.



started. From the second postoperative day, patient will start mobilizing the shoulder. These exercises include shoulder shrug, shoulder roll, pendulum movements and assisted arm elevation exercises up to 90°. Arm is rested in sling for four weeks.

From four weeks onwards, active assisted range of movement is begun, gradually progressing to full ROM. At the end of two months, shoulder muscle strengthening exercises are permitted. Patient is allowed to start sports training from six months onwards and full participation is allowed at 9 months to one year.

## 9. Order of remplissage and labral repair

There are two ways of remplissage. This is based on whether the surgeon decides to do remplissage from the start of the case.

If remplissage is decided early on, the best way is to place the remplissage anchor and sutures first and then tie at the end, after labral repair.

The steps are:

1. Diagnostic arthroscopy
2. Insertion of remplissage anchor in the appropriate location on the Hill-Sachs lesion.
3. Placement of the sutures in posterior capsule/infraspinatus tendon, but without tying them.
4. Completion of the anterior labral repair with 2–3 anchors, achieving inferior shift.
5. Tying the sutures of the remplissage.

There are some advantages with this technique. Clear visualization of Hill-Sachs defect and placement of anchor in the appropriate site on the humeral head. Also, more space is available to pass instruments to place the sutures in the appropriate points on the infraspinatus and capsule. In contrast, repairing the anterior labrum and re-tensioning of anterior capsule will tend to shift the humeral head backwards, thereby reducing 'working space' to perform remplissage posteriorly.

Remplissage anchor and sutures are placed, but left untied. If tied, it can result in less humeral head translation, thereby hampering access to anteroinferior labrum and IGHL. With remplissage sutures left untied, complete repair of the anterior labrum with its inferior shift is technically easy. Once the anterior labral repair is completed, it will automatically reduce the soft tissue to Hill-Sachs lesion.

In a case of borderline Hill-Sachs lesion, some surgeons may prefer to complete the anterior labral repair first and then take the arm into external rotation in abduction to check whether the Hill-Sachs lesion is engaging. If engaged, then one can proceed with remplissage. There is a small risk of damage to labral repair with this approach, as the repair is put to test immediately. Secondly, there is little working space for the insertion of remplissage anchors and sutures after anterior labral repair. Thirdly, forceful pushing and manipulation of the shoulder while inserting the Hill-Sachs suture anchor can disrupt the capsulolabral repair.

## 10. Two ways of knot tying

In remplissage knot tying, one should avoid catching any deltoid muscle fibres. This can cause pain on mobilization. There are two ways of achieving this.

### 10.1. Blind tying at subdeltoid level with intra articular view

Here, an accessory posterolateral portal is made and cannula is used to place the anchor and sutures. The cannula is withdrawn just enough to place the cannula tip outside the rotator cuff under the

deltoid, and the sutures are tied using sliding knots in a blind fashion.

Advantage: quick procedure, as this is done under intra-articular view from anterosuperior portal itself. No time is wasted in sub-acromial dissection to find the sutures.

Disadvantage: Chance of catching deltoid fibres if cannula is withdrawn more than the required level of depth.

### 10.2. Subacromial scopy and tying knots under vision

Remplissage anchors and sutures are placed. Labral repair is completed. The arthroscope is then placed in the subacromial space. The sutures are retrieved after clearing the subacromial space and then tied over the infraspinatus tendon under direct vision.

Advantage: Sutures tied under direct vision, so there is no chance of catching any deltoid fibres.

Disadvantage: Takes up additional time during surgery and added difficulty in locating the sutures in the subacromial space.

Another technique called 'Double Pulley' remplissage was described by Koo et al. where the sutures were tied sub-acromially.<sup>33</sup> Here, the subacromial space is cleared first. Through intra articular view, two trans-tendon suture anchors are placed in the Hill-Sachs lesion. Next, the previously placed Bankart repair sutures are tied, and finally the remplissage sutures are tied in the subacromial space over the infraspinatus by using the trans-tendon double-pulley technique. This technique uses the eyelets of the 2 suture anchors as pulleys and creates a double-mattress suture. The authors claimed a large footprint of fixation and direct visualization of knots in subacromial space as its advantages.

## 11. Advantages of arthroscopic Hill-Sachs remplissage

1. Simple arthroscopic technique, takes a little extra time to Bankart repair.
2. Local tissue advancement to fill in the Hill-Sachs defect, converting its location from intra articular to extra articular.
3. Keeps the humeral head centred over the glenoid, supports the anterior labral repair.
4. No significant loss of movement. Less than 10° difference in external rotation is hardly noticeable and hence has no impact on function.
5. No other significant complication has been reported.
6. Reduced recurrence rate following remplissage combined with Bankart repair when compared to arthroscopic Bankart repair alone.
7. Better functional score and lower risk of recurrence when compared with osteochondral substitute grafting

## 12. Disadvantages

Some patients may describe posterior shoulder pain due to capsular tenodesis, especially when the arm is taken into terminal external rotation. Care should be taken to avoid taking bite at the muscular portion of infraspinatus and catching any deltoid muscle fibres during knot tying.

## 13. Conclusions

Remplissage - the filling of the Hill-Sachs defect with infraspinatus and posterior capsule - is a reliable safe adjunct procedure to arthroscopic Bankart repair in cases of recurrent shoulder dislocation with large, engaging or off-track Hill-Sachs lesion and in revision instability surgery. It reduces the overall recurrence rate

and improves the functional outcome with excellently reported short to mid-term results.

## References

- Hill HA, Sachs MD. The grooved defect of the humeral head. A frequently unrecognized complication of dislocations of the shoulder joint. *Radiology*. 1940;35:690–700.
- Spatschil A, Landsiedl F, Anderl W, et al. Posttraumatic anterior-inferior instability of the shoulder: arthroscopic findings and clinical correlations. *Arch Orthop Trauma Surg*. 2006;126(4):217–222.
- Yiannakopoulos CK, Mataragas E, Antonogiannakis E. A comparison of the spectrum of intra-articular lesions in acute and chronic anterior shoulder instability. *Arthroscopy*. 2007;23(9):985–990.
- Burkhart SS, De Beer JF. Traumatic glenohumeral bone defects and their relationship to failure of arthroscopic Bankart repairs: significance of the inverted-pear glenoid and the humeral engaging Hill-Sachs lesion. *Arthroscopy*. 2000 Oct;16(7):677–694.
- Boileau P, Villalba M, Héry JY, Balg F, Ahrens P, Neyton L. Risk factors for recurrence of shoulder instability after arthroscopic Bankart repair. *J Bone Joint Surg Am*. 2006 Aug;88(8):1755–1763.
- Shibata H, Gotoh M1, Mitsui Y, et al. Risk factors for shoulder re-dislocation after arthroscopic Bankart repair. *J Orthop Surg Res*. 2014 Jul 4;9:53.
- Lee SH, Lim KH, Kim JW. Risk factors for recurrence of anterior-inferior instability of the shoulder after arthroscopic Bankart repair in patients younger than 30 years. *Arthroscopy*. 2018 Sep;34(9):2530–2536. <https://doi.org/10.1016/j.arthro.2018.03.032>.
- Yamamoto N, Itoi E, Abe H, et al. Contact between the glenoid and the humeral head in abduction, external rotation and horizontal extension: a new concept of glenoid track. *J Shoulder Elbow Surg*. 2007;16:649–656.
- Itoi E1, Yamamoto N, Kurokawa D, Sano H. Bone loss in anterior instability. *Curr Rev Musculoskelet Med*. 2013 Mar;6(1):88–94.
- Di Giacomo G, Itoi E, Burkhart SS. Evolving concept of bipolar bone loss and the Hill-Sachs lesion: from "engaging/non-engaging" lesion to "on-track/off-track" lesion. *Arthroscopy*. 2014 Jan;30(1):90–98.
- Di Giacomo G, De Vita A, Costantini A, de Gasperis N, Scarso P. Management of humeral head deficiencies and glenoid track. *Curr Rev Musculoskelet Med*. 2014 Mar;7(1):6–11. <https://doi.org/10.1007/s12178-013-9194-7>.
- Weber BG, Simpson LA, Hardegger F. Rotational humeral osteotomy for recurrent anterior dislocation of the shoulder associated with a large Hill-Sachs lesion. *J Bone Joint Surg*. 1984;66:1443–1450.
- Miniaci A, Berlet G. Recurrent anterior instability following failed surgical repair: allograft reconstruction of large humeral head defects. *J Bone Joint Surg Br*. 2001;83(Suppl 1):19–20.
- Weber BG. Operative treatment for recurrent dislocation of the shoulder. Preliminary report. *Injury*. 1969;1(2):107–109.
- Connolly JF. Humeral head defects associated with shoulder dislocation—their diagnostic and surgical significance. *Instr Course Lect*. 1972;21:42–54.
- Wolf EM, Arianjam A. Hill-Sachs remplissage, an arthroscopic solution for the engaging Hill-Sachs lesion: 2- to 10-year follow-up and incidence of recurrence. *J Shoulder Elbow Surg*. 2014 Jun;23(6):814–820.
- Purchase RJ, Wolf EM, Hobgood ER, Pollock ME, Smalley CC. Hill-Sachs "remplissage": an arthroscopic solution for the engaging hill-sachs lesion. *Arthroscopy*. 2008;24:723–726.
- Haviv B, Mayo L, Biggs D. Outcomes of arthroscopic "remplissage": capsule tenodesis of the engaging large Hill-Sachs lesion. *J Orthop Surg Res*. 2011;6:29.
- Zhu YM, Lu Y, Zhang J, Shen JW, Jiang CY. Arthroscopic Bankart repair combined with remplissage technique for the treatment of anterior shoulder instability with engaging Hill-Sachs lesion: a report of 49 cases with a minimum 2-year follow-up. *Am J Sports Med*. 2011;39:1640–1647.
- Park MJ, Tjoumakaris FP, Garcia G, Patel A, Kelly 4th JD. Arthroscopic remplissage with Bankart repair for the treatment of glenohumeral instability with Hill-Sachs defects. *Arthroscopy*. 2011 Sep;27(9):1187–1194. <https://doi.org/10.1016/j.arthro.2011.05.010>. Epub 2011 Aug 6.
- Nourissat G, Kilinc AS, Werther JR, Doursounian L. A prospective, comparative, radiological, and clinical study of the influence of the "remplissage" procedure on shoulder range of motion after stabilization by arthroscopic Bankart repair. *Am J Sports Med*. 2011;39(10):2147–2152.
- Franceschi F, Papalia R, Rizzello G, et al. Remplissage repair—new frontiers in the prevention of recurrent shoulder instability: a 2-year follow-up comparative study. *Am J Sports Med*. 2012;40:2462–2469.
- Boileau P, O'Shea K, Vargas P, et al. Anatomical and functional results after arthroscopic Hill-Sachs remplissage. *J Bone Joint Surg*. 2012;94(7):618–626.
- Ko SH, Shin SM, Jo BG. Outcomes of minimally 1 year follow-up for the arthroscopic Remplissage technique with Hill-Sachs lesion. *J Orthop*. 2013 Feb 20;10(1):41–45. <https://doi.org/10.1016/j.jor.2013.01.009>.
- Wolf Eugene M, Arianjam Afshin. Hill-Sachs remplissage, an arthroscopic solution for the engaging Hill-Sachs lesion: 2- to 10-year follow-up and incidence of recurrence. *J Shoulder Elbow Surg*. 2014;23:814–820.
- Garcia GH, Park MJ, Zhang C, Kelly 4th JD, Huffman GR. Large hill-sachs lesion: a comparative study of patients treated with arthroscopic Bankart repair with or without remplissage. *HSS J*. 2015 Jul;11(2):98–103. <https://doi.org/10.1007/s11420-015-9438-8>. Epub 2015 Apr 1.
- Brilakis E, Mataragas E, Deligeorgis A, Maniatis V, Antonogiannakis E. Midterm outcomes of arthroscopic remplissage for the management of recurrent anterior shoulder instability. *Knee Surg Sports Traumatol Arthrosc*. 2016 Feb;24(2):593–600. <https://doi.org/10.1007/s00167-014-2848-1>. Epub 2014 Feb 1.
- Cho NS, Yoo JH, Rhee YG. Management of an engaging Hill-Sachs lesion: arthroscopic remplissage with Bankart repair versus Latarjet procedure. *Knee Surg Sports Traumatol Arthrosc*. 2016 Dec;24(12):3793–3800. Epub 2015 Jun 5.
- Morsy MG. Arthroscopic remplissage: is it still an option? *EFORT Open Rev*. 2017 Dec 8;2(12):478–483. <https://doi.org/10.1302/2058-5241.2.160070>.
- Peter Domos, Ascione Francesco, Andrew L, Wallace. Arthroscopic Bankart repair with remplissage for non-engaging Hill-Sachs lesion in professional collision athletes. *Shoulder Elbow*. 2017;0(0):1–9. <https://doi.org/10.1177/1758573217728414>.
- Bonnevalle N, Azoulay V, Faraud A, Elia F, Swider P, Mansat P. Results of arthroscopic Bankart repair with Hill-Sachs remplissage for anterior shoulder instability. *Int Orthop*. 2017 Dec;41(12):2573–2580. <https://doi.org/10.1007/s00264-017-3491-5>. Epub 2017 May 11.
- Garcia GH, Park MJ, Baldwin K, Fowler J, Kelly 4th JD, Tjoumakaris FP. Comparison of arthroscopic osteochondral substitute grafting and remplissage for engaging Hill-Sachs lesions. *Orthopedics*. 2013 Jan;36(1):e38–e43. <https://doi.org/10.3928/01477447-20121217-16>.
- Koo SS, Burkhart SS, Ochoa E. Arthroscopic double-pulley remplissage technique for engaging Hill-Sachs lesions in anterior shoulder instability repairs. *Arthroscopy*. 2009 Nov;25(11):1343–1348. <https://doi.org/10.1016/j.arthro.2009.06.011>.



# Management of glenohumeral arthritis in the young patient – A systematic review

Robert W. Jordan<sup>\*</sup>, Cormac P. Kelly

Robert Jones and Agnes Hunt Hospital, United Kingdom

## ARTICLE INFO

### Article history:

Received 5 November 2018

Accepted 1 January 2019

Available online 4 January 2019

### Keywords:

Shoulder  
Osteoarthritis  
Degenerative disease  
Shoulder arthroplasty  
Shoulder replacement  
Glenoid resurfacing

## ABSTRACT

**Introduction:** Glenohumeral joint degeneration in young patients has varying aetiology and provides a challenging clinical problem whose management is controversial. This review aims to provide an overview of the surgical options for managing these young patients.

**Methods:** A systematic review of the literature was conducted in accordance with the PRISMA guidelines using the online databases Medline and EMBASE. Cases series and comparative studies reporting on surgical interventions for glenohumeral joint degeneration in young patients (<65 years or a mean age <60 years) were included. Robustness of study methodology was appraised using the Methodological index for non-randomised studies.

**Results:** 30 eligible studies were identified; 10 hemiarthroplasty (HA) and glenoid resurfacing, 4 HA and glenoid reaming, 4 total shoulder arthroplasty (TSA), 3 glenoid resurfacing, 3 arthroscopic debridement, 3 reverse shoulder arthroplasty (RSA), 2 humeral resurfacing and 1 pyrocarbon interposition arthroplasty. Arthroscopic treatments reported good post-operative functional results, but revision rates ranged from 15.8% to 22% at short term follow-up. Although HA and glenoid resurfacing provided an improvement in functional scores, a high revision rate was reported in most studies (9.1%–77%) which was higher than after HA and glenoid reaming (2.8%–16.7%) and humeral resurfacing (2%–12%). TSA was reported to improve the mean Constant Score from 34 to 64 but glenoid loosening ranged from 17.6% to 43.8% and revision rate 6.5%–34% across the studies.

**Conclusion:** Surgical intervention in young patients with glenohumeral degeneration carries higher risk of failure and subsequent need for potentially complex revision surgery. Therefore, non-operative measures should be exhausted and patients adequately counselled prior to proceeding to arthroplasty.

© 2019 International Society for Knowledge for Surgeons on Arthroscopy and Arthroplasty. Published by Elsevier, a division of RELX India, Pvt. Ltd. All rights reserved.

## 1. Introduction

The presence of glenohumeral joint degeneration in young and active individuals provides the treating clinician with a challenge. Their increased functional demands and expectations requires surgical reconstruction to have greater durability.<sup>1</sup> In young patients the prospect of early revision within 10 years needs to be considered and thus the choice of implants and surgical technique may differ from the older patient. The aetiology of early degenerative change is varied and can be secondary to trauma, surgery, avascular necrosis, glenoid dysplasia, infection and chondrolysis.

Traditional conservative management has included physiotherapy, activity modification and analgesics. Conservative measures are preferred initially as they subject patients to minimal risk

but the evidence to support the different treatments and their ability to alter disease progression is limited.<sup>2</sup> Although there is strong evidence for the use of paracetamol, anti-inflammatory and opiates medications for osteoarthritis in general, they all have specific adverse effects that need to be considered.<sup>3–6</sup> There is no available evidence to support the routine use of corticosteroid injections in shoulder arthritis<sup>7</sup> and sodium hyaluronate has only been shown to reduce pain at short term follow up.<sup>8</sup> Previous Cochrane reviews have highlighted the limited available evidence for both physiotherapy and injections in shoulder pain.<sup>9,10</sup> Both suprascapular nerve block and acupuncture have been shown to improve symptoms in general shoulder pain but specific studies on osteoarthritis are lacking.<sup>11,12</sup> There is little reported on the outcome of biologics and cell therapy in the shoulder<sup>13,14</sup> unlike the progress being made in certain types of early cartilage loss in the knee. It is likely that patients who are young and active will have a prolonged period of observation coupled with activity modification before the option of surgery is considered.

<sup>\*</sup> Corresponding author. Robert Jones and Agnes Hunt Hospital, Gobowen, Oswestry, SY10 7AG, United Kingdom.

E-mail address: [Robert.jordan6@nhs.net](mailto:Robert.jordan6@nhs.net) (R.W. Jordan).

Surgical options after failed conservative management include arthroscopic debridement, biological resurfacing, hemiarthroplasty (HA), total shoulder arthroplasty (TSA), reverse shoulder arthroplasty (RSA) and shoulder arthrodesis. Arthroscopic debridement has been proposed in patients with concentric wear, residual joint space of more than 2 mm and only mild loss of range of motion.<sup>15</sup> Limited reports are available on microfracture of isolated cartilage loss on the humeral head or glenoid however few authors see this treatment as affording any long-term benefits to patients.<sup>16,17</sup> Although an option, shoulder arthrodesis is unattractive to the younger patient due to the possibility of persistent peri scapular pain, stress on musculature and acromioclavicular joints combined with marked loss of motion.<sup>18</sup>

For these reasons it is not surprising that the number of arthroplasties being undertaken in young patients is increasing at a rate of 8.2% per year<sup>19</sup> despite age under 60 being associated with poorer outcomes.<sup>20–24</sup> TSA carries the risk of glenoid loosening which accounts for 39% of all complications<sup>25</sup> and has been reported in 73% of patients at 15–20 years follow up.<sup>26</sup> HA can cause glenoid arthritis, posterior humeral subluxation and posterior glenoid erosion.<sup>21, 22, 27–29</sup> Previous studies have demonstrated that TSA provides superior results to HA in terms of pain and function<sup>30–33</sup> leading to a trend to increased TSA compared to HA in young patients.<sup>19</sup> Biological resurfacing of the glenoid has been proposed as an additional technique to HA to avoid metal-on-bone contact and delay glenoid erosion. Despite RSA becoming increasingly used in older populations, the majority advocate that it should be used with care in younger patients and those with high functional demands.<sup>34,35</sup>

In this young population it is important to consider the requirement for future revision procedures given the challenges of revision in the presence of significant bone loss.<sup>36,37</sup> In addition, the revision of a failed HA to TSA has been shown result in inferior to those achieved after primary TSA.<sup>38,39</sup> The aim of this study was to provide an overview of the surgical options for managing young patients with glenohumeral joint degeneration, with particular respect to survivorship.

## 2. Methods

A systematic review of the literature was conducted in accordance with the PRISMA guidelines<sup>40</sup> using the online databases Medline and EMBASE. The review was registered on the PROSPERO database on 4th September 2018 (Reference CRD 42018108946). The searches were performed on the 23rd of August 2018 and repeated on the 30th of August 2018 to ensure accuracy. The Medline search strategy is illustrated in [Appendix Table A.1](#).

Only studies that were published in English were included. Both cases series and comparative studies reporting on surgical interventions for glenohumeral joint degeneration in young patients of any grade were included. For the purposes of this review young patients were defined as patient cohorts all under 65 years or a mean age under 60 years. The study must have reported either functional outcomes, revision rates or survivorship. In addition, only primary research was considered for review with any abstracts, comments, review articles and technique articles excluded. Data from comparative studies and case series were presented together as a narrative synthesis of each individual outcome measure. The robustness of study methodology was appraised using the Methodological index for non-randomised studies (MINORS)<sup>41</sup> and these findings are detailed in [Appendix Table A.2](#).

## 3. Results

The search strategy identified 30 studies eligible for inclusion (n = 1100);<sup>42–70</sup> 10 HA and glenoid resurfacing (n = 238), 4 HA and glenoid reaming (n = 141), 4 TSA (n = 191), 3 glenoid resurfacing

(n = 73), 3 arthroscopic debridement (n = 120), 3 RSA (n = 180), 2 humeral resurfacing (n = 102) and 1 pyrocarbon interposition arthroplasty (n = 55). A flow chart of the search strategy is shown in [Appendix Figure A1](#). Concise details of the included studies are given in [Appendices Table A.3 to A.10](#).

### 3.1. Hemiarthroplasty and glenoid resurfacing

HA has the potential advantage of avoiding glenoid loosening and failure which is relatively common after TSA in young patients.<sup>25,26</sup> An example case of a 26 year old with post-instability arthropathy treated successfully with hemiarthroplasty is illustrated in [Fig. 1A](#) and B. However, HA alone leaves the replacement humeral head articulating with the glenoid which may cause subsequent pain, erosion and arthritis.<sup>21,22, 27–29</sup> This potential glenoid erosion can lead to subsequent problems as revision to an anatomic total shoulder may be compromised by bone loss. This leads to difficult decision making and often the need to consider RSA in a patient who may be still very young and active. The addition of glenoid resurfacing to the HA is an attempt to avoid this metal to bone articulation preventing glenoid pain and erosion thus increasing the longevity of the implant.

Ten studies were identified that reported on results following HA and glenoid resurfacing,<sup>42–51</sup> concise details of these studies are shown in [Appendix Table A.3](#). Within these studies a variety of materials were used for glenoid resurfacing; meniscal allograft, fascia lata, dermal matrix, capsule, achilles allograft or a combination of these.

Overall the post-operative functional outcomes improved following intervention with the mean ASES score ranging from 57.7 to 76 and the mean Constant score from 29 to 58. The largest case series from Lo et al.<sup>47</sup> reported outcomes after dermal matrix resurfacing in 55 patients with a mean age of 50 years. At a mean of 5 years good outcomes were achieved in the majority (mean ASES 76) and the revision rate was 9.1% although only 5.4% for persistent pain believed to originate from the glenoid. However, the remaining 9 studies all reported higher revision rates, ranging from 9.1% to 77%. The highest revision rate was reported by Elhassan et al. who reported at 92% failure rate and 77% revision rate to TSA for persistent pain when their 13 patients were managed with either capsule, fascia lata or achilles allograft for glenoid resurfacing.<sup>50</sup>

Hammond et al.<sup>43</sup> provided the only comparative study comparing HA alone against HA with biological glenoid resurfacing using either a meniscal allograft or dermal matrix. The study reported no statistically significant difference in ASES, Constant score or ROM between the groups but the revision rate was double (60% vs 30%) after glenoid resurfacing. Strauss et al.<sup>48</sup> reported the use of both meniscal allograft (75%) and dermal matrix (25%) and a trend to increased revision rate with dermal matrix (70% vs 45%). Similarly, Puskas et al.<sup>45</sup> presented subgroups according to the material used to resurface the glenoid but the numbers were limited (n = 17) and the failure rate was high in all three groups; dermal matrix 100%, shoulder capsule 67% and meniscal allograft 60%.

### 3.2. Hemiarthroplasty and glenoid reaming – ‘ream and run’

HA and glenoid reaming is another surgical option which avoids a glenoid implant with the associated complications. As an alternative to resurfacing, the glenoid is reamed to ensure that the replaced humeral head can smoothly articulate with the glenoid and might be indicated when version of the glenoid is unacceptable. The downside of this technique is that the important subchondral plate is violated leading to the increased risk of further bone erosion.

Four studies reported results after hemiarthroplasty and reaming of the glenoid,<sup>52–55</sup> details of these studies are given in [Appendix Table A.4](#). Three studies over-reamed the glenoid 2 mm above the

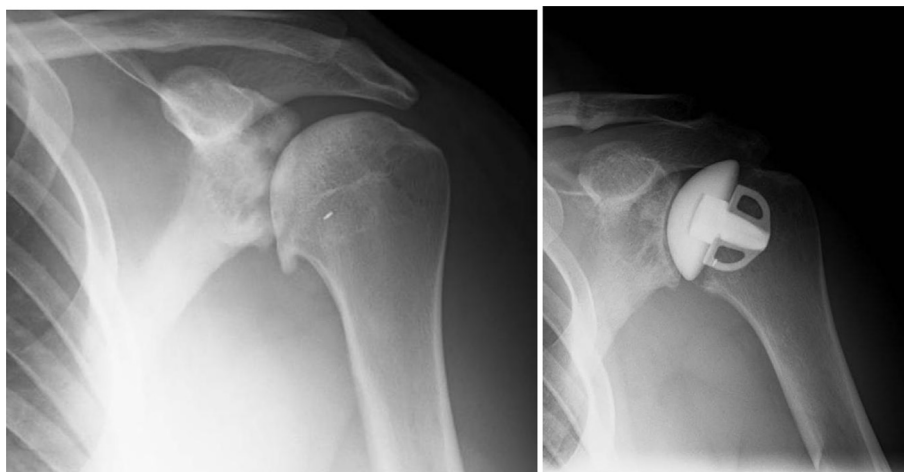

Fig. 1. A and 1B – Pre and Post-operative radiographs of a 26 year old with instability arthropathy treated with stemless hemiarthroplasty and glenoid microfracture.

humeral head size whilst the final study either concentrically reamed or over-reamed by 2 mm. Only one study reported the ASES score with a mean of 90 and three reported the Simple Shoulder Test with post-operative scores ranging from 9.4 to 10. Revision rates varied; Lynch reported that only 2.8% required revision,<sup>55</sup> whereas both Saltzman et al.<sup>52</sup> and Getz et al.<sup>54</sup> reported revision rates for glenoid failure as 10.7% and 16.7% respectively. Although these higher revision rates occurred in populations with lower mean age.

### 3.3. Total shoulder arthroplasty

TSA has previously been shown to provide better functional results than HA,<sup>30–33</sup> although the long-term risk of glenoid loosening and failure are recognised concerns. Four studies were identified that reported on TSA in young patients,<sup>56–59</sup> study details are presented in [Appendix Table A.5](#). Functional outcomes improved after the surgery with Simple Shoulder Value increasing from 12 to 70 and the Constant Score from 34 to 64.<sup>57,58</sup> Radiographic follow up showed glenoid loosening varied from 17.6% to 43.8% and that subluxation was noted in 50% of cases. The revision rate varied from 6.5% to 34% amongst the studies; Denard et al. and Gauci et al. provided the longest mean follow up for TSA studies.<sup>57,58</sup> Denard et al. reported an overall revision rate of 34% at just under 12 years follow up with the rate of revision for glenoid loosening 24%. Gauci et al. had similar length of follow up and demonstrated a 22% revision rate for all polyethylene cemented glenoid components.

Bartelt provided a comparison of TSA and HA in the management of 46 patients with a mean age of 49 years.<sup>56</sup> At a mean follow up of 7 years, the revision rate was 6.5% for TSA (2.2% for glenoid loosening) and 30% for HA (25% for glenoid pain). Gauci et al. compared results after TSA with cemented polyethylene glenoid and meta-backed glenoid component.<sup>58</sup> The improvement in Constant Score was comparable but at a mean 10 years follow up the revision rate was significantly higher in the metal-backed group; 70% vs 22% ( $p < 0.0001$ ).

### 3.4. Glenoid resurfacing

Glenoid resurfacing acts as an interposition arthroplasty without acquiring the risk of implants in this young population. Numerous materials have been tried as grafts over the years including capsular reflection, free fascia lata, various allograft and xenograft preparations. These techniques rely on having a reasonably smooth and congruent humeral head that articulates with the stable graft. Stabilisation of the graft can be achieved having either with sutures or

bone anchors. If the head is arthritic and deformed these procedures have been combined with hemiarthroplasty as previously described.

Three studies reported results after glenoid resurfacing (see [Appendix Table A.6](#)) using dermal matrix, meniscal allograft or porcine small intestinal mucosa.<sup>15,60,61</sup> The patients achieved good functional outcomes with ASES score improving to 76–78 and Constant Score of 79. Savoie et al. performed MRI scans on all patients during follow up and demonstrated that 19 of 20 allograft remained intact.<sup>61</sup> In addition, Savoie et al. reported survivorship of 75% at 5 years despite performing the procedure in young population with mean age of 32 years. However, the relatively high revision rates (range 23%–70%) at only midterm follow up raises concerns that the failure rate could rise with longer follow up.

### 3.5. Arthroscopic debridement

Three studies reported results after arthroscopic treatment,<sup>62–64</sup> detailed in [Appendix Table A.7](#). Both Kerr et al. and Van Thiel et al. groups described arthroscopic debridement with the majority of patients undergoing concomitant procedures which included capsular release, subacromial decompression, biceps tenotomy/tenodesis or distal clavicle resection.<sup>62,64</sup> Millett et al.<sup>63</sup> described a comprehensive arthroscopic management procedure (CAM) which involved glenohumeral chondroplasty, removal of loose bodies, humeral osteoplasty and osteophyte resection, anterior, posterior and inferior capsular release, subacromial decompression, axillary neurolysis and biceps tenodesis for each patient.

Overall all three studies showed good post-operative functional results with ASES score ranging from 72.7 to 83, SANE from 71 to 87 and DASH 17. Revision rates ranged from 15.8% to 22% although the follow up for these arthroscopic studies was even shorter (mean 10–20 months) and the mid to long term results of this approach are not known.

Kerr et al.<sup>62</sup> analysed the relationship between severity of the glenohumeral degeneration and the response to arthroscopic management. The authors reported that the grade of arthritis did not influence functional outcome but the presence of bipolar disease resulted in a poorer prognosis than unipolar disease ( $p = 0.014$ ). Similarly, Millett et al.<sup>63</sup> demonstrated that if the glenohumeral joint distance was under 2 mm that the patient had a 7.8 higher chance of a poor outcome following the CAM procedure ( $p = 0.037$ ).

### 3.6. Reverse shoulder arthroplasty

RSA has become increasingly used both in the primary

arthroplasty setting and as a salvage procedure in the older population but many caution its use in younger patients with long term results in this subgroup still uncertain.<sup>34,35</sup> Three studies reported the results of RSA in young patients and these are presented in [Appendix Table A.8](#).<sup>65–67</sup> The patients included in these studies differed from the other surgical interventions discussed. Overall the mean population age was higher and the prevalence of cuff tear arthropathy higher (59–100%). These significant differences between study population precludes direct comparison of the RSA results to other studies.

The studies report significant improvement in functional scores after RSA with mean post-operative ASES score ranging from 62 to 74 and 81% being satisfied or very satisfied with the outcome. The complication rate ranged from 15% to 37.5% with instability (1.5%–15%) and infection (1.5%–10.5%) the most frequent reasons for revision. Survivorship was reported between 91% and 98% at 5 years and 88% at 10 years follow up.

### 3.7. Humeral resurfacing hemiarthroplasty

Surface replacement offers a hemiarthroplasty technique but with additional advantages of ease of revision and reduced incidence of periprosthetic fracture. Copeland popularised the technique in the 1990s through to recent times.<sup>71</sup> An example case is illustrated in [Fig. 2A, B and 2C](#) where a 26 year old gentleman was managed with humeral resurfacing after a head splitting proximal humeral fracture dislocation with excellent clinical and radiographic results at 17 years follow up. However National joint registries suggest a downturn in its popularity.<sup>72</sup> This has mainly been related to reported early glenoid pain and need for revision.<sup>73–75</sup> The increased popularity of short stem devices also known as “stemless” has encroached on the surface replacement market as these short stems claim to offer the advantages of surface replacement but with the ability to allow better access to the glenoid.

Two studies reported the results after humeral resurfacing in young population,<sup>68,69</sup> see details in [Appendix Table A.9](#). Levy et al.<sup>68</sup> reported on 54 patients either undergoing humeral resurfacing and glenoid microfracture (n = 37) or TSA using a metal-backed glenoid (n = 17). Good functional scores were seen according to the Constant score in both groups with a trend to higher scores after resurfacing (77 vs 58). The revision rate was found to be higher after TSA 29% vs 12% after resurfacing at mean 14.5 years of follow up. 80% of revisions after TSA were due to glenoid loosening, whereas 60% of revisions following resurfacing were due to cuff failure and only one case due to glenoid erosion despite radiographic evidence of erosion in 32% of cases during follow up. Survivorship was similar between resurfacing and TSA at 5 years (97% vs 100%) but by 22 years survivorship was higher after resurfacing 85% vs 61%. Iagulli et al.<sup>69</sup> performed a retrospective case series of 48 patients undergoing resurfacing and at a mean of 6 years follow up reported evidence of radiographic glenoid erosion in 12.5% but

that only 2% patients required revision surgery for glenoid pain in the presence of cuff failure. The senior author has observed good clinical long-term outcomes in young patients with resurfacing hemiarthroplasty where the glenoid cartilage was intact at initial surgery ([Fig. 1A and B](#)).

### 3.8. Ceramic and pyrocarbon humeral arthroplasty

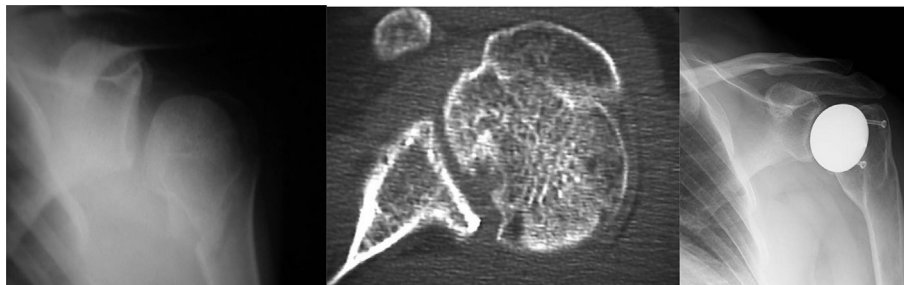
Glenoid failure secondary to wear debris and aseptic loosening is a common indication for revision surgery.<sup>76</sup> This is caused by increased eccentric loads, particularly in the case of malalignment, which leads to higher stresses and wear of the polyethylene.<sup>77</sup> Typically the articulating surfaces in shoulder arthroplasty are composed of metallic and polyethylene components. To overcome problem associated with polyethylene wear, alternative bearings have been sought. In total hip replacements, ceramics have been demonstrated to produce lower wear rates than metal heads.<sup>78,79</sup> This favorable wear performance and wide use of ceramics can be attributed to its inertness, low coefficient of friction, wettability, scratch resistance, and reduced hardness.<sup>80</sup> However data for the use of ceramics in shoulder surgery is limited. In a biomechanical study Mueller et al.<sup>81</sup> demonstrated a significant 26.7% reduction in wear when comparing ceramic to metallic heads in anatomic shoulder arthroplasty but further clinical evidence is required to confirm this potential benefit.

Garret et al.<sup>70</sup> performed the only study reporting on pyrocarbon interposition arthroplasty in young patients and details of this study are presented in [Appendix Table A.10](#). Early results at 26.8 months mean follow up showed that Constant scores improved from mean 34 to 66. Radiographic follow up demonstrated glenoid erosion in 10.9% and tuberosity thinning in 5.4%. Survivorship at 4 years was 89% with only one patient (1.8%) requiring revision for persistent pain. The study provides only early outcomes and the authors conclude that until long term results become available that the technique should only be performed at specialist centres.

## 4. Discussion

The results from this systematic review have highlighted the difficulty managing young active patients presenting with glenohumeral arthritis. Seven different surgical interventions have been presented with each raising concerns regarding revision rates for this subgroup of patients. Failure is especially important in this subgroup given their high activity levels, their longer life expectancy and the challenge presented by revision shoulder arthroplasty given poor glenoid bone stock and deteriorating soft tissues including the deltoid muscle and the rotator cuff.

Both arthroscopic debridement and glenoid resurfacing are techniques that avoid risks of implant failure and may provide a temporising measure to delay need for implant surgery with revision required in 15–22% after arthroscopy and 23–70% after



**Fig. 2.** A, 2B and 2C – Pre-operative, post-operative and 17 year follow-up radiographs of a 26 year old with head splitting proximal humeral fracture dislocation treated successfully with humeral resurfacing and autograft.

glenoid resurfacing. The studies reviewed suggest that if an arthroscopic debridement is considered that patient selection is important with the presence of a well-maintained glenohumeral joint space and unipolar arthritis associated with improved outcomes.<sup>62,63</sup> However, follow up results in these studies was limited to a mean of only 10–20 months. Biological glenoid resurfacing was advocated in young patients to reduce the glenoid erosion and pain after HA, however this technique had globally poor results and this review cannot support its routine use (revision rate 9.1%–77%). The low revision rates reported after humeral resurfacing (2% and 12%) and pyrocarbon interposition arthroplasty (1.8%) are encouraging but the availability of minimal data, the lack of comparative studies and lack of long term follow up prevents strong conclusions being drawn on these modalities.

The 14th UK National Joint Registry (NJR) report states that 4 year revision rates for HA, humeral resurfacing and TSA in England and Wales were 5.01% (3.79–6.59), 5.17% (4.09–6.54) and 3.53% (2.89–4.31) respectively.<sup>72</sup> The revision rates for HA (2.8–25%) and TSA (6.5–34%) in this review were higher than these NJR figures suggesting that this young subgroup of patients are indeed at increased risk of implant failure. The 14th NJR report supports this finding and it reported patients under the age of 65 years are at highest risk of failure with revision rates at 4 years of 7.62% (6.11–9.48) in males and 6.39% (4.9–8.3) in females. However, the NJR data is limited to 4 years follow up, inclusion of 23,608 replacements and further subgroup analysis of younger age groups has not been performed at this stage.<sup>72</sup>

Bartelt et al.<sup>56</sup> did perform a retrospective comparison of TSA and HA and demonstrated a trend to increase revision rate after HA (30% vs 6.4%) but this did not reach statistical significance and the study risked inclusion bias. Similarly the higher revision rates reported after TSA, 22% and 34%, were reported at 124 months and 115 months, whereas comparable revision rates after HA were reported over a shorter follow up period (32–51 months) suggesting TSA may have a comparably lower failure rate. The results from Gauci et al.<sup>58</sup> did demonstrate that meta-back glenoid components had a higher risk of failure than all polyethylene implants in TSA. Possible explanations for this include over lateralisation risking soft tissue failure,<sup>82,83</sup> difference in elasticity between metal and bone increasing risk of stress shielding<sup>84–86</sup> and difference in elasticity between polyethylene and metal increasing risk polyethylene wear.<sup>87,88</sup>

Although three studies were identified that reported on RSA in young patients, most patients included in these were reported to have cuff tear arthropathy and thus provided a different cohort of patients to those receiving the other interventions where post-instability, post-surgical, post-traumatic and primary osteoarthritis were the most frequent indication. These studies did show RSA is an option for these young patients with cuff arthropathy, but long-term studies are still required to test the implants survivorship in this young patient population with previous studies suggesting radiographic results, functional outcomes and survivorship deteriorated at a follow-up time of six to eight years after RSA.<sup>35</sup>

Appraisal of the studies using the Methodological index for non-randomised studies (MINORS) tool demonstrated a variety of limitations which are summarised in Appendix Table A.2. One major limitation of this review is its failure to identify all surgical interventions for treating glenohumeral degeneration in young patients despite the purposefully broad inclusion criteria. Cell therapy in the form of osteochondral autologous transfer surgery<sup>13</sup> and autologous chondrocyte implantation<sup>14</sup> has been proposed but data is limited to case reports and small case series. The use of partial prosthetic resurfacing such as the HemiCAP device (ArthroSurface Inc., Franklin, MA, USA) has been proposed as an option for contained defects in the humeral head with Sweet et al. reporting 20 cases with mean age of 48.9 years, good functional improvement ASES score 24.1 to 78.8 and 10% revision rate.<sup>89</sup>

Wang et al. reported an overall survival rate of 76.6% at 9.6 years after microfracture in 13 shoulders with a mean age of 36 years.<sup>16</sup> Similarly, Millet et al. reported on 31 cases with 4 years follow up with improvement in pain and function for small, focal isolated lesions on humeral head but poorer outcomes with bipolar lesions.<sup>17</sup>

## 5. Conclusion

Surgical intervention in young patients with glenohumeral degeneration carries higher risk of failure and subsequent need for potentially complex revision surgery. Therefore non-operative measures should be exhausted and patients adequately counselled prior to proceeding to arthroplasty. Although humeral resurfacing, HA and TSA have been shown to produce functional improvements, secondary to its lower revision rates and previous comparative studies demonstrating improved functional outcomes, TSA is proposed as the optimal treatment when arthroplasty is considered in these patients. Pre-operative planning with 3D simulation, patient specific guides and navigation techniques are now being used by surgeons to better recreate normal anatomy and orientation of implants. New materials such as Vitamin E enriched polyethylene and ceramic humeral heads may reduce particulate wear and thus the longevity of the bearing surfaces in younger patients however the outcomes of such innovations are as yet unknown.

## Conflicts of interest

No funding was received during the production of this manuscript.

Mr RW Jordan is currently undertaking a shoulder fellowship funded by Mathys (UK)

Mr CP Kelly is part of the development team for the Mathys Stemless implant.

## Appendix

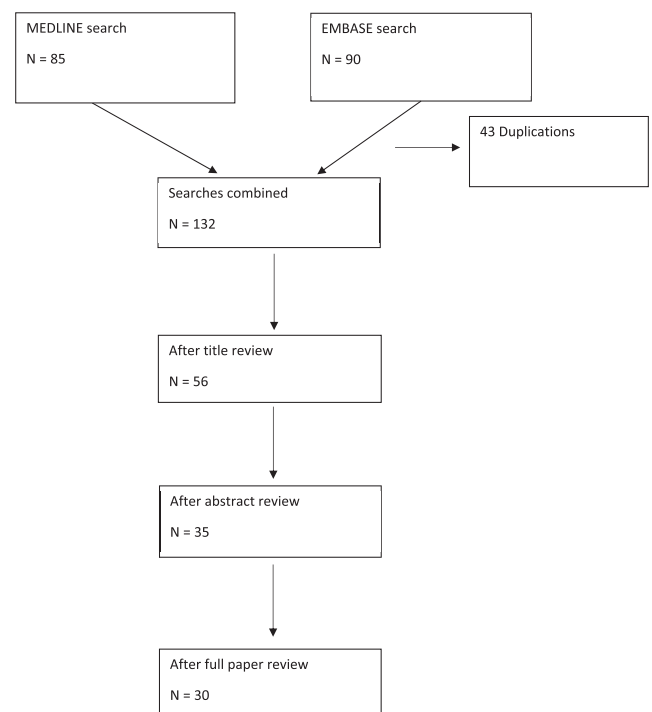


Fig. A1. Flow diagram of review process.

**Table A.1**  
Search strategy for Medline

Search number	Search term	Number
1	Shoulder arthritis.mp.	91
2	SHOULDER JOINT/	17553
3	ARTHRITIS/	34431
4	2 and 3	500
5	Glenohumeral arthritis.mp.	242
6	Young patient.mp.	4508
7	Young patients.mp.	18526
8	YOUNG ADULT/or young.mp.	1004177
9	1 or 4 or 5	732
10	6 or 7 or 8	1004177
11	9 AND 10	85

**Table A.2**  
Methodological items for non-randomised studies (MINORS) Scores for included studies

	Clear aim	Includes consecutive patients	Appropriate endpoints	Unbiased assessment	Appropriate follow-up	Loss to follow up <5%	Prospective study size calculation	Additional criteria if comparative study	Adequate control group	Contemporary groups	Baseline groups equivalent	Adequate statistical analyses	Total Score
Burkead et al. <sup>42</sup>	1	0	2	0	2	1	0	N/A	N/A	N/A	N/A	0	6/16
Hammond et al. <sup>43</sup>	2	2	2	2	2	1	0	1	2	2	2	2	20/24
Muh et al. <sup>44</sup>	2	0	2	0	2	2	0	N/A	N/A	N/A	N/A	2	10/16
Puskas et al. <sup>45</sup>	2	0	2	0	2	2	0	N/A	N/A	N/A	N/A	1	9/16
Lee et al. <sup>46</sup>	2	0	2	0	2	2	0	N/A	N/A	N/A	N/A	0	8/16
Lo et al. <sup>47</sup>													
Strauss et al. <sup>48</sup>	2	0	2	2	2	1	0	N/A	N/A	N/A	N/A	2	11/16
Bois et al. <sup>49</sup>	2	0	2	2	2	1	1	N/A	N/A	N/A	N/A	2	12/16
Elhassan et al. <sup>50</sup>	2	1	2	0	1	2	0	N/A	N/A	N/A	N/A	2	10/16
Wirth et al. <sup>51</sup>	2	2	2	0	2	1	0	N/A	N/A	N/A	N/A	2	11/16
Saltzman et al. <sup>52</sup>	2	2	2	0	2	1	0	N/A	N/A	N/A	N/A	2	11/16
	Clear aim	N/A	Appropriate endpoints	Unbiased assessment	Appropriate follow-up	Loss to follow up <5%	Prospective study size calculation	Additional criteria if comparative study	Adequate control group	Contemporary groups	Baseline groups equivalent	Adequate statistical analyses	Total Score
Somerson et al. <sup>53</sup>	2	2	2	0	2	1	0	N/A	N/A	N/A	N/A	2	11/16
Getz et al. <sup>54</sup>	2	1	2	1	2	1	0	N/A	N/A	N/A	N/A	2	11/16
Lynch et al. <sup>55</sup>	2	2	2	1	2	1	0	N/A	N/A	N/A	N/A	2	12/16
Bartelt et al. <sup>56</sup>	2	2	2	0	2	2	0	1	2	2	1	2	18/24
Denard et al. <sup>57</sup>	2	0	2	2	2	2	0	N/A	N/A	N/A	N/A	2	12/16
Gauci et al. <sup>58</sup>	2	2	2	0	2	2	0	1	2	2	2	2	19/24
Kusnezov et al. <sup>59</sup>	2	2	2	0	1	0	0	N/A	N/A	N/A	N/A	2	9/16
Hartzler et al. <sup>60</sup>	2	2	2	0	2	1	0	N/A	N/A	N/A	N/A	2	11/16
Savoie et al. <sup>61</sup>	2	1	2	0	2	1	0	N/A	N/A	N/A	N/A	1	9/16
Kerr et al. <sup>62</sup>	1	1	2	0	1	2	0	N/A	N/A	N/A	N/A	2	9/16
Millett et al. <sup>63</sup>	2	2	2	0	1	1	0	N/A	N/A	N/A	N/A	2	10/16
	Clear aim	Includes consecutive patients	Appropriate endpoints	Unbiased assessment	Appropriate follow-up	Loss to follow up <5%	Prospective study size calculation	Additional criteria if comparative study	Adequate control group	Contemporary groups	Baseline groups equivalent	Adequate statistical analyses	Total Score
Van Thiel et al. <sup>64</sup>	2	1	2	2	1	1	0	N/A	N/A	N/A	N/A	2	11/16
Ek et al. <sup>65</sup>	2	2	2	0	2	2	0	N/A	N/A	N/A	N/A	2	12/16
Samuelson et al. <sup>66</sup>	2	0	2	0	2	2	0	N/A	N/A	N/A	N/A	2	10/16
Muh et al. <sup>67</sup>	2	0	2	0	2	1	0	N/A	N/A	N/A	N/A	2	9/16
Levy et al. <sup>68</sup>	2	2	2	0	2	1	0	1	1	1	1	2	15/24
Iagulli et al. <sup>69</sup>	2	2	2	0	2	1	0	N/A	N/A	N/A	N/A	2	11/16
Garrett et al. <sup>70</sup>	2	2	2	1	2	2	0	N/A	N/A	N/A	N/A	2	13/16

MINOR scores: 0 (not reported), 1 (reported but inadequate) and 2 (reported and adequate).



**Table A.3**  
Summary of studies reporting hemiarthroplasty with biologic glenoid resurfacing

Study	Population	Intervention (s)	Comparator	Follow up (months)	Outcome Measures	Results	Revisions
Burkead et al. <sup>42</sup> (n = 6)	Mean 48 yrs <sup>33–54</sup> 100% male	Uncemented porous-coated modular HA Fascia lata autograft for glenoid	None	Mean 28 <sup>24–34</sup>	ROM Neer rating scale Pain	ROM • FF 81 to 138 • ER 5 to 50 • IR from L5 to T12 Neer rating scale • 83.3% excellent • 16.7% satisfactory results 83.3% excellent pain relief	16.7% revision rate Biceps tenodesis
Hammond et al. <sup>43</sup> (n = 20)	Mean 37.7 yrs <sup>19–54</sup>	BR group Cemented or cementless stemmed HA (n = 20) Lateral meniscal allograft or dermal matrix for glenoid	HA group Cemented or cementless stemmed HA (n = 21)	Mean 44.4 (12–88.8)	ASES Constant SST SANE VAS pain Radiographs ROM	ASES • BR group 59.5 • HA group 67 Constant • BR group 53 • HA group 67.9 SST • BR group 6.9 • HA group 7.5 VAS • BR group 4.8 • HA group 1.8 HA better VAS (p < 0.05) No difference SST, ASES, Constant or ROM	BR group • 60% revision rate • 0% glenoid erosion HA group • 30% revision rate 58% glenoid erosion on radiographs
Muh et al. <sup>44</sup> (n = 16)	Mean 36.1 yrs <sup>14–45</sup> 75% men	Stemmed HA or resurfacing Glenoid dermal matrix or achilles allograft	None	Mean 60 (24–96)	ASES VAS pain ROM	ASES 23.2 to 57.7 (p < 0.05) VAS 8.1 to 5.8 (p < 0.05)	44% revision rate • Mean 36 months • 100% converted to TSA Converted to TSA
Puskas et al. <sup>45</sup> (n = 17)	Mean 43 yrs <sup>31–57</sup>	Stemmed HA or resurfacing Glenoid • Dermal matrix (n = 6) • Meniscal allograft (n = 5) • Capsule interposition (n = 6)	None		SSV Constant score VAS pain ROM	SSV • Dermal matrix 23 to 35 • Meniscus 22 to 50 • Capsule 32 to 46 Constant score • Dermal matrix 32 to 29 • Meniscus 40 to 51 • Capsule 43 to 58 VAS Pain • Dermal matrix 4 to 7 • Meniscus 6 to 7 • Capsule 6 to 7	Dermal matrix • 100% failure • 83% revision rate • Mean 16 months Meniscus allograft • 60% failure • 60% revised • Mean 22 months Capsule interposition • 67% failure • 67% revised Mean 34 months
Lee et al. <sup>46</sup> (n = 21)	Mean age 54.8 <sup>35–68</sup> 71% men	Humeral resurfacing Capsule used for glenoid resurfacing	None	Mean 57.6 (24–127.2)	Constant score ASES Shoulder assessment form VAS Pain ROM Radiographs	Constant score 71.4 (41–95) ASES 74.4 (35–100) VAS pain at rest 0.5 (0–3) 56% moderate to severe glenoid erosion	14.2% revision rate • 4.7% converted to TSA for pain at 15 months • 4.7% infection 4.7% impingement
Lo et al. <sup>47</sup> (n = 55)	Mean 50 yrs <sup>23–65</sup>	Cemented stemmed humeral component  Dermal matrix for glenoid	None	Mean 60 (26–109)	WOOS ASES Pain SANE	WOOS 448±423 ASES 76±22 VAS pain 2.4±2.6	9.1% revision rate • 5.4% persistent pain • 1.8% Infection o 1.8% intraop humeral fracture Further 11% had poor function
Strauss et al. <sup>48</sup> (n = 41)	Mean 42.2 yrs (18–60)	Stemmed HA 84% and 16% resurfacing Lateral meniscal allograft (75%) or dermal matrix (25%) for glenoid	None	Mean 33.6 (8–98)	ASES SST Pain VAS	ASES 36.8 to 62 (p < 0.05) SST 4 to 7 (p < 0.05) VAS 6.3 to 3 (p < 0.05)	Clinical failure • Meniscus 45% • Dermal matrix 70% Revision rate 19% to TSA
Bois et al. <sup>49</sup> (n = 22)	Mean 46 yrs <sup>27–55</sup> 69% men	Stemmed HA Meniscal allograft for glenoid resurfacing	None	Mean 99.6 (60–120)	ASES SST VAS pain Radiographs ROM	ASES 31.6 to 59.6 (p < 0.001) SST 2.8 to 6.3 (o < 0.001) GH joint space 3.6 mm –1.4 mm Increased posterior glenoid erosion 2.8 mm to 4.1 mm	10 year survivorship 56.3% 30% known revisions 9 complications • 3 post op infections • 6 persistent shoulder pain and stiffness
Elhassen et al. <sup>50</sup> (n = 13)	Mean 34 yrs <sup>18–49</sup> 69% men	Stemmed anatomic prosthesis  Glenoid resurfaced using capsule, fascia	None	Mean 48 (6–102)	SSV Constant score VAS pain	SSV 21 to 33 Constant score 24 to 43 VAS pain 8 to 6	92% failure rate Revisions • 10 revision to TSA, mean time 16 months • Capsular release 4

(continued on next page)

**Table A.3** (continued)

Study	Population	Intervention (s)	Comparator	Follow up (months)	Outcome Measures	Results	Revisions
Wirth et al. <sup>51</sup> (n = 27)	Mean 43 <sup>24–53</sup> 70% men	lata or achilles allograft Stemmed anatomic prosthesis Meniscal allograft for glenoid	None	Mean 36 <sup>24–60</sup>	ASES SSV ROM	SST 2.7 to 7.3 ASES 30 to 67	<ul style="list-style-type: none"> <li>• Irrigation and debridement 1</li> <li>• Resection arthroplasty 1</li> <li>• 11% Revision rate</li> <li>• Displaced graft converted to shoulder replacement</li> <li>• 2 TSA for pain</li> <li>• 7.4% infection rate</li> </ul>

Abbreviations: ROM – range of motion, FF – forward flexion, ER – external rotation, IR – internal rotation, BR – biologic rotation, HA - hemiarthroplasty, ASES – American Shoulder Elbow Surgeons score, SST – Simple Shoulder Test, SANE - Single Assessment Numerical Evaluation score, VAS – Visual analogue score, TSA – total shoulder arthroplasty, WOOS - West Ontario Osteoarthritis Score, SSV – Subjective Shoulder Value, GH – Glenohumeral.

**Table A.4**  
Summary of studies reporting hemiarthroplasty with glenoid reaming

Study	Population	Intervention (s)	Follow up	Outcome Measures	Results	Revisions
Saltzman et al. <sup>52</sup> (n = 65)	Mean 48 yrs <sup>22–55</sup> 90.7% men	Stemmed humeral component Glenoid over reamed by 2 mm	Mean 43 <sup>24–85</sup>	SST Radiographs	SST 4.1 to 9.5 (p = 0.001) 72.7% of radiographs centred	Revision rate 13.8% <ul style="list-style-type: none"> <li>• 4 to TSA</li> <li>• 2 repeat glenoid reaming</li> <li>• 1 to reverse</li> <li>• 1 infection</li> <li>• 1 bone impingement</li> </ul>
Somerson et al. <sup>53</sup> (n = 17)	Mean 55 yrs <sup>24–69</sup> 64.7% men	Stemmed humeral component Glenoid over reamed by 2 mm	Median 51.6 (24–81.6)	SST ASES ROM Radiographs	SST 3.9 to 10.0 (p < 0.0001) ASES 43 to 90 (p < 0.0001)	Revision rate 17.6% <ul style="list-style-type: none"> <li>• Mean 32 months</li> <li>• 2 instability</li> <li>• 1 residual pain</li> </ul>
Getz et al. <sup>54</sup> (n = 24)	Mean 50 yrs (32–62.3) 100% men B2 Glenoids	Stemmed humeral component 54% Concentric glenoid reaming 46% 2 mm over-reamed	Mean 32.4 (8–110.4)	SST score PSS (with <70 defined as poor result) Revision rate Radiographs	42% had fair or poor outcome PSS 21% had residual posterior subluxation	Revision rate 25% <ul style="list-style-type: none"> <li>• 66.7% persistent pain at mean 11 months</li> </ul>
Lynch et al. <sup>55</sup> (n = 35)	Mean 57 yrs <sup>35–80</sup> 91% men	Stemmed humeral component Glenoid over reamed by 2 mm	Mean 32.4 <sup>24–48</sup>	SST Revision rate	SST 4.74 to 9.4	Revision rate 2.8% <ul style="list-style-type: none"> <li>• Repeat reaming</li> </ul>

Abbreviations: SST – Simple Shoulder Test, TSA – Total Shoulder Arthroplasty, ASES – American Shoulder and Elbow Surgeons score, ROM – range of motion, PSS – Penn Shoulder Score.

**Table A.5**  
Summary of studies reporting total shoulder arthroplasty

Study	Population	Intervention (s)	Comparator	Follow up	Outcome Measures	Results	Complications
Bartelt et al. <sup>56</sup> (n = 46)	Primary or secondary OA Mean 49 yrs <sup>21–55</sup> 67% men	TSA 4% required cuff repair	HA Mean age 49 yrs <sup>26–55</sup> 80% men	Mean 84 (9–242)	Pain Radiographs Neer Pain – 0 to 5	Pain TSA 4.4 to 2 HA 4.5 to 2.9 Subluxation 50% TSA 53.8% HA 17.6% TSA glenoid lucency	Revisions TSA 6.5% <ul style="list-style-type: none"> <li>• 4.3% infection</li> <li>• 2.2% glenoid loosening</li> <li>• HA 30%</li> <li>• 25% for pain (mean 4.5 years)</li> <li>• 5% infection</li> </ul> TSA Survival <ul style="list-style-type: none"> <li>• 100% at 5 years</li> <li>• 92% at 10 years</li> </ul> HA Survival <ul style="list-style-type: none"> <li>• 85% at 5 years</li> <li>• 72% at 10 years</li> </ul>
Denard et al. <sup>57</sup> (n = 50)	Mean 50.5 yrs <sup>35–55</sup>	TSA with keeled glenoid. 92% humerus cemented (Aequalis; Tornier, Edina, MN, USA)	None	Mean 115 (60–211)	Constant score SSV Radiographs	Constant score 31.6 to 20.7 (p < 0.001) SSV 12 to 70 Radiographic loosening 43.8%	Survivorship of glenoid <ul style="list-style-type: none"> <li>• 98% 5 year</li> <li>• 62% at 10 years</li> </ul> 34% revision <ul style="list-style-type: none"> <li>• 24% due to glenoid loosening</li> <li>• 4% subscapularis rupture</li> <li>• 2% humeral loosening</li> <li>• 2% oversized humeral head</li> </ul>
Gauci et al. <sup>58</sup> (n = 69)	Cemented group Mean 55 yrs <sup>40–60</sup> Metal-backed group Mean 53 yrs <sup>35–60</sup>	Cemented anatomic shoulder replacement, trapezoidal glenoid keel (Aequalis PE; Tornier,	Anatomic shoulder replacement, metal-backed glenoid (Aequalis MB	Mean 124 months	Constant scores SSV VAS for pain Radiographs	Constant score <ul style="list-style-type: none"> <li>• Cemented PE 33 to 64</li> <li>• Metal-backed 36 to 64</li> </ul> SSV • Cemented 69 • Metal-backed 71	Survivorship at 12 years <ul style="list-style-type: none"> <li>• 74% for cemented PE</li> <li>• 24% for metal-backed</li> <li>• P = 0.00002</li> </ul> Revision 70% vs 22% (p < 0.0001)

**Table A.5** (continued)

Study	Population	Intervention (s)	Comparator	Follow up	Outcome Measures	Results	Complications
		Montbonnot, France) N = 46	Glenoid; Tornier, Montbonnot, France) N = 23			VAS pain • Cemented 3 • Metal-backed 4	Complications • 28.2% cemented • 91% metal-backed
Kusnezov et al. <sup>59</sup> (n = 26)	Post-instability 50% Post-traumatic OA 26.9% Primary OA 19.2% Mean 45.8 yrs <sup>33–54</sup> 96% men	Anatomical TSR	None	Mean 41 (11.6–97.6)	Pain Return to duty ROM	Pain • 5.2 to 1.4 Return to duty • 72% at 1 year • 45.5% at two years	35% complications • 23.1% component failures • 7.7% glenoid acute failures after dislocations • 11.5% glenoid loosening • 3.8% humeral loosening

Abbreviations: OA - osteoarthritis, TSA – total shoulder arthroplasty, HA - hemiarthroplasty, SSV – Simple Shoulder Value, PE - polyethylene, VAS – Visual Analogue Score, ROM – range of motion.

**Table A.6**

Summary of studies reporting glenoid resurfacing

Study	Population	Intervention (s)	Follow up	Outcome Measures	Results	Revisions
Hartzler et al. (n = 43) <sup>60</sup>	Mean 57 yrs <sup>55–59</sup>	Dermal allograft >2 mm Graft Jacket	45 months <sup>9–71</sup>	ROM VAS pain ASES SSV Radiographic	• VAS 7 (6–8) to 2 (1–4) • ASES 47 (35–55) to 76 (57–88) • SSV post op 73 (65–90)	23.2% revision rate • 3 HA • 4 TSA • 3 RSA
Karelse et al. <sup>15</sup> (n = 10) RCT	Mean 44 yrs (19–57) 60% men	Meniscal allograft or dermal allograft	24	Constant score VAS	Constant score • 34 (15–46) VAS • 29 (28–33)	70% revision rate
Savoie et al. <sup>61</sup> (n = 20)	Mean 32 yrs (15–58)	Porcine small intestine mucosa	36–72	ASES UCLA Rowe score Constant-Murley VAS pain MRI	• Mean ASES 22 to 78 • UCLA 15 to 29 • Rowe score 55 to 81 • Constant-Murley score 26 to 79 • VAS pain 8 (0–10) to 2 • MRI 19/20 allograft intact	25% revision at 5 years

Abbreviations: ROM – range of motion, VAS – Visual Analogue Score, ASES – American Shoulder and Elbow Surgeons score, SSV – Subjective Shoulder Value, HA - hemiarthroplasty, TSA – total shoulder arthroplasty, RSA – reverse shoulder arthroplasty, RCT – randomised controlled trial, UCLA – University of California at Los Angeles Shoulder Score.

**Table A.7**

Summary of studies reporting arthroscopic treatment

Study	Population	Intervention (s)	Follow up (months)	Outcome Measures	Results	Revisions
Kerr et al. <sup>62</sup> (n = 19)	Mean age 38 (20–54) 63% men RC intact	Arthroscopic debridement	Mean 20 <sup>12–33</sup>	WOOS ASES SANE score SF-12	• WOOS 0.64 (0.12–0.98) • ASES 75.3 (24–100) • SANE score 71% • Comparable between grade 2/3 and grade 4 • Bipolar performed worse than unipolar o WOOS 0.52 vs 0.89 (p = 0.014) o SANE 49.3 to 89.6 (p = 0.022)	15.8% TSA
Millett et al. <sup>63</sup> (n = 30)	Mean age 52 (33–68) 79% men	Comprehensive arthroscopic management procedure	Mean 19.2 (25.2–56.4)	ROM ASES DASH SANE score Survivorship	ROM • FF 98.2 (20–180) to 152 (90–180) • ER 13.4 (–15 to 80) to 75.4 (45–100) ASES • 58 (42–78) to 83 (60–100) DASH • Post-op 17 (0–41) SANE score • 87 (70–100)	20% revision to replacement Survivorship • 92% 1 year • 85% 2 years Patients <2 mm GH joint space 7.8 times more likely to revise (p = 0.037)
Van Thiel et al. <sup>64</sup> (n = 71)	Mean age 47 (18–77) 66% men RC intact		Mean 10.1 (2.5–27.2)	Revision SST ASES SF-12 VAS pain ROM UCLA SANE	• WOOS 0.64 (0.12–0.98) • SST 6.1 (0–12) to 9 <sup>3–12</sup> • ASES 51.8 <sup>8–85</sup> to 72.7 (10–100) • VAS pain 4.8 (1–9) to 2.7 (0–9) • UCLA Post 28.3 (16–25) • SANE 71.1 (5–100)	Failure 22% • 4 HA • 9 TSA • 3 humeral head allograft

Abbreviations: RC - rotator cuff, WOOS - West Ontario Osteoarthritis Score, ASES – American Shoulder and Elbow Surgeons score, SANE – Single Assessment Numerical Evaluation score, SF-12 – Short Form survey, TSA - total shoulder arthroplasty, ROM – range of motion, DASH – Disabilities of the Arm, Shoulder and Hand score, GH – glenohumeral, SST -Simple Shoulder Test, VAS- Visual Analogue Score, UCLA – University of California at Los Angeles Shoulder score, HA – hemiarthroplasty.

**Table A.8**  
Summary of studies reporting reverse shoulder arthroplasty

Study	Population	Intervention (s)	Follow up	Outcome Measures	Results	Complications
Ek et al. <sup>65</sup> (n = 46)	Massive cuff tears Mean 60 yrs <sup>46–64</sup> 58% men	80% Delta III reverse (DePuy, Saint-Priest, France) 20% Anatomical Shoulder Reverse (Zimmer, Winterthur, Switzerland)	Mean 93 (60–171)	Constant score SSV ROM Radiographs	Constant 34 to 74 (p < 0.0001) SSV 23 to 66 (p < 0.0001) Notching in 56% of cases • Stage 1 24% • Stage 2 9% • Stage 3 21% • Stage 4 3%	Survival analysis • 98% at 5 years • 88% at 10 years 37.5% complications • 15% instability • 10.8% infection • 6.5% glenoid loosening
Samuelsen et al. <sup>66</sup> (n = 67)	CTA 76% 22% OA Mean 60 yrs <sup>50–65</sup> 59.7% men	Four RSA implants 59.7% uncemented	Mean 36 (24–96)	ASES SST Pain 1 to 5 ROM Radiographs	ASES 62±16 SST 5.9±3 Radiographs • 18% notching • 3% glenoid lucency	3% revision rates • 1.5% Infection • 1.5% Instability Survivorship • 99% at 2 years • 91% at 5 years 15% Complications • 7.4% instability, 3% required revision • 4.5% infections • 1.5% Humeral fracture • 1.5% nerve palsy
Muh et al. <sup>67</sup> (n = 67)	CTA 59.7% Failed primary 13.4% Inflammatory 14.9% Post traumatic 6% Mean 52.2 yrs <sup>23–60</sup> 37/66 men	Grammont design reverse shoulder prosthesis (Tornier, Saint-Ismier, France)	Mean 36.5 <sup>24–77</sup>	ASES VAS pain score ROM Radiographs	ASES 40 to 72.4 VAS pain 7.5 to 3.0 81% patients were either very satisfied or satisfied Scapula notching 43% • Grade 1 32.8% • Grade 2 7.5% • Grade 3 3%	15% Complications • 7.4% instability, 3% required revision • 4.5% infections • 1.5% Humeral fracture • 1.5% nerve palsy

Abbreviations: SSV – subjective shoulder value, ROM – range of motion, HA - hemiarthroplasty, CTA – cuff tear arthropathy, OA - osteoarthritis, RSA – reverse shoulder arthroplasty, ASES – American Shoulder and Elbow Surgeons score, SST – Simple Shoulder Test, VAS – Visual Analogue Score.

**Table A.9**  
Summary of studies reporting humeral resurfacing

Study	Population	Intervention (s)	Comparator	Follow up	Outcome Measures	Results	Complications
Levy et al. <sup>68</sup> (n = 54)	Mean 38.9 <sup>22–50</sup> 51% men	Copeland resurfacing (Biomet, Swindon, UK) Microfracture of glenoid	TSA with metal-backed glenoid	Mean 174 (120–300)	Constant score SANE Radiographs	Constant • HA 77 • TSA 58.1 ROM • HA FF 78 to 116 • HA abduction 55 to 108 • TSA FF 42 to 93 • TSA Abduction 38 to 81 Radiographs • 58% superior migration • 32% HA glenoid erosion	Revisions 5 TSA • Four loosening • 1 cuff failure 5 HA • 3 cuff failure • 1 glenoid erosion • 1 fracture Overall survivorship HA • 97% at 5 years • 97% at 10 years • 91% at 14 years • 85% at 22 years TSR • 100% at 5 years • 71% at 11 years • 71% at 14 years • 61% at 22 years
Iagulli et al. <sup>69</sup> (n = 48)	Mean 48 yrs <sup>21–59</sup>	Humeral resurfacing - Biomet Copeland prosthesis n = 22 (Warsaw, Indiana, USA). DePuy Global Cap n = 26 (Raynham, Massachusetts, USA)		Mean 72 (48–96)	UCLA score Satisfaction level Radiographs	VAS pain 7 to 1 UCLA 12.24 to 28.12 12.5% glenoid erosion	2% revision rate due to ongoing pain and cuff failure

Abbreviations: TSA – total shoulder arthroplasty, SANE - Single Assessment Numerical Evaluation score, HA - hemiarthroplasty, TSA – total shoulder arthroplasty, FF – forward flexion, UCLA – University California in Los Angeles score, VAS – Visual Analogue Score.

**Table A.10**  
Summary of studies reporting pyrocarbon interposition arthroplasty

Study	Population	Intervention (s)	Follow up	Outcome Measures	Results	Complications
Garret et al. <sup>70</sup> (n = 55)	Mean 50.7 (18–77) 50.7% men	Pyrocarbon arthroplasty - Inspyre implant (Tornier SAS, Montbonnot Saint Martin, France)	Mean 26.8 (24–38)	Constant score	Constant score 34.1 to 66.1 Radiographs • 10.9% Glenoid erosion • 5.4% Tuberosity thinning • 16.4% Humeral medialisation	Implant survival 89.2% at 49.7 months Complications • 3.6% Posterior subluxation • 3.6% Impingement • 3.6% Cuff tears • 1.8% Persistent glenoid pain requiring revision

## References

- Saltzman MD, Mercer DM, Warme WJ, Bertelsen AL, Matsen III FA. Comparison of patients undergoing primary shoulder arthroplasty before and after the age of fifty. *J Bone Joint Surg Am.* 2010;92:42–47.
- Thomas M, Bidwai A, Rangan A, et al. Glenohumeral osteoarthritis. *Shoulder Elbow.* 2016 Jul;8(3):203–214.
- Bijlsma JW. Analgesia and the patient with osteoarthritis. *Am J Therapeut.* 2002;9:189–197.
- Seed SM, Duncan KC, Lynch AM. Osteoarthritis: a review of treatment options. *Geriatrics.* 2009;64:20–29.
- Jawad AS. Analgesics and osteoarthritis: are treatment guidelines reflected in clinical practice? *Am J Therapeut.* 2005;12:98–103.
- Pincus T, Koch G, Lei H, et al. Patient Preference for Placebo, Acetaminophen (paracetamol) or Celecoxib Efficacy Studies (PACES): two randomised, double blind, placebo controlled, crossover clinical trials in patients with knee or hip osteoarthritis. *Ann Rheum Dis.* 2004;63(8):931–939.
- Gross C, Dhawan A, Harwood D, Gochanour E, Romeo A. Glenohumeral joint injections: a review. *Sport Health.* 2013;5:153–159.
- Blaine T, Moskowitz R, Udell J, Skyhar Levin R, Friedlander J, et al. Treatment of persistent shoulder pain with sodium hyaluronate: a randomized, controlled trial. A multicenter study. *J Bone Joint Surg Am.* 2008;90:970–979.
- Green S, Buchbinder R, Hettrick S. Physiotherapy interventions for shoulder pain. *Cochrane Database Syst Rev.* 2003;2:CD004258.
- Buchbinder R, Green S, Youd JM. Corticosteroid injections for shoulder pain. *Cochrane Database Syst Rev.* 2003;1:CD004016.
- Lathia AT, Jung SM, Chen LX. Efficacy of acupuncture as a treatment for chronic shoulder pain. *J Alternative Compl Med.* 2009;15:613–618.
- Jang JS, Choi HJ, Kang SH, Yang JS, Lee JJ, Hwang SM. Effect of pulsed radio-frequency neuromodulation on clinical improvements in the patients of chronic intractable shoulder pain. *J Korean Neurosurg Soc.* 2013;54:507–510.
- Schiebel M, Bartl C, Magosch P, Lichtenberg S, Habermeyer P. Osteochondral autologous transplantation for the treatment of full-thickness articular defects of the shoulder. *J Bone Joint Surg.* 2004;86-B:991–997.
- Romeo AA, Cole BJ, Mazzocca AD, Fox JA, Freeman KB, Joy E. Autologous chondrocyte repair of an articular defect in the humeral head. *Arthroscopy.* 2002;18:925–929.
- Karelse A, Spapens N, Van Tongel A, De Wilde L. Arthroscopic treatment of the young degenerative shoulder joint; is there a role for interpositioning arthroplasty? *Acta Orthop Belg.* 2016;82:339–345.
- Wang KC, Frank RM, Cotter EJ, et al. Long-term clinical outcomes after microfracture of the glenohumeral joint: average 10-year follow-up. *Am J Sports Med.* 2018 Mar;46(4):786–794.
- Millett PJ, Huffard BH, Horan MP, Hawkins RJ, Steadman JR. Outcomes of full-thickness articular cartilage injuries of the shoulder treated with microfracture. *Arthroscopy.* 2009;25:856–863.
- Richards R. Shoulder arthrodesis. In: *Presented at Ninth Combined Meeting of Orthopedic Associations of the English Speaking Worlds.* 1992 Jun (Toronto).
- Padegimas EM, Maltenfort M, Lazarus MD, Ramsey ML, Williams GR, Namdari S. Future patient demand for shoulder arthroplasty by younger patients: national projections. *Clin Orthop Relat Res.* 2015;473:1860–1867.
- Pfahler M, Jena F, Neyton L, Sirveaux F, Mole D. Hemiarthroplasty versus total shoulder prosthesis: results of cemented glenoid components. *J Shoulder Elbow Surg.* 2006;15:14–163.
- Sperling JW, Cofield RH, Rowland CM. Neer hemiarthroplasty and Neer total shoulder arthroplasty in patients fifty years old or less. Long term results. *J Bone Joint Surg Am.* 1998;80:464–473.
- Sperling JW, Cofield RH, Rowland CM. Minimum fifteen-year follow up of Neer hemiarthroplasty and total shoulder arthroplasty in patients age fifty years or younger. *J Shoulder Elbow Surg.* 2004;13:604–613.
- Chen AL, Bain EB, Horan MP, Hawkins RJ. Determinants of patient satisfaction with outcome after shoulder arthroplasty. *J Shoulder Elbow Surg.* 2007;16:25–30.
- Fehringer EV, Kopjar B, Boorman RS, Churchill RS, Smith KL, Matsen 3<sup>rd</sup> FA. Characterising the functional improvement after total shoulder arthroplasty for osteoarthritis. *J Bone Joint Surg Am.* 2002;84:1349–1353.
- Bohsali KI, Wirth MA, Rockwood Jr CA. Complications of total shoulder arthroplasty. *J Bone Joint Surg Am.* 2006;88:2279–2293.
- Raiss P, Bruckner T, Rickert M, Walch G. Longitudinal observational study of total shoulder replacements with cement: fifteen to twenty year follow up. *J Bone Joint Surg.* 2014;96:198–205.
- Rispoli DM, Sperling JW, Athwal GS, Schleck CD, Cofield RH. Humeral head replacement for the treatment of osteoarthritis. *J Bone Joint Surg Am.* 2006;88:2637–2644.
- Levine WN, Djurasovic M, Glasson HM, Pollock RG, Flatow EL, LU Bigliani. Hemiarthroplasty for glenohumeral osteoarthritis: results correlated to degree of glenoid wear. *J Shoulder Elbow Surg.* 1997;6(5):449–454.
- Levine WN, Fischer CR, Nguyen D, Flatow EL, Ahmad CS, LU Bigliani. Long-term follow-up of shoulder hemiarthroplasty for glenohumeral osteoarthritis. *J Bone Joint Surg Am.* 2012;94(22):e164.
- Amstutz HC, Campbell P, Kossovsky N, Clarke IC. Mechanism and clinical significance of wear debris induced osteolysis. *Clin Orthop.* 1992;276:7–18.
- Radnay CS, Setter KJ, Chambers L, Levine WN, LU Bigliani, Ahmad CS. Total shoulder replacement compared with humeral head replacement for the treatment of primary glenohumeral osteoarthritis: a systematic review. *J Shoulder Elbow Surg.* 2007;16:396–402.
- Edwards TB, Kadakia NR, Boulahia A, et al. A comparison of hemiarthroplasty and total shoulder arthroplasty in the treatment of primary glenohumeral osteoarthritis results of a multicentre study. *J Shoulder Elbow Surg.* 2003;12, 2:7–213.
- Bryant D, Litchfield R, Sandow M, Gartsman GM, Guyatt G, Kirkley A. A comparison of pain, strength, range of motion and functional outcomes after hemiarthroplasty and total shoulder arthroplasty in patients with osteoarthritis of the shoulder. A systematic review and meta-analysis. *J Bone Joint Surg Am.* 2005;87:1947–1956.
- Favard L, Leveigne C, Nerot C, Gerber C, De Wilde L, Mole D. Reverse prostheses in arthropathies with cuff tear: are survivorship and function maintained over time? *Clin Orthop Relat Res.* 2011;469:2469–2475.
- Guery J, Favard L, Sirveaux F, Oudet D, Mole D, Walch G. Reverse total shoulder arthroplasty. Survivorship analysis of eighty replacements followed for five to ten years. *J Bone Joint Surg Am.* 2006;88:1742–1747.
- Raiss P, Aldinger PR, Kasten P, Rickert M, Loew M. Total shoulder replacement in young and middle-aged patients with glenohumeral osteoarthritis. *J Bone Joint Surg Br.* 2008;90:764–769.
- Singh JA, Sperling JW, Cofield RH. Revision surgery following total shoulder arthroplasty: analysis of 2588 shoulders over three decades (1976 to 2008). *J Bone Joint Surg Br.* 2011;93:1513–1517.
- Sperling JW, Cofield RH. Revision total shoulder arthroplasty for the treatment of glenoid arthrosis. *J Bone Joint Surg Am.* 1998;80:860–867.
- Carroll RM, Izquierdo R, Vazquez M, Blaine TA, Levine WN, LU Bigliani. Conversion of painful hemiarthroplasty to total shoulder arthroplasty: long-term results. *J Shoulder Elbow Surg.* 2004;13:599–603.
- Moher D, Liberati A, Tetzlaff J, Altman DG. The PRISMA Group. Preferred reporting items for systematic reviews and meta-analysis: the PRISMA statement. *BMJ.* 2009;339:25–35.
- Slim K, Nini E, Forestier D, Kwiatkowski F, Panis Y, Chipponi J. Methodological index for non-randomized studies (minors): development and validation of a new instrument. *ANZ J Surg.* 2003;73(9):712–716.
- Burkead WZ, Hutton KS. Biologic resurfacing of the glenoid with hemiarthroplasty of the shoulder. *J Shoulder Elbow Surg.* 1995;4(4):263–270.
- Hammond J, Lin EC, Harwood DP, et al. Clinical outcomes of hemiarthroplasty and biological resurfacing in patients aged younger than 50 years. *J Shoulder Elbow Surg.* 2013;22:1345–1351.
- Muh SJ, Streit JJ, Shishani Y, Dubrow S, Nowinski RJ, Gobeze R. Biologic resurfacing of the glenoid with humeral head resurfacing for glenohumeral arthritis in the young patient. *J Shoulder Elbow Surg.* 2014;23:e185–e190.
- Puskas GJ, Meyer DC, Lebschi JA, Gerber C. Unacceptable failure of hemiarthroplasty combined with biological glenoid resurfacing in the treatment of glenohumeral arthritis in the young. *J Shoulder Elbow Surg.* 2015;24:1900–1907.
- Lee KT, Bell S, Salmon J. Cementless surface replacement arthroplasty of the shoulder with biologic resurfacing of the glenoid. *J Shoulder Elbow Surg.* 2009;18:915–919.
- Lo EY, Flanagan BA, Burkhead WZ. Biologic resurfacing arthroplasty with acellular human dermal allograft and platelet-rich plasma (PRP) in young patients with glenohumeral arthritis – average of 60 months of at mid-term follow-up. *J Shoulder Elbow Surg.* 2016;25:e199–e207.
- Strauss EJ, Verma NN, Salata MJ, et al. The high failure rate of biologic resurfacing of the glenoid in young patients with glenohumeral arthritis. *J Shoulder Elbow Surg.* 2014;23:409–419.
- Bois AJ, Whitney IJ, Somerson JS, Wirth MA. Humeral head arthroplasty and meniscal allograft resurfacing of the glenoid. *J Bone Joint Surg Am.* 2015;97:1571–1577.
- Elhassan B, Ozbaydar M, Diller D, Higgins LD, Warner JP. Soft-tissue resurfacing of the glenoid in the treatment of glenohumeral arthritis in active patients less than fifty years old. *J Bone Joint Surg Am.* 2009;91:419–424.
- Wirth MA. Humeral head arthroplasty and meniscal allograft resurfacing of the glenoid. *J Bone Joint Surg Am.* 2009;91:1109–1119.
- Saltzman MD, Chamberlain AM, Mercer DM, Warme WJ, Bertelsen AL, Matsen III FA. Shoulder hemiarthroplasty with concentric glenoid reaming in patients 55 years old or less. *J Shoulder Elbow Surg.* 2011;20:609–615.
- Somerson JS, Wirth MA. Self-assessed and radiographic outcomes of humeral head replacement with nonprosthetic glenoid arthroplasty. *J Shoulder Elbow Surg.* 2015;24:1041–1048.
- Getz CL, Kearns KA, Padegimas EM, Johnston PS, Lazarus MD, Williams GR. Survivorship of hemiarthroplasty with concentric glenoid reaming for glenohumeral arthritis in young, active patients with a biconcave glenoid. *J Am Acad Orthop Surg.* 2017;25(10):715–723.
- Lynch JR, Franta AK, Montgomery WH, Lenters TR, Mounce D, Matsen III FA. Self-assessed outcome at two to four years after shoulder hemiarthroplasty with concentric glenoid reaming. *J Bone Joint Surg Am.* 2007;89:1284–1292.
- Bartelt R, Sperling JW, Schleck CD, Cofield RH. Shoulder arthroplasty in patients aged fifty-five years of younger with osteoarthritis. *J Shoulder Elbow Surg.* 2011;20:123–130.
- Denard PJ, Raiss P, Sowa B, Walch G. Mid- to long-term follow-up of total shoulder arthroplasty using a keeled glenoid in young adults with primary glenohumeral arthritis. *J Shoulder Elbow Surg.* 2013;22:894–900.
- Gauci MO, Bonneville N, Moineau G, Baba M, Walch G, Boileau. Anatomical

- total shoulder arthroplasty in young patients with osteoarthritis, all-polyethylene versus metal-backed glenoid. *Bone Joint Lett J*. 2018;100:485–492.
59. Kusnezov N, Waterman BR, Parada S. Clinical outcomes of anatomical total shoulder arthroplasty in a young, active population. *Am J Orthoped*. 2016;45(5):E273–E282.
  60. Hartzler RU, Melapi S, de Beer JF, Burkhart SS. Arthroscopic joint preservation in severe glenohumeral arthritis using interpositional human dermal allograft. *Arthroscopy*. 2017;33(11):1920–1925.
  61. Savoie FH, Brislin KJ, Argo D. Arthroscopic glenoid resurfacing as a surgical treatment for glenohumeral arthritis in the young patient: midterm results. *Arthroscopy*. 2009;25(8):864–871.
  62. Kerr BJ, McCarty EC. Outcome of arthroscopic debridement is worse for patients with glenohumeral arthritis of both sides of the joint. *Clin Orthop Relat Res*. 2008;466:634–638.
  63. Millett PJ, Horan MP, Pennock AT, Rios D. Comprehensive arthroscopic management (CAM) Procedure: clinical results of a joint-preserving arthroscopic treatment for young, active patients with advanced shoulder osteoarthritis. *Arthroscopy*. 2013;29(3):440–448.
  64. Van Thiel GS, Sheehan S, Frank RM, et al. Retrospective analysis of arthroscopic management of glenohumeral degenerative disease. *Arthroscopy*. 2010;26(11):1451–1455.
  65. Ek ETH, Neukom L, Catanzaro S, Gerber C. Reverse total shoulder arthroplasty for massive irreparable rotator cuff tears in patients younger than 65 years old: results after five to fifteen years. *J Shoulder Elbow Surg*. 2013;22:1199–1208.
  66. Samuelson BT, Wagner ER, Houdek MT, et al. Primary reverse shoulder arthroplasty in patients aged 65 years or younger. *J Shoulder Elbow Surg*. 2017;26:e13–e17.
  67. Muh SJ, Streit JJ, Wanner JP, et al. Early follow-up of reverse total shoulder arthroplasty in patients sixty years of age or younger. *J Bone Joint Surg Am*. 2013;95:1877–1883.
  68. Levy O, Tsvieli O, Merchant J, et al. Surface replacement arthroplasty for glenohumeral arthropathy in patients aged younger than fifty years: results after a minimum ten-year follow-up. *J Shoulder Elbow Surg*. 2015;24:1049–1060.
  69. Iagulli ND, Field LD, Hobgood ER, et al. Surface replacement arthroplasty of the humeral head in young active patients – midterm results. *The Orthopaedic Journal of Sports Medicine*. 2014;2(1):1–7.
  70. Garrett J, Godeneche A, Boileau P, et al. Pyrocarbon interposition shoulder arthroplasty: preliminary results from a prospective multicentre study at 2 years of follow-up. *J Shoulder Elbow Surg*. 2017;26:1143–1151.
  71. Levy O, Copeland SA. Cementless surface replacement arthroplasty (Copeland CSRA) for osteoarthritis of the shoulder. *J Shoulder Elbow Surg*. 2004;13(3):266–271.
  72. 14<sup>th</sup> National Joint Registry for England and Wales Annual Report. 2017.
  73. Werner BS, Stehle J, Abdelkawi A, Plumhoff P, Hudek R, Gohlke F. Progressive glenoid bone loss caused by erosion in humeral head resurfacing. *Orthopä*. 2017;46(12):1028–1033.
  74. Geervliet PC, van den Bekerom MPJ, Spruyt P, Curvers M, van Noort A, Visser CPJ. Outcome and revision rate of uncemented glenohumeral resurfacing (C.A.P.) after 5–8 years. *Arch Orthop Trauma. Surgery (St Louis)*. 2017;137(6):771–778.
  75. Carroll RM, Izquierdo R, Vazquez M, Blaine TA, Levine WN, LU Bigliani. Conversion of painful hemiarthroplasty to total shoulder arthroplasty: long-term results. *J Shoulder Elbow Surg*. 2004;13(6):599–603.
  76. Bansal A, Khatib ON, Zuckerman JD. Revision total joint arthroplasty: the epidemiology of 63,140 cases in New York State. *J Arthroplasty*. 2014;29:23–27.
  77. Carpenter SR, Urrits I, Murthi AM. Porous metals and alternate bearing surfaces in shoulder arthroplasty. *Curr Rev Musculoskelet Med*. 2016;9:59–66.
  78. Clarke IC, Gustafson A. Clinical and hip simulator comparisons of ceramic-on-polyethylene and metal-on-polyethylene wear. *Clin Orthop Relat Res*. 2000;379:34–40.
  79. Hu D, Tie K, Yang X, Tan Y, Alaidaros M, Chen L. Comparison of ceramic-on-ceramic to metal-on-polyethylene bearing surfaces in total hip arthroplasty: a meta-analysis of randomized controlled trials. *J Orthop Surg Res*. 2015;10:22.
  80. Capello WN, D'Antonio JA, Feinberg JR, Manley MT, Naughton M. Ceramic-on-ceramic total hip arthroplasty: update. *J Arthroplasty*. 2008;23:39–43.
  81. Mueller U, Braun S, Schroeder S, et al. Influence of humeral head material on wear performance in anatomic shoulder joint arthroplasty. *J Shoulder Elbow Surg*. 2017;26(10):1756–1764.
  82. Boileau P, Avidor C, Krishan SG, Walch G, Kempf JF, Mole D. Cemented polyethylene versus uncemented metal-backed glenoid components in total shoulder arthroplasty: a prospective, double-blind, randomised study. *J Shoulder Elbow Surg*. 2002;11:351–359.
  83. Young AA, Walch G, Pape G, Gohlke F, Favard L. Secondary rotator cuff dysfunction following total shoulder arthroplasty for primary glenohumeral osteoarthritis: results of a multicentre study with more than five years of follow up. *J Bone Joint Surg Am*. 2012;94:685–693.
  84. Gupta S, van der Helm FCT, van Keulen F. The possibilities of uncemented glenoid component a finite element study. *Clin Biomech*. 2004;19:292–302.
  85. Gupta S, van der Helm FCT, van Keulen F. Stress analysis of cemented glenoid prostheses in total shoulder arthroplasty. *J Biomech*. 2004;37:1777–1786.
  86. Pelletier MH, Langdown A, Gillies RM, Sonnabend DH, Walsh WR. Photoelastic comparison of strains in the underlying glenoid with metal-backed and all-polyethylene implants. *J Shoulder Elbow Surg*. 2008;17:779–783.
  87. Cofield RH. Uncemented total shoulder arthroplasty. A review. *Clin Orthop Relat Res*. 1994;307:86–93.
  88. Taunton MJ, McIntosh AL, Sperling JW, Cofield RH. Total shoulder arthroplasty with a metal-baked, bone ingrowth glenoid component. Medium to long-term results. *J Bone Joint Surg Am*. 2008;90:2180–2199.
  89. Sweet SJ, Takara T, Ho L, Tibone JE. Primary partial humeral head resurfacing: outcomes with the HemiCAP implant. *Am J Sports Med*. 2015 Mar;43(3):579–587.



## Review article

## The management of glenoid bone loss in shoulder arthroplasty

Steven Kyriacou, Sirat Khan, Mark Falworth\*

Shoulder and Elbow Unit, Royal National Orthopaedic Hospital NHS Trust, Brockley Hill, Stanmore, Middlesex, HA7 4LP, UK



## ARTICLE INFO

## Article history:

Received 29 November 2018

Accepted 22 December 2018

Available online 26 December 2018

## ABSTRACT

Glenoid bone loss in shoulder arthroplasty poses a significant challenge for the surgeon managing this cohort of patients in both the primary and revision settings. This review article aims to review the methods of assessing glenoid bone loss and to report on the various techniques available to address it in both anatomical and reverse shoulder arthroplasty surgery.

© 2018 International Society for Knowledge for Surgeons on Arthroscopy and Arthroplasty. Published by Elsevier, a division of RELX India, Pvt. Ltd. All rights reserved.

## 1. Introduction

Shoulder arthroplasty is a reliable method in treating the symptoms associated with glenohumeral arthritis. The incidence of shoulder arthroplasty is increasing, however, the management of glenoid bone loss remains problematic and is associated with poorer clinical outcomes, instability and reduced implant survivorship.<sup>1</sup>

Glenoid bone loss can result in poor initial fixation and mal-positioning of the glenoid component of an anatomic shoulder replacement which in turn may lead to eccentric loading and accelerated polyethylene wear as well as premature loosening.<sup>2–5</sup> Indeed, Farron et al. reported >700% increase in micro-motion at the cement-bone interface and a 326% increase in contact stresses when the glenoid component is implanted in >10° retroversion.<sup>3</sup> This is relevant as up to 15% of patients with glenohumeral arthritis have posterior glenoid bone loss significant enough to make implantation of the glenoid prosthesis questionable without addressing the deficit.<sup>6</sup> This figure is significantly higher in the context of revision shoulder arthroplasty, and the loss of glenoid bone stock in Reverse Shoulder Arthroplasty (RSA) can also result in poorer outcomes.<sup>7,8</sup>

The risk of premature implant loosening and failure can be reduced with accurate pre-operative planning, correction of glenoid version and precise implant positioning and fixation.<sup>2</sup> The aim of this review is to provide an overview of the classification and investigation of glenoid bone loss in shoulder arthroplasty and to review the surgical strategies currently available to manage it.

## 2. Classification of glenoid bone loss

## 2.1. Primary glenoid bone loss

The characteristic wear pattern observed in glenohumeral osteoarthritis is one of posterior glenoid erosion associated with posterior humeral head subluxation. A second concavity may be formed when the bone loss associated with erosion is severe thus forming a biconcave deformity. Based on the patterns of wear observed from radiographs and CT scans of 151 patients with glenohumeral arthritis, Walch et al. proposed a classification system based upon the three glenoid morphologies observed.<sup>6</sup>

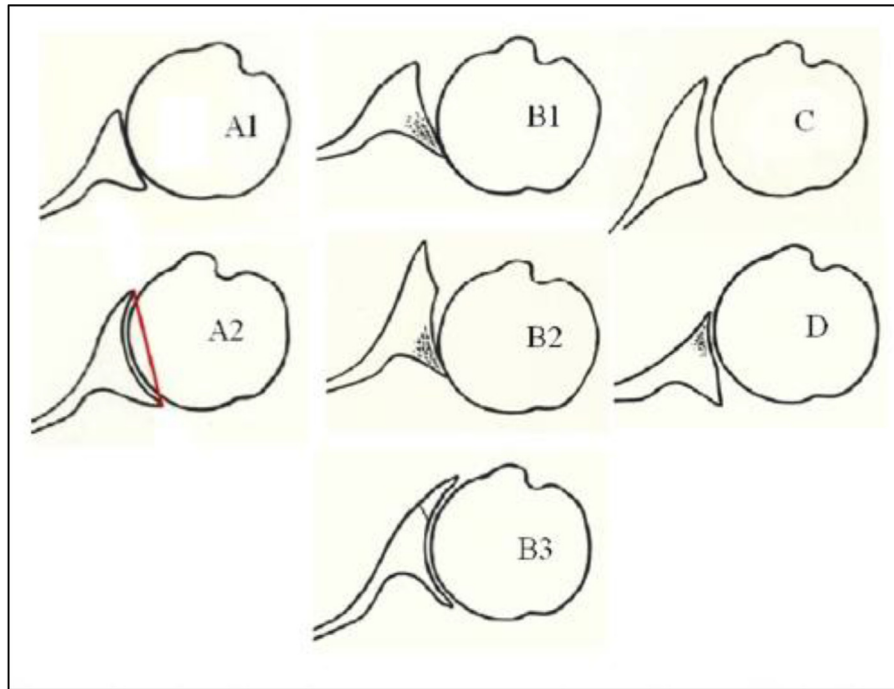
Type A (59%) was defined as central glenoid erosion with a centred humeral head. This was further subdivided based on the severity of erosion into A1 (minor) or A2 (major). Type B (32%) was defined as posterior humeral head subluxation and was further subdivided into B1 (joint space narrowing, subchondral sclerosis and osteophytes) and B2 (biconcave glenoid with posterior rim erosion). Type C (9%) was defined as glenoid retroversion >25° which is primarily dysplastic in origin. Bercik et al.<sup>9</sup> proposed the addition of a B3 and D glenoids with the B3 defined as mono-concave with pathologic retroversion of at least 15° or subluxation of 70%, or both (Fig. 1).

## 2.2. Secondary glenoid bone loss

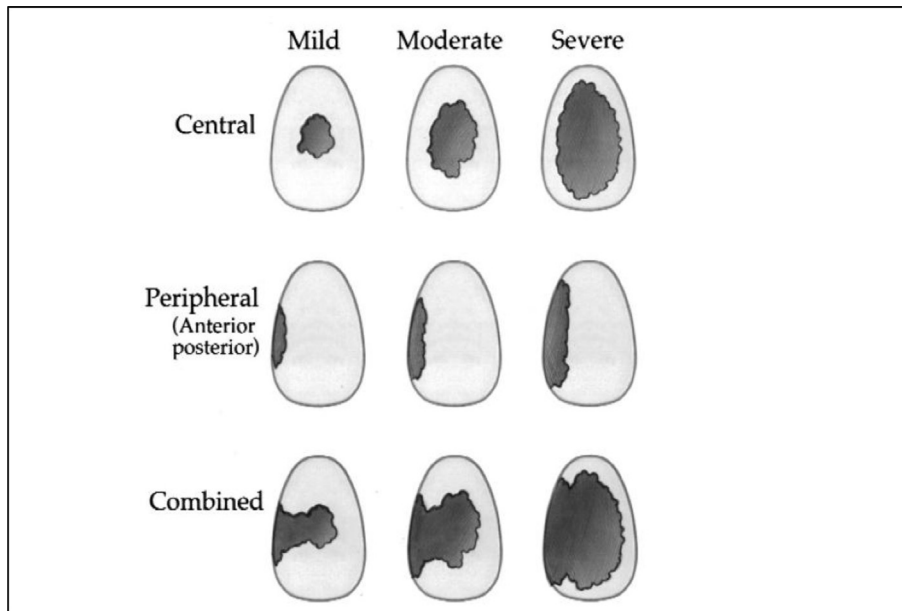
Secondary glenoid bone loss may occur due to trauma, infection, glenoid component loosening and in the setting of revision arthroplasty.<sup>10</sup> Intra-operative glenoid bone loss encountered during revision shoulder arthroplasty was classified by Antuna et al. as central, peripheral and combined with each classification being further subdivided into mild, moderate or severe (Fig. 2).<sup>11</sup>

\* Corresponding author.

E-mail address: [msfalworth@yahoo.com](mailto:msfalworth@yahoo.com) (M. Falworth).



**Fig. 1.** Modified Walch Classification of glenoid erosion in primary glenohumeral arthritis. (Reprinted with permission from Elsevier from Bercik MJ, Kruse K, Yalozis M, Gauci M, Chaoui J, Walch G. A Modification to the Walch classification of the glenoid in primary glenohumeral osteoarthritis using three dimensional imaging. J Shoulder Elbow Surg. 2016 Oct; 25(10):1601–6.



**Fig. 2.** Antuna classification of glenoid bone deficiencies after glenoid component removal (Reprinted with permission from Elsevier from Antuna SA, Sperling JW, Cofield RH, Rowland CM. Glenoid revision surgery after total shoulder arthroplasty. Journal of shoulder and elbow surgery. 2001; 10(3):217–24.).

**3. Aetiology of posterior glenoid bone loss**

Posterior glenoid bone loss commonly observed in osteoarthritic shoulders is thought to be initiated by posterior subluxation of the humeral head that may result in eccentric glenoid erosion due to increased, asymmetric posterior glenohumeral contact forces.<sup>12</sup> The finding of pre-osteoarthritic posterior subluxation of the humeral head was recently described by Domos et al. as the

‘Walch B0’ glenoid.<sup>13</sup> The aetiology of posterior humeral head subluxation however remains controversial and incompletely understood.

Walch et al. were the first to describe static posterior subluxation of the humeral head as a possible causative factor of glenohumeral osteoarthritis and hypothesized increased glenoid retroversion (mean value of 15°) was most likely reason for this occurring.<sup>14</sup> Knowles et al. similarly reported that patients with a



B2 osteoarthritic glenoid have 'significantly greater pre-morbid glenoid retroversion', suggesting this may be a contributing factor to posterior erosion.<sup>12</sup> However, other studies have questioned the link between pre-morbid glenoid retroversion and posterior glenoid erosion.<sup>15–17</sup> Based upon this conflicting evidence, Doms et al. postulated posterior humeral head subluxation may be multifactorial and related to a combination of bone and soft tissue factors including rotator cuff muscle imbalance and possible anterior capsular stiffness.<sup>13</sup>

#### 4. Pre-operative planning in glenoid bone loss

The assessment of glenoid version and bone loss is essential when planning shoulder arthroplasty, as failure to do so may lead to intra-operative difficulties and poor outcomes due to inadequate correction of the deformity.<sup>18</sup> Pre-operative planning with plain radiographs is recommended and although glenoid bone loss and posterior humeral head subluxation can be appreciated on the axillary view, the use of radiographs alone may overestimate retroversion in 86% of cases.<sup>19</sup> Therefore in the presence of glenoid bone loss and retroversion, CT imaging is recommended to more accurately assess the glenoid anatomy.<sup>20</sup>

Glenoid version can be determined using standard two-dimensional (2D) axial CT slices along the plane of the scapula at the level of the coracoid tip using a method described by Friedman et al.<sup>21</sup> The scapula axis reference line is drawn from the tip of the medial border of the scapula to the centre of the glenoid. A second line, the glenoid line, is drawn from the anterior to the posterior glenoid rim and glenoid version is then measured as the angle between the glenoid line and the line perpendicular to the scapular axis (Fig. 3).

However, this technique is reliant on the 2D analysis of a three-dimensional (3D) structure and is dependent on the assumption that the anatomy of the scapula axis, and both the anterior and posterior glenoid rim, are all representative of normal pre-degenerative anatomy. The anterior glenoid is therefore a critical landmark in the assessment of posterior bone loss. A CT scan demonstrating the medial border of the scapula is also necessary and the position and angle of the CT scanner gantry is a factor in accurate interpretation of the Friedman version angle.<sup>22</sup>

As an alternative, 3D CT imaging can be used. In the Vault model method, 3D CT images can be constructed from the standard 2D CT images such that normal glenoid version was noted to be 1.63° of

retroversion.<sup>23</sup> However, it also revealed that the shape of the glenoid vault was a highly congruent fit in normal glenoids and could be used to assess pathological glenoid bone loss.<sup>24</sup> Bicknell et al. also reported that the shape of the glenoid vault was consistent irrespective of age, sex or side and that the transverse and coronal planes of the glenoid were not altered in the presence of osteoarthritis.<sup>25</sup> This consistency in vault size can therefore be used in generating a vault model which can be aligned to the native vault that has not been affected by the arthritic process, thereby estimating the bone loss without the necessity of a scan of the contralateral side, which itself may be abnormal.<sup>24,26</sup>

The vault model has also been adapted into an alternative technique termed the glenoid vault method, which utilizes 3D reconstructed slices. Glenoid version is measured as the angle between the glenoid line and the line perpendicular to the glenoid vault axis. Using this method Matsumura et al. reported that the average glenoid retroversion in a normal shoulder using the conventional Friedman technique was  $1.1^{\circ} \pm 3.2^{\circ}$  compared to  $8.9^{\circ} + 2.7^{\circ}$  using the vault method suggesting that the Friedman technique may underestimate the severity of bone loss in the arthritic population.<sup>27</sup> However, this has not been confirmed in other studies and there is therefore no consensus as to which would be the most reliable way to assess version and bone loss, although there is increasing evidence that greater accuracy and reliability may be achieved with the use of 3D CT images and the vault model.<sup>24,28,29</sup>

#### 5. The surgical management of glenoid bone loss

Although shoulder arthroplasty for the treatment of glenohumeral arthritis has in general demonstrated excellent long term outcomes, the management of significant glenoid erosion, and in particular the B2 glenoid, has been associated with less favourable outcomes, increased complication rates, ongoing posterior instability and reduced implant survivorship.<sup>2,5,30,31</sup>

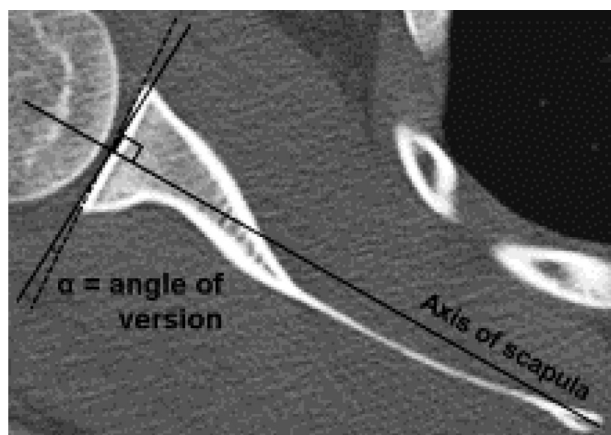
The degree of glenoid bone loss and its location is variable and will determine the technique used to address the deficit. In general, posterior bone loss is encountered in glenohumeral osteoarthritis, anterior bone loss in chronic anterior glenohumeral instability and superior defects in rotator cuff arthropathy. Global defects may be encountered in the revision setting.<sup>8</sup> The choice of technique to address the bone loss is based on the size and location of the deficit.

##### 5.1. Hemiarthroplasty

Total shoulder arthroplasty (TSA) is perceived to be the best treatment option for the management of shoulder arthritis.<sup>32</sup> However, hemiarthroplasty remains a viable treatment option in certain patient cohorts, particularly the young patient with concentric arthritis and in those with minimal glenoid wear.<sup>33</sup> It can also be advocated in those patients where there is insufficient glenoid bone stock for the implantation of a glenoid prosthesis, however, by not addressing the glenoid, pain and continued glenoid bone erosion may continue such that poor outcomes can be reported.<sup>34</sup>

The use of alternative materials for the humeral head, such as ceramic or Pyrolytic carbon (PyC), has been advocated, however there is currently no evidence to support their use over conventional materials.<sup>35,36</sup>

The use of a conventional hemiarthroplasty in conjunction with concentric reaming of the glenoid to correct glenoid version, has also been postulated as way to avoid the use of a glenoid implant in the younger patient.<sup>37,38</sup> The aim of a non-prosthetic glenoid arthroplasty, also known as 'Ream and Run', is to not only correct the version, but also to stimulate the formation of a fibrocartilage



**Fig. 3.** Friedman method of calculating glenoid version (Reprinted with permission from Elsevier from Poon PC, Ting FS. A 2-dimensional glenoid vault method for measuring glenoid version on computed tomography. *J Shoulder Elbow Surg.* 2012 Mar; 21(3):329–35.

covering to the glenoid, which in a canine model can form by 24 weeks.<sup>39</sup> As an alternative, concentric reaming can also be combined with an interposition arthroplasty.<sup>40</sup> Long term outcomes with both of these cohorts are however mixed and patient selection is critical.<sup>41–43</sup>

### 5.2. Eccentric reaming

The most common method of managing the glenoid erosion in anatomical TSA, including of a B2 glenoid, is currently eccentric reaming with the use of a standard glenoid component.<sup>44</sup> This technique, also termed 'high side reaming', involves reaming the glenoid to correct glenoid version whilst also re-creating a concentric socket.<sup>31</sup> However, correcting the glenoid to within 5° of its ideal version may be difficult.<sup>45,46</sup>

It is widely accepted that eccentric reaming alone may be used to correct glenoid retroversion up to 15° or posterior bone loss less than 8 mm.<sup>2,47–50</sup> Although this technique medialises the joint line, a small degree of medialisation can be corrected by choosing an implant of appropriate thickness to recreate the native joint line.<sup>44</sup> However, excessive medialisation may result in complications due to the loss of glenoid bone stock.

Violation of the subchondral plate diminishes the cortical support critical to the stability of the glenoid prosthesis and may therefore lead to an increased risk of implant loosening and subsidence.<sup>45,51–53</sup> Cortical penetration of the glenoid implant due to narrowing of the glenoid vault, may occur and with progressive medialisation, the narrowing of the glenoid also leads to a reduced area of bone available for implantation of the glenoid implant.<sup>49,54</sup> As a result, the use of a smaller glenoid component may be necessary, which may in turn lead to a radial mismatch with the humeral head replacement. Excessive medialisation may also lead to inadequate tensioning of the rotator cuff muscles and therefore a poorer functional outcome and an increased risk of instability. Indeed, Walsh et al. reported that of 92 B2 glenoids managed with a TSA, 16.3% required revision surgery. 21% of cases demonstrated radiological glenoid loosening with 6.5% of the 92 requiring revision for loosening, a further 5.4% for posterior dislocation and 4.3% for other complications.<sup>30</sup>

### 5.3. Anatomic total shoulder arthroplasty with bone grafting

In cases where glenoid bone loss and retroversion are too great to correct with eccentric reaming alone, the use of bone grafting may be considered. The exact technique utilised is dependent upon the nature of the defect. Contained, central defects are amenable to impaction grafting however peripheral or combined defects are more challenging and require internal fixation of the bone graft to the native glenoid.<sup>55</sup> It is particularly indicated in cases involving more than 1 cm of posterior bone loss.<sup>45</sup> Resected humeral head, iliac crest autograft and allograft may all be utilised and may be performed as a one or two stage procedure. However, results of studies reporting glenoid bone grafting in TSA have been mixed.

The use of cancellous morsalised graft for central contained glenoid defects with a standard polyethylene glenoid implant has been reported with some success although more peripheral and uncontained defects pose more of a challenge.<sup>49</sup> In such cases block autograft has been secured to the native glenoid with screw fixation or by impaction. In a series reported by Sebesan et al., 12 patients who received a TSA with an all polyethylene glenoid and with a minimum of 24 months follow up, demonstrated graft healing in 83% of cases.<sup>56</sup>

However, differing results are reported when a mixture of all polyethylene and metal back glenoid implants are used. Steinman et al. demonstrated that in 28 shoulders with an average follow up

of 63 months, 54% demonstrated evidence of lucency around the glenoid implant but that only 10% were considered to be radiographically loose.<sup>57</sup> Similarly, Klika et al. reported on 25 shoulders with a mean clinical follow up of 8.7 years where 92% of shoulders demonstrated a good clinical outcome despite 40% of glenoids being deemed at risk of failure.<sup>58</sup> Furthermore, Hill and Norris reported on 8 of 17 patients who had internally fixed glenoid bone graft with unsatisfactory functional results at long term follow up.<sup>59</sup>

What is not clear however, is whether these less than favourable results are secondary to the use of metal back glenoid implants, which have been shown to have increased polyethylene wear rates as compared to all polyethylene implants.<sup>60</sup> Furthermore, new 'platform' metalback glenoid implants such as the Universal Glenoid (Arthrex Inc, Naples, FL, USA) are now being released that may have the potential to allow some compression of a graft onto the native glenoid whilst also being retained in the later conversion to a reverse shoulder replacement. Although there is no data available as to the efficacy of these implants, they may offer a potential solution in the future.


Irrespective of what type of glenoid component is used, the need to perform bone grafting in conjunction with glenoid prosthesis implantation increases the risk of failure and some degree of radiographic lucency may be evident in over 50% of cases even in clinically asymptomatic patients.<sup>2,50,57,58</sup>

### 5.4. Augmented glenoid implants

Due to the limits in correction of glenoid deformity that can be achieved with eccentric reaming or bone grafting, augmented glenoid implants can also be considered. Their use is aimed at restoring glenoid anatomy whilst minimising further bone loss and glenoid medialisation associated with eccentric reaming whilst negating the risk of non-union associated with bone grafting techniques.<sup>61</sup> However, exact preparation of the native glenoid is necessary to accommodate the prosthesis and it is therefore a technically demanding procedure, with suboptimal seating predisposing to increased micro-motion and premature loosening.

Early metal backed wedge shaped glenoid augments were reported to have unacceptably high failure rates with 10 year survivorship as low as 31% thereby leading to their subsequent withdrawal.<sup>61,62</sup> All polyethylene glenoid augments have more recently been introduced and may hold promise for the future. These currently consist of either a posterior wedge shaped design (Exactech, Gainesville, FL, USA) or a posterior step design (DePuy, Warsaw, IN, USA) (Fig. 4a and b).<sup>2</sup> The morphology of the glenoid deformity and the design of the augment may have a significant effect of the forces transferred through the prosthesis, and influence the choice of implant used.<sup>44</sup> Both designs have been shown to be viable in cadaveric and simulation models, with a step-cut design demonstrating greater stability under cyclic eccentric loading by orientating the joint force vector perpendicular to the prosthesis.<sup>55,62–64</sup> This may therefore reduce shear stress at the interface between bone and prosthesis.<sup>65</sup>

There is however currently limited clinical data available regarding the outcomes of glenoid augments. Rice et al. reported the results of fourteen patients with mean follow up of five years treated with a keeled, all-polyethylene posteriorly augmented glenoid prosthesis.<sup>66</sup> The authors noted that although intermediate term pain relief was satisfactory, persistent posterior humeral head subluxation was not always corrected. Favorito et al. reported a series of 22 patients of posterior glenoid bone loss treated with stepped, all-polyethylene augmented glenoid component with 36 months mean follow up in which a statistically significant improvement in outcomes scores was observed as were two cases



**Fig. 4.** **a)** Wedge shaped posterior glenoid augment (Exactech, Gainesville, FL, USA). **(b).** Posterior step design glenoid augment (Depuy, Warsaw, IN, USA).

of prosthetic instability.<sup>67</sup> Trabecular metal augments used in association with a polyethylene glenoid implant have also recently been proposed as a means to correct retroversion of 25° or more with Sandow et al. reporting good outcomes of 10 patients at 24 months follow up.<sup>68</sup>

The use of augmented glenoids may therefore potentially be indicated in cases where glenoid retroversion is > 15°, however long term data is still required to evaluate clinical outcomes and longevity.<sup>69</sup>

### 5.5. Reverse shoulder arthroplasty and bone grafting

Glenoid bone loss is common in Reverse Shoulder Arthroplasty (RSA) in both the primary and revision setting with abnormal glenoid bone wear being reported in up to 38% of cases.<sup>70</sup> Typically superior glenoid erosion is encountered secondary to the migration of the humeral head however posterior wear is also common and more global defects are seen in the revision setting.<sup>71,72</sup> However, the semi-constrained design and decreased reliance on soft tissue balancing, permits RSA to be more tolerant to retroversion and therefore may also minimise the risk of recurrent posterior humeral head subluxation commonly observed when performing anatomic shoulder arthroplasty in patients with a B2 glenoid.<sup>2</sup>

Similar principals to those used in the management of bone loss with anatomical shoulder replacements can be considered. However, one has to be mindful that eccentric reaming can result in excessive medialisation, which may compromise baseplate fixation, result in notching and also adversely affect soft tissue tension such that the stability of the implant is compromised.

Baseplate stability is critical and will be dependent on both patient factors and design features related to the implant itself. The depth and volume of the glenoid is important, with bone loss medial to the coracoid often requiring consideration of bone graft to provide enough support for the baseplate. The size of the glenoid vault is also critical, not only to provide support for the baseplate, but to provide purchase for additional screw fixation. Implant design and the method of fixation of the baseplate, are therefore also important considerations in operative planning.

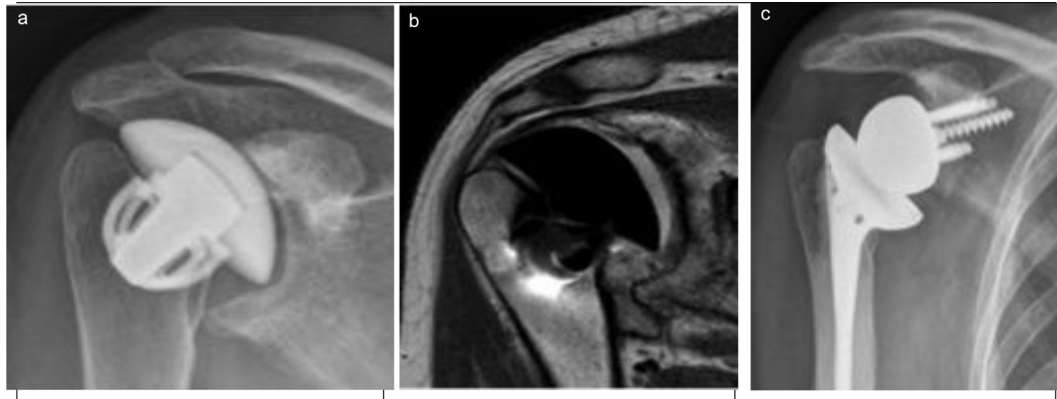
Essentially there are two different baseplate designs utilising either a peg or a central screw. With the peg designs, divergent supplemental screw fixation is advocated to reduce micromotion and therefore an adequate volume of the glenoid vault is needed to accommodate the screws.<sup>73</sup> The central screw designs may be able to avoid this, as the compressive forces generated by the screw provide the primary fixation and compression with additional

parallel locking screws being used to limit shear and torsion. One screw design, the Reverse Shoulder Prosthesis (DJO Global, Austin, TX, USA) generates 2000N of compressive force compared to 200N seen with the Grammont style peg and peripheral screws.<sup>74</sup> Where there is reasonable bone stock, the position of the baseplate can be optimised on the glenoid centerline as described by Matsen, such that bicortical screw fixation should be possible.<sup>75</sup> In instances where there is inadequate bone, an alternative centerline can be used so that the central screw passes along the axis of the scapular spine thereby optimising the bone stock that is available.<sup>76</sup>

The method of glenoid preparation prior to the placement of the graft will vary depending on the implant design and the method of grafting utilised. Adequate baseplate stability must be achieved and in several studies at least 50% contact has been shown to be necessary between the native glenoid and baseplate.<sup>77–79</sup> Depth of the glenoid vault is also important, however this varies depending on implant design. Werner et al. recommended at least 10–15 mm of the baseplate peg should pass into the native glenoid.<sup>77</sup> 10 mm was also the minimum recommended by Malhas et al. whereas Boileau et al. recommended a minimum of 8 mm depth when describing the bone increased offset (BIO) technique.<sup>55,60</sup> In the central screw designs, the use of the alternative glenoid line has been postulated as a technique to enhance implant fixation in cases with excessive bone loss.<sup>76</sup>

Baseplate position and orientation is also important when considering peripheral screw placement. Screws into the coracoid base and lateral scapular column tend to achieve the best fixation. Good graft incorporation has been described with only two peripheral screws in addition to the central peg and biomechanical studies have shown no difference in micro-motion of the baseplate when comparing two-screw and four-screw fixation.<sup>80,81</sup> In addition, screw divergence in the peg designed baseplates, have been shown to have a greater influence on fixation than the diameter or length of the screws.<sup>73</sup> However, this was not noted in the central screw designs, where four peripheral parallel locking screws gave optimal fixation.<sup>74</sup>

The compression of bone graft by the implant may also provide a more favourable environment for graft incorporation.<sup>82</sup> Most glenoid defects can be reconstructed as a single stage procedure. Humeral head autograft is most commonly used in the primary setting although structural allografts may yield equally acceptable results.<sup>82</sup> The size of the bone graft will be determined not only by the extent of the bone defect, but also the soft tissue tensioning. In cases of chronic medialisation, restoration of the normal joint line may not be possible and in such circumstances the use of a larger



**Fig. 5.** ab,c. X-ray (a), and MRI scan (b) revealing significant medialisation of a ceramic head Affinis hemiarthroplasty (Mathys, Switzerland) revised to (c) a Reverse Shoulder Arthroplasty (DJO Global, Austin, TX, USA) with iliac crest autograft whilst preserving the rotator cuff.

glenosphere may help enhance stability and also cover the bone graft.<sup>70,76</sup>

There are multiple published studies regarding RSA with glenoid bone grafting in both primary and revision settings describing satisfactory outcomes.<sup>8,60,71,72,76–78,82–86</sup> Boileau et al. reported humeral head autograft incorporation rates of 98% in a study of 42 patients who underwent a BIO reverse shoulder arthroplasty.<sup>60</sup> Gupta et al. reported a mean increase in Constant score of 61 points in 94 patients with only one implant failure at mean follow up of 2.4 years in patients who had undergone RSA with bone grafting.<sup>78</sup> Similarly, but by using a central screw designed implant, Lorenzetti et al. reported on 57 patients treated with a primary RSA (Reverse Shoulder Prosthesis, DJO Surgical, Austin, TX, USA) with glenoid bone grafting for severe bone loss by using the alternative glenoid line. 98% graft incorporation was reported and no baseplate failures were recorded.<sup>87</sup>

In the revision setting, Wagner et al. described 41 patients who underwent RSA with bone grafting. The survival rate free of radiographic glenoid loosening at two and five years was 92% and 89% respectively. However, the authors noted that 75% of the implants that failed utilised cortico-cancellous rather than structural bone graft.<sup>71</sup> Melis et al. in a series of 29 revision RSAs with either allograft or iliac crest autograft reported a 76% graft incorporation rate and 8% glenoid loosening rate at mean follow up of 47 months.<sup>85</sup>

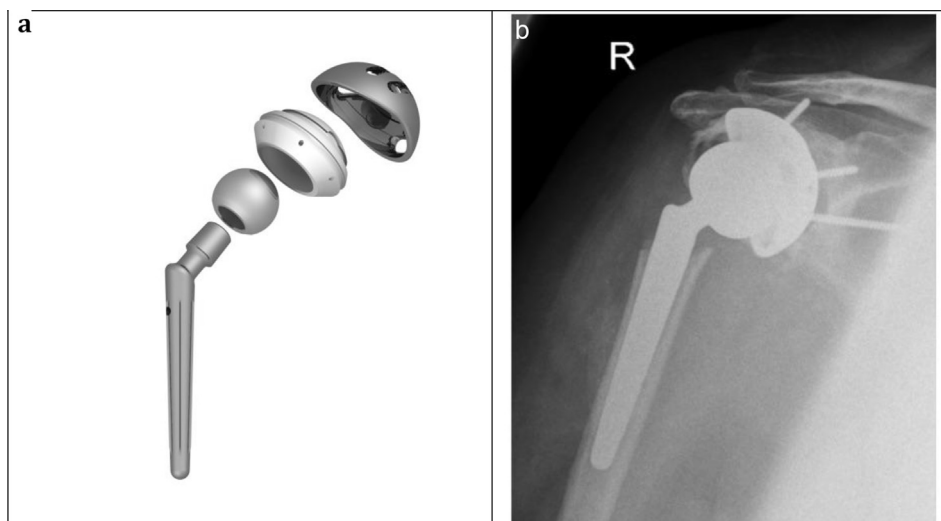
Although the most common indication for RSA remains rotator cuff arthropathy, its use is increasingly also being advocated in cases with significant glenoid bone loss but with an intact rotator cuff including in the B2 glenoid in elderly and low demand patients.<sup>2,31,44,88</sup> It is also becoming the prosthesis of choice in the revision settings (Fig. 5).<sup>31,78</sup>

#### 5.6. Custom made implants

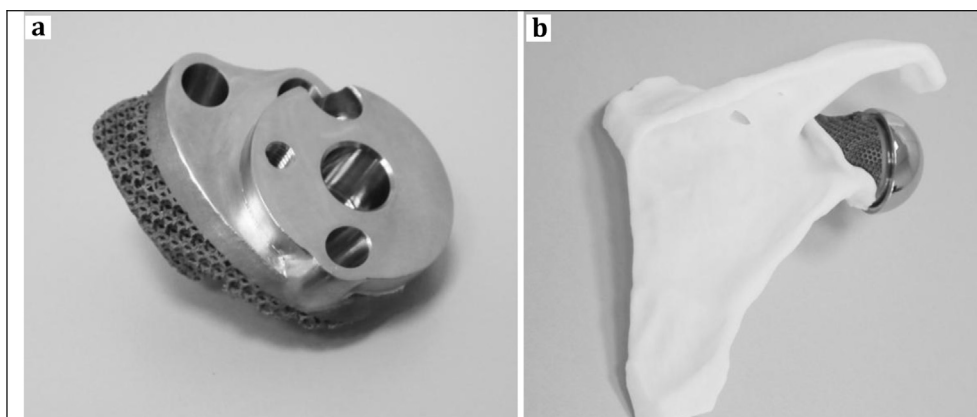
In instances of significant glenoid destruction such that stable fixation of a conventional glenoid baseplate is not technically achievable, the use of a custom made implant may be considered. However, the literature to support their use is currently limited.<sup>89–92</sup>

Computer-aided design and computer-aided manufacturing (CAD CAM) technology can be utilised to create a bespoke glenoid implant. The use of all polyethylene CAD CAM cemented glenoid implants has been suggested but for more challenging cases of glenoid bone loss a CAD CAM glenoid shell has been advocated (Stanmore Implants Worldwide - Stryker, MI, USA) (Fig. 6).<sup>89–92</sup> Chammaa et al. reported a series of 37 patients treated with CAD/CAM total shoulder replacements demonstrating 16% revision rate and 1 case of glenoid loosening at 5 year follow up.<sup>89</sup>

More recently, advances in 3D printing technology now make it possible to manufacture an implant which precisely matches the



**Fig. 6. a,b.** (a & b) CAD CAM Glenoid shell and humeral stem (Stanmore Implants Worldwide - Stryker, MI, USA).



**Fig. 7. a,b.** (a & b) 3D printed CAD CAM glenoid baseplate - Glenius Glenoid Reconstruction System (Materialise NV, Leuven, Belgium).

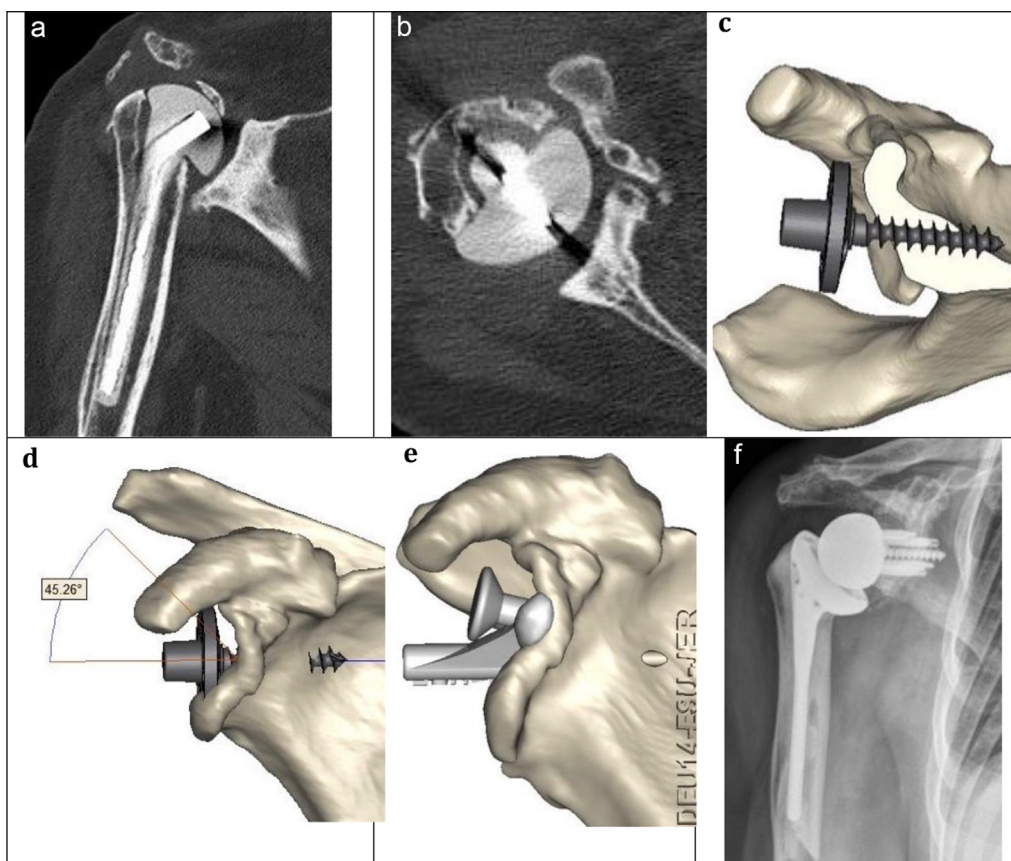
glenoid deformity of an individual patient and facilitates incorporation of an osteoconductive porous structure to promote osteointegration; Glenius Glenoid Reconstruction System (Materialise NV, Leuven, Belgium) (Fig. 7). Although this holds much promise for the future, evidence to support their use is currently limited.<sup>90</sup>

#### 5.7. Computer planning software and patient-specific instrumentation

Computer planning software and patient-specific instrumentation (PSI) may facilitate improved accuracy of glenoid component

implantation, especially in challenging cases with significant glenoid bone loss and deformity.<sup>93</sup> Planning software enables the surgeon to optimise positioning of the desired glenoid implant and there have been multiple recent publications demonstrating its use can lead to more accurate orientation of the glenoid components.<sup>50,94–97</sup> Furthermore, poor glenosphere position in RSA can be associated with a limited arc of movement due to impingement, increased scapular notching, instability and loosening leading to catastrophic failure of the component.<sup>98–100</sup>

Whilst surgical planning can be optimised with the use of computer software, PSI has been developed to facilitate greater accuracy in the intra-operative execution of the pre-operative plan.



**Fig. 8. a-f.** RSP Matchpoint Reverse Shoulder Arthroplasty (DJO Global, Austin, TX, USA) for massive glenoid bone loss. (a) Pre-operative x-ray demonstrating cement spacer with medialisation. (b) Pre-operative CT scan revealing significant glenoid bone loss and posterior retroversion. (c & d) Preoperative planning with RSP baseplate positioned for bicortical fixation and graft compression (Materialise NV, Leuven, Belgium) (e) Matchpoint jig position for central drill hole preparation. (f) Post-operative x-ray following glenoid allograft grafting and RSP insertion.

The principles behind PSI include a pre-operative thin-cut CT scan of the whole scapula and ipsilateral humerus following a pre-defined protocol. The original two-dimensional images are subsequently uploaded to a three-dimensional image processing software system and subsequently converted into a precise three-dimensional model of the patient's scapula. The surgeon then uses pre-operative virtual surgical planning software to optimise the position of the glenoid component in a process that may vary according to each implant manufacturer. A patient specific guide is then designed to fit onto the surface and border of the glenoid such that minimal additional exposure is needed. The sterilisable guide is then manufactured into a 3D stereolithography model with drill cylinders positioned within it to orientate the glenoid preparation/drill hole (Fig. 8).

There are multiple recently published studies reporting improved implant positioning in both cadaveric models and in-vivo using planning software.<sup>97,101–104</sup> However, whilst initial reports are encouraging, the period of post-operative follow is currently insufficient to demonstrate improved patient outcomes and implant survivorship.<sup>93</sup>

### 5.8. Intra-operative navigation

The use of intra-operative navigation is well established in knee arthroplasty although its potential application in shoulder arthroplasty is relatively new and less well understood.<sup>105</sup> Like PSI, intra-operative navigation is designed to help execute the pre-operative plan and potentially enable more accurate implantation of the glenoid component in cases with glenoid deformity. Its theoretical advantages over PSI are that it provides intra-operative feedback and a real-time view of drilling depth, screw placement and implant orientation. It also has the benefit of allowing the surgical plan to be adjusted intra-operatively. Its drawbacks are increased cost, time and technical difficulty due to placement of intra-operative arrays and confirmation of anatomic landmarks. However, like PSI, there is currently limited evidence to support the use of intra-operative navigation in shoulder arthroplasty.<sup>103,106–108</sup> A recent meta-analysis by Sadoghi et al. concluded navigation allows for greater accuracy of glenoid version but the clinical benefit over standard techniques remains as yet, unproven.<sup>105</sup>

## 6. Conclusion

The management of glenoid bone loss in shoulder arthroplasty remains challenging and the recognition of patients with such a deformity pre-operatively is imperative. Such patients require additional pre-operative CT imaging to accurately assess the extent and morphology of glenoid bone loss.

There are varied techniques available to manage this difficult scenario. The evidence to support each is however largely limited to retrospective case series and there is currently no consensus as to the optimum method of treatment. The choice of procedure will therefore depend upon the morphology of the deformity, the patient, the experience of the surgeon and the design of the chosen implant.

Detailed pre-operative planning, an understanding of the indications and limitations of each technique and an appreciation of the intra-operative difficulties that may be encountered are essential to enhance clinical outcomes and minimise complications.

### Role of funding source

The authors and their immediate families did not receive any financial payments or other benefit from any commercial entity

related to this review article. No grants or alternative sources of funding were used in its preparation.

### Declaration of conflicting interests

The authors declare the following potential conflicts of interests with respect to the authorship of this article; Mark Falworth performs a consultancy and educational role with DJO Global and Arthrex.

### References

1. Padegimas EM, Maltenfort M, Lazarus MD, et al. Future patient demand for shoulder arthroplasty by younger patients: national projections. *Clin Orthop Relat Res.* 2015;473(6):1860–1867.
2. Hendel MD, Werner BC, Camp CL, et al. Management of the biconcave (B2) glenoid in shoulder arthroplasty: technical considerations. *Am J Orthoped.* 2016;45(4):220–227.
3. Farron A, Terrier A, Buchler P. Risks of loosening of a prosthetic glenoid implanted in retroversion. *J Shoulder Elbow Surg.* 2006;15(4):521–526.
4. Sears BW, Johnston PS, Ramsey ML, et al. Glenoid bone loss in primary total shoulder arthroplasty: evaluation and management. *J Am Acad Orthop Surg.* 2012;20(9):604–613.
5. Iannotti JP, Norris TR. Influence of preoperative factors on outcome of shoulder arthroplasty for glenohumeral osteoarthritis. *J Bone Joint Surg Am Vol.* 2003;85-a(2):251–258.
6. Walch G, Badet R, Boulahia A, et al. Morphologic study of the glenoid in primary glenohumeral osteoarthritis. *J Arthroplasty.* 1999;14(6):756–760.
7. Riboh JC, Garrigues GE. Bone grafting in shoulder arthroplasty. *Orthopedics.* 2012;35(11):966–973.
8. Tashjian RZ, Granger E, Chalmers PN. Structural glenoid grafting during primary reverse total shoulder arthroplasty using humeral head autograft. *J Shoulder Elbow Surg.* 2018;27(1):e1–e8.
9. Bercik MJ, Kruse 2nd K, Yalozis M, et al. A modification to the Walch classification of the glenoid in primary glenohumeral osteoarthritis using three-dimensional imaging. *J Shoulder Elbow Surg.* 2016;25(10):1601–1606.
10. Gowda A, Pinkas D, Wiater JM. Treatment of glenoid bone deficiency in total shoulder arthroplasty: a critical analysis review. *JBS Rev.* 2015;3(7).
11. Antuna SA, Sperling JW, Cofield RH, et al. Glenoid revision surgery after total shoulder arthroplasty. *J Shoulder Elbow Surg.* 2001;10(3):217–224.
12. Knowles NK, Ferreira LM, Athwal GS. Premorbid retroversion is significantly greater in type B2 glenoids. *J Shoulder Elbow Surg.* 2016;25(7):1064–1068.
13. Domos P, Checchia CS, Walch G, Walch B0 glenoid: pre-osteoarthritic posterior subluxation of the humeral head. *J Shoulder Elbow Surg.* 2018;27(1):181–188.
14. Walch G, Ascani C, Boulahia A, et al. Static posterior subluxation of the humeral head: an unrecognized entity responsible for glenohumeral osteoarthritis in the young adult. *J Shoulder Elbow Surg.* 2002;11(4):309–314.
15. Gerber C, Costouros JG, Sukthankar A, et al. Static posterior humeral head subluxation and total shoulder arthroplasty. *J Shoulder Elbow Surg.* 2009;18(4):505–510.
16. Hoenecke Jr HR, Tibor LM, D'Lima DD. Glenoid morphology rather than version predicts humeral subluxation: a different perspective on the glenoid in total shoulder arthroplasty. *J Shoulder Elbow Surg.* 2012;21(9):1136–1141.
17. Ricchetti ET, Hendel MD, Collins DN, et al. Is premorbid glenoid anatomy altered in patients with glenohumeral osteoarthritis? *Clin Orthop Relat Res.* 2013;471(9):2932–2939.
18. Chan K, Knowles NK, Chaoui J, et al. Is the Walch B3 glenoid significantly worse than the B2? *Shoulder Elbow.* 2018;10(4):256–261.
19. Budge MD, Lewis GS, Schaefer E, et al. Comparison of standard two-dimensional and three-dimensional corrected glenoid version measurements. *J Shoulder Elbow Surg.* 2011;20(4):577–583.
20. Nyffeler RW, Jost B, Pfirrmann CW, et al. Measurement of glenoid version: conventional radiographs versus computed tomography scans. *J Shoulder Elbow Surg.* 2003;12(5):493–496.
21. Friedman RJ, Hawthorne KB, Genez BM. The use of computerized tomography in the measurement of glenoid version. *J Bone Joint Surg Am Vol.* 1992;74(7):1032–1037.
22. Bokor DJ, O'Sullivan MD, Hazan GJ. Variability of measurement of glenoid version on computed tomography scan. *J Shoulder Elbow Surg.* 1999;8(6):595–598.
23. Kwon YW, Powell KA, Yum JK, et al. Use of three-dimensional computed tomography for the analysis of the glenoid anatomy. *J Shoulder Elbow Surg.* 2005;14(1):85–90.
24. Scalise JJ, Bryan J, Polster J, et al. Quantitative analysis of glenoid bone loss in osteoarthritis using three-dimensional computed tomography scans. *J Shoulder Elbow Surg.* 2008;17(2):328–335.
25. Bicknell RT, Patterson SD, King GJ, et al. Glenoid vault endosteal dimensions: an anthropometric study with special interest in implant design. *J Shoulder Elbow Surg.* 2007;16(3 Suppl):S96–S101.
26. Scalise JJ, Codi MJ, Bryan J, et al. The three-dimensional glenoid vault model

- can estimate normal glenoid version in osteoarthritis. *J Shoulder Elbow Surg.* 2008;17(3):487–491.
27. Matsumura N, Ogawa K, Ikegami H, et al. Computed tomography measurement of glenoid vault version as an alternative measuring method for glenoid version. *J Orthop Surg Res.* 2014;9(1):17.
  28. Cunningham G, Freebody J, Smith MM, et al. Comparative analysis of 2 glenoid version measurement methods in variable axial slices on 3-dimensionally reconstructed computed tomography scans. *J Shoulder Elbow Surg.* 2018;27(10):1809–1815.
  29. Ganapathi A, McCarron JA, Chen X, et al. Predicting normal glenoid version from the pathologic scapula: a comparison of 4 methods in 2- and 3-dimensional models. *J Shoulder Elbow Surg.* 2011;20(2):234–244.
  30. Walch G, Moraga C, Young A, et al. Results of anatomic unconstrained prosthesis in primary osteoarthritis with biconcave glenoid. *J Shoulder Elbow Surg.* 2012;21(11):1526–1533.
  31. Denard PJ, Walch G. Current concepts in the surgical management of primary glenohumeral arthritis with a biconcave glenoid. *J Shoulder Elbow Surg.* 2003;12(3):207–213.
  32. Edwards TB, Kadakia NR, Boulahia A, et al. A comparison of hemiarthroplasty and total shoulder arthroplasty in the treatment of primary glenohumeral osteoarthritis: results of a multicenter study. *J Shoulder Elbow Surg.* 2003;12(3):207–213.
  33. Roberson TA, Bentley JC, Griscom JT, et al. Outcomes of total shoulder arthroplasty in patients younger than 65 years: a systematic review. *J Shoulder Elbow Surg.* 2017;26(7):1298–1306.
  34. Williams Jr GR, Rockwood Jr CA. Hemiarthroplasty in rotator cuff-deficient shoulders. *J Shoulder Elbow Surg.* 1996;5(5):362–367.
  35. Carpenter SR, Urits I, Murthi AM. Porous metals and alternate bearing surfaces in shoulder arthroplasty. *Curr. Rev. Musculoskel. Med.* 2016;9(1):59–66.
  36. Mueller U, Braun S, Schroeder S, et al. Influence of humeral head material on wear performance in anatomic shoulder joint arthroplasty. *J Shoulder Elbow Surg.* 2017;26(10):1756–1764.
  37. Weldon 3rd EJ, Boorman RS, Smith KL, et al. Optimizing the glenoid contribution to the stability of a humeral hemiarthroplasty without a prosthetic glenoid. *J Bone Joint Surg Am Vol.* 2004;86-a(9):2022–2029.
  38. Lynch JR, Clinton JM, Dewing CB, et al. Treatment of osseous defects associated with anterior shoulder instability. *J Shoulder Elbow Surg.* 2009;18(2):317–328.
  39. Matsen 3rd FA, Clark JM, Titelman RM, et al. Healing of reamed glenoid bone articulating with a metal humeral hemiarthroplasty: a canine model. *J Orthop Res: Official Pub. Orthop. Res. Soc.* 2005;23(1):18–26.
  40. Krishnan SG, Reineck JR, Nowinski RJ, et al. Humeral hemiarthroplasty with biologic resurfacing of the glenoid for glenohumeral arthritis. Surgical technique. *J Bone Joint Surg Am Vol.* 2008;90(Suppl 2 Pt 1):9–19.
  41. Elhassan B, Ozbaydar M, Diller D, et al. Soft-tissue resurfacing of the glenoid in the treatment of glenohumeral arthritis in active patients less than fifty years old. *J Bone Joint Surg Am Vol.* 2009;91(2):419–424.
  42. Gilmer BB, Comstock BA, Jette JL, et al. The prognosis for improvement in comfort and function after the ream-and-run arthroplasty for glenohumeral arthritis: an analysis of 176 consecutive cases. *J Bone Joint Surg Am Vol.* 2012;94(14):e102.
  43. Krishnan SG, Nowinski RJ, Harrison D, et al. Humeral hemiarthroplasty with biologic resurfacing of the glenoid for glenohumeral arthritis. Two to fifteen-year outcomes. *J Bone Joint Surg Am Vol.* 2007;89(4):727–734.
  44. Donohue KW, Ricchetti ET, Iannotti JP. Surgical management of the biconcave (B2) glenoid. *Curr. Rev. Musculoskel. Med.* 2016;9(1):30–39.
  45. Hsu JE, Ricchetti ET, Huffman GR, et al. Addressing glenoid bone deficiency and asymmetric posterior erosion in shoulder arthroplasty. *J Shoulder Elbow Surg.* 2013;22(9):1298–1308.
  46. Iannotti JP, Greeson C, Downing D, et al. Effect of glenoid deformity on glenoid component placement in primary shoulder arthroplasty. *J Shoulder Elbow Surg.* 2012;21(1):48–55.
  47. Clavert P, Millett PJ, Warner JJ. Glenoid resurfacing: what are the limits to asymmetric reaming for posterior erosion? *J Shoulder Elbow Surg.* 2007;16(6):843–848.
  48. Gillespie R, Lyons R, Lazarus M. Eccentric reaming in total shoulder arthroplasty: a cadaveric study. *Orthopedics.* 2009;32(1):21.
  49. Neer 2nd CS, Morrison DS. Glenoid bone-grafting in total shoulder arthroplasty. *J Bone Joint Surg Am Vol.* 1988;70(8):1154–1162.
  50. Nowak DD, Bahu MJ, Gardner TR, et al. Simulation of surgical glenoid resurfacing using three-dimensional computed tomography of the arthritic glenohumeral joint: the amount of glenoid retroversion that can be corrected. *J Shoulder Elbow Surg.* 2009;18(5):680–688.
  51. Haines JF, Trail IA, Nuttall D, et al. The results of arthroplasty in osteoarthritis of the shoulder. *J Bone Joint Surg. Br. Vol.* 2006;88(4):496–501.
  52. Walch G, Young AA, Boileau P, et al. Patterns of loosening of polyethylene keeled glenoid components after shoulder arthroplasty for primary osteoarthritis: results of a multicenter study with more than five years of follow-up. *J Bone Joint Surg Am Vol.* 2012;94(2):145–150.
  53. Walch G, Young AA, Melis B, et al. Results of a convex-back cemented keeled glenoid component in primary osteoarthritis: multicenter study with a follow-up greater than 5 years. *J Shoulder Elbow Surg.* 2011;20(3):385–394.
  54. Strauss EJ, Roche C, Flurin PH, et al. The glenoid in shoulder arthroplasty. *J Shoulder Elbow Surg.* 2009;18(5):819–833.
  55. Malhas A, Rashid A, Copas D, et al. Glenoid bone loss in primary and revision shoulder arthroplasty. *Shoulder Elbow.* 2016;8(4):229–240.
  56. Sabesan V, Callanan M, Ho J, et al. Clinical and radiographic outcomes of total shoulder arthroplasty with bone graft for osteoarthritis with severe glenoid bone loss. *J Bone Joint Surg Am Vol.* 2013;95(14):1290–1296.
  57. Steinmann SP, Cofield RH. Bone grafting for glenoid deficiency in total shoulder replacement. *J Shoulder Elbow Surg.* 2000;9(5):361–367.
  58. Klika BJ, Wooten CW, Sperling JW, et al. Structural bone grafting for glenoid deficiency in primary total shoulder arthroplasty. *J Shoulder Elbow Surg.* 2014;23(7):1066–1072.
  59. Hill JM, Norris TR. Long-term results of total shoulder arthroplasty following bone-grafting of the glenoid. *J Bone Joint Surg Am Vol.* 2001;83-a(6):877–883.
  60. Boileau P, Moineau G, Roussanne Y, et al. Bony increased-offset reversed shoulder arthroplasty: minimizing scapular impingement while maximizing glenoid fixation. *Clin Orthop Relat Res.* 2011;469(9):2558–2567.
  61. Cil A, Sperling JW, Cofield RH. Nonstandard glenoid components for bone deficiencies in shoulder arthroplasty. *J Shoulder Elbow Surg.* 2014;23(7):e149–e157.
  62. Iannotti JP, Lappin KE, Klotz CL, et al. Lift-off resistance of augmented glenoid components during cyclic fatigue loading in the posterior-superior direction. *J Shoulder Elbow Surg.* 2013;22(11):1530–1536.
  63. Knowles NK, Ferreira LM, Athwal GS. Augmented glenoid component designs for type B2 erosions: a computational comparison by volume of bone removal and quality of remaining bone. *J Shoulder Elbow Surg.* 2015;24(8):1218–1226.
  64. Hermida JC, Flores-Hernandez C, Hoenecke HR, et al. Augmented wedge-shaped glenoid component for the correction of glenoid retroversion: a finite element analysis. *J Shoulder Elbow Surg.* 2014;23(3):347–354.
  65. Luedke C, Kissenberth MJ, Tolan SJ, et al. Outcomes of anatomic total shoulder arthroplasty with B2 glenoids: a systematic review. *JBS Rev.* 2018;6(4):e7.
  66. Rice RS, Sperling JW, Miletti J, et al. Augmented glenoid component for bone deficiency in shoulder arthroplasty. *Clin Orthop Relat Res.* 2008;466(3):579–583.
  67. Favorito PJ, Freed RJ, Passanise AM, et al. Total shoulder arthroplasty for glenohumeral arthritis associated with posterior glenoid bone loss: results of an all-polyethylene, posteriorly augmented glenoid component. *J Shoulder Elbow Surg.* 2016;25(10):1681–1689.
  68. Sandow M, Schutz C. Total shoulder arthroplasty using trabecular metal augments to address glenoid retroversion: the preliminary result of 10 patients with minimum 2-year follow-up. *J Shoulder Elbow Surg.* 2016;25(4):598–607.
  69. Stephens SP, Paisley KC, Jeng J, et al. Shoulder arthroplasty in the presence of posterior glenoid bone loss. *J Bone Joint Surg Am Vol.* 2015;97(3):251–259.
  70. Frankle MA, Teramoto A, Luo ZP, et al. Glenoid morphology in reverse shoulder arthroplasty: classification and surgical implications. *J Shoulder Elbow Surg.* 2009;18(6):874–885.
  71. Wagner E, Houdek MT, Griffith T, et al. Glenoid bone-grafting in revision to a reverse total shoulder arthroplasty. *J Bone Joint Surg Am Vol.* 2015;97(20):1653–1660.
  72. Neyton L, Boileau P, Nove-Josserand L, et al. Glenoid bone grafting with a reverse design prosthesis. *J Shoulder Elbow Surg.* 2007;16(3 Suppl):S71–S78.
  73. Hopkins AR, Hansen UN, Bull AM, et al. Fixation of the reversed shoulder prosthesis. *J Shoulder Elbow Surg.* 2008;17(6):974–980.
  74. Frankle MVN, Pupello D, Gutierrez S. *Rationale and Biomechanics of the Reverse Shoulder Prosthesis: The American Experience.* New York: Thieme Medical Publishers; 2008.
  75. Rockwood CLS, Sperling J, Wirth M. *Fehringer E Rockwood and Matsen's 'The Shoulder'.* Elsevier; 2016.
  76. Klein SM, Dunning P, Mulieri P, et al. Effects of acquired glenoid bone defects on surgical technique and clinical outcomes in reverse shoulder arthroplasty. *J Bone Joint Surg Am Vol.* 2010;92(5):1144–1154.
  77. Werner BS, Bohm D, Abdelkawi A, et al. Glenoid bone grafting in reverse shoulder arthroplasty for long-standing anterior shoulder dislocation. *J Shoulder Elbow Surg.* 2014;23(11):1655–1661.
  78. Gupta A, Thussbas C, Koch M, et al. Management of glenoid bone defects with reverse shoulder arthroplasty-surgical technique and clinical outcomes. *J Shoulder Elbow Surg.* 2018;27(5):853–862.
  79. Formaini NT, Everding NG, Levy JC, et al. The effect of glenoid bone loss on reverse shoulder arthroplasty baseplate fixation. *J Shoulder Elbow Surg.* 2015;24(11):e312–e319.
  80. Bateman E, Donald SM. Reconstruction of massive uncontained glenoid defects using a combined autograft-allograft construct with reverse shoulder arthroplasty: preliminary results. *J Shoulder Elbow Surg.* 2012;21(7):925–934.
  81. James J, Allison MA, Werner FW, et al. Reverse shoulder arthroplasty glenoid fixation: is there a benefit in using four instead of two screws? *J Shoulder Elbow Surg.* 2013;22(8):1030–1036.
  82. Jones RB, Wright TW, Zuckerman JD. Reverse total shoulder arthroplasty with structural bone grafting of large glenoid defects. *J Shoulder Elbow Surg.* 2016;25(9):1425–1432.
  83. Mizuno N, Denard PJ, Raiss P, et al. Reverse total shoulder arthroplasty for primary glenohumeral osteoarthritis in patients with a biconcave glenoid. *J Bone Joint Surg Am Vol.* 2013;95(14):1297–1304.
  84. Kelly 2nd JD, Zhao JX, Hobbgood ER, et al. Clinical results of revision shoulder arthroplasty using the reverse prosthesis. *J Shoulder Elbow Surg.* 2012;21(11):1516–1525.
  85. Melis B, Bonnevalle N, Neyton L, et al. Glenoid loosening and failure in anatomical total shoulder arthroplasty: is revision with a reverse shoulder

- arthroplasty a reliable option? *J Shoulder Elbow Surg.* 2012;21(3):342–349.
86. Tashjian R. No Bone? No Problem! Is Bone-Grafting at the Time of Revision to a Reverse Shoulder Arthroplasty a Reasonable Option? Commentary on an article by Eric Wagner, MD, et al.: "Glenoid Bone-Grafting in Revision to a Reverse Total Shoulder Arthroplasty". *J Bone Joint Surg Am Vol.* 2015;97(20):e68.
  87. Lorenzetti A, Streit JJ, Cabezas AF, et al. Bone graft augmentation for severe glenoid bone loss in primary reverse total shoulder arthroplasty: outcomes and evaluation of host bone contact by 2D-3D image registration. *JB JS Open Access.* 2017;2(3). e0015.
  88. McFarland EG, Huri G, Hyun YS, et al. Reverse total shoulder arthroplasty without bone-grafting for severe glenoid bone loss in patients with osteoarthritis and intact rotator cuff. *J Bone Joint Surg Am Vol.* 2016;98(21):1801–1807.
  89. Chammaa R, Uri O, Lambert S. Primary shoulder arthroplasty using a custom-made hip-inspired implant for the treatment of advanced glenohumeral arthritis in the presence of severe glenoid bone loss. *J Shoulder Elbow Surg.* 2017;26(1):101–107.
  90. Stoffelen DV, Eraly K, Debeer P. The use of 3D printing technology in reconstruction of a severe glenoid defect: a case report with 2.5 years of follow-up. *J Shoulder Elbow Surg.* 2015;24(8):e218–e222.
  91. Gunther SB, Lynch TL. Total shoulder replacement surgery with custom glenoid implants for severe bone deficiency. *J Shoulder Elbow Surg.* 2012;21(5):675–684.
  92. Dines DM, Gulotta L, Craig EV, et al. Novel solution for massive glenoid defects in shoulder arthroplasty: a patient-specific glenoid vault reconstruction system. *Am J Orthoped.* 2017;46(2):104–108.
  93. Wylie JD, Tashjian RZ. Planning software and patient-specific instruments in shoulder arthroplasty. *Curr. Rev. Musculoskel. Med.* 2016;9(1):1–9.
  94. Werner BS, Hudek R, Burkhart KJ, et al. The influence of three-dimensional planning on decision-making in total shoulder arthroplasty. *J Shoulder Elbow Surg.* 2017;26(8):1477–1483.
  95. Iannotti JP, Weiner S, Rodriguez E, et al. Three-dimensional imaging and templating improve glenoid implant positioning. *J Bone Joint Surg Am Vol.* 2015;97(8):651–658.
  96. Iannotti J, Baker J, Rodriguez E, et al. Three-dimensional preoperative planning software and a novel information transfer technology improve glenoid component positioning. *J Bone Joint Surg Am Vol.* 2014;96(9):e71.
  97. Walch G, Verzeridis PS, Boileau P, et al. Three-dimensional planning and use of patient-specific guides improve glenoid component position: an in vitro study. *J Shoulder Elbow Surg.* 2015;24(2):302–309.
  98. Dallalana RJ, McMahon RA, East B, et al. Accuracy of patient-specific instrumentation in anatomic and reverse total shoulder arthroplasty. *Int J Shoulder Surg.* 2016;10(2):59–66.
  99. Nyffeler RW, Sheikh R, Atkinson TS, et al. Effects of glenoid component version on humeral head displacement and joint reaction forces: an experimental study. *J Shoulder Elbow Surg.* 2006;15(5):625–629.
  100. Levigne C, Garret J, Boileau P, et al. Scapular notching in reverse shoulder arthroplasty: is it important to avoid it and how? *Clin Orthop Relat Res.* 2011;469(9):2512–2520.
  101. Hendel MD, Bryan JA, Barsoum WK, et al. Comparison of patient-specific instruments with standard surgical instruments in determining glenoid component position: a randomized prospective clinical trial. *J Bone Joint Surg Am Vol.* 2012;94(23):2167–2175.
  102. Levy JC, Everding NG, Frankle MA, et al. Accuracy of patient-specific guided glenoid baseplate positioning for reverse shoulder arthroplasty. *J Shoulder Elbow Surg.* 2014;23(10):1563–1567.
  103. Verborgt O, Vanhees M, Heylen S, et al. Computer navigation and patient-specific instrumentation in shoulder arthroplasty. *Sports Med Arthrosc Rev.* 2014;22(4):e42–e49.
  104. Throckmorton TW, Gulotta LV, Bonnarens FO, et al. Patient-specific targeting guides compared with traditional instrumentation for glenoid component placement in shoulder arthroplasty: a multi-surgeon study in 70 arthritic cadaver specimens. *J Shoulder Elbow Surg.* 2015;24(6):965–971.
  105. Sadoghi P, Vavken J, Leithner A, et al. Benefit of intraoperative navigation on glenoid component positioning during total shoulder arthroplasty. *Arch Orthop Trauma Surg.* 2015;135(1):41–47.
  106. Kircher J, Wiedemann M, Magosch P, et al. Improved accuracy of glenoid positioning in total shoulder arthroplasty with intraoperative navigation: a prospective-randomized clinical study. *J Shoulder Elbow Surg.* 2009;18(4):515–520.
  107. Nguyen D, Ferreira LM, Brownhill JR, et al. Improved accuracy of computer assisted glenoid implantation in total shoulder arthroplasty: an in-vitro randomized controlled trial. *J Shoulder Elbow Surg.* 2009;18(6):907–914.
  108. Stubig T, Petri M, Zeckey C, et al. 3D navigated implantation of the glenoid component in reversed shoulder arthroplasty. Feasibility and results in an anatomic study. *Int. J. Med. Robot. + Comput. Ass. Sur.: MRCAS.* 2013;9(4):480–485.





## Two portal technique with antegrade suture passer and knotless anchors for Arthroscopic Bankart repair: A technical note

Joong-Bae Seo, Kang Heo, Jong-Heon Yang, Jae-Sung Yoo\*

Department of Orthopedic Surgery, Dankook University College of Medicine, Cheonan, South Korea

### ARTICLE INFO

#### Article history:

Received 13 November 2018

Accepted 1 January 2019

Available online 2 January 2019

#### Keywords:

Shoulder  
Bankart  
Arthroscopy  
Instability

### ABSTRACT

Arthroscopic Bankart repair is generally accepted as the choice of treatment for labrum and glenoid rim restoration. Recently, the antegrade suture passer has been one of the widely used devices in arthroscopic surgery. This device saves time by combining tissue grasping, suture passage, and suture retrieval into one convenient step. In addition, a knotless anchor is also used for a Bankart repair to prevent knot-induced articular cartilage injuries. Arthroscopic Bankart repair usually uses two anterior portals (anterosuperior accessory portal and anteroinferior working portal) with one posterior viewing portal. The purpose of this technical note was to present a simple and easy technique for Bankart repair using a single anterior working portal with an antegrade suture passer and knotless anchors.

© 2019 International Society for Knowledge for Surgeons on Arthroscopy and Arthroplasty. Published by Elsevier, a division of RELX India, Pvt. Ltd. All rights reserved.

### 1. Introduction

According to the evolution of arthroscopic surgery, the arthroscopic Bankart repair is generally accepted as the choice of treatment to restore the labrum and the glenoid rim.<sup>1,2</sup> In 1991, Wolf et al.<sup>3</sup> described arthroscopic Bankart repair with anchors. It involved the use of two anterior working portals and one posterior viewing portal and intra-articular knot tying. They described that the anteroinferior portal was used for anchor insertion and passing suture loops, and the anterosuperior portal was used for anterior visualization, shuttle relay of suture, and for insertion of a grasper to place tension on the labrum while sutures were passed through the anteroinferior portal.<sup>3</sup>

The antegrade suture passer is a widely used device in arthroscopic surgery. This device saves time by combining tissue grasping, suture passage, and suture retrieval into one convenient step.<sup>4</sup> The antegrade suture passer also uses flexible, small-caliber needles to help minimize damage to the tissue intraoperatively.<sup>4</sup> In addition, knotless anchors are also widely used for Bankart repairs to prevent knot-induced articular cartilage injuries.

In this technical note, our preferred technique for the

arthroscopic Bankart repair with a single working portal using an antegrade suture passer and knotless anchors is described. To our knowledge, a similar technique to the one we will present has not yet been formally published in the literature.

### 2. Operative technique

#### 2.1. Anesthesia, patient positioning, and portal placement

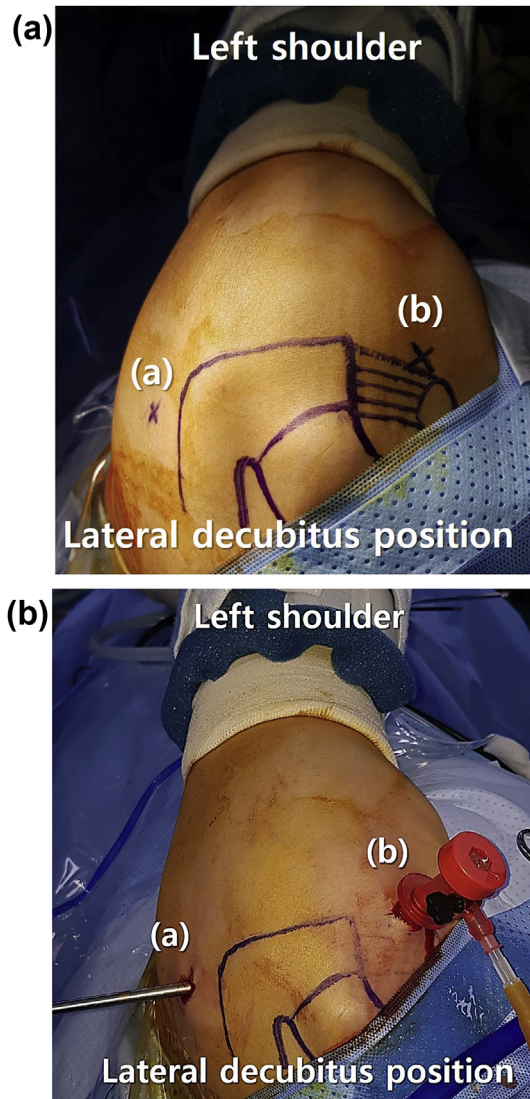
The patient is positioned in the lateral decubitus position with the affected arm in 10 lbs. of balanced longitudinal and lateral suspension via use of the STAR device (Arthrex, Naples, FL). A standard posterior portal is created for initial intra-articular visualization. Under direct visualization, the anterior working portal (anteroinferior portal) is created through the rotator interval using the outside-in technique. To determine the proper position of the anterior portal, an 18-gauge spinal needle is first inserted just above the subscapularis. After the determination of the anterior portal position, the needle is then removed and a skin incision is made wide enough to insert the working cannula (Dry-Doc cannula, ConMed, USA) (Fig. 1).

#### 2.2. Glenoid preparation and anterior labral repair

The anterior labrum is mobilized with an arthroscopic elevator (Arthrex, Naples, FL) and a motorized shaver is used to debride the exposed labral edge to promote healing. Anchor insertion sites are

\* Corresponding author. Department of Orthopaedic Surgery, Dankook University College of Medicine, 119, Dandae-ro, Dongnam-gu, Cheonan-si, Chungnam, 330-715, South Korea. Tel.: +82 41 550 3060; fax: +82 41 556 3238.

E-mail address: [osarthro@gmail.com](mailto:osarthro@gmail.com) (J.-S. Yoo).



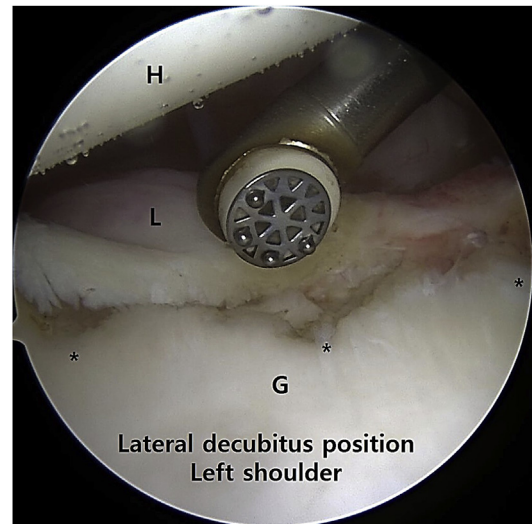
**Fig. 1.** Left shoulder of patient is placed in the lateral decubitus position. (a) as a standard posterior viewing portal and (b) as a single anterior working portal are shown.

marked with electrocautery device on the glenoid surface, 1–2 mm toward the articular cartilage of the rim (Fig. 2). A bleeding bed along the glenoid neck is formed using a burr and arthrocare (Quantum 2; Smith & Nephew Inc., Austin, TX, USA) (Fig. 3).

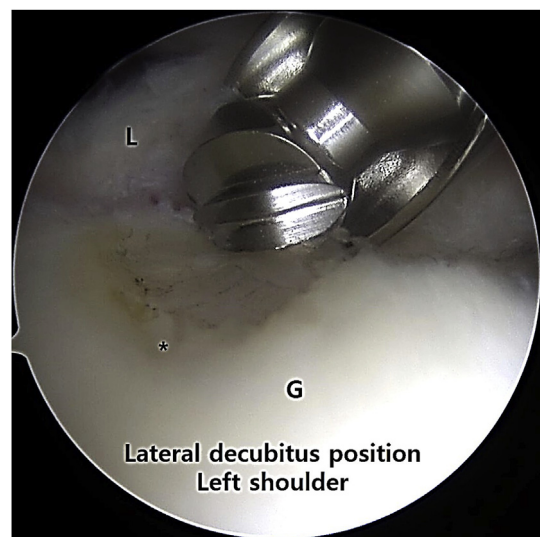
First, Number 2 Fiberwire (Arthrex, Naples, FL) is loaded with the Arthrex Scorpion (Arthrex, Naples, FL). This antegrade suture passer is used to penetrate the detached labrum at approximately 1 cm lateral to the glenoid (Fig. 4).

A drill hole is created on the glenoid surface for the 2.9 mm PushLock anchor, 1–2 mm toward the articular cartilage of the rim (Fig. 5). The first drill hole is created adjacent to the lowest point of the detached labrum near the point of passage of the first loop of the fiberwire. Both ends of the fiberwire are then passed through the distal ring of the Pushlock anchor, which is then inserted and tapped into the previously created drill hole to the appropriate depth for the 2.9 mm PushLock anchor (Arthrex, Naples, FL) (Fig. 6).

Additional anchors are placed as necessary until the 2 o'clock position in the right shoulder and the 10 o'clock position in the left shoulder can be achieved. In all cases, three or four suture anchors are used (Fig. 7).



**Fig. 2.** Anchor insertion sites were marked with arthrocare on the glenoid surface, 1–2 mm toward the articular cartilage of the rim. H: humeral head, L: labrum, G: glenoid, Asterik: anchor insertion sites.



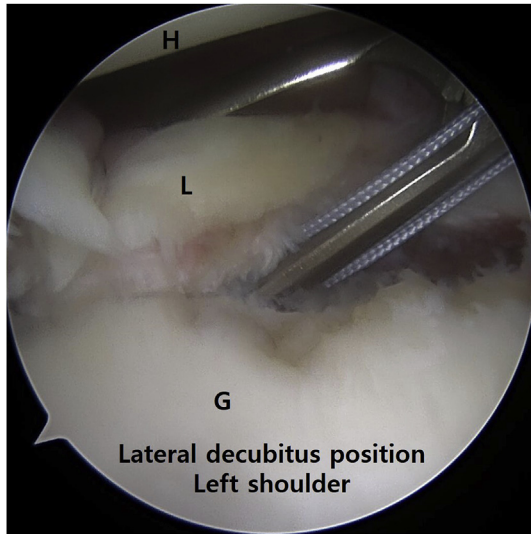
**Fig. 3.** The anterior glenoid neck being prepared with a burr. H: humeral head, L: labrum, G: glenoid, Asterik: anchor insertion site.

### 2.3. Postoperative rehabilitation

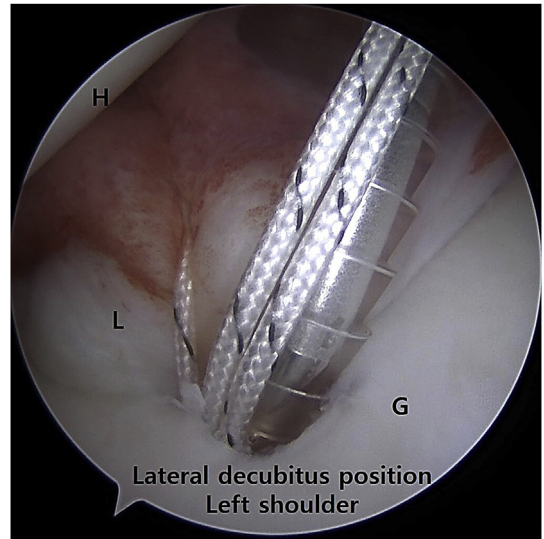
A small abduction pillow is used for 6 weeks and pendulum exercises were started one week postoperatively. Passive and active assisted forward flexions were initiated to work towards 90° two weeks postoperatively. At four weeks, passive and active assisted external rotations of 20° were allowed. Active muscle strengthening exercises with bands were started at 6 weeks. At 18 weeks after surgery, patients were allowed to return to sports.

## 3. Discussion

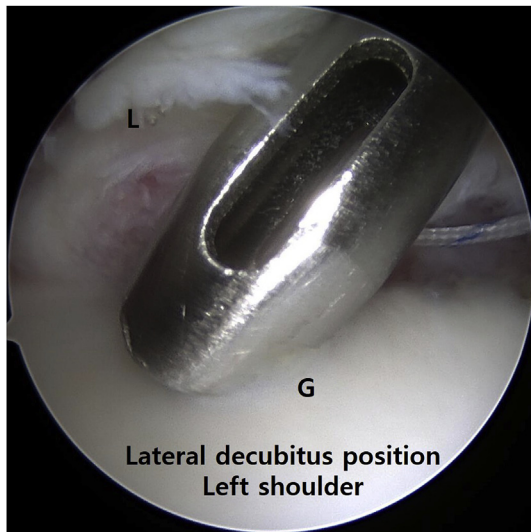
First and foremost, portals for arthroscopy should prevent damage to adjacent neurovascular structures.<sup>5</sup> Moreover, portals should allow for a good view of the intraarticular structures and allow easy access of intraarticular pathology to facilitate easy debridement or repair.<sup>5</sup> The arthroscopic technique described by



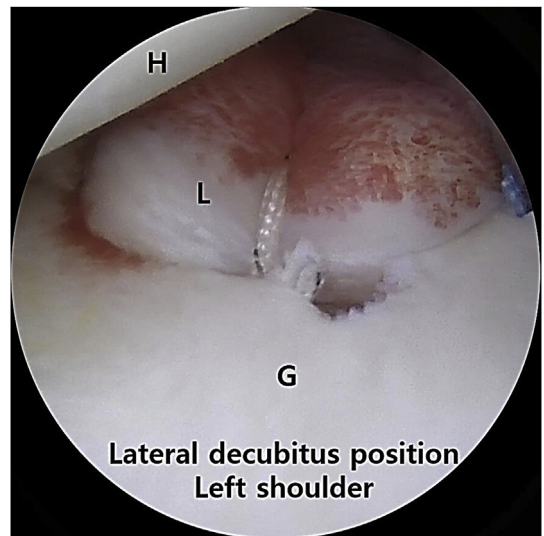
**Fig. 4.** The Number 2 Fiberwire loaded antegrade suture passer is used to penetrate the detached labrum. H: humeral head, L: labrum, G: glenoid, Asterik: anchor insertion site.



**Fig. 6.** Both ends of the fiberwire are then passed through the distal ring of the 2.9 mm Pushlock anchor, which is then inserted and tapped into the drill hole to the appropriate depth as marked on the inserter. H: humeral head, L: labrum, G: glenoid.



**Fig. 5.** A drill hole placed at the previous marked site that is on the glenoid surface 1–2 mm from the glenoid rim. L: labrum, G: glenoid.



**Fig. 7.** View through posterior portal after completed repair using 3 anchors. H: humeral head, L: labrum, G: glenoid.

Wolf in 1991 is considered as the standard for arthroscopic Bankart repairs.<sup>3</sup> The posterior viewing portal is located in an interval between the teres minor and the infraspinatus tendons, although this portal passes through the latter tendon.<sup>3</sup> The surgeon can, if necessary, switch to viewing from an anterosuperior portal to observe the posterior intra-articular shoulder anatomy. However, the posterior viewing portal with 70° scope allows an excellent view of most intraarticular structures and pathology.

The anterior working portals both pass through the rotator interval; one just above the subscapularis tendon and the other just anterior to the long head of the biceps.<sup>3</sup> These two portals lie in the “intra-articular triangle,” as described by Matthews et al.<sup>6</sup> This triangle is bounded by the glenoid rim, humeral head, and the long head of the biceps tendon. The anterior inferior portal allows access of the anterior inferior labrum and glenoid.<sup>3,5,6</sup>

The arthroscopic Bankart repair requires the use of suture anchors, of which there are two varieties: those that require knot

tying and those that do not.<sup>7,8</sup> The knot-tying suture anchors are predominantly used, especially for intra-articular labral procedures.<sup>9,10</sup> There are several knot-tying techniques available; however, it is recommended that all stacked half-hitch knots be locked with three reversing half-hitch knots on alternate posts after the initial sliding knot is made.<sup>11</sup> Because the volume of the knot-tying could be problematic in the joint, one of the essential techniques in knot-tying suture anchors is placement of the knot, which should be located away from the articular surface.<sup>12,13</sup> It is a widely-accepted belief that this helps to prevent knot-induced damage to the articular cartilage.<sup>13</sup> However, Kim et al. described that knot migration occurs from the capsule toward the glenoid surface after shoulder motion through a cadaveric study.<sup>13</sup> They described that knot movement to an unintended location could lead to damage to the articular surface.<sup>13</sup> Therefore, one way to prevent this knot-

induced problem is to use knotless anchors. Despite most clinical studies exhibiting satisfactory results with knotless anchors in the Bankart repair,<sup>14–16</sup> one comparative clinical study showed that knotless anchors had a higher redislocation rate than the knot-tying suture anchors.<sup>17</sup> In addition, there are reports of arthropathy occurring after the use of knotless anchors intraarticularly.<sup>18,19</sup> Different designs of knotless anchors have recently been made available that have comparable characteristics to knot-tying suture anchors, which may increase their popularity among shoulder surgeons.<sup>13,18,19</sup>

With the evolution of arthroscopic surgery, various suture passing methods have been described. The antegrade suture passage is an effective and convenient method, and combines tissue grasping, suture passage, and suture retrieval into one step without the shuttle relay procedure.<sup>4</sup> Recently, this device has been used for not only arthroscopic rotator cuff repair but also the arthroscopic Bankart repair.

In this technical note, we describe an anterior inferior portal that was used for arthroscopic Bankart repair without an anterior superior portal. An anterior superior portal is not necessary when using the antegrade suture passage and knotless anchors. This single working portal technique with antegrade suture passage and knotless anchors is a simple and easy procedure that saves time and is less invasive.

#### Appendix A. Supplementary data

Supplementary data to this article can be found online at <https://doi.org/10.1016/j.jajs.2019.01.003>.

#### References

- Kim SH, Ha KI, Cho YB, Ryu BD, Oh I. Arthroscopic anterior stabilization of the shoulder: two to six-year follow-up. *J Bone Joint Surg Am.* 2003;85-A(8):1511–1518.
- Stokes DA, Savoie 3rd FH, Field LD, Ramsey JR. Arthroscopic repair of anterior glenohumeral instability and rotator interval lesions. *Orthop Clin N Am.* 2003;34(4):529–538.
- Farley TE, Howell SM, Love KF, Wolfe RD, Neumann CH. Meniscal tears: MR and arthrographic findings after arthroscopic repair. *Radiology.* 1991;180(2):517–522.
- Kim MS, Kim DW, Choi YE, Bachman Jr L, Kim SH. Performance of antegrade suture passers according to tendon thickness. *Int J Shoulder Surg.* 2015;9(2):47–51.
- Ng DZ, Lau BPH, Tan BHM, Kumar VP. Single working portal technique for knotless arthroscopic bankart repair. *Arthrosc Tech.* 2017;6(5):e1989–e1992.
- Matthews LS, Zarins B, Michael RH, Helfet DL. Anterior portal selection for shoulder arthroscopy. *Arthroscopy.* 1985;1(1):33–39.
- Thal R. A knotless suture anchor. Design, function, and biomechanical testing. *Am J Sports Med.* 2001;29(5):646–649.
- Slabaugh MA, Friel NA, Wang VM, Cole BJ. Restoring the labral height for treatment of Bankart lesions: a comparison of suture anchor constructs. *Arthroscopy.* 2010;26(5):587–591.
- Baumgarten KM, Wright RW. Incorporating evidence-based medicine in arthroscopic knot preferences: a survey of american orthopaedic society for sports medicine members. *Am J Orthop (Belle Mead NJ).* 2010;39(12):577–581.
- Nho SJ, Frank RM, Van Thiel GS, et al. A biomechanical analysis of anterior Bankart repair using suture anchors. *Am J Sports Med.* 2010;38(7):1405–1412.
- Chan KC, Burkhart SS, Thiagarajan P, Goh JC. Optimization of stacked half-hitch knots for arthroscopic surgery. *Arthroscopy.* 2001;17(7):752–759.
- E M. Arthroscopic knot tying. In: Angelo RL, Esch JC, Ryu RKN, eds. *AANA Advanced Arthroscopy: The Shoulder Ed 1.* Philadelphia: Saunders/Elsevier; 2010:9.
- Kim SH, Crater RB, Hargens AR. Movement-induced knot migration after anterior stabilization in the shoulder. *Arthroscopy.* 2013;29(3):485–490.
- Oh JH, Lee HK, Kim JY, Kim SH, Gong HS. Clinical and radiologic outcomes of arthroscopic glenoid labrum repair with the BioKnotless suture anchor. *Am J Sports Med.* 2009;37(12):2340–2348.
- Kocaoglu B, Guven O, Nalbantoglu U, Aydin N, Haklar U. No difference between knotless sutures and suture anchors in arthroscopic repair of Bankart lesions in collision athletes. *Knee Surg Sports Traumatol Arthrosc.* 2009;17(7):844–849.
- Thal R, Nofziger M, Bridges M, Kim JJ. Arthroscopic Bankart repair using Knotless or BioKnotless suture anchors: 2- to 7-year results. *Arthroscopy.* 2007;23(4):367–375.
- Cho NS, Lubis AM, Ha JH, Rhee YG. Clinical results of arthroscopic bankart repair with knot-tying and knotless suture anchors. *Arthroscopy.* 2006;22(12):1276–1282.
- Athwal GS, Shridharani SM, O'Driscoll SW. Osteolysis and arthropathy of the shoulder after use of bioabsorbable knotless suture anchors. A report of four cases. *J Bone Joint Surg Am.* 2006;88(8):1840–1845.
- Boden RA, Burgess E, Enion D, Srinivasan MS. Use of bioabsorbable knotless suture anchors and associated accelerated shoulder arthropathy: report of 3 cases. *Am J Sports Med.* 2009;37(7):1429–1433.



## Research paper

# Physiotherapy treatment for atraumatic recurrent shoulder instability: Updated results of the Derby Shoulder Instability Rehabilitation Programme

Marcus Bateman<sup>a,\*</sup>, Sally E. Osborne<sup>b</sup>, Benjamin E. Smith<sup>a</sup>

<sup>a</sup> University Hospitals of Derby & Burton NHS Foundation Trust, London Road Community Hospital, London Road, Derby, DE1 2QY, UK

<sup>b</sup> University Hospitals of Derby & Burton NHS Foundation Trust, Royal Derby Hospital, Uttoxeter Road, Derby, DE22 3DT, UK

## ARTICLE INFO

## Article history:

Received 24 November 2018

Accepted 1 January 2019

Available online 7 January 2019

## Keywords:

Atraumatic  
Shoulder  
Instability  
Physiotherapy  
Rehabilitation

## ABSTRACT

**Background:** There is limited evidence to guide therapists in the management of patients with atraumatic shoulder instability however physiotherapy remains the recommended course of treatment. In this paper we report the updated results of a rehabilitation programme designed for this patient group.

**Method:** A service evaluation was conducted at a large university teaching hospital in the UK between August 2013 and September 2018 including patients with atraumatic Stanmore type 2 or 3 instability. Western Ontario Shoulder Index (WOSI) and Oxford Instability Shoulder Scores (OISS) were measured at baseline and final follow-up. OISS was also repeated at every clinic visit. Patients were treated using the Derby Shoulder Instability Rehabilitation Programme until a point of agreed discharge.

**Results:** 66 patients were included but 15 were lost to follow-up. Patients attended for a mean of 6.9 sessions over 30 weeks. The mean OISS (n = 51) improved from 38.00 to 21.96 (p < 0.001). Including patients that did not complete follow-up in a sensitivity analysis, the mean OISS (n = 63) improved from 38.41 to 24.46 (p < 0.001). The mean WOSI (n = 51) improved from 45.10% to 85.81% (p < 0.001). In terms of the four WOSI sub-groups: the 'Physical' domain improved from mean 47.98%–81.19% (p < 0.001), the 'Sport & Work' domain improved from mean 40.17%–82.00% (p < 0.001), the 'Lifestyle' domain improved from 50.73% to 83.45% (p < 0.001) and the 'Emotions' domain improved from 32.84% to 79.78% (p < 0.001).

**Conclusion:** For patients with atraumatic shoulder instability the Derby Shoulder Instability Rehabilitation Programme provides significant benefit to patients in terms of pain, stability and function. Further study is required to assess whether such improvements can be sustained in the medium and long terms.

© 2019 International Society for Knowledge for Surgeons on Arthroscopy and Arthroplasty. Published by Elsevier, a division of RELX India, Pvt. Ltd. All rights reserved.

## 1. Introduction

The shoulder is the most commonly dislocated joint and whilst in the majority of cases this occurs as a result of trauma, it can also occur in the absence of trauma. Atraumatic shoulder instability is associated with underlying dysfunction of the joint capsule where laxity can lead to symptomatic instability: usually pain, repeated subluxation or full dislocation.<sup>1,2</sup> In such cases the recommended

management is conservative, in the form of physiotherapy rehabilitation, and surgery is regarded as a last resort.<sup>3</sup> There is limited evidence to guide physiotherapists regarding the most effective strategies of rehabilitation.<sup>4</sup> For this reason the Derby Shoulder Instability Rehabilitation Programme was developed. Early results were published in 2015 on a small group of 18 patients suggesting that the programme showed promising outcomes.<sup>5</sup> In this paper the results of a larger patient population are reported.

The Derby Programme is designed to be simple for both patients and therapists to understand. It consists of two groups of exercises (see Fig. 1) and the patient is instructed to only practice two exercises at any one time. The exercises are ordered in increasing difficulty with the patients required to achieve a target number of repetitions or performance time without a rest before progressing

\* Corresponding author. Physiotherapy Department (Level 3), London Road Community Hospital, Derby, DE1 2QY, UK.

E-mail address: [marcus.bateman@nhs.net](mailto:marcus.bateman@nhs.net) (M. Bateman).

URL: <http://DerbyShoulderUnit.co.uk>

@MarcusBatemanPT (M. Bateman)

## **Derby Shoulder Instability Rehabilitation Programme**

Only prescribe one exercise from each section at any one time.

Each set of exercises is listed in order of treatment progression and can also be used for functional assessment. If the patient can achieve the target then progress to the next exercise.

Section 1: Working on speed of muscle activation, plyometrics, deceleration of fast movement

Prescribe maximum repetitions until fatigue or the specified target.  
Two sessions per day.

	Target Reps
Drop & catch 1kg weight at 90° scaption	100
Drop & catch 1kg weight at 90° scaption on 1 leg (opposite side)	100
Drop & catch 1kg weight at 90° scaption with eyes closed	100
Drop & catch 1kg weight in AER/AIR	100
Falling press up in standing	50
Falling press up to waist level	50
Plyometric push up with hand clap	20
Doorway fall	20

Section 2: Working on proprioception, muscle balance, trunk stability

Prescribe 5 repetitions of the patient's maximum ability or specified target time.  
Two sessions per day.


	Target Time
Single handed ball roll on wall	60s
Single handed kneeling crosses	60s
Kneeling single handed ball roll	60s
Single handed crosses in push up position	60s
Double handed ball roll in push up position	60s
Double ball roll in push up positions	60s

*Note: For patients with significant posterior instability modify the position for the single hand exercises to do with the shoulder in an abducted rather than flexed position.*

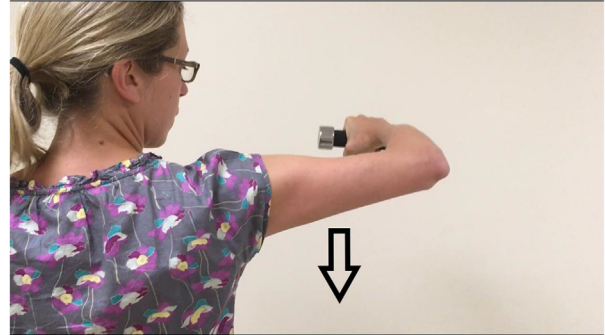
Fig. 1. The Derby Shoulder Instability Rehabilitation Programme overview.

to the next exercise in the section. The exercises are intended not just to improve strength but also stamina, speed of muscle activation, proprioception and absorption of impact to help rehabilitate patients back to both functional daily activity and high level sport. There is evidence to suggest that patients with shoulder instability lack proprioception<sup>6</sup> and that exercise that includes weight-bearing

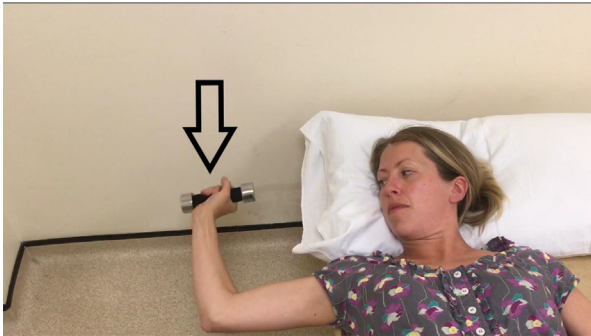through the arm on an unsteady surface<sup>7</sup> or plyometrics<sup>8</sup> can help patients restore it. Patients are therefore instructed in exercises from the outset involving weight-bearing through their arm and perform fast plyometric movements to gain strength. Details of the exercises are shown in Fig. 2 and exercise videos can be accessed via [DerbyShoulderUnit.co.uk](http://DerbyShoulderUnit.co.uk). The focus of all of the exercises is based



Exercise 1a: Drop and catch a 1kg weight at 90° abduction in the scapular plane. If this is too difficult to begin with then use a smaller weight or lower the arm to 45° abduction. Target repetitions: 100. The exercise can then be modified to be performed with the patient's eyes closed or standing on the contra-lateral leg.



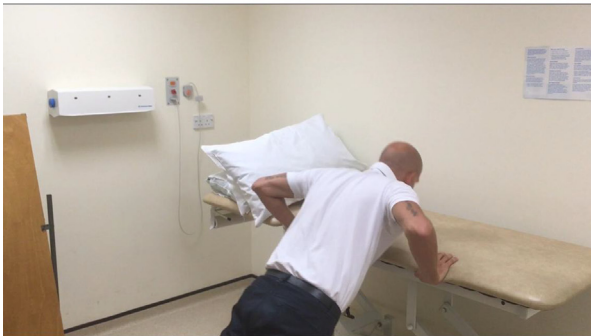Exercise 1b: Drop and catch a 1kg weight at 90° abduction but with the elbow flexed. The patient is instructed to keep the elbow high so that the movement is primarily internal rotation of the shoulder. Target repetitions: 100.



Exercise 1c: For patients with anterior instability symptoms progress to dropping and catching a 1kg weight into external rotation at 90° abduction. This is performed lying supine. Target repetitions: 100.



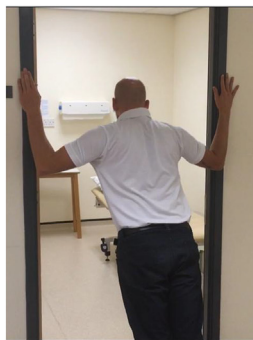Exercise 1d: Falling push up in standing. The patient stands one arm length from the wall. They are instructed to fall towards the wall and save themselves with their hands in a push up position. They then plyometrically push away from the wall back to a standing position. Target repetitions: 50.



Exercise 1e: Falling push up to waist level. With a similar technique to exercise 1d the patient now falls to waist level, for example to the height of a kitchen work surface. Target repetitions: 50.




Exercise 1f: Plyometric push up with hand clap. Target repetitions: 20. If this is too difficult then it can be performed in kneeling first before progressing to the full push up position.



Exercise 1g: Doorway fall. For patients with anterior instability this end stage exercise involves falling through a doorway. The patient is instructed to stand one arm length from the doorway, fall forwards and then save themselves by positioning their shoulders in an abducted and externally rotated position. They then push back up into a standing position. Target repetitions: 20.


**Figure 2.** Detailed instructions for each exercise used in the Derby Shoulder Instability Rehabilitation Programme.



Exercise 2a: Single hand ball roll on the wall. The patient is instructed to stand 1.5 arm lengths from the wall. They lean forward with their hand on a firm ball at 90° shoulder flexion. Applying as much body weight as possible the patient is instructed to roll the ball very slowly up and down trying to control and tremor. If tremor is present then the patient continues this exercise at home. If they can perform it for 1 minute smoothly they progress to the next exercise.




Exercise 2b: Kneeling crosses. The patient kneels with their weight on their symptomatic arm. With their free arm they point to the corners of a cross or square thereby transferring weight over the symptomatic arm. Patients are encouraged to make as large a movement as possible. The movement should be performed smoothly, without tremor, for 1 minute before progressing to the next exercise.



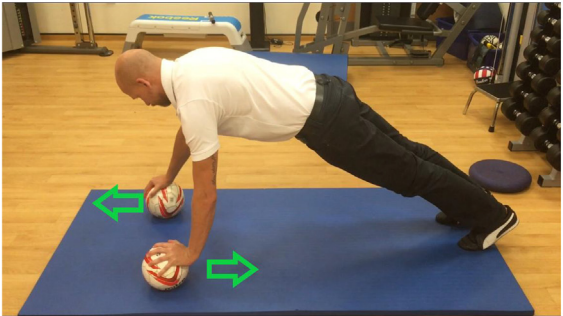
Exercise 2c: Kneeling single hand ball roll. The patient kneels with as much weight as possible through their symptomatic arm on a firm ball. They then roll the ball slowly forwards and backwards. The movement should be performed smoothly, without tremor, for 1 minute before progressing to the next exercise.



Exercise 2d: Crosses in a push up position. The patient adopts a push up position but then keeps their weight on their symptomatic arm whilst pointing to the corners of a cross or square with their other hand. Patients are encouraged to make as large a movement as possible. The movement should be performed smoothly, without tremor, for 1 minute before progressing to the next exercise.



Exercise 2e: Double handed ball roll in push up position. The patient adopts a push up position weight-bearing on a firm ball. The ball is then rolled slowly forwards and backwards. The movement should be performed smoothly, without tremor, for 1 minute before progressing to the next exercise.



Exercise 2f: Double ball roll in push up position. The patient adopts a push up position with each hand on a firm ball. One ball is rolled slowly forwards while the other ball is rolled slowly backwards and vice versa. The movement should be performed smoothly, without tremor, for 1 minute.

Figure 2. (continued).

upon an activity using the hand rather than a correction of posture or 'abnormal' pattern of movement. The reasoning behind this is to reduce the over-medicalisation of the problem, reduce the focus on the shoulder, reduce the emphasis on what is abnormal and concentrate on improving functional ability instead. Alongside the prescription of exercise patients also receive education regarding the condition with emphasis that this is a lifelong condition that requires self-management. This is to reduce the demand of a 'quick fix' and set appropriate expectations regarding timescales for improvement: usually several months. Patients are also advised that mild or moderate pain during exercise is normal and to be expected, to help reduce the fear of pain during activity, with reassurance that pain does not equate to tissue damage.<sup>9</sup> There is evidence to suggest that performing exercises that are painful may have a greater effect than those that are pain free in the short term.<sup>10</sup> Patients are told to expect improvements in ability to perform the exercises but not necessarily a corresponding initial

improvements in pain or reduction in subluxation. Our observation is that patients typically reach a certain threshold of exercise ability, unique to them, when symptoms suddenly begin to improve rather than a steady improvement from the outset. It is important therefore to try and encourage patients to persevere with the programme even if there is little benefit in the short term.

## 2. Methods

A prospective service evaluation was implemented in August 2013 in both the adult and paediatric physiotherapy outpatient clinics in our large university teaching hospital and continues to the present day. Included patients had a history of atraumatic recurrent shoulder instability. Patients were clinically assessed by an experienced physiotherapist and findings were correlated with the patient's history and imaging findings. Classification of instability was made using the Stanmore system.<sup>2</sup> Those with a history of trauma



(type 1) or a single instability episode only were excluded. Those classified as type 2 or type 3 were included. All patients were treated using the Derby Shoulder Instability Rehabilitation Programme provided they met the basic inclusion criteria detailed in the programme:

- No clinical evidence of neurological muscle weakness compared with the contralateral side
- No true scapula winging that would indicate a long thoracic nerve lesion (but asymmetrical patterning is accepted)
- Able to maintain sitting balance on a gymball as a means of assessing basic trunk stability
- Able to achieve 90° scaption as required to perform the exercises in section 1 of the programme.

Any patients who were unable to fulfil these last two criteria were first instructed in other exercises to perform before starting the programme. Examples of this were to practice single leg balance or sitting balance on a gymball; or isotonic elastic band shoulder external rotation exercises.

Results were reviewed from August 2013 up to September 2018. All patients are invited to complete a Western Ontario Shoulder Index (WOSI)<sup>11</sup> and Oxford Instability Shoulder Score (OISS)<sup>12</sup> at their initial consultation. The OISS is repeated at every clinic visit but the WOSI is only repeated at the time of agreed discharge, for logistical reasons, due to the fact that it takes longer to complete. The OISS is scored from 12 to 60 points with 12 indicating a perfect score for a normal healthy stable shoulder. The WOSI is presented as a percentage, with a higher score meaning a better level of function and shoulder stability. The minimum clinically important difference for the OISS is 4.5 points<sup>13</sup> and for the WOSI is 10.4%.<sup>14</sup> Baseline measures were compared to those from final follow up with statistical analysis performed using Microsoft Excel. Normality of data was assessed using Skewness and Kurtosis tests and deemed to be normally distributed if both results fell between -2 and +2. OISS data were normally distributed so were subsequently tested for significance using a two-tailed student t-test. WOSI data, including subgroups, were not normally distributed so analysed using the Wilcoxon signed ranks test. For those patients that did not complete the programme to an agreed time of discharge the OISS up until their last clinic appointment could still be used for a sensitivity analysis but WOSI data could only be analysed for those that had completed the package of care.

### 3. Results

68 patients with atraumatic recurrent shoulder instability were treated over the five year period. Two patients were excluded from the programme: one due to a congenital hand deformity meaning they could not perform the exercises and the other likewise due to comorbidities and multiple other joint pathologies. The population demographics of the 66 patients that started the programme included 23 males and 43 females. Mean age 21.65 (range 12–52) with mean symptom duration of 34 months (range 1 month–21 years). Only nine patients had symptoms for less than six months. Adult patients were typically referred for further investigation with 29 patients undergoing magnetic resonance imaging and seven patients diagnostic arthroscopy. Children were not referred for imaging routinely. In more severe child cases plain radiography was used to exclude dysplasia. Six patients were classified as Stanmore type 2 with the majority of 60 classified as type 3 (with the caveat that 30 of the youngest patients had not had detailed investigations). All patients displayed clinical signs of shoulder laxity in at least one direction. Five patients had a prior formal diagnosis of Ehlers-Danlos Syndrome (hypermobility-type). 18 patients had

symptomatic anterior instability, 17 posterior instability and 31 had both anterior and posterior instability. Patients with type 2 instability despite some structural abnormality still responded well to treatment with mean OSIS improvement 16.83 points (range 6–32) and WOSI 40.25% (range 24.71–63.29), all above the MCID for each outcome measure. Patients who completed the programme (n = 51) attended for a mean of 6.9 sessions over a mean of 30 weeks.

Of the 66 patients, 51 completed the programme up to a point of agreed discharge. Three patients did not re-attend after the first visit so no OISS data was available for comparison from these patients. The mean OISS (n = 51) improved from 38.00 to 21.96 (p < 0.001). Including patients that did not complete follow-up in a sensitivity analysis, the mean OISS (n = 63) improved from 38.41 to 24.46 (p < 0.001). The mean WOSI (n = 51) improved from 45.10% to 85.81% (p < 0.001). In terms of the four WOSI sub-groups: the 'Physical' domain improved from mean 47.98%–81.19% (p < 0.001), the 'Sport & Work' domain improved from mean 40.17%–82.00% (p < 0.001), the 'Lifestyle' domain improved from 50.73% to 83.45% (p < 0.001) and the 'Emotions' domain improved from 32.84% to 79.78% (p < 0.001). The results are summarised in Table 1.

### 4. Discussion

Our findings suggest that the Derby Shoulder Instability Rehabilitation Programme significantly improves the symptoms of patients with atraumatic shoulder instability whether they have a structural lesion (i.e. Stanmore Type 2) or not. Likewise, there was no difference if the patient suffered from anterior instability, posterior instability or both. Adherence to treatment was high with 51 out of 66 patients (77%) completing the programme to an agreed end point. Of the remaining 15 that did not, two relocated geographically due to work/university, one suspended treatment due to pregnancy and is yet to return, and one contacted the department to state they were much improved but failed to return the final outcome questionnaires. Five of the 15 patients that failed to complete the programme had achieved greater than the 4.5-point MCID of the OISS at their last visit. Of those that completed the programme 46 out of 51 (90%) surpassed the MCID of the OISS. Interestingly one 13-year-old patient did not meet the MCID of both the OISS and WOSI but subjectively reported that they were greatly improved. This perhaps suggests an initial lack of understanding of the outcome questionnaires having scored very highly at baseline. Two other patients that failed to meet the MCID of the OISS had a clinically important 26- and 27-point respective improvement in WOSI suggesting that the outcome measures may not correlate perfectly. Indeed, analysis of our complete dataset found a Pearson's correlation coefficient of 0.70 between the change in OISS and the change in WOSI scores. Overall, 54 of 66 patients (82%) found a meaningful improvement in symptoms based upon the MCID of the OISS.

As mentioned previously, there is limited evidence to guide physiotherapists when treating patients with atraumatic shoulder instability. Until recently the protocol by Burkhead & Rockwood<sup>15</sup> was the only reproducible exercise regime but this lacked detailed assessment of patient outcomes. Watson and colleagues have devised a different regime and reported their results of a service evaluation in 2017.<sup>16</sup> They also conducted a randomised clinical trial to compare the Watson protocol against the Burkhead & Rockwood protocol.<sup>17</sup> Whilst both regimes were found to be effective patients following the Watson protocol achieved greater improvements based upon the WOSI and Melbourne Instability Shoulder Scores. In Table 2 the outcomes of our study are compared against the WOSI and OISS scores reported by the Watson group.<sup>16</sup> This suggests that similar results can be achieved using the Derby

**Table 1**  
Results – The change in mean Oxford Instability Shoulder Score (OISS) and Western Ontario Shoulder Index (WOSI) domains between baseline and final follow-up.

	Baseline (Mean)	Final Follow-up (Mean)	Significance	Number of patients
OISS	38.00 points	21.96 points	p < 0.001	51
OISS (sensitivity analysis)	38.41 points	24.46 points	p < 0.001	63
WOSI (Total)	45.10%	85.81%	p < 0.001	51
WOSI (Physical)	47.98%	81.19%	p < 0.001	51
WOSI (Sport & Work)	40.17%	82.00%	p < 0.001	51
WOSI (Lifestyle)	50.73%	83.45%	p < 0.001	51
WOSI (Emotions)	32.84%	79.78%	p < 0.001	51

**Table 2**  
A comparison of treatment outcomes between the Derby and Watson protocols.

	Derby Protocol	Watson Protocol <sup>16</sup>
<b>Total Patients</b>	<b>66</b>	<b>43</b>
<b>Patients Completed Treatment</b>	<b>51</b>	<b>39</b>
<b>Follow up</b>	<b>30 weeks (mean, n = 51)</b>	<b>24 weeks</b>
<b>Sessions</b>	<b>6.9 (mean, n = 51)</b>	<b>12</b>
Baseline WOSI	45.10% (SD 18.00)	39.78% (SD 15.61)
End WOSI	85.81% (SD 16.33)	77.04% (SD 12.01)
<b>Change in WOSI</b>	<b>40.71% (n = 51)</b>	<b>37.26% (n = 39)</b>
Baseline OSIS	38.00 (SD 8.19)	35.76 (SD 8.59)
End OSIS	21.96 (SD 7.03)	20.67 (SD 6.97)
<b>Change in OSIS</b>	<b>16.04 (n = 51)</b>	<b>15.09 (n = 39)</b>
Sensitivity Analysis	<b>13.95 (n = 63)</b>	–

protocol. The studies differ in the fact that the Watson study was conducted over a fixed 12-week time frame with patients attending on a weekly basis then outcomes measured at 24 weeks. Patients were only included if they had multi-directional instability (i.e. anterior and posterior) and were excluded if there was an underlying structural lesion. The Derby results are reported at final follow up ranging from 6 to 51 weeks with a mean of 30 weeks, though patients attended fewer times (mean 6.9). This is due to the nature of the Derby programme being self-managed, meaning that patients decide on their own follow-up intervals based upon their own schedules and target-driven exercise progressions.

It is important to acknowledge the limitations of this study. Atraumatic shoulder instability is potentially a life long condition and therefore conclusions drawn from a mean follow up of 30 weeks should be interpreted with some caution. Long term follow up is required for this patient group to assess whether such exercise programmes result in sustained improvements over long periods of time. Whilst our patients are advised to continue with regular exercise to maintain their functional improvement it remains to be seen whether this is achievable. Interestingly one patient in our cohort was previously treated as a young teenager based upon similar exercise principles, prior to the implementation of the formal programme, and their symptoms resolved. Seven years later as a university student they began to experience symptoms again with posterior subluxation every time the shoulder flexed beyond 90°. They attributed this to a change of lifestyle from regular sport and exercise to long hours spent at a desk. Having been guided through the rehabilitation programme again their symptoms resolved but it highlights the point that levels of exercise need to be maintained to prevent re-occurrence.

This study is also from a single centre and lacks a control or comparator intervention. It is though unlikely that patients' symptoms would have resolved naturally without treatment due to the length of symptoms (mean 34 months) and many of the patients having failed to improve with different physiotherapy interventions previously with other providers. This group of patients with atraumatic shoulder instability is difficult to study due to the relatively uncommon nature of the condition. We were only able to

identify such 66 patients over a five-year period in a large teaching hospital with wide catchment area. The only randomised trial on the subject conducted in Australia managed 41 patients over two years.<sup>17</sup> Our group of 66 patients though is the largest reported, equal to Burkhead & Rockwood,<sup>15</sup> and includes validated pathology-specific outcome measures. There is though a need to continue following this patient cohort to ascertain the outcomes in the longer term.

## 5. Conclusions

For patients with atraumatic shoulder instability the Derby Shoulder Instability Rehabilitation Programme provides significant benefit to patients in terms of pain, stability and function. Further study is required to assess whether such improvements can be sustained in the medium and long terms.

## Ethics

Ethical approval was not required because this was a service evaluation of current treatment practice.

## Declarations of interest

BS and SO: none.

MB reports personal fees from educational courses related to the assessment and treatment of shoulder disorders, outside the submitted work.

## Acknowledgments

The authors wish to thank Adam Smithson and Marie Morgan for demonstrating the exercises in Fig. 2.

## References

- Bateman M, Jaiswal A, Tambe AA. Diagnosis and management of atraumatic shoulder instability. *Journal of Arthroscopy and Joint Surgery*. 2018;5(2):79–85.
- Lewis A, Kitamura T, Bayley JIL. (ii) the classification of shoulder instability: new light through old windows!. *Curr Orthop*. 2004;18(2):97–108.
- Noorani A, Goldring M, Jaggi A, et al. BESS/BOA patient care pathways: atraumatic shoulder instability. *Shoulder Elbow*; 2018 [In Press] <https://doi.org/10.1177/1758573218815002>.
- Warby SA, Pizzari T, Ford JJ, Hahne AJ, Watson L. The effect of exercise-based management for multidirectional instability of the glenohumeral joint: a systematic review. *J Shoulder Elbow Surg*. 2014;23(1):128–142.
- Bateman M, Smith BE, Osborne SE, Wilkes SR. Physiotherapy treatment for atraumatic recurrent shoulder instability: early results of a specific exercise protocol using pathology-specific outcome measures. *Shoulder Elbow*. 2015;7(4):282–288.
- Barden JM, Balyk R, Raso VJ, Moreau M, Bagnall K. Dynamic upper limb proprioception in multidirectional shoulder instability. *Clin Orthop Relat Res*. 2004;420:181–189.
- Naughton J, Adams R, Maher C. Upper-body wobbleboard training effects on the post-dislocation shoulder. *Phys Ther Sport*. 2005;6(1):31–37.
- Swanik KA, Lephart SM, Swanik CB, Lephart SP, Stone DA, Fu FH. The effects of shoulder plyometric training on proprioception and selected muscle performance characteristics. *J Shoulder Elbow Surg*. 2002;11(6):579–586.
- Smith BE, Hendrick P, Bateman M, et al. Musculoskeletal pain and exercise-

- challenging existing paradigms and introducing new. *Br J Sports Med.* 2018. <https://doi.org/10.1136/bjsports-2017-098983>.
10. Smith BE, Hendrick P, Smith TO, et al. Should exercises be painful in the management of chronic musculoskeletal pain? A systematic review and meta-analysis. *Br J Sports Med.* 2017;51(23):1679–1687.
  11. Kirkley A, Griffin S, McLintock H, Ng L. The development and evaluation of a disease-specific quality of life measurement tool for shoulder instability. The Western Ontario Shoulder Instability Index (WOSI). *Am J Sports Med.* 1998;26(6):764–772.
  12. Dawson J, Fitzpatrick R, Carr A. The assessment of shoulder instability. The development and validation of a questionnaire. *J Bone Joint Surg Br.* 1999;81(3):420–426.
  13. Moser JS, Barker KL, Doll HA, Carr AJ. Comparison of two patient-based outcome measures for shoulder instability after nonoperative treatment. *J Shoulder Elbow Surg.* 2008;17(6):886–892.
  14. Kirkley A, Werstine R, Ratjek A, Griffin S. Prospective randomized clinical trial comparing the effectiveness of immediate arthroscopic stabilization versus immobilization and rehabilitation in first traumatic anterior dislocations of the shoulder: long-term evaluation. *Arthroscopy.* 2005;21(1):55–63.
  15. Burkhead Jr WZ, Rockwood Jr CA. Treatment of instability of the shoulder with an exercise program. *J Bone Joint Surg Am.* 1992;74(6):890–896.
  16. Watson L, Balster S, Lenssen R, Hoy G, Pizzari T. The effects of a conservative rehabilitation program for multidirectional instability of the shoulder. *J Shoulder Elbow Surg.* 2017;27(1):104–111.
  17. Warby SA, Ford JJ, Hahne AJ, et al. Comparison of 2 exercise rehabilitation programs for multidirectional instability of the glenohumeral joint: a randomized controlled trial. *Am J Sports Med.* 2017;46(1):87–97.



## Avoiding complications in elbow arthroscopy

William D. Harrison <sup>a,\*</sup>, Xenia Tonge <sup>a</sup>, Vijay Bhalaiak <sup>b</sup>

<sup>a</sup> Health Education England North-West, Mersey Deanery, Summers Rd, Liverpool, L3 4BL, UK

<sup>b</sup> Wirral University Hospital Trust, Arrowe Park Road, The Wirral, UK



### ARTICLE INFO

#### Article history:

Received 29 November 2018

Accepted 1 January 2019

Available online 2 January 2019

#### Keywords:

Elbow arthroscopy

Complications

Indications

Anatomy

### ABSTRACT

The elbow joint is a complex anatomical structure and is susceptible to a wide variety of complex pathologies, ranging from traumatic to inflammatory. Elbow arthroscopy is a challenging procedure with a steep learning curve and a high risk of iatrogenic injury. The indications for arthroscopic elbow surgery are discussed in this article, along with a suggested comprehensive surgical technique, including patient set-up and steps to avoid iatrogenic damage. There is detailed explanation of specific portal sites, with advantages and disadvantages of each, as well as the anatomical considerations. This article also reviews the available literature regarding the frequency of complications and in particular; nerve injury and ways in which they may be avoided.

Crown Copyright © 2019 Published by Elsevier, a division of RELX India, Pvt. Ltd on behalf of International Society for Knowledge for Surgeons on Arthroscopy and Arthroplasty. All rights reserved.

### 1. Introduction

Elbow arthroscopy is a challenging procedure, used for a variety of increasingly complex elbow pathologies. The elbow is complex hinge joint and is composed of the humeroulnar, humeroradial and radioulnar joints. It has tight access with a small working space, large fat pads and is bordered by important and delicate anatomical structures. The elbow contributes heavily towards upper limb function and can be compromised from seemingly innocuous pathologies and poor rehabilitation.

The theoretical advantages of arthroscopic surgery include decreased post-operative pain, improved articular diagnostic assessment, reduced heterotrophic ossification, better cosmesis and decreased morbidity. According to O'Driscoll et al.'s large case series from 1992, arthroscopy has a diagnostic benefit in over two-thirds of patients and a therapeutic benefit occurs in 60–95% of patients.<sup>1</sup>

The evidence base of elbow arthroscopy compared to that of the knee and the shoulder is much less established. The merits of arthroscopic assessment and treatment of the elbow are countered however, by a relatively high iatrogenic complication rate.<sup>1</sup> The risk of neurovascular injury in particular, compromises the regular use of elbow arthroscopy. As such, the indications for surgery remain

quite controversial. An understanding of the pathoanatomy of the elbow is crucial to successful surgery and the procedure. Gaining experience in elbow arthroscopy can be challenging due to the infrequency of cases. Quantifying the learning curve is difficult, however, experience is important factor for good outcomes.

#### 1.1. Current indications for elbow arthroscopy

The indications for elbow arthroscopy largely depend on the experience of the arthroscopist. Patient selection in elbow surgery is a key component to achieving good results. The most common broad indications in adults, with satisfactory outcomes include: debridement or fixation of osteochondral defects, clearance of posterior impingement and arthroscopic release of the post-traumatic stiff elbow, including plica.<sup>2</sup> Elbow arthroscopy is also an excellent option for debridement for septic elbow arthritis, synovectomy for inflammatory arthritis, loose body extraction and debridement for osteoarthritis.<sup>3</sup> See [Table 1](#).

Elbow arthroscopy is also a valid option in the management of paediatric and adolescent pathologies. Micheli et al. reviewed their practice of paediatric elbow arthroscopy showing their paediatric indications as follows: osteochondritis dessicans (58%), arthrofibrosis (20%), synovitis (10%), acute trauma (10%) and posterior olecranon impingement syndrome (10%).<sup>4</sup>

There is debate about the efficacy of arthroscopic tennis elbow release. A randomised, double-blind sham-controlled trial has been set-up (awaiting results) in order to compare arthroscopic release of extensor carpi radialis brevis (ECRB) with sham surgery.<sup>5</sup>

\* Corresponding author.

E-mail addresses: [will.d.harrison@gmail.com](mailto:will.d.harrison@gmail.com) (W.D. Harrison), [xenia.tonge@doctors.org.uk](mailto:xenia.tonge@doctors.org.uk) (X. Tonge), [vijaybhalaiak@nhs.net](mailto:vijaybhalaiak@nhs.net) (V. Bhalaiak).

**Table 1**  
Current indications for elbow arthroscopy.<sup>2–7</sup>

Common	Uncommon
Debridement of osteophytes	ECRB release
Release of soft tissue contractures	Adjunct to fracture fixation
Synovectomy	Diagnostic
Osteochondral defect management	
Washout for septic arthritis	
Removal of loose bodies	
Assessment of valgus instability	

The role of elbow arthroscopy as a diagnostic tool compared to established radiological options is controversial.<sup>6</sup> The authors' view is that a clear surgical target should be identified pre-operatively, given the high reported iatrogenic injury rates from the procedure itself. Therefore, it is recommended that the surgeon and the patient fully understand the diagnosis, the rationale and the surgical goals for elbow arthroscopy prior to undergoing the procedure.

Acute elbow trauma can also be managed arthroscopically, although much less frequent than elective indications. In a review article of 13 publications, van Tongel et al. summarised the use of arthroscopy in fracture management to include displaced radial head fractures, coronoid and capitellum fractures in adults and displaced radial neck and lateral humeral condyle fractures in children.<sup>7</sup> Soft tissue reconstruction in the form of distal biceps repair, medial avulsion of triceps repair and reconstruction of the radial ulnohumeral ligamentous complex have also been published.<sup>7</sup> These procedures are not mainstream and they have little evidence to support their efficacy. These indications are not recognised by the senior author.

As our understanding of elbow pathoanatomy is improving, surgical indications will continue to evolve and elbow arthroscopy is becoming a mainstream specialist procedure. Many indications for this surgery still pose considerable controversy and there is a paucity of level I and II research to provide guidance. Other areas of established arthroscopic practice; such as arthroscopy in the degenerative knee, and more recently, subacromial arthroscopic shoulder decompression have been shown to be less effective than previously thought.<sup>8,9</sup> The importance of these studies are to better understand the role of arthroscopic surgery in specific patient groups and guide patient selection.

## 1.2. Anatomical considerations

An understanding of the surface anatomy of the elbow is fundamental to safe portal positioning and understanding risk when using instruments inside the joint. Portal landmarks are discussed in detail in the next section. It is important to acknowledge that normal and pathological variants in the neuroanatomy exist around the elbow and that extravasation of fluid and other intra-operative circumstances can alter the usual pathway of the nerves. Also, it is very important to recognise that the neuroanatomy dynamically changes through flexion-extension and pro-supination.

Unlu et al. performed a cadaveric study of 20 specimens using Steinmann pins to simulate an arthroscopy portal. The proximity of the neurovascular structures to the pins was measured in five different positions. The radial nerve is considered a high risk structure, particularly from the anterolateral portal. The radial nerve showed significant proximity to the anterolateral portal in full elbow flexion, full elbow extension, and forearm supination. Although we pronate the forearm to protect the posterior interosseous nerve (PIN) during open surgery, there is evidence to

suggest that supination translates the PIN further from the joint capsule, and is preferred for arthroscopic surgery when working near the anterior capsule of the radial head.<sup>10</sup>

The distance between the median nerve and anterior portals was significantly decreased with full extension.<sup>11</sup> There was a significant 10–20% nerve-pin contact in their cadaveric series, although this does not correlate with the post-operative clinical manifestation of transient nerve injury after elbow arthroscopy which was quoted at 1.7% in a series of 416 patients.<sup>12</sup> The median nerve and brachial artery are at relatively low risk of injury as they are protected by brachialis and theoretically, the lateral decubitus positioning will allow the neurovascular structures to move anteriorly due to gravity.

Miller et al. looked at the relationship of nerves to the capsule after insufflation and also at varying degrees of flexion.<sup>13</sup> The key messages from the paper were that insufflation improved the distance of the nerve from the bone, however it did not displace the nerve from the capsule. This has implications for intra-articular debridement near the capsule, that may lead to nerve injury - known as a "from within-out injury".

The ulnar nerve lies on the medial head of triceps and posterior to the medial intermuscular septum. At the level of the elbow, it sits superficial to the capsule and the medial collateral ligament. The ulnar nerve is at risk in posterior compartment surgery, particularly if the instruments over penetrate through the capsule. The ulnar nerve also significantly limits instrumentation in the medial gutter.

## 1.3. Portals

Not only is it important to mark out the portals pre-operatively, but also to assess all available radiological imaging and to make a plan based on pathology for the likely portal utilisation and sequence during the case.

The nomenclature of the elbow portals has varied between literature sources and also over time, as the use of certain portals have gone out of favour. Table 2 describes the commonly used nomenclature of the portals and further discussion of the landmarks, hazards and uses are described below.

### 1.4. Medial portal

The anteromedial portal is 2 cm anterior and 2 cm proximal to the medial epicondyle and should be just anterior to the medial intermuscular septum. The trajectory of the trochar is towards the radial head and the advice is to stay on the bone. It provides an excellent view to the entire anterior compartment of the elbow and also the medial gutter. The anteromedial portal avoids damage to the medial antebrachial cutaneous nerve, however it lies 4–14 mm from the medial nerve and 9–17 mm from the brachial artery.<sup>14</sup> Avoiding extension at the time of portal creation is important as it has been shown to obliterate the bone-to-nerve distance in experimental cadaveric studies, making the risk of iatrogenic injury much higher. Pro-supination is ideally in a neutral position to avoid radial nerve damage from the anteromedial portal.<sup>10</sup> The portal is therefore made at 90° flexion and

**Table 2**  
Commonly used portals for elbow arthroscopy.

Medial	Posterior	Lateral
Anteromedial (also known as proximo-medial)	Posterocentral	Anterolateral
	Posterolateral	Proximal-lateral Midlateral (soft-spot) Accessory lateral

in neutral supination and the blunt trochar passes between the humerus and brachialis, which acts as a protective cushion to the anterior neurovascular structures.

### 1.5. Lateral portals

The anterolateral portal lies at proximal border of the lateral epicondyle and also approximately 1 cm anterior to the lateral epicondyle. Once again, care must be taken to avoid injury to the radial nerve which lies between 4 and 11 mm from this portal.<sup>14</sup> This portal is best made under direct vision, using an inside-out technique to avoid radial nerve injury. It is safe to pass the instruments from an anterolateral to posteromedial orientation, rather than entering the joint by pushing across transversely towards the neurovascular structures.

The proximal lateral portal is 1 – 2 cm proximal to the lateral epicondyle and is anterior to the lateral column of the distal humerus and is considered the safest portal to use. The proximal lateral portal in particular gives good visualisation of the entire anterior compartment including the lateral recess, medial capsule, coronoid process and anterior humeral fossa.

The midlateral utilises the same entry point and trajectory as the initial insufflation needle in the soft-spot of the elbow, in the middle of triangle of the lateral olecranon, the radial head and the lateral epicondyle. The main structure at risk is the posterior antebrachial cutaneous nerve. It is used in each case for the insufflation of the joint capsule and can also be used as a visualisation and instrumentation portal for the inferior radiocapitellar joint and radioulnar joint.

Accessory lateral portals can be placed around the areas between the posterolateral (described below) and the midlateral portals. They provide alternative access to pathologies of the radiocapitellar joint and can be considered an augment to visualisation or difficult access for instrumentation in this tight area.

### 1.6. Posterior portals

The posterolateral portal is 2–3 cm proximal from the tip of the olecranon in the 90° flexed elbow and lies on the lateral border of

the triceps tendon. The structures at risk with this portal are the medial and posterior antebrachial cutaneous nerves, however it is also considered a relatively safe portal. It gives good visualisation of the entire posterior compartment and the lateral gutter with access to the radiocapitellar joint. It is the primary posterior portal in most cases.

The posterocentral portal is in the midline of the elbow, 3 cm proximal to the tip of the olecranon. It is a safe portal and penetrates through the triceps tendon. It uses are for visualisation and instrumentation of the olecranon tip, the humeral fossa and the humeral trochlea. It can also be used to assess the medial gutter and for safe removal of loose bodies found in the posterior compartment.

### 1.7. Surgical technique

Surgical technique is not prescriptive, but the following are a series of recommendations to reduce the risk of iatrogenic injury. Clinical reassessment should be performed on the day of surgery to assess the overlying skin, the range of movement in the elbow, range of movement in the shoulder and a full neurovascular assessment. Deformity and the chronically contracted elbow are important to recognise pre-operatively as it can lead to aberrant position of the neurovascular structures.<sup>2</sup> A subluxating ulnar nerve may also be identified clinically and is best felt proximal to the medial epicondyle.<sup>15</sup>

The first step is an examination under anaesthesia of the elbow assessing the range of movement and evidence of instability. Options for positioning include supine, prone and lateral decubitus. Positioning for arthroscopy is usually in the lateral decubitus position with elbow in 90° flexion, which is the senior authors preferred method (See Fig. 1). Lateral decubitus, or even prone positioning, make the posterior compartment more accessible and the limb more stable during work. The lateral position theoretically may allow the anterior neurovascular structures to move away from the capsule by gravity.

The advantage of the supine position is a more anatomic position, easier to convert to an open medial collateral ligament reconstruction and it is easier for the anaesthetist. The

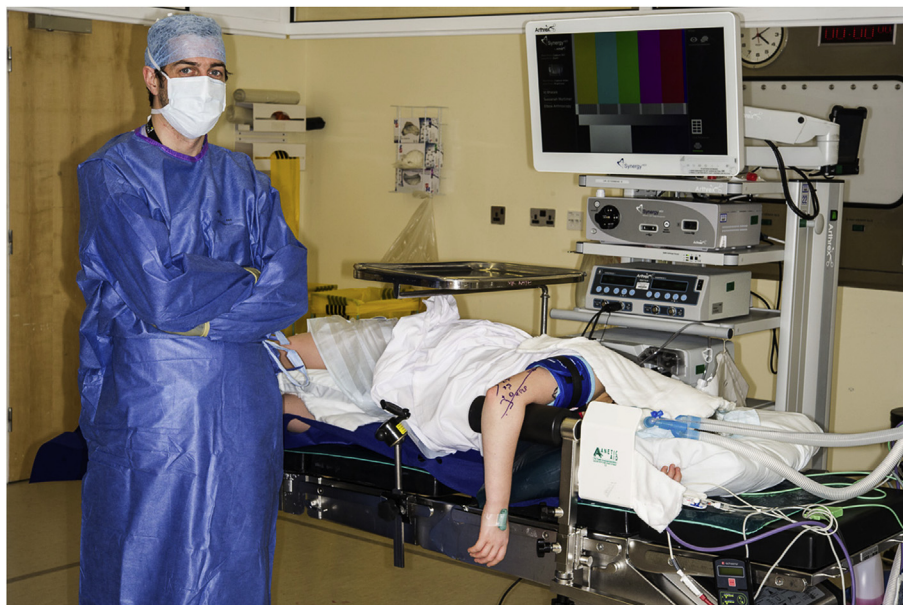

Fig. 1. Patient positioning. Lateral decubitus with a Mayo table over the patient for tool placement and an arm bolster to bring the elbow to 90° of flexion.

disadvantages of supine positioning include the set-up for limb suspension, stability of the arm whilst working, and difficulty accessing the posterior compartment.

An above-elbow tourniquet is placed with an impervious shut-off drape. Chinese finger traps provide excellent hold of the distal upper limb. Landmarks are drawn up; the olecranon, triceps tendon, medial and lateral epicondyles, radial head and the likely paths of the ulnar, radial/posterior interosseous and median nerves (see Figs. 2–4). It is better to define landmarks and all portals at the start, rather than halfway through the procedure when swelling can compromise accuracy. A Mayo table can be placed over the midriff portion of the patient to enable the passage of instruments and improve ergonomics.

The WHO checklist and exsanguination of the limb are performed and the forearm is bound with a crepe bandage. It is recommended that the bandage is not too tight as it can lead to neuropraxia. Insufflation of the joint is performed using a 20 ml syringe of normal saline to the midlateral portal described as the soft spot in the middle of triangle of the lateral olecranon, the radial head and the lateral epicondyle (see Fig. 5). Joint insufflation increases the bone-to-nerve distance by 12 mm for median nerve and 6 mm for radial nerve and reduces the risk of damage at the portal site.<sup>13</sup> It is however, important to note that joint insufflation does not increase the capsule-to-nerve distance.<sup>13</sup> This is important as intra-operative diathermy and instrumentation near the capsule can easily lead to nerve damage. Confirmation of joint insufflation is made by seeing fullness in the olecranon fossa and re-filling of the syringe once thumb pressure is removed (indicating that the

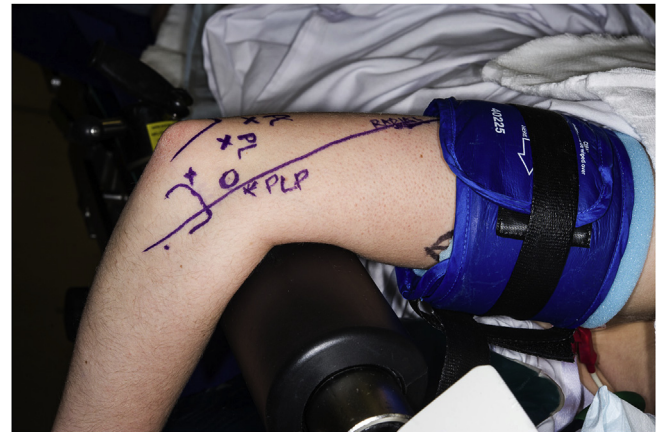

Fig. 3. Surface landmarks – lateral view. PLC refers to the proximalateral portal. Note the area of the midlateral portal (soft spot), marked with an “X” and the relation of the radial nerve to the PLC.

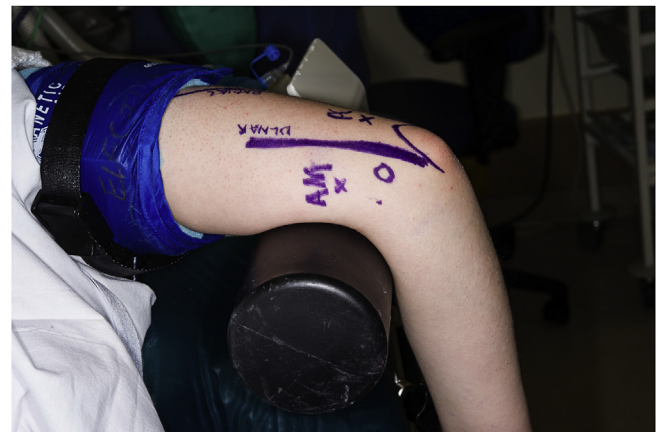

Fig. 4. Surface landmarks – medial view. AM refers to the anteromedial portal which is adjacent to the ulnar nerve.

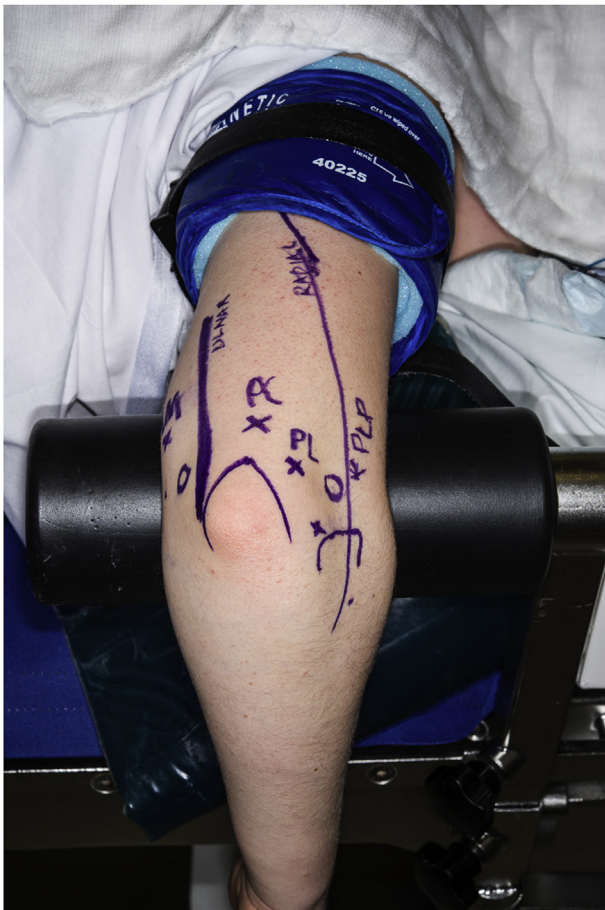


Fig. 2. Surface landmarks – posterior view. PC refers to the posterocentral portal and PL is the posterolateral portal.

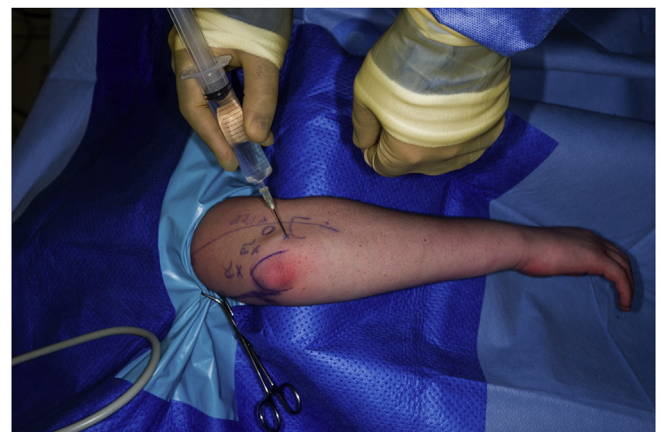
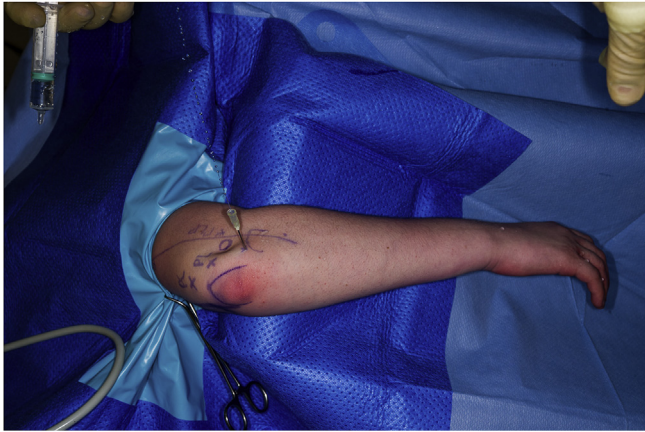
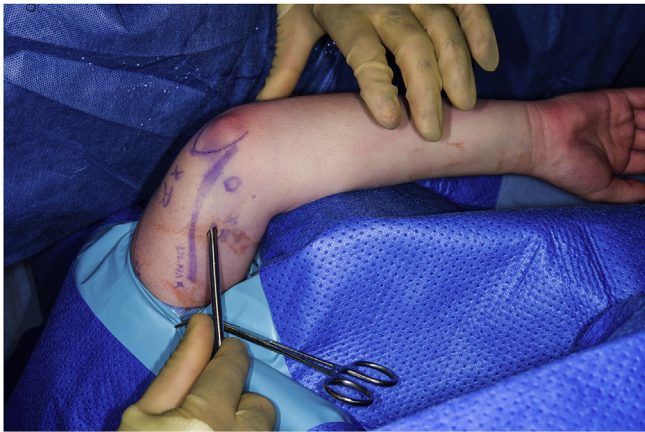Fig. 5. Joint insufflation into the midlateral portal (soft spot) with a 20 ml syringe.

fluid has not extravasated into the soft tissues). (See Fig. 6).

The dermal layer only is incised with a 15 blade and then systematic and careful blunt dissection is made down to the joint capsule in a “nick and spread technique”. The elbow capsule is breached with a blunt trocar (see Fig. 7), at which point saline will



**Fig. 6.** Confirmation of joint insufflation, with a jet of saline seen after the removal of the syringe. The needle can be left in situ and used as an irrigation portal.



**Fig. 7.** Access to the anteromedial portal. Initially with a “nick and spread” technique followed by a blunt trochar to access the joint. Note the arm is at 90° flexion.

pass through the portal. A 4.5 mm scope using a low-flow cannula is passed into the joint and pressurised with 30 mmHg of irrigating fluid. Avoid high pressures within the elbow as it can easily lead to capsule rupture. A smaller scope, such as a 2.7 mm may be used for posterior portals and paediatric patients. Using a scope with no perforations near the tip can reduce intraoperative extravasation. Excessive fluid pressure and prolonged operating time can lead to capsular damage, intra-articular bleeding and extravasation of fluid. All these factors can contribute to inadvertent neurovascular damage. The most important step in fluid management is balancing the inflow and the outflow. A tip for reducing extravasation volumes is to gently bind the forearm intraoperatively with a bandage. Once the procedure is complete, the unwrapping of the forearm will allow locally high pressure extravasation at the portals to easily diffuse into the remainder of the forearm. Factors that reduce the operative time include the ergonomics of the set-up, the experience of the surgeon, the assistant and the scrub team. The elbow is re-examined after the procedure to assess the range of movement, particularly for impingement and stiffness indications.

Once the scope is within the joint, intra-operative principles to reduce iatrogenic damage include portal placement under direct vision (particularly the anterolateral portal), gentle movement within the joint to avoid chondral damage, avoidance of suction shaver or diathermy near the anterior capsule of the elbow and always debride under direct vision. Hooded burrs reduce the risk of

inadvertent iatrogenic injury and focus the mind to a smaller area of activity. The efficient use of portals allows better visualisation and access to various areas of the joint. Decision making of portal use comes with experience. Moving between portals requires care and can be supplemented by using retractors or sheaths to pass the scope over. The same care needs to be taken when re-utilising a portal as when it was first created. Infiltration of the local anaesthetic to the joint can be a useful option for analgesia, but has a risk of transient postoperative nerve palsy from extravasation of fluid from the joint capsule to the surrounding nerves.

### 1.8. Complications

A number of case reports and small series have reported traumatic nerve palsies with an alarming frequency. The mainstay of the current literature on elbow arthroscopy explore the indications and the nuance of portal positioning. There are no randomised controlled trials assessing the efficacy of elbow arthroscopy.

Two large retrospective series report over 800 cases of elbow arthroscopy and give us the best insight into the risks of surgery – which are discussed below.<sup>12,16</sup> The indications for surgery from both articles pooled from a wide range of inflammatory, degenerative and traumatic aetiologies, with a variety of intra-operative procedures being undertaken in both series.

The superficial infection rates ranged from 7 to 11% and deep infection from 0.8 to 2.2%.<sup>12,16</sup> The use of intraoperative steroid injection had a significant contribution towards the development of infection ( $P < 0.0001$ ).<sup>12</sup>

Persistent contracture of  $<20^\circ$  occurred in 1.5% of cases and half of these required return to theatre for manipulation as a second procedure. There were no cases in either series of persistent post-operative contracture  $>20^\circ$ .<sup>12,16</sup>

There is speculation that major nerve palsies are under-reported in the literature following elbow arthroscopy.<sup>17</sup> Kelly et al. reported 2.5% (12/473) had transient nerve palsies.<sup>16</sup> The nerve palsies were broken down into; five ulnar palsies (1%), four superficial radial palsies (0.8%), one posterior interosseous palsy (0.2%), one medial antebrachial cutaneous palsy (0.2%), and one anterior interosseous palsy (0.2%). An underlying diagnosis of rheumatoid arthritis ( $p < 0.001$ ) and a pre-operative contracture ( $p < 0.05$ ) proved to be the most significant risk factor for nerve palsy. This low rate of transient nerve palsy was mirrored in the paper by Nelson et al. who reported just 1.7% (7/417) cases developing these temporary symptoms.<sup>12</sup> There were no persistent neurological injuries in either series, nor any complication of vascular injury, haematoma or compartment syndrome.<sup>12,16</sup>

“Major complications” occurred in 5% of cases, often requiring further surgery. The indications for return to theatre included washout for deep infections (9/473), heterotrophic ossification (6/473), and manipulation under anaesthesia for persistent contracture (4/473).<sup>16</sup>

Nelson et al. adjusted for the case complexity against the presence of complications and concluded that “complexity does not appear to affect the rate of complications with modern surgical techniques”.<sup>12</sup> However, these types of post-hoc subgroup analyses are fraught with type II error and therefore are not reliable.

### 1.9. Checklist of recommendations to reduce risks of surgery

1. Pre-operative physical examination to assess for deformity and subluxating ulnar nerve
2. Marking of anatomic landmarks and likely portals
3. Pre-operative joint capsule distension
4. Portal placement with the elbow at 90°
5. Use of a “nick and spread” technique



6. Place portals under direct vision when possible
7. Recognise that the neuroanatomy is dynamic with elbow movement
8. Avoiding radiofrequency diathermy and burring with suction when in the proximity of nerves; especially in the posteromedial corner and anterior capsule
9. Familiarity with the advantages of, preferably, five portals.<sup>2</sup>

#### Declarations of interest

None.

#### Conflicts of interest

This research did not receive any specific grant from funding agencies in the public, commercial, or not-for-profit sectors.

#### Appendix A. Supplementary data

Supplementary data to this article can be found online at <https://doi.org/10.1016/j.jajs.2019.01.001>.

#### References

1. O'Driscoll SW, Morrey BF. Arthroscopy of the elbow. Diagnostic and therapeutic benefits and hazards. *J Bone Joint Surg Am*. 1992;74(1):84–94.
2. Doornberg JN, Bexkens R, Thé B, Eygendaal D. Arthroscopy of the elbow. *Orthop Traumatol*. 2016;30(4):301–309. <https://doi.org/10.1016/j.mporth.2016.07.001>.
3. Adams JE, King GJ, Steinmann SP, Cohen MS. Elbow arthroscopy: indications, techniques, outcomes, and complications. *J Am Acad Orthop Surg*. 2014;22(12):810–818. <https://doi.org/10.5435/jaaos-22-12-810>.
4. Micheli LJ, Luke AC, Mintzer CM, Waters PM. Elbow arthroscopy in the pediatric and adolescent population. *Arthroscopy*. 2001;17(7):694–699. <https://doi.org/10.1053/jars.2001.25338>.
5. Matache BA, Berdusco R, Momoli F, Lapner PLC, Pollock JW. A randomized, double-blind sham-controlled trial on the efficacy of arthroscopic tennis elbow release for the management of chronic lateral epicondylitis. *BMC Musculoskelet Disord*. 2016;17(1):239. <https://doi.org/10.1186/s12891-016-1093-9>.
6. Torabi M, Martell B, Tuohy C, Lenchik L. MRI–arthroscopy correlation of the elbow: a primer for radiologists. *Curr Radiol Rep*. 2016;4(2):10. <https://doi.org/10.1007/s40134-015-0137-5>.
7. van Tongel A, Macdonald P, van Riet R, Dubberley J. Elbow arthroscopy in acute injuries. *Knee Surgery. Sport Traumatol Arthrosc*. 2012;20(12):2542–2548. <https://doi.org/10.1007/s00167-012-1904-y>.
8. Sihvonen R, Paavola M, Malmivaara A, et al. Arthroscopic partial meniscectomy versus sham surgery for a degenerative meniscal tear. *N Engl J Med*. 2013;369(26):2515–2524. <https://doi.org/10.1056/NEJMoa1305189>.
9. Beard DJ, Rees JL, Cook JA, et al. Arthroscopic subacromial decompression for subacromial shoulder pain (CSAW): a multicentre, pragmatic, parallel group, placebo-controlled, three-group, randomised surgical trial. *Lancet*. 2018 Jan 27;391(10118):329–338.
10. Arrigoni P, Cucchi D, Menon A, et al. The posterior interosseous nerve crosses the radial head midline and increases its distance from bony structures with supination of the forearm. *J Shoulder Elbow Surg*. 2018;Nov(18):S1058–S2746. <https://doi.org/10.1016/j.jse.2018.08.019>, 30614-1.
11. Unlu MC, Kesmezacar H, Akgun I, Ogut T, Uzun I. Anatomic relationship between elbow arthroscopy portals and neurovascular structures in different elbow and forearm positions. *J Shoulder Elbow Surg*. 2006;15(4):457–462. <https://doi.org/10.1016/j.jse.2005.09.012>.
12. Nelson GN, Wu T, Galatz LM, Yamaguchi K, Keener JD. Elbow arthroscopy: early complications and associated risk factors. *J Shoulder Elbow Surg*. 2014;23(2):273–278. <https://doi.org/10.1016/j.jse.2013.09.026>.
13. Miller CD, Jobe CM, Wright MH. Neuroanatomy in elbow arthroscopy. *J Shoulder Elbow Surg*. 1995;4(3):168–174. [https://doi.org/10.1016/S1058-2746\(05\)80047-3](https://doi.org/10.1016/S1058-2746(05)80047-3).
14. Lynch GJ, Meyers JF, Whipple TL, Caspari RB. Neurovascular anatomy and elbow arthroscopy: inherent risks. *Arthroscopy*. 1986;2(3):190–197. [https://doi.org/10.1016/S0749-8063\(86\)80067-6](https://doi.org/10.1016/S0749-8063(86)80067-6).
15. Hilgersom NFJ, Cucchi D, Luceri F, et al. Locating the ulnar nerve during elbow arthroscopy using palpation is only accurate proximal to the medial epicondyle. *Knee Surg Sports Traumatol Arthrosc*. 2018 Aug 23. <https://doi.org/10.1007/s00167-018-5108-y> [Epub ahead of print].
16. Kelly EW, Morrey BF, O'Driscoll SW. Complications of elbow arthroscopy. *J Bone Joint Surg Am*. 2001;83-A(1):25–34. [https://doi.org/10.1016/s0749-8063\(85\)80038-4](https://doi.org/10.1016/s0749-8063(85)80038-4).
17. Desai MJ, Mithani SK, Lodha SJ, Richard MJ, Leversedge FJ, Ruch DS. Major peripheral nerve injuries after elbow arthroscopy. *Arthrosc J Arthrosc Relat Surg*. 2016. <https://doi.org/10.1016/j.arthro.2015.11.023>.



Contents lists available at ScienceDirect

## Journal of Arthroscopy and Joint Surgery

journal homepage: [www.elsevier.com/locate/jajs](http://www.elsevier.com/locate/jajs)

Research paper

## Bipolar radial head arthroplasty for management of radial head fractures



B. Hari Krishnan\*, Tej Pratap Gupta

Dept of Orthopaedics, Base Hospital, Lucknow, Uttar Pradesh, PIN - 226002, India

## ARTICLE INFO

## Article history:

Received 25 March 2018

Accepted 17 September 2018

Available online 18 September 2018

## 1. Introduction

Radial head fractures constitute approximately 4% of all fractures in adults and represent over 30% of fractures around elbow joint.<sup>1–3</sup> Radial head fractures are known to occur in young and active individuals aged between 20 and 60 years.<sup>4</sup> These fractures present as an isolated lesion or may present in association with other injuries such as fracture of the coronoid process, medial collateral ligament tear, injury to the interosseous membrane and the triangular fibrocartilage complex. These injuries may render the elbow joint unstable to valgus stress, leading to axial instability of the forearm with subluxation of the distal radio-ulnar joint.<sup>4–6</sup>

The principal goal of treatment of radial head fractures is its anatomical preservation, to stabilize the forearm in axial as well as valgus loading of upper limb and regain good pain free elbow function, with ability to achieve adequate motion and joint stability.<sup>7–10</sup> The critical role played by the radial head in overall stability of the elbow and forearm emphasizes the need for all attempts at its reconstruction by internal fixation or to replace it with a prosthesis rather than excision.

Most radial head fractures with extensive comminution are non-reconstructable. Their surgical treatment requires radial head excision or replacement using a prosthesis.<sup>11</sup> Radial head excision alone leads to altered kinematics and instability of the elbow. With radial head replacement, the kinematics and stability of the elbow are restored to near normalcy.<sup>12</sup>

The comminuted fractures of the radial head are mostly treated by excision in most Indian hospitals. However, complications such

as cubitus valgus, elbow stiffness, proximal migration of radius, chronic wrist pain and degenerative changes may develop following initial successful treatment.

The lack of radiocapitellar joint may also lead to chronic elbow pain due to degenerative changes in the ulno-humeral joint.<sup>13,14</sup>

Also, when these radial head fractures are associated with ligamentous injury, simple excision generally result in elbow instability in the young. These may be overcome by a prosthetic replacement of the radial head following excision of the radial head.

The ideal radial head prosthesis is still in evolution. Various prosthesis with cemented or a cementless stem and mono/bipolar or modular heads are available in developed nations. However these are not available in India till date. Few indigenous designs are available; however these require further evaluation as regards their metallurgy, bearing surfaces, biomechanical suitability and ease of carrying out the replacement during surgery. We used an indigenously designed and manufactured titanium bipolar radial head prosthesis with a surface-textured stem (Phoenix Surgicals, India) in our study. (Fig. 1).

## 2. Materials and methods

An observational descriptive study was carried out on thirty patients between years 2013–14 requiring radial head replacement at a tertiary care Orthopaedic centre. The aim was to study the clinical outcomes in patients of non-reconstructable comminuted fractures of radial head managed with radial head replacement prosthesis. The objectives were

- To describe early clinical outcome following prosthetic replacement of radial head with regards to symptomatic relief in pain, recovery of motion, grip strength and stability.
- To assess the loosening of prosthesis and proximal migration of radius on post-operative follow up radiographs.

Informed written consent from patients and institutional ethical clearance was obtained to carry out the study.

The inclusion and exclusion criteria for the study were as follows:

Inclusion criteria - Radial head fractures in adults with skeletal

\* Corresponding author.

E-mail address: [hari\\_os@yahoo.co.in](mailto:hari_os@yahoo.co.in) (B. Hari Krishnan).




Fig. 1. Titanium Bipolar Radial head prosthesis.

maturity where radial head was comminuted and non-reconstructable.

**Exclusion criteria** – Pathological fracture, paediatric radial head fracture, psychological and/social conditions with poor compliance, compound fracture/dislocation radial head, patients with known allergy/metallosis, radial head fractures with comminution extending more than a centimetre below the radial articular surface.

The signs of associated ligamentous injuries to the medial side of elbow (swelling, ecchymosis) was documented, however no change in treatment protocol was done, as all comminuted radial head fractures which were not reconstructable were replaced by prosthesis, irrespective of associated medial side injuries.

Patients were operated in a supine position with elbow resting over radiolucent side arm trolley. Kocher's lateral approach was used in all the patients. Radial neck was osteotomised a centimetre below the articular surface so as to have adequate mobility of the bipolar prosthetic head following its insertion. The diameter and length of excised radial head was measured and prosthetic replacement done using implant with 2 mm smaller diameter and the length of radius maintained. (Figs. 3–5). During prosthesis insertion, care was taken to keep the head portion of the prosthesis within the radioulnar joint surface. Any overstuffing of the radio-capitellar joint was avoided by adjusting the depth of insertion and assessed under direct vision. The autologous bone graft from excised head was used for grafting to achieve press fit of the prosthesis. No drains were placed during wound closure. Elbow and forearm movements were allowed in the immediate post-operative

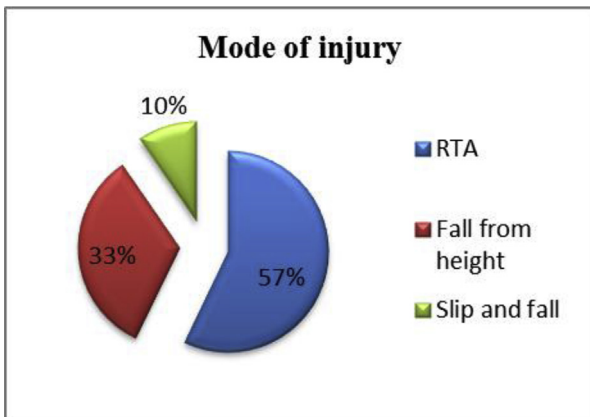


Fig. 2. Pie chart depicting mode of injury.

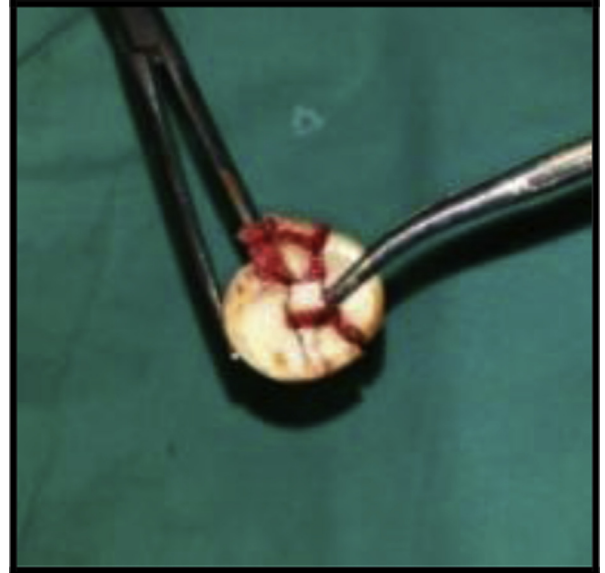


Fig. 3. Reconstruction of excised radial head for sizing.

period in all patients.

The following outcome measures evaluated in the study:

- Subjective - clinical relief of symptoms such as pain. 'Pain' was graded using visual analogue scale (VAS).
- Objective - range of motion, grip strength. 'ROM' of elbow flexion-extension and forearm pronation-supination was evaluated using 'hand-held goniometer'. 'Grip strength' was measured using hand held dynamometer and compared with normal limb.

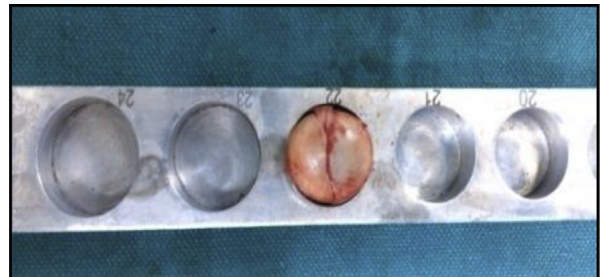


Fig. 4. Measurement of excised radial head using measuring gauge

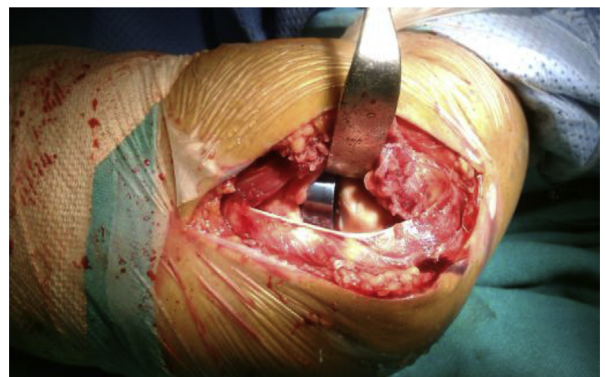


Fig. 5. Radial head prosthesis in situ prior to wound closure.

c. Radiological evidence of loosening of prosthesis and proximal migration of radius.

Follow-up examination was done at 06 weeks, 03 months, 06 months, 1yr and 2yrs using patient's subjective evaluation, functional outcome and radiographic assessment for complications, if any. AP and lateral radiographs of forearm including elbow and wrist was done to assess for loosening of prosthesis and proximal migration of radius. (Fig. 6).

An adverse event or complication was defined as any event that necessitated another operative procedure or additional medical treatment. Post-operative complications like surgical site infection, wound dehiscence, hardware prominence and scar related problems were also noted if any.

### 3. Observations & Results

30 patients of fracture radial head were managed by replacement. The follow-up rate was 100% at each examination till completion of study. The data analysis was done using SPSS software version 17. Paired *t*-test was used to find the association/significance between various variables. Fischer exact test was used for analysis of demographic variables with outcome variables. The observed results were determined to be significant if the P value was <0.05 and not significant if it was >0.05.

Mean age of patients was 36 years. The commonest mode of injury was road traffic accident.(66.66%),(Fig. 2). Comminuted fracture of radial head was seen more frequently in males (70%) (M: F = 21: 9). 04 patients had associated elbow dislocation which was reduced at the primary health care centre. 02 patients had terrible triad injury and 01 patient had associated olecranon fracture. No patient presented with Essex-Lopresti injury or distal radio-ulnar joint disruption. 60% had an injury to the dominant side.

Mean duration between injury and presentation to hospital was 8.3 days.14 patients (73.33%) were operated within 01 week of injury and remaining were operated within 1–4 weeks due to late presentation. Additional procedures involved tension band wiring for olecranon fracture and interfragmentary screw fixation for coronoid fracture in one patient each. There was no surgical site infection or wound dehiscence.

Mean tourniquet time was 55 min. Mean duration of hospital stay was 8 days. Initial 02 patients who were operated, underwent

implant removal at 03 months for restricted ROM of elbow joint. One patient had associated olecranon fracture and other had associated posterior dislocation of elbow joint as initial injury. In both these patients undersizing of the implant was not done and prosthesis of same size as native radial head was used which could have led to radio-capitellum overstuffing resulting in restricted ROM. Following implant removal these patients had significant improvement in ROM. Intra operatively one patient had features suggestive of 'metallosis' while other had heterotopic ossification (HO) (not significant to affect the ROM and did not progress on further follow up). Both patients developed wrist pain and valgus instability at 06 month follow up.

#### 3.1. Functional outcome at 06 weeks post op

'Subjective outcome analysis' included elbow pain evaluation using visual analogue score (VAS). The VAS scores were grouped into 03 i.e. mild (<2), moderate (3–7) and severe (>7). The group median VAS was 5; 02 patients (6.66%) had VAS between 3 and 7 while 28 patients (90.5%) had VAS <2. None of the patients had wrist pain and elbow valgus instability.

'Clinical outcome analysis' included elbow flexion, forearm ROM i.e. pronation and supination, grip strength and deformity i.e. fixed flexion deformity at elbow. ROM was grouped into 03 groups i.e. <90°, 90–120° and >120°. Mean elbow flexion was found to be 83° (SD = 8.58). 17 patients (81%) had <90° elbow flexion and 04 patients (19%) were having flexion between 90 and 120°. None of the patients had ROM >120°.

Forearm pronation and supination was evaluated and grouped into 2 groups i.e. <45° and >45°. Mean forearm pronation was found to be 37.6°. 17 patients (81%) had <45° pronation. Mean forearm supination was found to be 40.7°. 12 patients (57%) had >45° supination. Grip strength was evaluated using hand held dynamometer and compared with contralateral normal limb. Mean grip strength was found to be 24%; 18 patients (85.7%) had grip strength <25%. Stiffness and deformity were evaluated and measured using hand held goniometer. Patients were grouped into 2 groups i.e. <30° and >30° fixed flexion deformity. Mean fixed flexion deformity was found to be 37.3°. 19 patients (90.5%) had fixed flexion deformity >30°.

None of the patients had implant loosening in follow up radiographs. 01 patient (4.8%) had radiological evidence of HO in the flexor aspect; however, it did not restrict elbow ROM, hence was offered no active treatment.

#### 3.2. Functional outcome at 03 months post op

Elbow pain evaluation using VAS score showed median score of 2; 17 patients (81%) had VAS <2. None of the patients had wrist pain or elbow valgus instability. Mean elbow flexion was 109° with 19 patients (90.5%) having flexion between 90 and 120°. Mean forearm pronation was 52.3° with 18 patients (85.7%) having >45° pronation. Mean forearm supination was 56.6° with 18 patients (85.7%) having >45° supination. Mean grip strength at 03 months follow up was 55.4% with 11 patients (52.4%) having grip strength in the range of 25–50%. Mean fixed flexion deformity was 25.4° with 15 patients (71.4%) having fixed flexion deformity <30°.

None of the patients had proximal migration of radius or implant loosening. No new case of heterotopic ossification was found. 02 patients underwent implant removal at 03 months follow up.

#### 3.3. Functional outcome at 06 months post op

Elbow pain evaluation using VAS showed median score of 1; all

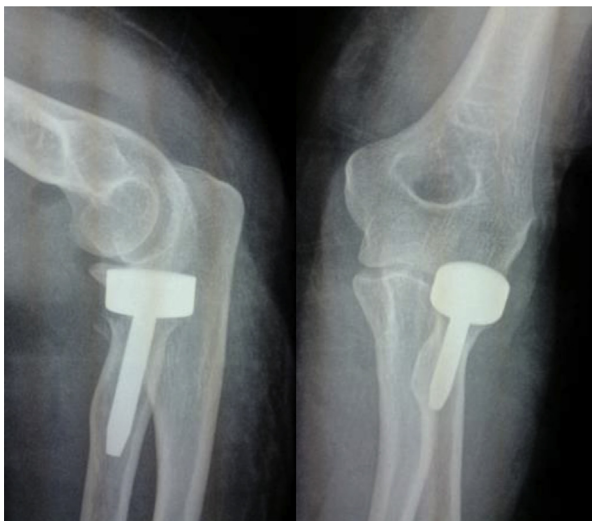

Fig. 6. Lateral & AP elbow radiographs with radial head prosthesis.

patients had VAS <2. Mean elbow flexion was 126° with 16 patients (76.2%) having elbow flexion >120°. Mean forearm pronation was found to be 71° with 19 patients (90.5%) having >45° pronation. Mean forearm supination was 73° with all patients having supination >45°. Mean grip strength was 79.5% with 12 patients (57%) having grip strength >75% compared to other side. Mean fixed flexion deformity was 14°; all patients had fixed flexion deformity <30°.

Radiographs revealed no proximal migration of radius or implant loosening. No new case of heterotopic ossification was detected. However, 02 patients (9.5%) who underwent implant removal at 03 months follow up developed valgus instability and wrist pain.

Significant difference between mean elbow flexion, forearm pronation/supination and grip strength was noted at 6 weeks compared with similar movements at 3 months, and between ROM at 6 weeks and 6 months by using unpaired *t*-test ( $p < 0.05$ ). By using paired *t*-test ( $p < 0.05$ ); there was significant difference between mean elbow FFD at 6 week and at 3 month and between 6 week and 6 month.

'Dominant side' had better grip strength at 06 weeks follow up as compared to non-dominant side ( $p < 0.05$ ); however, there was no difference in grip strength on further follow up at 03 and 06 months. Other outcome variables showed no association with dominance of hand. Patients with 'associated elbow injuries' had significantly reduced pronation at 03 months follow up ( $p < 0.05$ ). There was no difference at follow up at 06 months. Other outcome variables showed no association with associated elbow injuries. 'Duration from injury to surgery' had significant association on grip strength at 06 weeks follow up ( $p < 0.05$ ). Patients operated within a week of injury had reduced grip strength; however, there was no difference in grip strength on further follow up. Other outcome variables showed no association with 'duration from injury to surgery'. Age and sex of the patient had no significant association with any of the outcome variables i.e. elbow and forearm ROM, grip strength and pain.

#### 3.4. Outcome at 01 and 02 years post op

There was no significant difference recordable in the clinical, radiological and functional outcome parameters of all the patients at 01 and 02 years follow up. None of the patient reported any remarkable changes from previous follow-up. No patient had radiological evidence of loosening or implant breakage at two years follow up.

#### 4. Discussion

The treatment of comminuted fractures of radial head remains controversial and challenging till date and no data is available from Indian subcontinent. Treatment outcomes are further worsened by associated injuries of the elbow. In spite of adequate fixation there is increased incidence of residual pain, stiffness, non-union, osteonecrosis of radial head and secondary osteoarthritis of radio-capitulum joint.<sup>15</sup>

Simple excision of the radial head in isolated uncomplicated fractures of radial head provides good symptomatic relief and full ROM in individuals leading sedentary lifestyle. However, in patients with non-reconstructable comminuted fractures of radial head, excision and radial head replacement is considered appropriate treatment. Poor results have been reported by Mikic, Josefsson, Hall and Leppilähti et al. in their respective studies after radial head excision.<sup>20–24</sup>

Radial head prosthesis restores elbow stability to a level similar to that of the normal elbow when a fracture of the radial head

occurs alone or in combination with dislocation of the elbow, rupture of the medial collateral ligament, fracture of the proximal ulna, or fracture of the coronoid process. The bipolar radial head implant acts as a spacer, allowing early soft tissue healing and restoration of mobility similar to native radial head.<sup>16</sup> Results of our study corroborates well with available evidence in existing literature.

Age and sex of the patient was found to have no significant statistical association with any of the 'outcome variables in our study'. Even though 'Sex of the patient' and pain score (VAS) had no statistically significant association, there was clinically increased duration of analgesics intake in 'male population' ( $P = 0.061$ ) in our study. This could be explained by the incidental presence of more 'associated elbow injuries' in male population (which was not a statistically significant association).

Doornberg JN, Shore and Grewal et al. noted multiple associated elbow injuries in their respective studies on radial head fractures. In patients with associated elbow injuries, significantly reduced pronation at 03 months follow up was noted ( $p < 0.05$ ). However, there was no difference in pronation at 06 months follow up. Other outcome variables showed no association with associated elbow injuries.<sup>17,18</sup> On evaluating the effects of 'hand dominance' on 'outcome variables' it was found that 'Dominant side' had better grip strength at 06 weeks follow up as compared to non-dominant side ( $p < 0.05$ ); however there was no difference in grip strength on further follow up at 03 and 06 months. Other outcome variables showed no association with dominance of hand.

On evaluating the effect of duration from injury to surgery on outcome variables, we noticed significant association on grip strength at 06 weeks follow up ( $p < 0.05$ ). Patients operated within a week of injury had reduced grip strength; however, there was no difference in grip strength on further follow up. Other outcome variables showed no association with 'duration from injury to surgery'.

Claudia lamas et al. in their follow up of 04 yrs on 47 patients found that VAS at rest was 1 and mean VAS during activity was 1.7.<sup>27</sup> In our study, at 06 weeks 19 patients (90.5%) had VAS of 3–7. At 03 months, 17 patients (81%) had VAS <2. At 06 months all patients had VAS <2.

There was significant difference ( $P < 0.05$ ) between mean elbow and forearm ROM and fixed flexion deformity at 6 week compared with ROM at 3 month, and between ROM at 6 weeks and 6 months. Our results corroborated well with observations of Grewal R et al., Hung-Yang Chien et al. and Claudia lamas et al.<sup>25–27</sup>

All patients were free of wrist pain and valgus instability at 06 weeks and 03 months follow up. However, in 02 patients (9.5%) implant had to be removed for restricted range of movements. On follow up at 06 months both patients had wrist pain and valgus instability. However, radiographs did not show any proximal migration of radius and differences in ulnar variance on comparing with contralateral side.

None of our patients developed proximal migration of radius or features of osteolysis/loosening till 06 months follow up in contrary to study by John C. Berschback et al. where all 27 patients had some form of lucency around stem on average follow up of 2 year.<sup>19</sup> In the study by John C. Berschback et al. almost 50% patients developed heterotopic bone mass and 4 out of total 27 had to undergo surgery for HO mass removal for restoration of movements.<sup>19</sup> In our study one patient had heterotopic ossification at 06 weeks follow up over the anterior aspect of radial tuberosity which did not increase in size and was found to be not interfering with ROM thus didn't require excision. All the patients were given Tab Indomethacin 25 mg three times a day for 03 weeks post op as prophylaxis for heterotopic ossification.

Grewal R et al. found considerable alteration in radiocapitellar

joint pressures with over lengthening of 2.5 mm.<sup>25</sup> Hung-Yang Chien et al. had prosthesis removal in 01 patient out of total 13 patients at 02 months follow up due to restricted ROM caused by overstuffing of implant.<sup>26</sup> In our study, 02 patients underwent implant removal at 03 month follow up for not gaining satisfactory range of movement of elbow joint. One had associated olecranon fracture and other had associated posterior dislocation elbow as initial injury, however these factors had no statistical association with restricted movements in remaining patients. During index surgery both these patients were given implant size which were same as native radial head size. While in all other cases implant size was reduced by 2 mm while measuring assembled fragments of fractured radial head in 'sizer' on table. This ensured inserting prosthesis with size 2 mm less than the native radial head. This reduced radiocapitellar overstuffing and helped achieve satisfactory ROM. None of the patients with 'downsizing' of the implant had valgus instability at any follow up. In the 02 patients who underwent implant removal, intra operative findings included 'metallosis' in one patient while other had features suggestive of 'myositis' (not significant enough to affect the ROM and this HO did not progress on further follow up). Both patients developed wrist pain and valgus instability at 06 month follow up.

#### 4.1. Limitations

This study has few limitations. Apart from small sample size, the main limitation was that a single cohort with non-reconstructable radial head fractures was evaluated with no control or comparison group. The study does not assesses the complexity of pre-operative ligament injuries as well. The study was solely conducted to assess the outcome of an indigenously available prosthesis to manage non-reconstructable radial head fractures in terms of its capability to achieve post-operative pain relief and the incidence of prosthesis loosening and failure. The study does not compare any difference in the outcome in patients with either isolated radial head injuries or those with associated medial side ligamentous disruption.

#### 5. Conclusion

From our study, we have noticed that with our indigenously available radial head replacement prosthesis we were able to restore elbow stability with satisfactory results in terms of pain and elbow movements, and rapidity in regaining grip strength and power of elbow musculature in patients with non-reconstructable radial head fractures. Our results were in line with many other studies in existing literature. Patients were able to perform activities of daily living without any significant morbidity and there was no requirement of further intervention.

It appears that radial head replacement surgery for comminuted fractures of radial head produce satisfactory clinical outcome. However comparative study is needed to assess benefits of radial head replacement over radial head excision. Also studies need to be conducted to assess differences in outcome of replacement of radial head in isolated injuries and in those associated with medial side ligamentous disruption. Further randomized studies with larger sample size and follow up duration are required to determine the advantages of radial head replacement over excision of radial head, type of prosthesis used, bearing surfaces, stem design and other outcome variables.

#### Acknowledgement

Authors are grateful to DGAFFMS India for financial support for this research through AFMRC Project No. 4461/2013.

#### References

1. Court-Brown CM, Caesar B. Epidemiology of adult fractures: a review. *Injury*. 2006;37:691–697.
2. Duckworth AD, Clement ND, Jenkins PJ, Aitken SA, Court-Brown CM, McQueen MM. The epidemiology of radial head and neck fractures. *J Hand Surg*. 2012;37:112–119.
3. Ikeda M, Sugiyama K, Kang C, Takagaki T, Oka Y. Comminuted fractures of the radial head. Comparison of resection and internal fixation. *J Bone Jt Surg*. 2005;87-A:76–84.
4. An K, Morrey B. Biomechanics of the elbow. In: Morrey BF, ed. *The Elbow and its Disorders*. Philadelphia: WB Saunders; 2000:43–60.
5. Morrey B. Current concepts in the treatment of fractures of the radial head, the olecranon, and the coronoid. *J Bone Joint Surg*. 1995;77(2):316–327.
6. Davidson PA, Moseley jr JB, Tullos HS. A potentially complex injury. *Clin Orthop Relat Res*. 1993;297:224–230.
7. Hotchkiss RN. *Fracture and Dislocation of the Elbow*. Rockwood and Green's *Fractures in Adults*. 1996.
8. McKee M, Jupiter J. *Trauma to the Adult Elbow and Fractures of the Distal Humerus*. Philadelphia: Skeletal trauma Saunders; 1998:1455–1469.
9. Shore BJ, Mozzon JB, MacDermid JC, Faber KJ, King GJ. Chronic posttraumatic elbow disorders treated with metallic radial head arthroplasty. *J Bone Joint Surg Am Vol*. 2008;90(2):271–280.
10. Beingsner DM, Dunning CE, Gordon KD, Johnson JA, King GJ. The effect of radial head excision and arthroplasty on elbow kinematics and stability. *J Bone Joint Surg*. 2004;86(8):1730–1739.
11. Quintero J, Varecka T. *Olecranon/radial Head/complex Elbow Injuries*. Stuttgart: AO Principles of fracture management Thieme; 2000:323–339.
12. King GJ, Zarzour ZD, Rath DA, Dunning CE, Patterson SD, Johnson JA. Metallic radial head arthroplasty improves valgus stability of the elbow. *Clin Orthop Relat Res*. 1999;368:114–125.
13. Broberg MA, Morrey BF. Results of delayed excision of the radial head after fracture. *J Bone Jt Surg*. 1986;68-A:669–674.
14. Goldberg I, Peylan J, Yosipovitch Z. Late results of excision of the radial head for an isolated closed fracture. *J Bone Jt Surg*. 1986;68-A:675–679.
15. Harrington IJ, Sekyi-Otu A, Barrington TW, Evans D, Tuli V. The functional outcome with metallic radial head implants in the treatment of unstable elbow fractures: a long-term review. *Journal of Trauma and Acute Care Surgery*. 2001;50(1):46–52.
16. Ashwood N, Bain GI, Unni R. Management of Mason type-III radial head fractures with a titanium prosthesis, ligament repair, and early mobilization. *J Bone Joint Surg Am Vol*. 2004;86-a(2):274–280.
17. Doornberg JN, Parisien R, van Duijn PJ, Ring D. Radial head arthroplasty with a modular metal spacer to treat acute traumatic elbow instability. *J Bone Joint Surg Am Vol*. 2007;89(5):1075–1080.
18. Key JA, Conwell HE. *Fractures, Dislocations and Sprains*. St Louis: Mosby; 1951: 604–610.
19. Berschback JC, Lynch TS, Kalainov DM, Wysocki RW, Merk BR, Cohen MS. Clinical and radiographic comparisons of two different radial head implant designs. *J Shoulder Elbow Surg/American Shoulder and Elbow Surgeons [et al]*. 2013;22(8):1108–1120.
20. Ring D, Quintero J, Jupiter JB. Open reduction and internal fixation of fractures of the radial head. *J Bone Joint Surg*. 2002;84(10):1811–1815.
21. Mikic ZD, Vukadinovic SM. Late results in fractures of the radial head treated by excision. *Clin Orthop*. 1983;181:220–228.
22. Josefsson PO, Gentz CF, Johnell O, Wendeberg B. Dislocations of the elbow and intraarticular fractures. *Clin Orthop Relat Res*. 1989;246:126–130.
23. Leppilähti J, Jalovaara P. Early excision of the radial head for fracture. *Int Orthop*. 2000;24(3):160–162.
24. Hall JA, McKee MD. Posterolateral rotatory instability of the elbow following radial head resection. *J Bone Joint Surg*. 2005;87(7):1571–1579.
25. Grewal R, MacDermid JC, Faber KJ, Drosdowech DS, King GJ. Comminuted radial head fractures treated with a modular metallic radial head arthroplasty. Study of outcomes. *J Bone Joint Surg Am Vol*. 2006;88(10):2192–2200.
26. Chien HY, Chen AC, Huang JW, Cheng CY, Hsu KY. Short- to medium-term outcomes of radial head replacement arthroplasty in posttraumatic unstable elbows: 20 to 70 months follow-up. *Chang Gung Med J*. 2010;33(6):668–678.
27. Lamas C, Castellanos J, Proubasta I, Dominguez E. Comminuted radial head fractures treated with pyrocarbon prosthetic replacement. *Hand (New York, NY)*. 2011;6(1):27–33.



## Review article

# Medical management of wrist and hand inflammatory conditions: A literature review

Meenakshi Jolly <sup>a,\*</sup>, Asha Patnaik <sup>b</sup>, Courtney O'Brien <sup>a</sup>, Anupam Basu <sup>c</sup>, Augustine Manadan <sup>d</sup>

<sup>a</sup> Department of Medicine, Division of Rheumatology, Rush University Medical Center, Chicago, IL, USA

<sup>b</sup> Department of Medicine, Division of Rheumatology, Allergy and Immunology, Stony Brook University Hospital, SUNY, Stony Brook, NY, USA

<sup>c</sup> Department of Radiology, John H Stroger Hospital, Chicago, IL, USA

<sup>d</sup> Department of Medicine, Division of Rheumatology, John H Stroger Hospital, Chicago, IL, USA

## ARTICLE INFO

## Article history:

Received 12 October 2018

Accepted 23 November 2018

Available online 24 November 2018

## Keywords:

Inflammatory hand conditions

Rheumatoid arthritis

Systemic lupus erythematosus

Psoriatic arthritis

Crystalline arthritis

## ABSTRACT

Differential diagnosis for inflammatory arthritis of the hands includes infectious processes and autoimmune conditions like rheumatoid arthritis, systemic lupus erythematosus, and crystalline arthritis, among others. As medical management of the inflammatory arthritis is (a) targeted to the specific disease and severity of the symptoms, (b) posed with diagnostic dilemmas due to overlap in presentation, and (c) adversely affected by incorrect treatment which may further complicate the diagnosis and outcomes, reaching the correct diagnosis is pivotal towards appropriate management. Medical management may span from antibiotics, corticosteroids, non-steroidal anti-inflammatory drugs, to immunosuppressive medications (conventional synthetic DMARDs and biologic agents). Herein we discuss the medical management of the most clinically relevant inflammatory arthritides involving the hand.

© 2018 Published by Elsevier, a division of RELX India, Pvt. Ltd on behalf of International Society for Knowledge for Surgeons on Arthroscopy and Arthroplasty.

## 1. Introduction

Arthritis of the hand has a major impact not only on one's physical functioning and independence but also on one's daily quality of life. In general, prevalence estimates for arthritis of the hand are not available, except for osteoarthritis. Inflammatory arthritis is characterized by presence of synovitis. Diagnostic considerations for inflammatory arthritis are shown in [Table 1](#). These conditions may be stratified based on onset of symptoms (acute or chronic), number of joints involved (monoarticular, oligoarticular, or polyarticular), and pattern of joint involvement. This stratification aids in establishing a specific diagnosis when combined with thorough history taking, examination, laboratory, and/or imaging work up ([Table 2](#)). Infectious arthritis remains an important differential diagnosis for arthritis of the hand and thus should be excluded in the presence of concerning signs and symptoms. The coexistence of infectious and non-infectious arthritis in the hand has been reported but is relatively uncommon. Rheumatoid

arthritis is one of the autoimmune conditions that typically involves both hands and wrists in a bilateral symmetrical pattern. However, several non-rheumatoid arthritis conditions, such as crystalline arthritis (pseudogout) and systemic lupus erythematosus (SLE), may also present in a similar manner, which can pose a diagnostic challenge.<sup>1</sup> A review of salient features and medical management of the most clinically relevant non-infectious inflammatory arthritic conditions involving the hands is presented.

## 2. Rheumatoid arthritis

Rheumatoid arthritis (RA) is the most common symmetric inflammatory arthritis involving multiple joints, including the hands and wrists. The prevalence of RA has increased during the period 2004 to 2014, and the conservative estimate for RA in 2014 in the US was 1.28–1.36 million adults.<sup>2</sup> In a study of 200 patients with RA, 94% suffered from at least one hand or wrist related symptom within 2–4 years of disease duration, while 70% were found to have at least one impairment in the dominant hand on physical examination of the hand or wrist.<sup>3</sup>

Patients with RA typically present with symptoms of pain, swelling, and morning stiffness of the hands and wrists. Specific

\* Corresponding author. Professor of Medicine Rush University Medical Center, 1611 W Harrison Street, Suite 510, Chicago, IL, 60612, USA.

E-mail address: [Meenakshi\\_Jolly@Rush.edu](mailto:Meenakshi_Jolly@Rush.edu) (M. Jolly).

**Table 1**  
Differential diagnosis for inflammatory arthritis.

Inflammatory Mono- or Oligoarthritis (<4 Joints)	
Crystalline	Gout (monosodium urate) Calcium pyrophosphate dehydrate deposition disease (CPPD or pseudogout)
Auto-Immune	Sarcoidosis, reactive arthritis
Infectious	Non-gonococcal septic arthritis: bacterial, mycobacterial, or fungal Gonococcal arthritis Lyme disease
Inflammatory Polyarthritis (≥4 Joints)	
Auto-Immune	Rheumatoid arthritis Systemic lupus erythematosus Seronegative spondyloarthritis (including psoriatic arthritis, ankylosing spondylitis, Behcet's Disease, enteropathic arthritis with inflammatory bowel disease, reactive arthritis), Whipple's disease, SAPHO (synovitis, active pustulosis, hyperostosis and osteitis), celiac disease Serum sickness, post-infectious Others: Still's Disease (adult and juvenile), systemic sclerosis, mixed connective tissue disease, myositis, relapsing seronegative symmetrical synovitis with pitting edema (RS3PE)
Infectious	
Bacterial	Bacterial endocarditis Lyme disease Gonococcal arthritis
Viral	Rubella Hepatitis B and C HIV Parvovirus

joints involved in the hands include the metacarpophalangeal (MCP) and proximal inter phalangeal (PIP) in a bilateral symmetrical pattern. In addition, radiocarpal (RC), carpal, and carpometacarpal (CMC) joints as well as ulnar styloid (US) are commonly involved. Marginal erosions followed by disfigurements may develop in the hands over time, adding to the disability. These deformities include ulnar deviation, swan neck (Fig. 1), boutonniere deformity, rheumatoid nodules, and arthritis mutilans. Tendon ruptures within the hand and wrist may also occur with extensor tendon ruptures being more common than flexor. Tendon ruptures are caused by either attrition of the tendon over bony spurs, ischemia due to hypertrophic synovium, or invasive tenosynovitis. Other secondary manifestations of RA include entrapment neuropathy secondary to synovitis (carpal tunnel syndrome, cubital tunnel syndrome), mononeuritis multiplex (wrist drop), and rheumatoid vasculitis.

Diagnosis is based on history and physical examination, along with laboratory tests and imaging that may provide supporting evidence for RA or exclude other etiologies. American College of Rheumatology (ACR)/European League against Rheumatism (EULAR) classification criteria for rheumatoid arthritis (2010) may be a helpful guide in the diagnosis of RA.<sup>4</sup> Rheumatoid factor (RF) is positive in 70–85% of RA patients but may also be seen in 5–10% of healthy people and in patients with SLE, mixed cryoglobulinemia (usually caused by hepatitis C virus [HCV]), and infections. Antibodies to citrullinated peptides (anti-CCP) are positive in 50–60% of RA patients and are considered more specific (>95%). Seronegative RA patients have neither RF or anti-CCP, and the diagnosis may be made based on symptoms, examination, and exclusion of other potential etiologies. Crystalline disease, SLE, viral arthritis, palindromic rheumatism, polymyalgia rheumatica, psoriatic arthritis, and osteoarthritis may mimic RA presentation.

The treatment of RA<sup>5</sup> is geared towards controlling joint inflammation and preventing irreversible joint damage. The

therapeutic strategy is based on various factors and includes evaluation of disease activity, response to prior treatments, comorbidities, and patient preference. “Treat to target” is a proactive treatment approach directed at achieving remission or at least low disease activity in those patients with difficult-to-control disease. Treat to target approach involves careful tracking of a patient's disease activity using standardized assessment tools (e.g. disease activity score- DAS, RAPID3) and revision of management strategy to achieve the target of remission or low disease activity, thereby avoiding/limiting irreversible damage. This is attained through early institution of disease-modifying anti-rheumatic drug (DMARD) therapy and escalation or adjustment of treatment plan if necessary in order to achieve quick and sustained control of inflammation. Early involvement of a rheumatologist is recommended as it is associated with better patient outcomes in RA.<sup>6,7</sup> Patients should be evaluated every 3–5 weeks initially to evaluate treatment effectiveness and screen for medication related side effects. However, a coordinated team approach with active involvement of the patient's primary care provider is also required as major morbidity and mortality in RA results from cardiovascular disease, infections, and malignancy.

Non-pharmacologic interventions, such as patient education, self-management programs, nutritional and exercise counselling, cardiovascular risk screening, immunizations, and osteoporosis screening, are important adjunctive treatments. Multiple studies have shown early diagnosis, timely initiation of disease modifying anti-rheumatic drugs (DMARDs), use of treat-to-target approach, and limited use of NSAIDs and/or corticosteroids for flare ups have resulted in significant improvement in morbidity and mortality.<sup>8,9</sup> DMARDs help to achieve optimal disease control by reducing joint damage. These agents include methotrexate (MTX), hydroxychloroquine, sulfasalazine, leflunomide (Lef), and biologics (Table 3). Guidelines recommend that all patients with newly diagnosed RA should be started on DMARDs. Therapy with monotherapy DMARDs vs combination therapy DMARDs vs biologics±DMARDs is dependent on disease activity and other factors. The most common DMARD utilized in RA is low dose MTX because of its faster onset of action, similar or better efficacy, and improved long-term tolerance as compared to other non-biologic DMARD monotherapies.<sup>10</sup> MTX is associated with improved survival when compared to other DMARDs.<sup>11</sup> Its use in pregnancy is contraindicated due to teratogenic potential. Folic acid supplementation is recommended with use of MTX to reduce risk of side effects. Based on moderate to high quality evidence, a weekly dose of MTX (7.5 mg–25 mg) has shown significant clinical improvement in the majority of RA patients when compared to placebo. When MTX is not tolerated or contraindicated, other DMARDs may be used in its place.

Clinical trials conducted from 1985 to 2016 involving more than 37,000 participants aimed to evaluate the effectiveness of monotherapy with MTX vs MTX with non-biologic DMARD vs MTX with biologic DMARD. The results demonstrated that MTX with sulfasalazine and hydroxychloroquine (‘triple therapy’) was superior to MTX monotherapy but similar to MTX + biologic therapy in both MTX-naïve and inadequate-response (MTX) populations.<sup>12</sup> In randomized trials of patients with early RA, similar improvements in disease activity are seen with initial monotherapy with MTX as compared to initial monotherapy with TNF inhibitor; however, radiographic progression was slower in TNF inhibitor monotherapy group.<sup>13</sup> Although janus kinase inhibitors tofacitinib<sup>14</sup> and baricitinib<sup>15</sup> have shown superior efficacy in comparison to MTX for early RA treatment, their cost is a limiting factor. Side effects of medications should be reviewed with patients, and it is recommended most patients be screened (Table 3) with baseline blood counts, kidney-liver function tests, and for infections (Hepatitis B



**Table 2**  
Diagnostic work-up and clinical characteristics of various forms of inflammatory arthritis involving hand and wrist.

	Diagnostics	Radiographic findings	Pattern of joint involvement	Other features
RA	<ul style="list-style-type: none"> <li>- RF as screening test (positive in ~80%)</li> <li>- Anti-CCP is specific</li> <li>- Often ↑ ESR and/or CRP</li> </ul>	<ul style="list-style-type: none"> <li>- Symmetric joint space narrowing</li> <li>- Marginal erosions</li> </ul>	<ul style="list-style-type: none"> <li>- Often symmetric polyarthritis with significant morning stiffness that improves with joint use</li> <li>- Proximal distribution of hand (MCP, PIP, IP of thumb) and wrists; feet and large joints may also be affected</li> </ul>	<ul style="list-style-type: none"> <li>- Rheumatoid nodules</li> <li>- Lung and eye involvement may also occur</li> </ul>
SLE	<ul style="list-style-type: none"> <li>- ANA as screening test (positive in ~95%)</li> <li>- Anti-dsDNA and anti-Smith are specific</li> <li>- Complements C3 and C4 may be low</li> <li>- Other antibodies: anti-SSA, anti-SSB, anti-RNP</li> </ul>	<ul style="list-style-type: none"> <li>- X-rays usually appear normal with preserved joint space</li> <li>- Some cases may present with reducible ulnar deviation and MCP subluxation (Jaccoud's arthropathy)</li> </ul>	<ul style="list-style-type: none"> <li>- Often symmetric polyarthritis</li> <li>- Nearly all joints can be affected but hands and knees are most common</li> <li>- Tenosynovitis and tendon derangement (including rupture) are complications</li> </ul>	<ul style="list-style-type: none"> <li>- Other organ systems may be involved:</li> <li>- Lupus nephritis</li> <li>- Serositis</li> <li>- Oro-nasal ulcers</li> <li>- Butterfly rash</li> <li>- Cytopenias</li> </ul>
PsA	<ul style="list-style-type: none"> <li>- No standard serological markers</li> <li>- Negative anti-CCP and RF</li> </ul>	<ul style="list-style-type: none"> <li>- Dactylitis (sausage digit)</li> <li>- Arthritis mutilans with progressive disease</li> <li>- "Pencil-in-cup" deformity</li> <li>- Resorption of distal phalanx tuft (acro-osteolysis)</li> <li>- Marginal bone erosions and bony proliferation appear as fluffy periostitis</li> </ul>	<ul style="list-style-type: none"> <li>- Varies from symmetric polyarthritis to asymmetric oligoarthritis +/- axial involvement</li> <li>- Often bilateral asymmetric</li> <li>- Distal distribution of hand with IP&gt;MCP joints; DIP involvement is characteristic</li> </ul>	<ul style="list-style-type: none"> <li>- Psoriasis rash marked by erythematous, silvery-scaled patches</li> <li>- Nail changes: nail pitting, discoloration, subungual hyperkeratosis</li> <li>- May be associated with inflammatory back pain (sacroiliitis)</li> </ul>
Gout	<ul style="list-style-type: none"> <li>- Needle-shaped negatively birefringent crystals in synovial fluid</li> <li>- Normal or ↑ uric acid (can be falsely low during acute attacks)</li> </ul>	<ul style="list-style-type: none"> <li>- Typically preserved joint space</li> <li>- Tophi will appear as radio-opaque densities usually located in peri-articular regions</li> <li>- Punched-out erosions</li> <li>- Overhanging edges</li> </ul>	<ul style="list-style-type: none"> <li>- Often monoarticular (MTP, knee, ankle)</li> <li>- Most commonly involved joints of hand include the wrist, MCPs, or PIPs usually in an asymmetric pattern</li> </ul>	<ul style="list-style-type: none"> <li>- Tophi may be present</li> <li>- Risk factors include obesity, post menopause, alcohol consumption, hyperlipidemia, diabetes, kidney disease, medications</li> <li>- Coexisting infection needs to be ruled out</li> </ul>
CPPD	<ul style="list-style-type: none"> <li>- Rhomboid-shaped weakly positive birefringent crystals in synovial fluid</li> </ul>	<ul style="list-style-type: none"> <li>- Chondrocalcinosis +/- changes of OA (asymmetric joint space narrowing, subchondral sclerosis, osteophytes)</li> <li>- Calcification of TFCC of wrist and radiocarpal narrowing</li> </ul>	<ul style="list-style-type: none"> <li>- Often monoarticular (knee most common followed by wrist, shoulder, ankle, MTP)</li> <li>- Chronic CPPD may present in pseudoRA pattern with MCPs most commonly affected in hand</li> </ul>	<ul style="list-style-type: none"> <li>- Can co-exist with gout and OA</li> </ul>
Erosive OA	<ul style="list-style-type: none"> <li>- Negative RF, anti-CCP, and ANA</li> </ul>	<ul style="list-style-type: none"> <li>- Joint space narrowing</li> <li>- Subchondral "gull wing" erosions</li> <li>- Marginal osteophytes</li> </ul>	<ul style="list-style-type: none"> <li>- Primarily affects hand with IP&gt;MCP joints, 1<sup>st</sup> CMC joints, STT complex</li> </ul>	<ul style="list-style-type: none"> <li>- Can mimic RA or PsA</li> <li>- No systemic symptoms</li> <li>- Predominantly affects females</li> </ul>

Abbreviations: RF, rheumatoid factor; CCP, anti-cyclic citrullinated peptide; anti-RNP, ribonucleoprotein; ANA, antinuclear antibody; ESR, erythrocyte sedimentation rate; CRP, C-reactive protein; MCP, metacarpal phalangeal; IP, interphalangeal; PIP, proximal interphalangeal; MTP, metatarsal phalangeal; CMC, carpometacarpal; SLE, systemic lupus erythematosus; anti-dsDNA, double stranded DNA; CPPD, calcium pyrophosphate deposition; STT, scapho-trapezio-trapezoid; TFCC, triangular fibrocartilage complex; RA, rheumatoid arthritis; PsA, psoriatic arthritis; OA, osteoarthritis.

and/or C and tuberculosis) prior to starting DMARDs (MTX or Lef) or biologics. In addition, ongoing serial monitoring for medication side effects is recommended for a majority of the medications.<sup>16</sup>

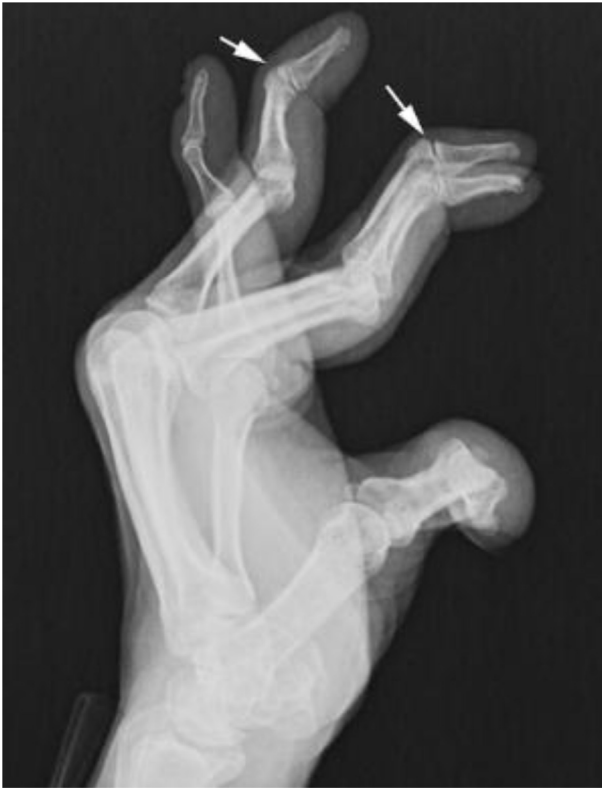### 3. Systemic lupus erythematosus (SLE)

SLE is a multisystem, inflammatory autoimmune disease that predominantly affects young women. Hallmark of the condition is the presence of anti-nuclear antibody (ANA), which is used as a screening test for patients with suspected SLE. SLE is frequently associated with unpredictable disease flares. Disease manifestations are heterogeneous, as it may affect a single organ system or any combination of organs. Arthritis and cutaneous involvement are the most common manifestations. Patients frequently seek medical care because of hand symptoms, which may be seen in 90% of patients with SLE.<sup>17,18</sup>

Musculoskeletal manifestations in SLE may present as an inflammatory arthritis, typically in a bilateral, symmetric distribution in the hands. Non-erosive joint disease is the most common pattern seen in SLE, but an erosive form may also occur.<sup>19,20</sup> In the event of poorly controlled inflammation over time, patients with SLE may develop joint subluxations (Fig. 2) (wrist, MCP joints) and/or reducible hand deformities involving the wrist (ulnar deviation), MCP, and PIP joints (flexion and extension deformities caused from

ligamentous laxity, which may mimic swan neck and Boutonnière's deformities seen in RA). The latter referred to as Jaccoud's arthropathy is a visible deformity that is disabling and negatively impacts patients daily living and quality of life.<sup>21</sup> Tenosynovitis and rarely tendon ruptures have been reported to occur. Patients with erosive Jaccoud's arthritis usually have anti-citrullinated protein antibodies.<sup>20</sup> In a self-reported survey study, 73% of SLE patients reported having hand problems and up to 25% reported having hand deformities. As compared to age and gender matched health controls, 58% of SLE patients had pain and/or difficulty in performing one or several tasks on the simple hand test, compared with 8% in the healthy group. There was significant association of hand and finger function with arthritis impact measurement scales health status.<sup>21</sup>

Diagnosis of SLE is based on history, examination and laboratory evaluation. Various classification criteria have been developed for SLE; however, these are used more for research purposes rather than establishing a diagnosis. Laboratory studies that could support SLE diagnosis include ANA, double stranded DNA antibody, anti-ribonuclear protein antibody, anti-smith antibody, Sjogren antibodies (Ro and La), complement C3 and C4, complete blood count, basic metabolic panel, and urinalysis. When organ systems outside the musculoskeletal system are involved (e.g. renal), a tissue diagnosis of SLE may be reached through a biopsy.



**Fig. 1.** Hand deformities (swan neck) in rheumatoid arthritis.

Medical management includes patient education and avoidance of known triggers (e.g. sun exposure or drugs). Treat to target approaches have recently been defined in SLE and include remission on and off medications and low disease activity state on and off medications.<sup>22,23</sup>

Treatment algorithms for SLE have been studied.<sup>24</sup> Antimalarials, specifically hydroxychloroquine (HCQ) with or without corticosteroids, are the first line treatment for SLE patients with non-erosive, non-deforming inflammatory polyarthritis. HCQ use is associated with reduced SLE flares and organ damage in the long term and improves survival.<sup>25</sup> NSAIDs may be used as an adjunct or as a substitute to corticosteroids for arthritis flares. Methotrexate may be added to this regimen if low disease activity state or remission is not achieved with first line treatment options, as it has been shown to be effective in controlling articular symptoms and allowing reduction in steroid dose.<sup>26</sup> Other therapeutic options that may be tried in the case of either intolerance or inadequate response to first- or second-line agents for arthritis include azathioprine, mycophenolate mofetil, leflunomide,<sup>27</sup> rituximab,<sup>28</sup> and belimumab.<sup>29</sup> Belimumab has been found to improve arthritis in patients with SLE. At 3 months, 61% of the SLE patients with arthritis showed at least 50% improvement in their arthritis.<sup>30</sup> Choice of agent is also based on patient preference and other factors, such as cost and plans for pregnancy. Screening for retinal toxicity with HCQ, contraceptive use with MTX and mycophenolate mofetil (MMF), and serial monitoring for medication side effects are indicated (Table 3).

#### 4. Psoriatic arthritis

Psoriatic arthritis (PsA) is one of the seronegative spondyloarthropathies seen in association with psoriasis. Enthesopathy is the hallmark of these conditions. Nail deformities, such as pitting, may

also be seen. It typically involves joints in an asymmetric and destructive pattern. In the hands, distal interphalangeal (DIP) joints are most often involved in contrast to RA, although MCP's and wrist may also be involved. Psoriatic arthritis of the hand may present with dactylitis in the form of sausage digit, a term referring to diffuse soft tissue swelling of a whole digit. The disease tends to affect peripheral joints in a "ray" distribution, in which there is inflammatory involvement of all 3 contiguous joints of a digit, with sparing of other digits. Fluffy periostitis on plain radiographs (Fig. 3), especially in enthesal areas, may be seen. Other radiographic changes include bony erosions, pencil in cup deformities resulting in telescoping of digits, and arthritis mutilans, akin to that seen in RA. Patients concomitantly may have inflammatory low back pain from spinal or sacroiliac joint involvement. Diagnosis is based on history, examination, and exclusion of other conditions. Imaging and a known history of psoriasis may aid in the diagnosis.

Medical management of PsA includes similar agents to those used in RA management, such as NSAIDs, DMARDs and biologics. Treat to target approach is utilized to attain remission or low disease activity state. Early referral to rheumatologist is associated with better outcomes in psoriatic arthritis.<sup>31</sup> Patient education, role of exercise, and physical therapy are important in management. Patients with mild peripheral arthritis can be managed with NSAIDs alone. Patients with moderate to severe disease or mild disease (not responsive to NSAIDs) may be treated with conventional DMARDs such as MTX or Lef. Sulfasalazine or azathioprine are other options for patients intolerant or unwilling to use MTX/Lef. Patients with severe peripheral disease at presentation or patients with inadequate response to MTX/Lef may be treated with biologics, such as anti-TNF agents. Apremilast, an oral phosphodiesterase inhibitor, may be used in early non-erosive disease in patients. Other biologics like anti-IL-17 blockers (e.g. ixekizumab, secukinumab, brodalumab), anti-IL-23 (guselkumab), CTLA-4 (abatacept), anti-IL-12 and IL-23 (ustekinumab), and JAK kinase inhibitor (tofacitinib) are also alternatives for patients with TNF resistant or intolerant disease.

#### 5. Crystalline arthritis

Several types of crystals can cause acute and chronic inflammation of the hand and wrist. Monosodium urate crystals are involved in the development of gout, whereas calcium pyrophosphate crystals are involved in calcium pyrophosphate deposition disease (CPPD), also known as pseudogout. Other forms of crystals include basic calcium phosphate crystals (BCP-calcium hydroxyapatite), whose deposition results in calcific tendinitis or calcific periarthritis.

#### 6. Gout

Gout affects roughly 3% of US population,<sup>32</sup> and the prevalence varies based on body mass index. There has been an increase in the incidence and prevalence of gout over the years, which may be due to increased longevity, increased incidence of metabolic syndrome, use of medications associated with gout, increased consumption of foods associated with metabolic syndrome, and/or food additives. Risk factors for gout include age, gender, genetic variants, dietary factors including food additives (such as high fructose corn sugar), postmenopausal state, chronic kidney disease, alcohol, enhanced production of uric acid or poor excretion in the setting of renal insufficiency, medications, and metabolic syndrome. Gout tends to occur in previously damaged or osteoarthritic joints.

Acute gout flare may present with acute mono- or oligoarthritis. Joints of the hand most commonly involved include the wrist, MCPs, or PIPs, usually in an asymmetric pattern. Intense, sudden

**Table 3**  
DMARDs (Conventional synthetic and biologic) used for management of rheumatoid arthritis.

DMARDs	MECHANISM OF ACTION	TOXICITY	MONITORING
Methotrexate (csDMARD)	Anti-inflammatory (mediated through adenosine). It also inhibits folic acid metabolism.	- Hepatotoxicity - Myelosuppression - Infection - Interstitial pneumonitis - Pregnancy category X	Baseline chest x-ray; CBC, chemistry, and LFTs every 4 weeks for the first 3 months, then every 12 weeks thereafter
Hydroxychloroquine (csDMARD)	Interferes with antigen processing in macrophages and other antigen-presenting cells	- Irreversible retinal damage - Cardiotoxicity - Blood dyscrasia	Fundus and visual field every 12 months
Sulfasalazine (csDMARD)	Anti-inflammatory salicylate and sulfa moieties	- Granulocytopenia - Hemolytic anemia (with G6PD deficiency)	CBC, chemistry, and LFTs every 4 weeks for the first 3 months, then every 12 weeks thereafter
Leflunomide (csDMARD)	Inhibits pyrimidine synthesis	- Hepatotoxicity - Myelosuppression - Infection - Pregnancy category X	CBC, chemistry, and LFTs every 4 weeks for the first 3 months, then every 12 weeks thereafter
Infliximab (bDMARD)	Chimeric anti-TNF- $\alpha$ antibody	- $\uparrow$ Risk bacterial and fungal infections - Reactivation of latent tuberculosis - $\uparrow$ Lymphoma risk - Drug-induced lupus - Neurologic deficits	and LFTs periodically
Etanercept (bDMARD)	Anti-TNF- $\alpha$ -receptor protein	- As above	Monitor for injection site reactions
Adalimumab (bDMARD)	Human anti-TNF- $\alpha$ antibody	- As above	Monitor for injection site reactions
Golimumab (bDMARD)	Human antibody to TNF $\alpha$	- As above	Monitor for injection site reactions
Certolizumab (bDMARD)	Fab portion of monoclonal antibody to TNF $\alpha$	- As above	Monitor for injection site reactions
Abatacept (bDMARD)	Downregulation of T cells using recombinant CTLA4	- $\uparrow$ Risk bacterial, viral infections	Monitor for infusion reactions
Rituximab (bDMARD)	Monoclonal antibody against CD20. Targets B cells	- $\uparrow$ Risk bacterial and viral infections - Infusion reaction - Cytopenia - Hepatitis reactivation	and CBC at regular intervals
Tocilizumab (bDMARD)	Humanized monoclonal antibody to IL-6 receptor	- Infusion reaction - LFT elevation - Dyslipidemia - Cytopenias	CBC and LFTs at regular intervals
Tofacitinib (new agent-synthetic DMARD)	Inhibits Janus kinases (JAK)	- Risk of infection - LFT elevation - Dyslipidemia - Neutropenia	CBC, LFTs, and lipids at regular intervals

Abbreviations: LFTs, liver function tests; CBC, complete blood count; csDMARD, conventional synthetic disease-modifying antirheumatic drug; bDMARD, biological disease-modifying antirheumatic drug; TNF, tumor necrosis factor.

Adapted from Shilpa et al. Management of rheumatoid arthritis: Review of current guidelines. Journal of Arthroscopy and Joint Surgery. 2016; 3(2):45–50.

inflammation produces significant swelling, erythema, and immense pain in the affected joint(s). Joint aspiration is obtained to document negatively birefringent intracellular needle shaped monosodium urate (MSU) crystals. Although rare, concomitant septic arthritis and gout have been reported in a very small minority of cases.

Flares of gout may be precipitated by alcohol, changes in diet or medications, and acute illnesses. Tophaceous gout may develop over time with typical erosive changes marked by overhanging edges (Fig. 4), causing hand deformities. Gout, when polyarticular, may be confused with RA.

Medical management of gout is aimed at (a) control of acute inflammation, (b) prevention of flares, (c) urate lowering therapy, and (d) management of comorbidities. Patient education is pivotal in life style modifications, prevention of flares, compliance with medications, and treatment of comorbidities. For acute gout flares, NSAIDs, glucocorticoids (intra-articular or systemic), or colchicine are utilized based on patient preference, number of joints involved, and co-morbidities. There is no significant difference in efficacy between NSAIDs and oral prednisone in acute flares.<sup>33</sup> NSAIDs may

be especially used within 48 h of symptoms onset in younger patients, in those without risk for gastrointestinal bleeding, in the absence of chronic kidney disease, or in those at low risk for cardiovascular disease. Intra-articular corticosteroids may be utilized for monoarticular gout after reasonable exclusion of septic arthritis. In fact, patients may be more receptive to intra-articular injections given concerns for potential side effects of systemic therapy (e.g. poor glycemic control, water retention, gastritis, or weight gain). In the case of polyarticular acute gout flare, oral corticosteroids (prednisone 30 mg daily) may be indicated and tapered off within 7–10 days. Colchicine when selected must be initiated within 24 h of gout flare onset. Low dose colchicine was found to be effective and shown to have a better safety profile compared to high dose colchicine in treatment of acute gout flare<sup>34</sup> and is thus preferred. Dose modifications are required with renal and hepatic impairment. In resistant acute flares, IL-1 inhibitors (anakinra and canakinumab) may be tried.

Reduction of acute gout flares during institution of urate lowering medications is accomplished by prophylaxis with low dose colchicine, NSAIDs, or low dose oral corticosteroids. Recurrent

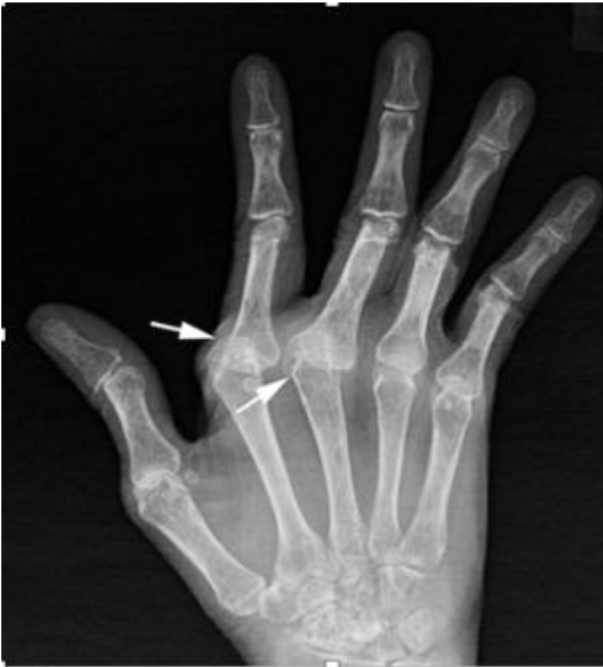

Fig. 2. Subluxations (MCP joints) in SLE.

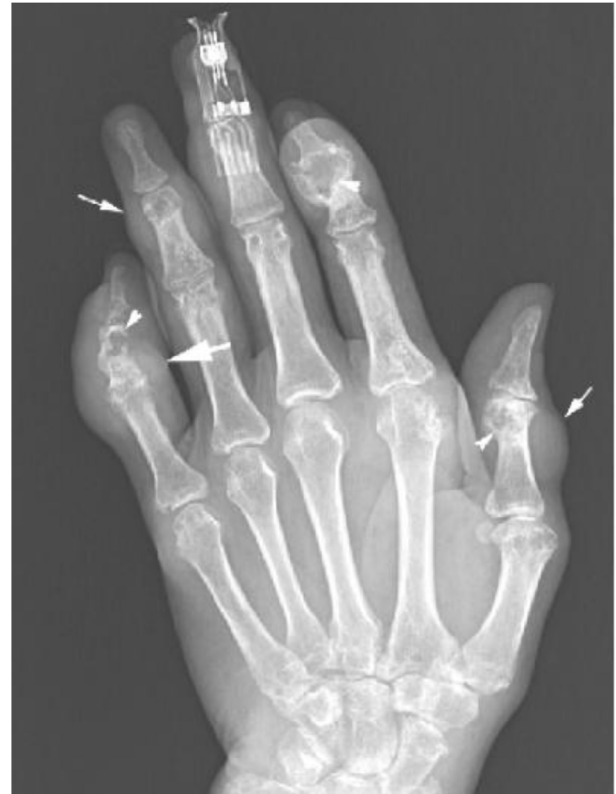

Fig. 4. Tophaceous gout.

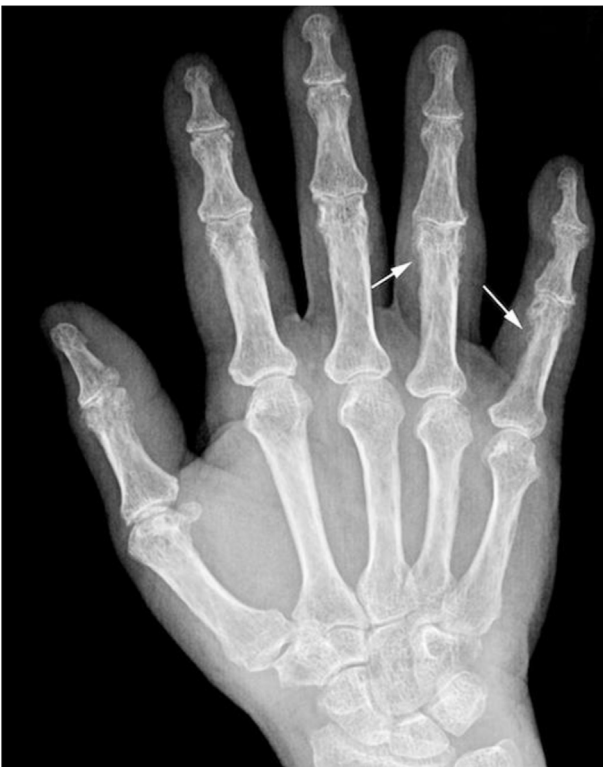

Fig. 3. Fluffy periostitis in psoriatic arthropathy.

acute gout, erosive and/or tophaceous arthritis, gout with renal insufficiency, and recurrent nephrolithiasis are some of the indications for institution of urate lowering therapy (ULT). The target serum urate goal for ULT is less than 6 mg/dl. Xanthine oxidase inhibitors (allopurinol or febuxostat) are the first line urate lowering drugs, followed by the addition of the uricosuric

(probenecid). Careful monitoring for development of rashes, hypersensitivity, and bone marrow suppression needs to be discussed with the patient when employing xanthine oxidase inhibitors. In poorly controlled gout patients, large depositions of extracellular MSU crystal may form visible nodules, referred to as tophi. Tophaceous gout can be managed with standard urate lowering drugs (allopurinol or febuxostat), but pegloticase may be the most effective drug in this situation. Pegloticase, a recombinant mammalian urate oxidase, is not commonly used though due to greater risk of gout flare and infusion reactions.

## 7. Pseudogout

CPPD crystals may also cause an inflammatory arthritis of the hand and wrist. Acute arthritis in this setting is referred to as pseudogout, as the clinical presentation may be similar to gout. Inflammatory and chronic degenerative joint disease may also occur with CPPD and may resemble RA in presentation. CPPD deposition in articular cartilage is called chondrocalcinosis and is most often asymptomatic in the elderly. The prevalence of chondrocalcinosis increases with age. It may affect 4–5% of adult UK population.<sup>35</sup>

Patients may present with acute to subacute inflammation of the joints that may be self-limited and typically resolves over 2–3 weeks. In the hand, the wrist is the most common joint involved. When CPPD occurs in the wrist, plain radiographs may demonstrate calcifications within the triangular fibrocartilage complex (TFCC), radiocarpal narrowing, and scapholunate collapse in advanced cases. Patients undergoing certain stressors (trauma, surgery, or severe medical illness) or metabolic derangements are at higher risk for pseudogout flares. Pseudogout is on rare occasions associated with hemochromatosis, hypomagnesemia or hypo/

hyperphosphatemia, hypercalcemia, and hyperparathyroidism. In the right clinical setting, some of these conditions should be screened for with appropriate tests.

Diagnosis of pseudogout is made by imaging and documentation of weakly birefringent rhomboid or rod shaped CPPD crystals in synovial fluid. Acute flare is managed with NSAIDs or low to moderate dose corticosteroids (intra-articular or systemic) based on number of joints involved and co-morbidities. Corticosteroids may be tapered off within 2–3 weeks. Alternatively, low dose colchicine may be utilized if initiated within 24 h of symptoms onset. For prevention of recurrent flares, low dose colchicine may also be used. Patient education and appropriate monitoring for side effects of NSAIDs, corticosteroids, and colchicine are recommended. IL-1 inhibitors (anakinra and canakinumab) may also offer relief of acute pseudogout for those with resistant or recurrent pseudogout flares. In some patients with chronic pseudogout hand arthropathy, the clinical picture may mimic RA in a so called pseudorheumatoid presentation. These may be treated with NSAIDs, colchicine, hydroxychloroquine, or low dose corticosteroids.

## 8. Erosive osteoarthritis

Erosive osteoarthritis is an uncommon, aggressive variant inflammatory form of osteoarthritis that presents with subacute onset of bilateral, symmetric involvement of the interphalangeal joints of the hands. It may be mistaken for seronegative RA. Heberden and Bouchard nodes may be confused with rheumatoid nodules. Unlike RA, the DIP joints are affected in erosive hand OA. The classic radiographic changes of erosive OA are “gull wing” deformities, which help differentiate it from the marginal erosions of RA. The available treatments include NSAIDs and other analgesics.

## 9. Other autoimmune conditions

Systemic juvenile inflammatory arthritis frequently involves the wrists. Sarcoidosis may be associated with oligoarticular symmetrical joint disease, and hand involvement may mimic RA.<sup>36</sup> Chronic arthritis is rare in sarcoidosis, but dactylitis and Jaccoud's arthritis have been reported. In patients with mixed connective tissue disease, puffy hands are characteristically seen. Arthritis may be similar to RA (erosive) or SLE, and frequently rheumatoid factor and anti-CCP are present. Wrists, MCP, and PIP joints are the most frequently involved joints in patients with inflammatory muscle disease related arthritis.<sup>37</sup> Arthralgias and arthritis, especially in wrists, may be noted in serum sickness. Medical management of above conditions centers around control of acute inflammation and the underlying autoimmune condition.

## 10. Conclusions

Noninfectious conditions, in particular autoimmune diseases and crystalline arthritis, are commonly associated with inflammatory arthritis of the hands and pose diagnostic dilemmas. Appropriate diagnosis, patient education, timely institution of medical management of the underlying condition, and monitoring for potential medication side effects seems to improve patient outcomes.

## Conflicts of interest

The authors declare that there is no conflict of interest.

## Declarations of interest

None.

## Funding

This research did not receive any specific grant from funding agencies in the public, commercial, or not-for-profit sectors.

## Appendix A. Supplementary data

Supplementary data to this article can be found online at <https://doi.org/10.1016/j.jajs.2018.11.007>.

## References

- Choo AD, Middleton G, Wilson RL. Non-rheumatoid inflammatory arthroses of the hand and wrist. *quiz 2488 J Hand Surg Am.* 2015 Dec;40(12):2477–2487. <https://doi.org/10.1016/j.jhsa.2015.05.029>. Review. Erratum in: *J Hand Surg Am.* 2016 Apr;41(4):576. PMID:26537452.
- Hunter TM, Boytsov NN, Zhang X, Schroeder K, Michaud K, Araujo AB. Prevalence of rheumatoid arthritis in the United States adult population in health-care claims databases, 2004–2014. *Rheumatol Int.* 2017 Sep;37(9):1551–1557. <https://doi.org/10.1007/s00296-017-3726-1>. Epub 2017 Apr 28.
- Horsten NC, Ursum J, Roorda LD, van Schaardenburg D, Dekker J, Hoeksma AF. Prevalence of hand symptoms, impairments and activity limitations in rheumatoid arthritis in relation to disease duration. *J Rehabil Med.* 2010 Nov;42(10):916–921. <https://doi.org/10.2340/16501977-0619>.
- Aletaha D, Neogi T, Silman AJ, et al. Rheumatoid arthritis classification criteria: an american college of rheumatology/European League against rheumatism collaborative initiative. *Arthritis Rheum.* 2010;62(9):2569–2581. <https://doi.org/10.1002/art.27584>, 2010 Sep.
- Arora Shilpa, Rafiq Arash, Jolly Meenakshi. Review article Management of rheumatoid arthritis: review of current guidelines. *Journal of Arthroscopy and Joint Surgery.* 2016;3(2):45–50.
- Zink A, Fischer-Betz R, Thiele K, et al. German Collaborative Arthritis Centers Health care and burden of illness in systemic lupus erythematosus compared to rheumatoid arthritis: results from the National Database of the German Collaborative Arthritis Centres. *Lupus.* 2004;13(7):529–536.
- Bonafede M, Johnson B, Shah N, et al. Disease-modifying antirheumatic drug initiation among patients with newly diagnosed rheumatoid arthritis. *Am J Manag Care.* 2018;24(8):SP279–SP285.
- Knevel R, Schoels M, Huizinga TW, et al. Current evidence for a strategic approach to the management of rheumatoid arthritis with disease-modifying antirheumatic drugs: a systematic literature review informing the EULAR recommendations for the management of rheumatoid arthritis. *Ann Rheum Dis.* 2010;69(6):987.
- Schoels M, Knevel R, Aletaha D, et al. Evidence for treating rheumatoid arthritis to target: results of a systematic literature search. *Ann Rheum Dis.* 2010;69(4):638.
- Maetzel A, Wong A, Strand V, Tugwell P, Wells G, Bombardier C. Meta-analysis of treatment termination rates among rheumatoid arthritis patients receiving disease-modifying anti-rheumatic drugs. *Rheumatology.* 2000;39(9):975.
- Choi HK, Hernán MA, Seeger JD, Robins JM, Wolfe F. Methotrexate and mortality in patients with rheumatoid arthritis: a prospective study. *Lancet.* 2002;359(9313):1173.
- O'Dell JR, Curtis JR, Mikuls TR, et al. TEAR Trial Investigators. Validation of the methotrexate-first strategy in patients with early, poor-prognosis rheumatoid arthritis: results from a two-year randomized, double-blind trial. *Arthritis Rheum.* 2013;65(8):1985.
- Batho JM, Martin RW, Fleischmann RM, et al. A comparison of etanercept and methotrexate in patients with early rheumatoid arthritis. *N Engl J Med.* 2000;343(22):1586.
- Lee EB, Fleischmann R, Hall S, et al. ORAL Start Investigators. Tofacitinib versus methotrexate in rheumatoid arthritis. *N Engl J Med.* 2014 Jun;370(25):2377–2386.
- Fleischmann R, Schiff M, van der Heijde D, et al. Baricitinib, methotrexate, or combination in patients with rheumatoid arthritis and No or limited prior disease-modifying antirheumatic drug treatment. *Arthritis Rheum.* 2017;69(3):506.
- Singh JA1, Furst DE, Bharat A, et al. 2012 update of the 2008 American College of Rheumatology recommendations for the use of disease-modifying antirheumatic drugs and biologic agents in the treatment of rheumatoid arthritis. *Arthritis Care Res.* 2012 May;64(5):625–639. <https://doi.org/10.1002/acr.21641>.
- Dray GJ. The hand in systemic lupus erythematosus. *Hand Clin.* 1989;5:145–155.
- Bleifeld CJ, Inglis AE. The hand in systemic lupus erythematosus. *J Bone Joint Surg.* 1974;56A:1207–1215.
- Tani C, D'Aniello D, Possemato N, et al. MRI pattern of arthritis in systemic lupus erythematosus: a comparative study with rheumatoid arthritis and healthy subjects. *Skeletal Radiol.* 2015 Feb;44(2):261–266. <https://doi.org/10.1007/s00256-014-2033-0>. Epub 2014 Oct 24.
- Ceccarelli F, Massaro L, Perricone C, et al. Jaccoud's arthropathy in systemic lupus erythematosus: clinical, laboratory and ultrasonographic features. *Clin*

- Exp Rheumatol.* 2017 Jul-Aug;35(4):674–677. Epub 2017 Mar 23.
21. Malcus Johnsson P, Sandqvist G, Bengtsson AA, Nived O. Hand function and performance of daily activities in systemic lupus erythematosus. *Arthritis Care Res.* 2008;59:1432–1438.
  22. Petri M, Magder LS. Comparison of remission and lupus low disease activity state in damage prevention in a United States systemic lupus erythematosus cohort. *Arthritis Rheum.* 2018 May 27. <https://doi.org/10.1002/art.40571> [Epub ahead of print]. PMID:29806142.
  23. Tselios K, Gladman DD, Touma Z, Su J, Anderson N, Urowitz MB. Clinical remission and low disease activity have comparable outcomes over 10 years in systemic lupus erythematosus. *Arthritis Care Res.* 2018 Jul 28. <https://doi.org/10.1002/acr.23720> [Epub ahead of print].
  24. Muangchan C, van Vollenhoven RF, Bernatsky SR, et al. Treatment algorithms in systemic lupus erythematosus. *Arthritis Care Res.* 2015 Sep;67(9):1237–1245. <https://doi.org/10.1002/acr.22589>.
  25. Ponticelli C, Moroni G. Hydroxychloroquine in systemic lupus erythematosus (SLE). *Expert Opin Drug Saf.* 2017 Mar;16(3):411–419.
  26. Carneiro JR, Sato EI. Double blind, randomized, placebo controlled trial of methotrexate in systemic lupus erythematosus. *J Rheumatol.* 1999 Jun;26(6):1275–1279.
  27. Tam LS, Li EK, Wong CK, et al. Double-blind, randomized, placebo controlled pilot study of leflunomide in systemic lupus erythematosus. *Lupus.* 2004;13:601–604.
  28. Terrier B, Amoura Z, Ravaud P, et al. Safety and efficacy of rituximab in systemic lupus erythematosus: results from 136 patients from the French autoimmunity and rituximab registry. *Arthritis Rheum.* 2010;62:2458–2466.
  29. Artifoni M, Puéchal X. How to treat refractory arthritis in lupus? *Joint Bone Spine.* 2012 Jul;79(4):347–350. <https://doi.org/10.1016/j.jbspin.2011.12.010>. Epub 2012 Feb 14.
  30. Hui-Yuen JS, Reddy A, Taylor J, et al. Safety and efficacy of belimumab to treat systemic lupus erythematosus in academic clinical practices. *J Rheumatol.* 2015 Dec;42(12):2288–2295. <https://doi.org/10.3899/jrheum.150470>. Epub 2015 Nov 1.
  31. Haroon M, Gallagher P, FitzGerald O. Diagnostic delay of more than 6 months contributes to poor radiographic and functional outcome in psoriatic arthritis. *Ann Rheum Dis.* 2015;74(6):1045. Epub 2014 Feb 13.
  32. Juraschek SP, Miller 3rd ER, Gelber AC. Body mass index, obesity, and prevalent gout in the United States in 1988–1994 and 2007–2010. *Arthritis Care Res.* 2013 Jan;65(1):127–132.
  33. Janssens HJ, Janssen M, Van de Lisdonk EH, et al. Use of oral prednisolone or naproxen for the treatment of gout arthritis: a double-blind, randomized equivalence trial. *Lancet.* 2008;371:1854–1860.
  34. Terkeltaub RA, Furst DE, Bennett K, Kook KA, Crockett RS, Davis MW. High versus low dosing of oral colchicine for early acute gout flare: twenty-four-hour outcome of the first multicenter, randomized, double-blind, placebo-controlled, parallel-group, dose-comparison colchicine study. *Arthritis Rheum.* 2010;62(4):1060.
  35. Neame RL, Carr AJ, Muir K, Doherty M. UK community prevalence of knee chondrocalcinosis: evidence that correlation with osteoarthritis is through a shared association with osteophyte. *Ann Rheum Dis.* 2003;62(6):513.
  36. Kaufman LD. Lofgren's syndrome (acute sarcoidosis) sine erythema nodosum mimicking acute rheumatoid arthritis. *N Y State J Med.* 1990;90(9):463.
  37. Klein M, Mann H, Pleštilová L, et al. Arthritis in idiopathic inflammatory myopathy: clinical features and autoantibody associations. *J Rheumatol.* 2014 Jun;41(6):1133–1139. <https://doi.org/10.3899/jrheum.131223>. Epub 2014 May 1.



## Research paper

# A comparative study on functional outcome of ACL reconstruction: Quadriceps versus hamstring tendon autograft



Sandeep Yadav Tirupathi <sup>a,\*</sup>, Divyanshu Goyal <sup>a</sup>, Vidyasagar Jvs <sup>b</sup>

<sup>a</sup> Arthroscopy and Sportsmedicine, India

<sup>b</sup> Department of Orthopaedics and Arthroscopy and Sports Medicine, Gleanables Global Hospitals, Sagar Road, Saroor Nagar, L.B. Nagar, Hyderabad, 500035, Telangana State, India

## ARTICLE INFO

## Article history:

Received 6 February 2018

Accepted 17 September 2018

Available online 18 September 2018

## Keywords:

ACL reconstruction

Quadriceps graft

Hamstring graft

## ABSTRACT

**Introduction:** There are various soft tissue graft options available for anterior cruciate ligament reconstruction. This study aims to compare the functional outcome following anterior cruciate ligament reconstruction between quadriceps tendon and hamstring tendon autografts.

**Hypothesis:** There was no significant difference in functional outcome of anterior cruciate ligament reconstruction between quadriceps and hamstring tendon autografts at two years follow up.

**Methods:** Out of total 96 patients in our study, 48 patients included in quadriceps tendon autograft group and remaining 48 patients included in hamstring tendon group. Both group of patients were treated by same surgeon, with similar fixation methods and criteria for functional outcomes includes IKDC scores and clinical assessment of stability at 2 years follow up.

**Results:** Preoperative IKDC scores in quadriceps and hamstring tendon group are 56 and 58 respectively. Out of 48 patients in quadriceps tendon group 4 patients lost for follow up and out of 48 patients in hamstring tendon group 6 patients lost for follow up at 12 weeks. At 2 year follow up IKDC scores in quadriceps tendon group is 114 in 40 patients and 100 in 4 patients (mean IKDC score 113), in hamstring tendon group is 119 in 38 patients and 113 in 4 (mean IKDC score 118) with p value > 0.05 (p = 0.97) showing no statistical significance.

**Conclusion:** Our study shows no statistical significant difference between quadriceps and hamstring tendon autograft groups at 2 years follow up following anterior cruciate ligament reconstruction. This shows our hypothesis was correct.

© 2018 Published by Elsevier, a division of RELX India, Pvt. Ltd on behalf of International Society for Knowledge for Surgeons on Arthroscopy and Arthroplasty.

## 1. Introduction

Ligament injuries around knee are most common sports injuries.<sup>1,2</sup>

ACL is one of the most common injured ligament in the knee joint which shows good results after ligament reconstruction.

Most common mechanism of injury causing ACL tear is non-contact combined valgus- and internal-rotation trauma.<sup>3</sup>

Various types of grafts are available for ACL reconstruction which includes BTB graft, hamstring grafts, quadriceps grafts and allografts.

Several studies in the literature compared BTB autograft with

hamstring autograft. Anterior knee pain and kneeling pain shown to be less in hamstring autograft patients.<sup>4,5</sup>

Other studies compared BTB autograft with quadriceps autograft which showed no significant difference in knee stability and functional outcomes except anterior knee pain more in BTB patients.<sup>6,7</sup>

Quadriceps tendon autograft was first introduced by Blauth<sup>8</sup> and further studied by Stabuli et al.<sup>9,10</sup>

There are few studies in the literature comparing the quadriceps tendon autograft with hamstring autograft.

Our objective of the study was to compare knee stability and functional outcome after ACL reconstruction with quadriceps tendon autograft and hamstring autograft.

\* Corresponding author.

E-mail address: [sandykmc2005@gmail.com](mailto:sandykmc2005@gmail.com) (S.Y. Tirupathi).

## 2. Material and methods

Between 2010 and 2012 out of 234 ACLR done 96 patients who accepted are included in our study.

Age of the patients in our study between 20 and 50 years, both male and female are included.

Unilateral isolated ACL injured are included.

No previous surgeries in the involved knee.

No significant deformities of knee.

Single bundle method of ACL reconstruction using either hamstring tendon autograft or quadriceps tendon autograft is included.

No associated major comorbidities limiting postoperative rehabilitation protocol.

Randomization was done into two groups. Group A: autologous quadriceps tendon graft and Group B: autologous hamstring tendon grafts. Randomizer was blinded to which graft will be used. After history, clinical examination and MRI confirmation, first patient was allotted to group a and second patient to group b in simple alternate method of randomization.

All surgical procedures done by single surgeon (senior author). Except for type of graft all other factors remained same in surgery.

## 3. Surgical procedure

Patient positioned supine on the operation table under anaesthesia. Examination under anaesthesia done to assess and confirm type of ligament injuries and to confirm the diagnosis.

Tourniquet applied and pressure kept at 350 Hg. Thorough scrubbing done with savlon and betadine scrub and painting done with betadine solution followed by sterile draping.

In group A: Ipsilateral quadriceps tendon graft obtained by a 10 cm long mid line supra patellar incision starting at superior pole of patella shown in Fig. 1, skin and deep fascia cut in same line to expose q-tendon, width and length measured with a scale, width being 9 mm and length being 10 cm, first two parallel incisions were made in q-tendon width being 9 mm and interval between rectus and vastus intermedius tendons is separated by a blunt instrument one and half inch proximal to superior pole of patella and continued distally and proximally until 10 cm length is made sure then rectus tendon was divided sharply with knife at superior pole of patella and with ethibond no.5 sutures through it held strong and storz Q-grafter introduced and by pulling on the ethibond sutures and pushing the grafter till 10 cm length by guillotine action the graft is cut and withdrawn through the wound as shown in the Fig. 2.

On the graft master table q-tendon graft was cleaned of any residual muscle fibers and both ends were tubularized to get a rounded appearance and graft diameter and length were measured.

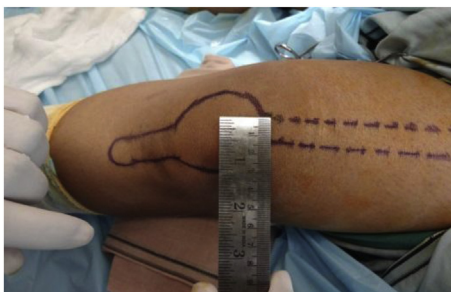

Fig. 1. Skin marking for quadriceps graft harvest.

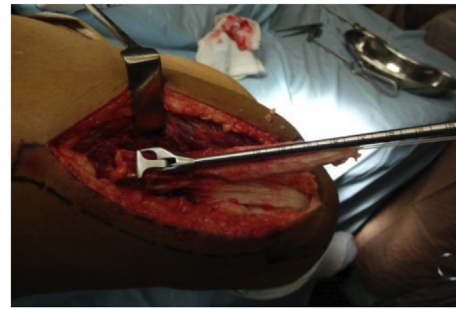


Fig. 2. Harvesting the quadriceps graft.

Though 10 cm was harvested we found in all cases the final length to be only 8.5 cm–9.0 cm and final diameter to be 8.5 mm–9.0 mm.

Routine arthroscopy was performed and any meniscal tears were excised and using storz fixed angle tibial zig a guide wire was passed from outside into intra articular point on medial slope of medial tibial spine through the remnant stump of native ACL equidistant between anterior and posterior horns of lateral meniscus.

Incremental reaming was done with cannulated reamers till the tunnel diameter reached the graft diameter. Through an accessory medial portal a separate guide wire was passed into the joint flexed 90 deg, into the femoral land mark below resident's ridge avoiding pcl and medial femoral condylar surface and incremental reaming with cannulated reamers was done till femoral tunnel reached graft diameter.

Graft is passed through the tibial tunnel, across the joint into femoral tunnel until 20–25 mm graft is in femoral tunnel and distal graft tip is seen at outer mouth of tibial tunnel.

While holding lead sutures and trailing sutures tightly stability and range of motion of joint was checked and femoral end was fixed first with measured size megafix c.p. (beta tri calcium phosphate and PLLA fenestrated smooth threaded interference screw - storz) using torque screw driver (storz) and arthroscope is removed from joint, once again stability and rom checked and while distal trailing sutures were tightly held by a trained assistant with limb in 5 deg external rotation tibial side graft tunnel fixation was done using similar IFS (storz) and final check was done to see stability, disappearance of anterior draw and pivotshift. No extra cortical or suspensory fixation was used in any case.

All wounds were closed, sterile dressing was done, sterile cylindrical roller cotton was applied and crepe bandage was done and after deflating the tourniquet a temporary long leg brace was applied. and patient was shifted to surgical post op care unit for observation. Antibiotic prophylaxis was used in all patients.

In group B: Ipsilateral semitendinosus and gracilis grafts were

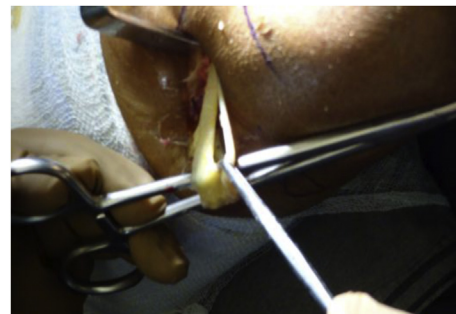

Fig. 3. Harvesting hamstring tendon graft.



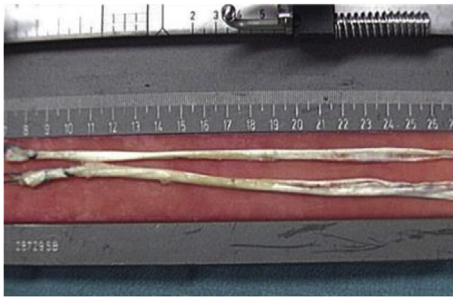

Fig. 4. Hamstring graft preparation.

harvested as shown in the Fig. 3 and prepared as shown in the Fig. 4 and rest of surgical procedure was same.

First post op day patient was made to walk full weight bearing and with brace which was discarded after one week. Suture removal was done on 10th post op day in all cases and accelerated rehabilitation protocol was followed. post op exercises rehabilitation was supervised by the surgeon and qualified sports medicine physiotherapist.

Follow up was at 3 weeks, 6 weeks, 12 weeks, 6 months, one year and two years.

At 3 weeks weight resisted hamstring and isometric q-strengthening was started, activities of daily living were started and patient was allowed to go to work and at 9 weeks proprioceptive exercises were started at 9 months patients were allowed to go to recreational sports activity with care.

At 12 weeks, 6 months, one year and two years all clinical instability tests, single leg stance time, radiographic laxometry were done and functional assesment done with IKDC scoring system.

#### 4. Results

At 12 weeks in quadriceps tendon group out of 48 patients 4 were lost for follow up and in hamstring group out of 48 patients 6 were lost for follow up.

Clinical stability subjective and tested in quadriceps graft group 32 stable, 12 complained of fear of instability but no anterior draw positive and radiographic instability absent, in hamstring graft group 38 stable and 4 complained of instability not confirmed by tests.

IKDC functional assessment scores: Preop IKDC scoring in quadriceps group is 56 and in hamstring group is 58, post op IDKC scoring at 6 months in quadriceps graft group 92 (in 30 patients) 87 (in 14 patients) and in hamstring graft group 96 (in 38 patients) 90 (in 4 patients), at one year in quadriceps graft group score is 114 (40 patients) 100 (4 patients), at two years scores were same. See Table 1.

Statistical analysis: The mean IKDC scores in both the groups

were analysed with chi square test with p value 0.05 considered significant. In this study p value is 0.93 at 6months follow up and 0.97 at 1 year and 2 years follow up which shows no statistical significance (p value > 0.05) between two groups.

Clinical instability tests Lachman test, anterior drawer test, pivot shift test done, single leg stance time, radiographic laxometry were done at each follow up visits. No symptomatic instability or clinical instability seen in all patients in both groups.

In muscle strength assessment quadriceps tendon graft patients exhibited extension weakness with loss of terminal 10 deg extension (active) by six months q-power returned with full extension, did not correlate with IKDC scoring hamstring tendon graft patients immediate post op period -weakness of knee flexor power was present in all patients upto 12 weeks, recovered by 6 months, did not correlate with IKDC scoring.

#### 5. Discussion

In our study data showed no significant difference the two groups in terms of functional outcome scores and knee stability with two years follow up.

Study conducted by sof u et al.<sup>11</sup> reported that a quadrupled hamstring tendon autograft is superior to a central quadriceps tendon-patellar bone graft. They believe quadriceps tendon diameter and strength decreases greatly after harvest and these changes leads to increased biomechanical strength on reconstructed ligament in the early stages of healing causing earlier elongation. This leads to instrumental laxity measurement findings poor in QT than HT group.

Kim et al.<sup>12</sup> reported mean side to side difference in 28 patients for single bundle quadriceps reconstruction was 2.64 mm.

E Cavaignac et al.<sup>13</sup> reported that QT graft in ACL reconstruction leads to equal or better functional outcomes than does the use of an HT graft, without affecting morbidity which differs with Sofu et al.<sup>11</sup> results.

Lee et al.<sup>14</sup> reported similar knee joint stability and functional outcomes in anatomic ACL reconstruction using the QT graft as compared with the double bundle hamstring tendon autograft and additionally better flexor muscle strength recovery was found in patients QT graft. There are certain limitation of this study as it uses double bundle technique in hamstring graft patients.

In our study extensor weakness with loss of terminal 10° extension in quadriceps tendon group and flexor muscle weakness in hamstring tendon group was only for short period which improved in all cases of both the groups with no morbidity after six months. There were no revision surgeries due to infections and graft failures in both the groups at two years follow up.

Using hamstring tendon autograft (either ST alone or both ST and gracilis) shows hamstring strength deficits of between 3% and 27% compared with non-operated limb, indicating that hamstring strength deficits persist despite successful completion of rehabilitation.<sup>15</sup>

Table 1

Comparison of IDKC scores in both groups with corresponding p values.

	Quadriceps group IKDC score	Hamstring group IKDC score	P value
Pre op	56	58	
6 months	92 (30 patients)	96 (38 patients)	0.93
	87 (14 patients)	90 (4 patients)	
	90 (mean score)	95 (mean score)	
1 year	114 (40 patients)	119 (38 pts)	0.97
	100 (4 patients)	113 (4 pts)	
	113 (mean score)	118 (mean score)	
2 years	113 (mean score)	118 (mean score)	0.97

Nakamura N et al.<sup>16</sup> reported that loss of flexor strength following the harvest of the hamstring tendons may be more significant than has been previously estimated.

Lee et al.<sup>17</sup> 2004 reported the quadriceps muscle power is not compromised despite sacrificing part of the tendon. Our results show recovery with a mean of 82% of contralateral side at 1 year, and 89% at 180°/second at 2 years.

The mean cross-sectional area of a 10-mm wide quadriceps tendon graft is 64 mm<sup>2</sup>, which is significantly larger than the 37 mm<sup>2</sup> of the patellar tendon, so it can presumably reproduce the broad anatomic insertion of the native ACL to the tibia.<sup>17</sup>

The ultimate failure load of the quadriceps tendon–bone complex was measured at 2173 ±618N compared with the 1953 ±325 N of the bone–patellar tendon–bone complex.<sup>18,19</sup>

Systemic review by Slone et al. showed that use of QT atograft for ACL reconstruction is safe, reproducible and versatile graft that should be considered in future studies of ACL reconstruction.<sup>20</sup>

There are certain limitations in our study first was the midterm follow up of 2 years, long term studies needed for better analysis. Second other functional outcome scores were not evaluated.

## 6. Conclusion

In our study we found that there was no significant difference in functional outcome and knee stability in patients of ACL reconstruction in between quadriceps and hamstring tendon auto grafts. Weakness in muscle strength in both the procedures was seen only short term and improved in all cases with no morbidity within 6 months. So both the grafts can be suitable choice for ACL reconstruction based on surgeon choice and expertise.

## References

- Akkaya S, Serinken M, Akkaya N, Türkçüer I, Uyanik E. Football injuries on synthetic turf fields. *Joint Diseases and Related Surgery*. 2011;22: 155-9.
- Öztürk S, Kılıç D. What is the economic burden of sports injuries? *Joint Diseases and Related Surgery*;24:108-111.
- Nordenvall R, Bahmanyar S, Adami J, Stenros C, Wredmark T, Felländer-Tsai L. A population-based nationwide study of cruciate ligament injury in Sweden, 2001-2009: incidence, treatment, and sex differences. *Am J Sports Med*. 2012;40:1808–1813.
- Freedman KB, D'Amato MJ, Nedeff DD, Kaz A, Bach Jr BR. Arthroscopic anterior cruciate ligament reconstruction: a metaanalysis comparing patellar tendon and hamstring tendon autografts. *Am J Sports Med*. 2003;31:2–11.
- Kuşkucu M, Pehlivan Ö, Solakoglu C, Kaplan H. Reconstruction of the anterior cruciate ligament rupture using four-strand hamstring tendon autograft. *Eklemler Hastalıkları Cerrahisi*. 2003;14:209–213.
- Lee JK, Lee S, Lee MC. Outcomes of anatomic anterior cruciate ligament reconstruction: bone-quadriceps tendon graft versus double-bundle hamstring tendon graft. *Am J Sports Med*. 2016;44(9):2323–2329.
- Lippe J, Armstrong A, Fulkerson JP. Anatomic guidelines for harvesting a quadriceps free tendon autograft for anterior cruciate ligament reconstruction. *Arthroscopy*. 2012;28(7):980–984.
- Blauth W. 2-strip substitution-plasty of the anterior cruciate ligament with the quadriceps tendon [in German]. *Unfallheilkunde*. 1984;87(2):45–51.
- Stäubli HU, Schatzmann L, Brunner P, Rincon L, Nolte LP. Mechanical tensile properties of the quadriceps tendon and patellar ligament in young adults. *Am J Sports Med*. 1999;27(1):27–34.
- Stäubli HU, Schatzmann L, Brunner P, Rincon L, Nolte LP. Quadriceps tendon and patellar ligament: cryosectional anatomy and structural properties in young adults. *Knee Surg Sports Traumatol Arthrosc*. 1996;4(2):100–110.
- Sofu Hakan, Şahin Vedat, Gürsu Sarper, Yıldırım Timur, İssin Ahmet, Ordueri Mehmet. Use of quadriceps tendon versus hamstring tendon autograft for arthroscopic anterior cruciate ligament reconstruction: a comparative analysis of clinical results. *Joint Diseases and Related Surgery*. 2013;24(3): 139–143.
- Kim SJ, Jo SB, Kumar P, Oh KS. Comparison of single- and double-bundle anterior cruciate ligament reconstruction using quadriceps tendon-bone autografts. *Arthroscopy*. 2009;25:70–77.
- Cavaignac Etienne, Coulin Benoit, Tscholl Philippe, Nik Mohd Fatmy Nik, Duthon Victoria, Menetrey Jacques. Is quadriceps tendon autograft a better choice than hamstring autograft for anterior cruciate ligament reconstruction? A comparative study with a mean follow-up of 3.6 years. *Am J Sports Med*. 2017;45(6):1326–1332.
- Joon Kyu Lee, Lee Sahngoon, Lee Myung Chul. Outcomes of anatomic anterior cruciate ligament reconstruction: bone-quadriceps tendon graft. *Am J Sports Med*. 2016;44(9):2323–2329.
- Ardern CL, Webster KE, Taylor NF, Feller JA. Hamstring strength recovery after hamstring tendon harvest for anterior cruciate ligament reconstruction: a comparison between graft types. *Arthroscopy: The Journal of Arthroscopic & Related Surgery*. 2010;26(4):462–469.
- Nakamura N1, Horibe S, Sasaki S, et al. Evaluation of active knee flexion and hamstring strength after anterior cruciate ligament reconstruction using hamstring tendons. *The Journal of Arthroscopic & Related Surgery*. 2002;18(6): 598–602.
- Lee Sahngoon, Seong Sang Cheol, Jo Hyunchul, Park Yoon Keun, Lee Myung Chul. Outcome of anterior cruciate ligament reconstruction using quadriceps tendon autograft. *Arthrosc J Arthrosc Relat Surg*. 2004;20(8):795–802. October.
- Harris NL, Smith DA, Lamoreaux L, Purnell M. Central quadriceps tendon for anterior cruciate ligament reconstruction. Part I: morphometric and biomechanical evaluation. *Am J Sports Med*. 1997;25:23–28.
- Staubli HU, Schatzmann L, Brunner P, Rincon L, Nolte LP. Quadriceps tendon and patellar ligament: cryosectional anatomy and structural properties in young adults. *Knee Surg Sports Traumatol Arthrosc*. 1996;4:100–110.
- Slone HS, Romine SE, Premkumar A, Xerogeanes JW. Quadriceps tendon autograft for anterior cruciate ligament reconstruction: a comprehensive review of current literature and systematic review of clinical results. *Arthroscopy*. 2015;31(3):541–554.



## Research paper

Functional outcome of patellar resurfacing vs non resurfacing in Total Knee Arthroplasty in elderly: A prospective five year follow-up study<sup>☆</sup>Lokesh Chawla<sup>a, \*</sup>, Shivanand M. Bandekar<sup>b</sup>, Vivek Dixit<sup>a</sup>, Ambareesh P<sup>c</sup>, Arun Krishnamoorthi<sup>b</sup>, Sushanth Mummigatti<sup>b</sup><sup>a</sup> All India Institute of Medical Sciences (AIIMS), New Delhi, India<sup>b</sup> Goa Medical College and Hospital, India<sup>c</sup> Vydehi Institute of Medical Sciences and Research Centre, Bengaluru, India

## ARTICLE INFO

## Article history:

Received 7 April 2018

Accepted 17 September 2018

Available online 18 September 2018

## Keywords:

Osteoarthritis

Resurfacing

Total knee arthroplasty

1

## ABSTRACT

**Introduction:** Osteoarthritis of knee is one of the most common orthopaedic problems of elderly. Total knee arthroplasty is a common surgical procedure. Many of the poor functional outcomes are related to problems of patellofemoral joint and there is considerable debate whether patella should be resurfaced or not at the time of total knee arthroplasty.

**Material & methods:** A total of 100 subjects were evaluated and were further randomized equally into two arms by using standard computer generated random table. Each arm was designated to either RS or Non RS between June 2011 to May 2013 at Department of Orthopaedic Surgery, Goa Medical College and Hospital followed by approval of ethical committee. Exclusion criteria for the study included history of patella fracture, age <50 years, Patellofemoral instability, Prior patellectomy, Prior knee replacement surgery, Prior hip replacement surgery, Patient with osteoarthritis of hip, Prior history of tibial condyle or distal femoral fractures. Chi square test was used for statistic analysis.

**Results:** Knee society score including clinical and functional (KSS) were performed for assessment. There were a total of 80 female and 20 male patients. Out of 80 female knees, 41 were resurfaced and 39 were not. Out of 20 male knees, 9 were resurfaced and 11 were not. Mean clinical knee score ranging from 0 to 100 points in the resurfaced group improved from 28.6 to 84.14 and; from 24.72 to 86.2 in the non resurfaced group. The difference in the clinical knee score amongst resurfaced and non resurfaced group was not statistically significant at 5 years follow up. The mean functional knee score on a range of 0–100 point went up from 39.1 to 90.1 in resurfaced group and; from 45 to 92.4 in the non resurfaced group. The difference in functional knee score amongst resurfaced and non resurfaced groups is not statistically significant even at 5 years follow up post operatively. However NRS group received better increment in scores than RS group. Visual Analogue Scale (VAS) was used for anterior knee pain assessment pre and post operatively in both groups and was not statistically significant as well. None of the patients underwent revision of total knee replacement after the primary procedure.

**Conclusion:** A similar knee evaluation score was observed in both RS and NRS groups after 5 year of follow up. However, it appears that non-resurfacing had shown marginally better scores than resurfacing group.

© 2018 Published by Elsevier, a division of RELX India, Pvt. Ltd on behalf of International Society for Knowledge for Surgeons on Arthroscopy and Arthroplasty.

<sup>☆</sup> Place of Study: Goa Medical College and Hospital, Bambolim, Goa-403202, India.

\* Corresponding author. 5019, 5th Floor, Teaching Block, Department of Orthopaedics, All India Institute of Medical Sciences, New Delhi, 110029, India

E-mail addresses: [lokeshchawla1405@gmail.com](mailto:lokeshchawla1405@gmail.com) (L. Chawla), [shivabandekar@gmail.com](mailto:shivabandekar@gmail.com) (S.M. Bandekar), [vivek\\_spggi@yahoo.com](mailto:vivek_spggi@yahoo.com) (V. Dixit), [ambareesh999@rediffmail.com](mailto:ambareesh999@rediffmail.com) (A. P.), [arunkjuvantaz@gmail.com](mailto:arunkjuvantaz@gmail.com) (A. Krishnamoorthi), [sush.base@gmail.com](mailto:sush.base@gmail.com) (S. Mummigatti).

## 1. Background &amp; introduction

Osteoarthritis of knee is one of the most common orthopaedic problems of elderly. Total knee Arthroplasty (TKA) being a common surgical procedure is proven to have long term clinical success.<sup>1–3</sup>

There is considerable debate whether patella should be resurfaced or not at the time of total knee Arthroplasty because in sizable

number of patients, poor functional outcomes may be due to problems of patellofemoral joint. Routine PRS appears to be an option to reduce the patello-femoral related pain but prospective randomized trials have not provided consistent results in short to medium term.

Patellar complications following Total Knee Arthroplasty (TKA) is a major mode of failure and PRS is often recommended based on higher revision rates.<sup>4</sup> Total knee replacement with or without patella resurfacing is still a contentious issue despite three decades of successful joint replacement surgery. The benefits of TKA are excellent pain relief with improved function and durability.<sup>5</sup>

Problems with the patellofemoral joint still play a major role in failure rates.<sup>6</sup> Early design of total knee replacements did not resurface the patella hence leading to around 50% problems with anterior knee pain<sup>7</sup>

Subsequently, TKA designs were modified and this also led to the development of patella resurfacing; with the first reported patella resurfacing occurring in 1974. A polyethylene dome design for the Insall-Burstein total condylar knee replacement (Zimmer, Warsaw, Indiana) was introduced<sup>8</sup> This led to design modification and patella resurfacing which became a cause for concern. The literature<sup>9</sup> showed early complications rates ranged from 4% to 50%. These complications are over or under restoration of patellar thickness, fracture, aseptic loosening, wear, component failure, patellar clunk syndrome and tendon ruptures.

The Australian Orthopaedic Association (National Joint Replacement Registry) which conducted a study on large number of subjects, concluded that rate of early revision was higher in the NRS group (4%) compared to the PRS group (3.1%) at 5 years follow up.<sup>10</sup> Whether Patellar Resurfacing provides better functional outcomes in patients undergoing Total Knee Arthroplasty (TKA) in Elderly? To verify this finding in Indian set up, this study has been planned.

## 2. Materials & methods

A total of 100 subjects were evaluated prospectively between June 2011 to May 2013 at Department of Orthopaedic Surgery, Goa Medical College and Hospital followed by approval of ethical committee. Subjects were further randomized equally into two arms by using standard computer generated random table. Each arm was designated to either PRS or NRS one day prior to surgery. Exclusion criteria for the study included history of patella fracture, Age <50 years, Patellofemoral instability, Prior patellectomy, Prior knee replacement surgery, Prior hip replacement surgery, Patient with osteoarthritis of hip, Prior history of tibial condyle or distal femoral fractures. Preoperative knee scores were clearly documented. The arthroplasty was performed by senior surgeon following standard approach with medial parapatellar arthrotomy under combined spinal and epidural anaesthesia (CSEA). All patients received size specific femoral and tibial components. All components were cemented. For PRS, patellar preparation was done using a saw (Fig. 1) and 3 peg oval patellar button component was used (Fig. 2). In cases of NRS, patelloplasty was done in which osteophytes were removed by trimming around patella and denervating it. Patellofemoral tracking was assessed in all cases after trial component insertion and after implantation of definitive implants. No selective resurfacing was done. Need for lateral release was assessed after checking patellar tracking. Soft tissue balancing was ensured on table. The degree of damage to patellar articular cartilage was recorded at the time of surgery. Suction drain was applied at the end of surgery for 24 h postoperatively. Patients were made to walk on second postoperative day and put on continuous passive motion along with isometric quadriceps exercises with full weight bearing. Postoperative complications if any were clearly documented. Patients were followed up

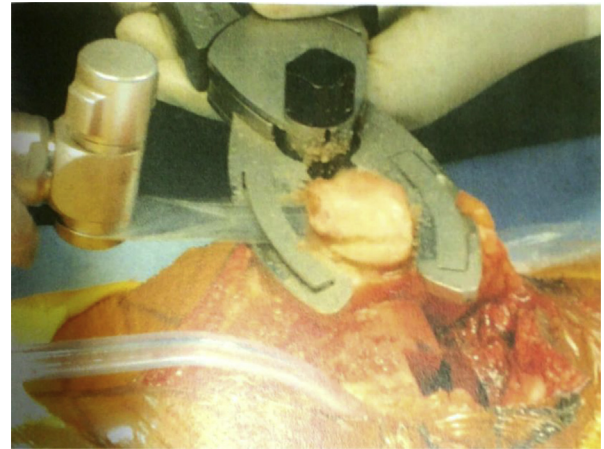


Fig. 1. Patellar preparation during patellar resurfacing in TKA.

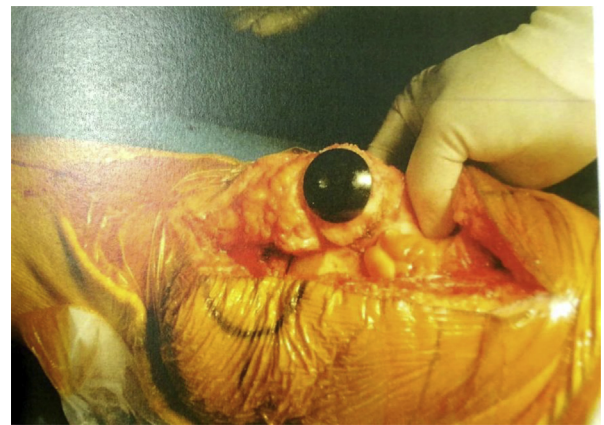


Fig. 2. Insertion of trial patellar component.

postoperatively at 6–8 weeks, 6 months, 1 year, two years and 5 years postoperatively. Pre and post operative evaluation was done using knee society score (KSS) which consists of 100 points scale for clinical score and 100 point scale for function score. The clinical score comprises of pain, total range of flexion, flexion contracture (if present), extension lag, alignment (Varus & Valgus), and stability (Antero-posterior & Medio-lateral) parameters. The function score has points for walking, Stair climbing and walking aid used. Assessment of Anterior Knee Pain was done using Visual Analogue Scale (VAS) pre and post operatively. Standard Anteroposterior and Lateral view X-rays were taken preoperatively in all cases, immediate postoperatively, at 6 months, 1 year, 2 years and 5 years postoperatively. Postoperative X rays were evaluated for component loosening, wear and patellofemoral problems including fracture or loosening of resurfaced patella, subluxation, dislocation and wear of non resurfaced patella.

### 2.1. Post operative protocol

Suction drain was kept for 24 h and patients were given intravenous antibiotics for 48 h and analgesics. Physiotherapy was started within two days of surgery and immediate post operative complications were noted. Immediate post operative X rays were done to analyse for component positioning. Patients were evaluated post op by:

**Table 1**  
Gender Distribution among patients in two groups.

	Sex	PRS	NRS	Total
Female	No.	41	39	80
	%	82%	78%	80%
Male	No.	9	11	20
	%	18%	22%	20%
Total	No.	50	50	100
	%	100.0%	100.0%	100.0%

1. Knee Society Score (KSS).
2. Any complications which developed.
3. Post operative radiographs to see for positioning of components.
4. Visual Analogue Scale (VAS) for Anterior Knee Pain.

Entire clinical and functional outcome was graded as following depending on the total Knee Society Score.

Poor	:	Score below 60
Fair	:	60–69
Good	:	70–79
Excellent	:	80–100

Anterior Knee Pain assessment was done using VAS ranging from 0 to 100 pre and postoperatively.

### 3. Results

Out of 100 subjects, there were a total of 80 female and 20 male patients. Out of 80 female knees, 41 were resurfaced and 39 were not. Out of 20 male knees, 9 were resurfaced and 11 were not (Table 1). Arthroplasty were performed in 57 right sided knees as compared to left sided, which were 43.

### 4. Knee society score

#### i. Clinical Score

Mean clinical knee score ranging from 0 to 100 points in the PRS group improved from 28.6 to 84.14 and; from 24.72 to 86.2 in the NRS group. The difference in the clinical knee score amongst two groups was not statistically significant at 5 years follow up. However, the increment in score was more in the NRS group compared to PRS group.

#### ii. Functional Score

The mean functional knee score on a range of 0–100 point went up from 39.1 to 90.1 in resurfaced group and; from 45 to 92.4 in the non resurfaced group. The difference in functional knee score amongst resurfaced and non resurfaced groups is not statistically significant even at 5 years follow up post operatively. However, the increment in score was more in the NRS group compared to PRS group.

#### iii. Mean Knee Society Score

The mean knee society score (KSS) on scale ranging from 0 to 200 points in the resurfaced group improved from 67.76 to 174.24 and; went up from 69.72 to 178.6 in the non surfaced. p value calculated using independent “t-test” with 96° of degrees of freedom is 0.9047, hence the difference in two groups is not statistically significant at 5 years follow up. It is clearly evident that

increment in score was more in the NRS group compared to PRS group.

#### 4.1. Overall outcome

82% of the patient in resurfaced group had excellent outcome compared to 86% in the non resurfaced group. By using simple interactive statistical analysis we found that all the sub headings in pre and postoperative groups when compared amongst resurfaced and non resurfaced groups have non significant p-value.

The statistic analysis was done using chi square test because the distribution was non normal.

Here the **variable “x” is chi square value** calculated at 2° of freedom.

Knee Score	Resurfaced	Percentage	Non resurfaced	Percentage
Excellent	41	82%	43	86%
Good	4	8%	5	10%
Fair	2	4%	0	0
Poor	3	6%	2	4%
TOTAL	50	100%	50	100%

Visual Analogue Scale		
(Pre-op) x = 2.0172, p = 0.5688	Resurfacing	Non – Resurfacing
Zero	0	0
One	0	0
Two	0	0
Three	0	0
Four	2(4%)	2(4%)
Five	3(6%)	3(6%)
Six	6(12%)	9(18%)
Seven	13(26%)	10(20%)
Eight	25(50%)	23(46%)
Nine	1(2%)	2(4%)
Ten	0	1(2%)

Visual Analogue Scale		
(Post-op) x = 2.7984, p = 0.9464	Resurfacing	Non – Resurfacing
Zero	28(56%)	25(50%)
One	1(2%)	3(6%)
Two	3(6%)	4(8%)
Three	4(8%)	3(6%)
Four	0	0
Five	3(6%)	6(12%)
Six	2(4%)	2(4%)
Seven	3(6%)	2(4%)
Eight	4(8%)	3(6%)
Nine	2(4%)	2(4%)
Ten	0	0

**Visual Analogue Scale (VAS)** was used for anterior knee pain assessment pre and post operatively in both groups. However, there was no statistically significant difference in the pre and post operative period when compared amongst the two groups.

#### 4.2. Complications

There was no intra operative complication noted in either group. Two patients develop wound dehiscence, one patient had betadine allergy and one developed superficial wound infection in NRS group. In PRS group, one patient developed superficial wound infection and one developed deep wound infection in which the implant was removed and arthrodesis was done as a salvage procedure using Charnley’s clamps. The clamps were removed 3 months post operatively and weight bearing was started as tolerated. None of the patients underwent revision of total knee

replacement after the primary procedure. The major patellofemoral complications of patellar loosening, patellar fracture and patellar ligament rupture was not seen in either group due to short term (5 years) follow up. Long term result and follow up are yet to be analysed.

## 5. Discussion

The major findings of this study was that 82% of the patients in PRS group had shown excellent outcome compared to 86% in the NRS group. Additionally, VAS revealed no significant difference between two groups. The surgery was performed by senior surgeon, whose surgical technique has remained same over the years, thereby eliminating variable surgical technique and skills as confounding variables. These variations are due to different prosthetic designs on the femoral and the patellar side, different techniques regarding the retained patella, variable degrees of arthritis of patella, variable initial diagnosis and differences between different population groups add difficulties in interpretation of results of various studies. We kept duration of follow up of 60 months for both resurfaced and non resurfaced group, as most studies have reported that anterior knee pain develops early following TKA within first 18 months. With the increase of survival rates of TKA, patellar complications such as anterior knee pain, impingement, and secondary damage to patellar articular surface are also on the rise. In contrary, patients who had patellar resurfacing can lead to reduced survival rate because of wear, loosening of the implant, fractures, osteonecrosis of the patella, increase of chance of infections and subluxation of patella. Literature suggests complications after resurfacing the patella in total knee replacement depend on four main categories; these are patient factors, design factors, surgical techniques and material properties<sup>11</sup>

According to matthew p., resurfacing of patella is controversial. accurate component implantation is imperative for a successful outcome if the patella is resurfaced.<sup>12</sup> Cherian et al., 2016 studied prs versus circumferential denervation of patella in tka and compared the rates of anterior knee pain and functional outcomes between resurfaced patellas and non resurfaced patellas in 110 patients with minimum of 2 years follow up, and found no significant differences between the groups for kss, anterior knee pain, or vas.<sup>13</sup>

Abdul khan and nikhil pradhan reviewed 765 patients to study post-op patellofemoral pain, clunk and crepitus in resurfaced and non resurfaced groups. Incidence of post-op pain, clunk and crepitus is lower in the resurfaced group.<sup>14</sup> Results from meta analysis of 1725 knees concluded with no difference between the prs and nrs groups in terms of anterior knee pain, knee pain score, KSS and knee function score. absolute risk of reoperation was reduced by 4% in prs arm.<sup>15</sup>

In this observational study, we also did not find any statistical differences in pain, mobility and alignment. However, NRS group has shown better increment in overall score than PRS group. Previously published literature suggests that patella resurfacing reduce the anterior knee pain<sup>16</sup>. Studies done by Campbell et al.,<sup>17</sup> Chi Peng et al.<sup>18</sup> and Feller et al.<sup>19</sup> assessing KSS among patients undergoing TKA showed similar results to our study and there was no statistical significant difference between two groups as well.

Anterior Knee Pain should not be presumed to be secondary to patella femoral resurfacing or non resurfacing etiology.<sup>20</sup> Another prospective study showed that there was no difference between two sides in incidence of anterior knee pain/ascending or descending stairs.<sup>21</sup> However, Waikakul S. et al.<sup>22</sup> showed that patients with resurfacing had better results in terms of Anterior Knee Pain and tenderness but patients with non resurfacing had a better improvement of position sense. The above studies

emphasized that resurfacing should be used in severe articular cartilage damage, not as a routine operation. While analysing incidence of anterior knee pain, there was no significant difference as assessed by VAS in our study as well.

A longitudinal study done by Lyback et al.<sup>23</sup> with 52 patients has shown that anterior knee pain was present in 47% of patients with an un-replaced patella and 11% patients in resurfaced patella whereas, Holt GE et al.<sup>24</sup> showed that by retaining native patella they were able to retain highly satisfactory medium term results in terms of pain relief and function.

Through a prospective randomized study, Burnett et al.<sup>20</sup> with 10 year follow up found no significant differences in anterior knee pain, functional scores or revision rates between surfaced and non resurfaced groups.

Waters and Bently<sup>25</sup> observed that the overall postoperative knee scores were lower in the non resurfacing group and the difference was significant among patients with osteoarthritis. The findings of the study added that patients who had a bilateral knee replacement were more likely to prefer the resurfaced side.

Levitsky KA et al.<sup>26</sup> reported the incidence of anterior knee pain in the absence of resurfacing to be high as 19%, following with no incidence of reoperation in both the groups.

The patellar resurfacing alone will not prevent the occurrence of anterior knee pain, as the soft tissue balancing is equally important to mitigate the postoperative pain and complications too. With much attention and advancement of new prosthetic designs which appears to have substantially lowered the rate of complications of patellar resurfacing as the recent studies have demonstrated no appreciable risk of complications when compared with non resurfacing.

The follow up period of 5 years is barely adequate for the evaluation as the problems with wear and loosening of patellar component may increase with time. The study was carried out on a limited number of patients (N = 100). Another limitation of study is recollection bias since patients may have forgotten the tough time associated with first knee and may have higher expectations from second knee. Hence we have not included patients undergoing bilateral TKA. It shouldn't be always presumed that anterior knee pain before and after TKA is secondary to patellofemoral etiology, other factors may play a role in the dynamic development of anterior knee pain after TKA like patient and knee specific characteristics, prosthetic designs, operative technique, treatment of patella and time of assessment.

The continued study of this topic with long term follow up in randomized controlled trials remains essential to our understanding of patella in total knee arthroplasty. The development of total joint registries will allow surgeons to draw conclusions on the basis of large numbers of patients and will improve the reporting of results of patellar resurfacing in clinical trials.

## 6. Conclusion

Even after 20 years of debate, the decision whether to resurface the patella or not during the primary Total Knee Arthroplasty seemingly appears controversial. Despite having similar outcome scores regardless in both the groups, non resurfacing seems to provide better outcomes. There can be no definite conclusion because of many confounding factors such as component designs, surgeon experience and surgical techniques. However, our findings may be specific to certain extent because of the use of same prosthesis and the surgical techniques. None the less, a continued study of this issue with long term follow up in randomized, controlled, clinical trials remains essential to the understanding of the patella in TKA.

## Contribution

Lokesh Chawla: lead member of research team who followed up the patients and data collection, assisted all surgeries.

Shivanand M. Bandekar: Conceptualized the research question and performed surgeries.

Vivek Dixit: Manuscript preparation and literature search.

Ambareesh P: Data analysis.

Arun Krishnamoorthi: Data entry and record keeping.

Sushanth Mummigatti: Preoperative work up.

## Acknowledgement

We would like to thank the department of orthopaedics, Goa Medical College & Hospital along with OT Staff.

## References

- Pavone V, Boettner F, Fickert S, Sculco TP. Total condylar knee arthroplasty a long term follow-up. *Clin Orthop Relat Res.* 2001;388:18–25.
- Rand JA, Ilstrup DM. Survivorship analysis of total knee arthroplasty: cumulative rates of survival of 9200 total knee arthroplasties. *J Bone Joint Surg.* 1991;73A:397–409.
- Ritter MA. The Anatomical Graduated Component total knee replacement. A long-term evaluation with 20-year survival analysis. *J Bone Joint Surg.* 2009;91:745–749.
- Lygre SH, Espehaug B, Havelin LI, Vollset SE, Furnes O. Does patella resurfacing really matter? Pain and function in 972 patients after primary total knee arthroplasty. *Acta Orthop.* 2010;81:99–107.
- Dennis DA, Clayton ML, O'Donnell S, Mack RP, Stringer EA. Posterior cruciate condylar total knee arthroplasty. Average 11-year follow-up evaluation. *Clin Orthop Relat Res.* 1992;281:168–176.
- Doolittle 2nd KH, Turner RH. Patellofemoral problems following total knee arthroplasty. *Orthop Rev.* 1988;17:696–702.
- Clayton ML, Thirupathi R. Patellar complications after total condylar arthroplasty. *Clin Orthop Relat Res.* 1982;170:152–155.
- Insall J, Scott WN, Ranawat CS. The total condylar knee prosthesis. A report of two hundred and twenty cases. *J Bone Joint Surg Am.* 1979;61:173–180.
- Enis JE, Gardner R, Robledo MA, Latta L, Smith R. Comparison of patellar resurfacing versus nonresurfacing in bilateral total knee arthroplasty. *Clin Orthop Relat Res.* 1990;260:38–42.
- Clements WJ, Miller L, Whitehouse SL, Graves SE, Ryan P, Crawford RW. Early outcomes of patella resurfacing in total knee arthroplasty. *Acta Orthop.* 2010;81:108–113.
- Smith AJ, Lloyd DG, Wood DJ. A kinematic and kinetic analysis of walking after total knee arthroplasty with and without patellar resurfacing. *Clin Biomech.* 2006;21:379–386.
- Abdel Matthew P, Parratte Sebastian, Nicolaas C. *Budhiparama Curr Rev Musculoskeletal Med.* 2014;7:117–124.
- Brian A, Spencer DO, Jeffery J, et al. Patellar resurfacing versus circumferential denervation of the patella in total knee replacement. *Orthopaedics.* 2016;39:e1019–e1023.
- Khan Abdul, Pradhan Nikhil. Results of total knee replacement with/without resurfacing of patella. *Acta Orthop Bras.* 2012;20:300–302.
- Chen Kai, Li Guodong, Dong Fu, Yuan Chaoqun, Zhang Qiang, Cai Zhengdong. Patellar Resurfacing versus non resurfacing in total knee arthroplasty: a meta-analysis of randomised controlled trials. *Int Orthop.* 2013;37:1075–1108.
- Waters TS, Bentley G. Patellar resurfacing in total knee arthroplasty. A prospective, randomized study. *J Bone Joint Surg Am.* 2003;85-A:212–217.
- Campbell DG, Duncan WW, Ashworth M, et al. Patellar resurfacing in total knee replacement: a ten-year randomised prospective trial. *J Bone Joint Surg Br.* 2006;88:734–739.
- Peng CW, Tay BK, Lee BP. Prospective trial of resurfaced patella versus non-resurfaced patella in simultaneous bilateral total knee replacement. *Singap Med J.* 2003;44:347–351.
- Feller JA, Bartlett RJ, Lang DM. Patellar resurfacing versus retention in total knee arthroplasty. *J Bone Joint Surg Br.* 1996;78:226–228.
- Burnett RS, Boone JL, Rosenzweig SD, Steger-May K, Barrack RLJ. *Bone Joint Surg Am.* 2009;91:2562–2567.
- Keblish PA, Varma AK, Greenwald AS. Patellar resurfacing or retention in total knee arthroplasty. A prospective study of patients with bilateral replacements. *J Bone Joint Surg Br.* 1994;76:930–937.
- Waikakul S, Vanadurongwan V, Bintachitt P. The effects of patellar resurfacing in total knee arthroplasty on position sense: a prospective randomized study. *J Med Assoc Thai.* 2000;83:975–982.
- Lybäck CO, Lehto MU, Hämäläinen MM, Belt EA. Patellar resurfacing reduces pain after TKA for juvenile rheumatoid arthritis. *Clin Orthop Relat Res.* 2004;423:152–156.
- Holt GE, Dennis DA. The role of patellar resurfacing in total knee arthroplasty. *Clin Orthop Relat Res.* 2003;416:76–83.
- Waters TS, Bentley G. Patellar resurfacing in total knee arthroplasty. A prospective, randomized study. *J Bone Joint Surg Am.* 2003;85-A:212–217.
- Levitsky KA, Harris WJ, McManus J, Scott RD. Total knee arthroplasty without patellar resurfacing. Clinical outcomes and long-term follow-up evaluation. *Clin Orthop Relat Res.* 1993;286:116–121.



Contents lists available at ScienceDirect

## Journal of Arthroscopy and Joint Surgery

journal homepage: [www.elsevier.com/locate/jajs](http://www.elsevier.com/locate/jajs)

# A prospective comparative study between intravenous and intraarticular tranexamic acid administration in decreasing the perioperative blood loss in total knee arthroplasty

Nitin Mehta, Naman Goel, Ankit Goyal\*, Deepak Joshi, Deepak Chaudhary

Sports Injury Centre, VMMC and Safdarjung Hospital, New Delhi, India



## ARTICLE INFO

## Article history:

Received 4 May 2018

Accepted 9 November 2018

Available online 10 November 2018

## Keywords:

Tranexamic acid

Arthroplasty

Replacement

Knee

Blood loss

## ABSTRACT

**Purpose:** Total knee arthroplasty (TKA) is a common and safe surgical procedure, but the high perioperative blood loss is a cause of concern. Use of tranexamic acid to address this issue has gained popularity recently but no clear consensus is available regarding its ideal mode of administration. We conducted this study to evaluate and compare the efficacy of intravenous as well as intraarticular routes of administration of tranexamic acid.

**Methods:** 300 patients planned for B/L Total Knee Arthroplasty were randomized into 3 groups; group IV (Intravenous, n = 100), group IA (Intraarticular, n = 100) and a control group (n = 100). In group IV, patients received 1 g tranexamic acid intravenously; in group IA 2.5 g tranexamic acid was given intraarticular in both knees and a control group which did not receive tranexamic acid. The primary outcomes measures were total blood loss (intraoperative blood loss + drain amount), pre and post surgery haemoglobin levels and the transfusion rate and quantity. The secondary outcome measures were complications.

**Results:** Administration of tranexamic acid through either of the two routes resulted in statistically significant decrease in the total perioperative blood loss and transfusion requirement. There was no statistically significant difference in the results between the two test groups.

**Conclusions:** Both intravenous as well as intraarticular administration of tranexamic acid provided excellent results no known adverse effects. However neither of the two modalities should be considered superior to the other.

© 2018 Published by Elsevier, a division of RELX India, Pvt. Ltd on behalf of International Society for Knowledge for Surgeons on Arthroscopy and Arthroplasty.

## 1. Introduction

Total knee arthroplasty (TKA) is a common surgical procedure performed to relieve the pain and disability associated with advanced arthritis of the knee due to any cause. The dramatic improvement in pain and functional status of the patient has led to its widespread acceptance. Although this procedure is considered to be relatively safe, the high perioperative blood loss<sup>1,2</sup> is a cause of concern. Since majority of the patients undergoing a TKA are in the older age group with associated co-morbidities, significant blood loss carries an even greater risk.

In order to address this problem various strategies are available. These include use of pneumatic tourniquet, regional anaesthesia, controlled hypotension, intra-operative blood salvage etc. The use of intra-operative tourniquet to decrease the total blood loss in TKA has remained questionable.<sup>3,4</sup> Despite these measures, the amount of blood loss in TKA ranges from 500 to 1500 ml<sup>5,6</sup> which necessitates the frequent use of allogenic blood transfusion. Excess bleeding may lead to prolonged post-operative pain, wound hematoma formation and arthrofibrosis, all of which may compromise the final outcome of surgery. Hence perioperative blood loss management is imperative to prevent the bleeding related complications and transfusion related morbidity. One such strategy that is gaining popularity worldwide over the last few years is the use of an antifibrinolytic agent such as tranexamic acid.

Various studies including reviews and meta-analysis have demonstrated the efficacy of both intravenous(IV) and

\* Corresponding author.

E-mail addresses: [nitinmehta2001@yahoo.com](mailto:nitinmehta2001@yahoo.com) (N. Mehta), [goel.dnman@gmail.com](mailto:goel.dnman@gmail.com) (N. Goel), [ankit.ortho@gmail.com](mailto:ankit.ortho@gmail.com) (A. Goyal), [dr\\_j@rediffmail.com](mailto:dr_j@rediffmail.com) (D. Joshi), [deepakchaudhary@hotmail.com](mailto:deepakchaudhary@hotmail.com) (D. Chaudhary).



intraarticular (IA) administration of tranexamic acid in reducing blood loss in TKA without any increased risk of thromboembolic complications.<sup>9–11</sup> However no clear consensus is available regarding which mode of administration is superior. This has prejudiced the use of this potentially valuable substance in becoming a routine in orthopaedic practice.

Hence we conducted this study to evaluate the efficacy as well as compare the two modalities of tranexamic acid administration i.e. intravenous & intraarticular, in reducing the perioperative blood loss and transfusion requirements in patients undergoing total knee arthroplasty. Further the results were compared with a control group in which tranexamic acid was not given with all other factors kept alike.

## 2. Materials and methods

A prospective comparative study was conducted between April 2016 and Oct 2017 involving 300 consecutive patients scheduled for total knee arthroplasty due to advanced osteoarthritis of knee. Only cases undergoing Bilateral Total Knee Arthroplasty were included in our study to maintain uniformity.

Each patient scheduled for a primary B/L TKA in our centre was subjected to a thorough evaluation. The pre-operative haemostatic assessment including haemoglobin level, platelet count, bleeding time, clotting time, Prothrombin time, activated partial thromboplastin time, INR ratio was done apart from other routine investigations.

Patients with history of previous ipsilateral knee surgery, allergy/hypersensitivity to TXA, known history of thromboembolic disease (DVT/PE/Stroke/transient Ischemic attack), any renal/hepatic insufficiency or preoperative coagulopathy (platelet count < 150000/INR > 1.4) were excluded.

The study was approved by the institutional ethics committee. A written informed consent was taken from the patients who fulfilled the criteria. The base line characteristics of the patients such as age, weight, height, BMI, gender and any co-morbidity were recorded.

Patients were subjected to computer generated randomization and were allocated to an Intravenous (IV) group (n = 100), an intraarticular (IA) group (n = 100) and a control (C) group (n = 100).

In Group IV, patients received 1 g tranexamic acid through intravenous route after sensitivity testing. TXA was administered after combined spinal epidural anaesthesia was given but before inflation of tourniquet. A single dose of tranexamic acid was given in our study.

In Group IA, patients received 2.5 g TXA (500mg/5 ml vial; 25 ml) diluted with 25 ml normal saline to form a total volume of 50 ml given equally in both the knee joints after wound closure through the drain pipe which was clamped immediately after administration of TXA.

In Group C patients did not receive tranexamic acid with all other factors kept alike.

### 2.1. Operative technique and post operative care

Bilateral Total Knee Arthroplasty was performed under combined spinal epidural anaesthesia. The same surgical team operated all the cases. The pneumatic tourniquet was applied to the proximal thigh with pressure of 280 mm Hg. Prophylactic antibiotics were given and the standard midline skin incision and medial parapatellar arthrotomy approach was used. After bony preparation, the implant (PFC sigma, DePuy) was inserted with full cementation. The orifice of the femoral medullary cavity was plugged with a bone fragment. Post cement setting the tourniquet was deflated and bleeders were cauterised. The intraoperative blood loss was determined by measuring the weight change of gauze pieces/mop

pads by using a weight measuring device and by observing the fluid level of suction reservoirs. From the sum of these two values the volume of fluid used for irrigation was subtracted which gave us an approximate value of the intraoperative blood loss. The standard drain tube (Size 14) was placed in the joint. Wound was closed sequentially in layers. As mentioned above, in Group IA, the tranexamic acid preparation was injected into the joint using the drain and immediately clamped. A bulky compressive dressing was applied thereafter. In all patients the drain was clamped for 4 h and then opened. The drain was removed at the time of 1st post op dressing done on day 2 of surgery.

In the post operative period each patient received the same protocol regarding analgesia, antibiotic prophylaxis and DVT prophylaxis. We use tablet apixaban 2.5 mg started 24 h after surgery and given twice a day for 12 days for DVT prophylaxis. The post operative Hb level was assessed on day 2 and this value was used for comparison in our study. Blood transfusion was done if Hb level was less than 10 or if any anaemic symptoms or anaemia related organ dysfunction was suspected and this was recorded.

The drain output was measured and recorded at the time of removal of drains on post op day-2. Patients were encouraged to do ankle pump exercises in the immediate post op period and were mobilised using walker on day 2 of surgery. Patients were daily assessed clinically for any signs of DVT/PE and Doppler ultrasound was done only if any symptoms suggestive of DVT were present. Any other post op complications such as skin necrosis, infection etc were also recorded.

### 2.2. Outcome measures

The primary outcome measures included the total amount of blood loss (intraoperative blood loss + post operative blood loss through suction drains of both knees), the pre and post surgery haemoglobin levels, the transfusion rate and the transfusion quantity. The secondary outcome measures were complications such as superficial or deep infection, wound dehiscence, DVT, Pulmonary embolism, or any organ dysfunction.

### 2.3. Statistical analysis

Statistical analysis was performed by the SPSS program for Windows, version 17.0. Continuous variables are presented as mean  $\pm$  SD, and categorical variables are presented as absolute numbers and percentage. Data were checked for normality before statistical analysis using Shapiro Wilk test. Normally distributed continuous variables were compared using ANOVA. If the F value was significant and variance was homogeneous, Tukey multiple comparison test was used to assess the differences between the individual groups; otherwise, Tamhane's T2 test was used. Categorical variables were analyzed using the chi square test. For all statistical tests, a p value less than 0.05 was taken to indicate a significant difference.

## 3. Results

The demographic data of the three groups was comparable with no significant differences in age, weight, height, BMI and gender distribution (Table 1).

The operative and post operative characteristics are presented in Table 2. The mean value of the tourniquet time did not show any significant difference (p = 0.585) between the three groups. The Hb values preoperatively varied from 10.8 to 14.9 but the mean values in all groups were comparable. The post op Hb values were significantly lower in the control group and the fall of Hb was significant when compared between the Control and IV group as

**Table 1**  
Demographic factors.

	Control Group	Group IV	Group 1A	P Value
	Mean ± SD	Mean ± SD	Mean ± SD	
Age	61.34 ± 7.38	62.86 ± 6.08	61.85 ± 4.81	0.219
Weight	64.25 ± 11.08	65.61 ± 12.02	62.83 ± 11.37	0.234
Height	1.55 ± 0.13	1.58 ± 0.09	1.57 ± 0.09	0.084
BMI	27.36 ± 6.12	26.52 ± 5.58	25.79 ± 5.04	0.143
Gender(F/M)	62/38	59/41	56/44	0.689

**Table 3**  
Transfusion data.

Transfusion	Control Group	Group IV	Group 1A	P Value
	Frequency (%)	Frequency (%)	Frequency (%)	
0	26 (26.0%)	63 (63.0%)	56 (56.0%)	<0.001
1	56 (56.0%)	32 (32.0%)	27 (26.0%)	
2	17 (17.0%)	5 (5.0%)	10 (10.0%)	
3	1 (1.0%)	0 (0.0%)	0 (0.0%)	
Total	100 (100%)	100 (100%)	100 (100%)	

well as between the control and the IA group ( $p = 0.013$ ). However no such statistically significant difference existed when the values were compared between the two test groups i.e. the intravenous and intraarticular group ( $p = 1.0$ ).

The intraoperative blood loss values declined maximally in the IV group and the result was statistically significant ( $p < 0.001$ ). This shows that there is a significant reduction in intraoperative blood loss when intravenous tranexamic acid is given at the start of the surgery. Since IA tranexamic acid is given through drain pipes after wound closure, its main role is to decrease the volume of post operative blood loss through suction drains.

The mean total drain output in each of the two test groups was much lower than the control group. The results were statistically significant in all intra group comparisons thereby implying that the extent of post operative blood loss in significantly reduced in both the test groups as compared to the control group and this reduction was more in the IA group as compared to the IV group.

The mean total blood loss of both knees in the control group was  $1061.30 \pm 170.06$  whereas in the IV and IA groups it was  $607.90 \pm 94.37$  and  $614.15 \pm 128.73$  respectively. Both test groups had a statistically significant reduction in the total blood loss. However we could not find any statistical difference between the two test groups ( $p = 0.972$ ).

The transfusion rate in control group, IV group and IA group was 74%, 37% and 44% respectively. The number of units transfused was also higher in the control group with respect to the two test groups and this difference was statistically significant (Table 3).

### 3.1. Complications

In our study no adverse events attributable to tranexamic acid were found in any of the patients receiving either IV or IA tranexamic acid. One patient in the control group developed deep infection which was managed as per protocol. 3 patients in IV and 2 in IA group developed superficial stitch line infections which were managed by debridement and extended course of antibiotics. No patient was found with signs of DVT or pulmonary embolism.

## 4. Discussion

Total knee arthroplasty is becoming increasingly popular primarily due to its high success rate and minimal complications. Perioperative blood loss management has been identified as the key factor that can further improve the outcome of this surgery. Out of the various strategies that are available, tranexamic acid has shown promising results in various studies done in recent years to evaluate its efficacy and safety profile.<sup>9–11</sup>

In the present study, the role of tranexamic acid, given by two most popular routes of administration i.e. the intravenous route and the intraarticular route, was investigated in cases of B/L TKA. This was done by monitoring a variety of parameters such as the drop in haemoglobin levels, the difference in the intraoperative blood loss, drain amount and transfusion requirements between the two test groups and further the results were compared with a control group to validate the findings.

For intravenous administration of TXA, no clear cut guidelines are available in literature regarding the dosage, number of injections and time of administration of tranexamic acid. Various authors have reported excellent results with multiple dose IV administration regimes involving 2–3 doses given at specified times during the surgery ranging from just before tourniquet inflation till 3 h after surgery.<sup>9,10,12,13</sup> Tzatzairis T et al.<sup>15</sup> conducted a study comparing the role of IV TXA with topical TXA in decreasing blood loss in TKA found that a single 1 g IV TXA administration given 20 min before tourniquet inflation was effective in decreasing the blood loss. However conflicting evidence was provided by other authors such as Maniar RN et al.<sup>18</sup> who found that a single dose did not give effective results and the three dose regime gave best results. Regarding the amount of TXA, Noticewala MS et al.<sup>16</sup> reported good results with 500 mg IV tranexamic acid, but most authors have used a dose of 10 mg/kg<sup>9,10,12,13</sup> or a fixed dose of 1 g<sup>14,15</sup> TXA. We used a single dose of 1 g tranexamic acid given 15–20 min prior to tourniquet inflation in our study.

Regarding topical administration also no fixed guideline is available in current literature. Multiple studies<sup>9–16</sup> using different

**Table 2**  
Operative and post operative characteristic and comparisons.

Tourniquet time (minutes)	Control Group	Group IV	Group 1A	P Value	Control Group V/S Group IV	Control Group V/S Group 1A	Group IV V/S Group 1A
	Mean ± SD	Mean ± SD	Mean ± SD				
	85.96 ± 8.20	86.26 ± 8.83	85.00 ± 9.83	0.585			
Haemoglobin (g/dl)							
Pre op	12.85 ± 0.97	12.74 ± 1.01	12.76 ± 1.11	0.712	0.727	0.788	0.994
Post op	9.96 ± 1.12	10.41 ± 1.00	10.41 ± 1.17	0.005	0.013	0.013	1.000
Drain output (ml)							
Right	366 ± 11.66	219.5 ± 60.09	156.35 ± 58.09	<0.001	<0.001	<0.001	<0.001
Left	363 ± 102.4	222.6 ± 54.84	180 ± 63.04	<0.001	<0.001	<0.001	<0.001
Total	729 ± 156.38	442.1 ± 19.73	336.35 ± 89.95	<0.001	<0.001	<0.001	<0.001
Intraoperative blood loss(ml)	332.30 ± 64.71	165.80 ± 49.75	317.80 ± 86.15	<0.001	<0.001	0.1799	<0.001
Total blood loss(ml)	1061.30 ± 170.06	607.90 ± 94.37	614.15 ± 128.73	<0.001	<0.001	<0.001	0.972

concentrations of tranexamic acid for local administration have been published showing good results. Concentrations of TXA ranging from 1 g to 3 g diluted with normal saline have been used in these studies. Most have administered the diluted tranexamic acid solution through the drain pipe into the joint cavity after wound closure. In the present study, good results were obtained with diluted solution of 2.5 g TXA administered in both knees intraarticularly. The drain pipe was clamped immediately and opened after 4 h because for the agent to work a stipulated contact period is necessary. The duration of clamping the drain pipe was variable in the literature with the usual duration being 1 h.<sup>16</sup> Paphon Sa-ngasoongsong et al.<sup>17</sup> evaluated the efficacy of low dose IA-TXA with prolonged drain clamping (upto 12 h) and found it to a safe and effective blood conservation technique. The proposed advantage of intraarticular mode of administration is that since the systemic absorption is very low<sup>17</sup> the theoretical adverse effects of TXA, such as increased risk of thromboembolic events, can be minimised by using this approach.

Despite the abundance of literature supporting the use of tranexamic acid in reducing blood loss associated with TKA, its routine use is still limited and this was the key reason why we conducted this study. In the present study, it was found that IV administration of TXA was effective in decreasing both the intra operative blood loss as well as the drain amount, effectively decreasing the mean perioperative blood loss by over 40%. As a result the transfusion requirement in this set of patients also went down.

Since the surgeries were performed under tourniquet control, we were sceptical about the raised risk of thromboembolic events due to TXA usage. However this group did not have any thromboembolic complications or any other adverse events which may be attributed to the use of IV tranexamic acid.

Similar results were obtained in Group IA, in which intra-articular administration of TXA acid was done. Significant decrease in the drain output was observed, as a result of this, fall of Hb and the transfusion requirement went down in this group of patients. No adverse local events were reported following the use of TXA in the joint cavity.

These findings are in accordance with the existing literature with minor differences.<sup>9–16</sup> We feel the differences are due to the different regimes and the dosage of TXA used in other studies as a higher dose could lead to better haemostasis.

In the present study bias was eliminated by including a demographically comparable population, with the surgery performed by the same surgical team using a fixed implant design. However, we feel that there were several shortcomings of our study. Firstly, we recognise that our study was not blinded. Secondly the role of different concentrations/repetition of TXA could not be investigated because of lack of dose dependant groups. Also the long term sequelae of its use or development of any late thromboembolic events was not studied.

The results of our study further reinforce the fact that tranexamic acid is an extremely valuable agent that is cheap, easily available and devoid of any adverse effects, that may have a tremendous role to play in improving the outcome of TKA surgeries in the future.

## 5. Conclusions

In our study involving 300 subjects undergoing B/L Total Knee

Arthroplasty, we found that a single preoperative dose of 1 g tranexamic acid is highly effective in decreasing the perioperative blood loss with no known adverse effects. The intraarticular administration of tranexamic acid also provided similar results. The use of this cost effective measure to conserve blood is thus recommended. But we also conclude that neither of the two modalities should be considered superior to the other as both have shown similar results. Further clinical studies are necessary to determine the precise dosage and timing to make the best use of this worthy agent.

## Funding

This research did not receive any specific grant from funding agencies in the public, commercial, or not-for-profit sectors. [7, 8].

## References

- Hiippala ST, Strid LJ, Wennerstrand MI, et al. Tranexamic acid radically decreases blood loss and transfusions associated with total knee arthroplasty. *Anesth Analg*. 1997;84(4):839–844.
- Sehat KR, Evans RL, Newman JH. Hidden blood loss following hip and knee arthroplasty. Correct management of blood loss should take hidden loss into account. *J Bone Joint Surg Br*. 2004;86(4):561–565.
- Mutlu S, Guler O, Mutlu H, et al. Tourniquet use during total knee arthroplasty does not offer significant benefit: a retrospective cohort study. *Int J Surg*. 2015;18:123–127.
- Smith TO, Hing CB. Is a tourniquet beneficial in total knee replacement surgery? A meta-analysis and systematic review. *Knee*. 2010;17(2):141–147.
- Sehat KR, Evans R, Newman JH. How much blood is really lost in total knee arthroplasty? Correct blood loss management should take hidden loss into account. *Knee*. 2000;7:151–155.
- Rosencher N, Kerckamp HE, Macheras G, et al. Orthopedic surgery transfusion hemoglobin European Overview (OSTHEO) study: blood management in elective knee and hip arthroplasty in Europe. *Transfusion*. 2003;43:459–469.
- Jans O, Kehlet H, Johansson PI. Transfusion-related mortality after primary hip arthroplasty – an analysis of mechanisms and confounders. *Vox Sang*. 2012;103:301–308.
- Hoylaerts M, Lijnen HR, Collen D. Studies on the mechanism of the anti-fibrinolytic action of tranexamic acid. *Biochim Biophys Acta*. 1981;673:75–85.
- Alshryda S, Sukeik M, Sarda P, et al. A systematic review and meta-analysis of the topical administration of tranexamic acid in total hip and knee replacement. *Bone Joint Lett J*. 2014;96(8):1005–1015.
- Yang ZG, Chen WP, Wu LD. Effectiveness and safety of tranexamic acid in reducing blood loss in total knee arthroplasty: a meta-analysis. *J Bone Jt Surg Am*. 2012;94:1153–1159.
- Kim TK, Chang CB, Koh JJ. Practical issues for the use of tranexamic acid in total knee arthroplasty: a systematic review. *Knee Surg Sports Traumatol Arthrosc*. 2014;22(8):1849–1858.
- Lemaire R. Strategies for blood management in orthopaedic and trauma surgery. *J Bone Jt Surg Br*. 2008;90:1128–1136.
- Fu DJ, Chen C, Guo L, et al. Use of intravenous tranexamic acid in total knee arthroplasty: a meta-analysis of randomized controlled trials. *Chin J Traumatol*. 2013;16:67–76.
- Freedman J, Luke K, Monga N, et al. A provincial program of blood conservation: the Ontario Transfusion Coordinators (ONTrAC). *Transfus Apher Sci*. 2005;33:343–349.
- Tzatzairis T, Drosos GI, Kotsios S, et al. Intravenous vs topical tranexamic acid in total knee arthroplasty without tourniquet application: a randomized controlled study. *J Arthroplasty*. 2016;31(11):2465–2470.
- Noticewala MS, Nyce JD, Wang W, et al. Predicting need for allogeneic transfusion after total knee arthroplasty. *J Arthroplasty*. 2012;27:961–967.
- Sa-ngasoongsong P, Wongsak S, Chanplakorn P, et al. Efficacy of low-dose intra-articular tranexamic acid in total knee replacement: A prospective triple-blinded randomized controlled trial. *BMC Musculoskel Disord*. 2013;14:340.
- Maniar RN, Kumar G, Singhi T, et al. Most effective regimen of tranexamic acid in knee arthroplasty: a prospective randomized controlled study in 240 patients. *Clin Orthop Relat Res*. 2012;470(9):2605–2612.



# A novel method for protecting the inter-meniscal ligament during anterior cruciate ligament reconstruction

David R.W. MacDonald\*, Iain Stevenson

Aberdeen Royal Infirmary, Aberdeen, AB25 2ZN, UK



## ARTICLE INFO

### Article history:

Received 12 April 2018

Accepted 9 November 2018

Available online 10 November 2018

## ABSTRACT

The intermeniscal ligament is an anatomical structure which is a risk of damage during arthroscopic anterior cruciate ligament reconstruction. We present a simple technique to protect this structure during the procedure.

© 2018 Published by Elsevier, a division of RELX India, Pvt. Ltd on behalf of International Society for Knowledge for Surgeons on Arthroscopy and Arthroplasty.

## 1. Background

The intermeniscal (IM) ligament is described in Gray's anatomy as “connecting the anterior convex margin of the lateral meniscus to the anterior end of the medial meniscus”. The average perpendicular distance of the IM ligament from the tibial insertion of the anterior cruciate ligament is 7.8 mm.<sup>1</sup> As improper tunnel placement is the cause of failure of ACL reconstruction in 70% of cases, and ideal tibial tunnel placement is described as 9 mm posterior to the IM ligament, the ligament is at risk of damage during ACL reconstruction.<sup>2</sup>

## 2. Technique

We have found that it is possible to retract the IM ligament anteriorly and away from the site of tibial tunnel drill placement using an arthroscopic hook (Fig. 1). The hook can be placed through the same arthroscopic portal as the arthroscope, or through a separate anteromedial, anterolateral or central patellar portal, and is held by the assistant during drilling of the tunnel. This technique reliably prevents damage to the IM ligament.

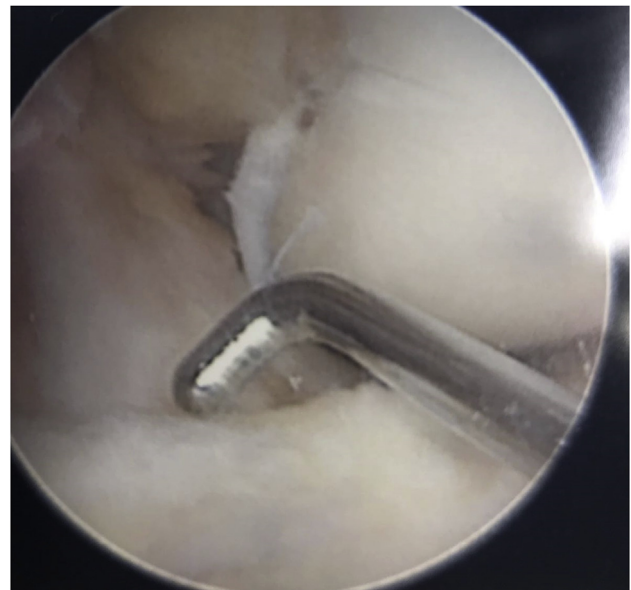


Fig. 1. Retraction of the intermeniscal ligament using an arthroscopic hook.

## 3. Discussion

The result of damage to the IM ligament is unknown. In biomechanical studies, sectioning of the ligament has been shown not to adversely affect tibiofemoral or menisci contact stresses.<sup>3</sup>

However histological studies have demonstrated the presence of free nerve endings and mechanoreceptors within the IM ligament, suggesting it may have a proprioceptive role.<sup>4</sup> It has also been suggested that damage to the IM ligament may play a role in anterior knee discomfort following intramedullary tibial nailing.<sup>5</sup> Given this uncertainty it is important to preserve this structure.

\* Corresponding author.

E-mail addresses: [david.macdonald7@nhs.net](mailto:david.macdonald7@nhs.net) (D.R.W. MacDonald), [iainstevenson@nhs.net](mailto:iainstevenson@nhs.net) (I. Stevenson).

## References

1. Nelson EW, Laprade RF. The anterior intermeniscal ligament of the knee: an anatomic study. *Am J Sports Med.* 2000;28:74–76.
2. Patel KA, Chhabra A, Makovicka JL. Anterior cruciate ligament tunnel placement using the pathfinder guide. *Arthroscopy Techniques.* 2017;6:1291–1296.
3. Poh SY, Yew KS, Wong PL, et al. Role of the anterior intermeniscal ligament in tibiofemoral contact mechanics during axial joint loading. *Knee.* 2012;19:135–139.
4. Yildirim FB, Soyuncu Y, Oguz N, et al. Anterior intermeniscal ligament: an ultrastructural study. *Ann Anat.* 2007;189:510–514.
5. Yildirim FB, Soyuncu Y, Oguz N, Aydin AT, Sindel M, Ustunel I. Quantification of anterior cortical bone removal and intermeniscal ligament damage at the tibial nail entry zone using parapatellar and retropatellar approaches. *J Orthop Trauma.* 2013;27:438–441.



## Case report

## Arthroscopy assisted stieda process excision in a case of posterior ankle impingement

Clement Joseph <sup>a</sup>, Shiva Reddy <sup>b</sup>, Arjun Ballal <sup>c,\*</sup><sup>a</sup> Department of Arthroscopy and Sports Medicine, Gleneagles Global Health City, 439, Cheran Nagar, Perumbakkam, Chennai, Tamil Nadu, 600100, India<sup>b</sup> Department of Arthroscopy and Sports Medicine, 439, Cheran Nagar, Perumbakkam, Chennai, Tamil Nadu, 600100, India<sup>c</sup> Ballal Healthcare, 'Sweeny Complex', Near Khushi Hotel, Santhekatte, Kallianpur, Udipi, 576105, India

## ARTICLE INFO

## Article history:

Received 29 January 2018

Accepted 2 September 2018

Available online 4 September 2018

## ABSTRACT

Hindfoot pain can result from bony and soft tissue causes and can be traumatic or non-traumatic. Here we present a rare case of hindfoot pain due to impingement from an elongated lateral tubercle (Stieda's process) of the posterior process of the talus in a 40 year old man and its management. The patient underwent hindfoot arthroscopy, with excision of the Stieda's process and decompression of Flexor hallucis tendon. It was followed by immobilisation in POP SLAB for a week and Cam boot walker mobilisation for three weeks. On follow up His AOFAS scores improved from 45/100 points to 94/100 points.

© 2018 Published by Elsevier, a division of RELX India, Pvt. Ltd on behalf of International Society for Knowledge for Surgeons on Arthroscopy and Arthroplasty.

## 1. Introduction

Hindfoot pain can be caused by traumatic and non-traumatic pathologies. Some of the causes of non-traumatic hindfoot pain include Tenosynovitis, tarsal tunnel syndrome, Haglund's deformity, a prominent lateral process (Stieda's process) and Os trigonum can be termed as the non-traumatic causes.<sup>1,2</sup>

Stieda's process, which is an elongated lateral process of talus is also sometimes considered an anatomical variant.<sup>2–4</sup> It usually forms from the fusion of a secondary ossification center at the posterolateral aspect of the talus with rest of the talus where the fused segment remains longer than usual, usually this occurs between 7 and 13 years.<sup>5</sup> L. Stieda described it in 1869.<sup>6</sup> It is often identified in lateral views of the ankle and in sagittal sections of CT and MRI.<sup>2</sup> Stieda's process can produce symptoms if it is acutely fractured or if it causes impingement between tibia and posterior aspect of calcaneum, especially in plantar flexion. It needs to be differentiated from an os trigonum (particularly if partially fused): which refers to a separate bony ossicle at the lateral tubercle of the talus.<sup>2</sup>

Impingement due to an Stieda's process is often treated by excision by open or arthroscopic techniques after failure of

conservative measures.<sup>2</sup>

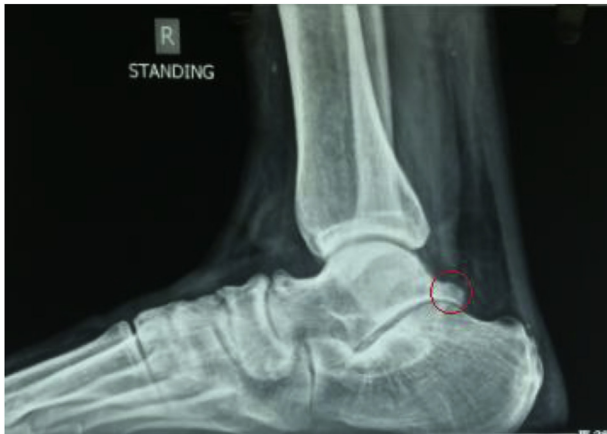Here we present a case of hindfoot pain due to a Stieda process managed successfully by arthroscopic excision.

## 2. Materials and methods

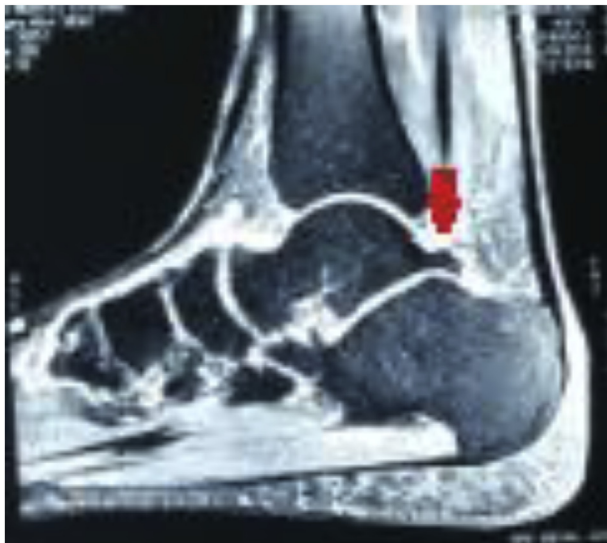A 40 year old gentleman presented to our out-patient department with history of right hindfoot pain for over four years. There was not history of any trauma. The pain was insidious in onset and was gradually progressive. The pain aggravated on activity and was relieved at rest. He used to play badminton occasionally, which he was unable to do. He was not a smoker or alcoholic and there were no other constitutional symptoms. He had a history of three injections to the ankle wherein the last injection to the posterior part of the ankle gave good improvement of symptoms for a period for three months. Clinical examination revealed tenderness in the posterior compartment of the ankle, which aggravated with plantarflexion of the ankle. There were no signs of inflammation. His ankle showed a five degrees decrease in plantar flexion and inversion as compared to the contralateral ankle and nearly normal comparable dorsiflexion and eversion. His American Orthopaedic Foot and Ankle Society's (AOFAS) ankle-hindfoot scale<sup>7</sup> was noted to be 45/100 points. The lateral radiographs of the ankle and MRI revealed an elongated lateral tubercle of the talus (Stieda's process) [Figs. 1 and 2]. He was advised arthroscopic excision as he was significantly disabled.

\* Corresponding author.

E-mail address: [5arjunballal@gmail.com](mailto:5arjunballal@gmail.com) (A. Ballal).

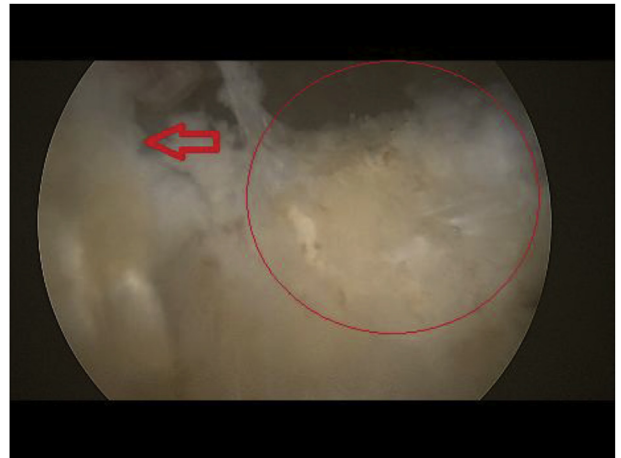

**Fig. 1.** Lateral radiograph of the right ankle showing an elongated lateral tubercle of the posterior process of the right talus, marked by the circle.

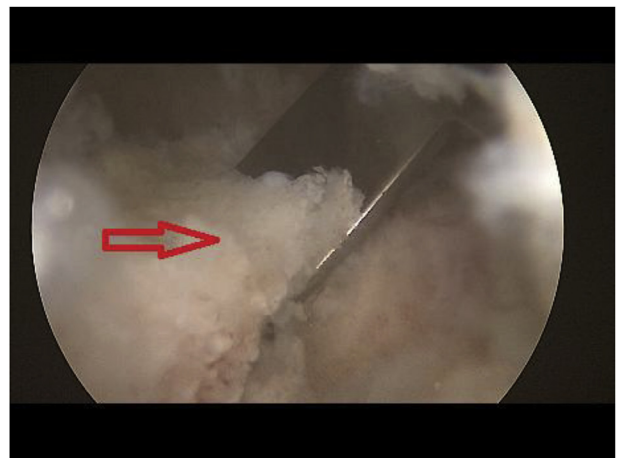


**Fig. 2.** Pre-operative MRI of the right ankle showing the elongated lateral tubercle of the posterior process (Stieda's process) marked by the red arrow.


Under general anaesthesia, tourniquet control and prone position, with ankles free outside the table, a horizontal line connecting the tips of medial and lateral malleoli was marked on the posterior ankle. At this level, posteromedial portal was made just anterior to the medial border of tendoachilles and the trocar was inserted at right angle, to prevent injury to the neurovascular structures. The posterolateral portal was made at the same level, but a cm anterior to the lateral border of the tendoachilles. The posterior process was found to be right in front of the scope [Fig. 3]. Soft tissue was cleared around the talar process by shaver and radiofrequency probe. Tibiotalar joint could be identified above the process after debriding a bit of the posterior capsule and subtalar joint could not be identified because of the prominence of the process. The talar process was excised using burrs, chiselling and shavers to ensure a flat surface posteriorly and the subtalar joint line could be visualised after the excision [Fig. 4]. The portals were switched and the flexor hallucis longus tendon was identified and even though the mobility was normal, a decompression was performed. An erosive irregular area was noted on the superior aspect of the calcaneum due to the impingement of the Stieda process. Smoothing of this area was done with the burr [Figs. 5 and 6].



**Fig. 3.** Intra-operative image, within the circle is the Stieda process and the arrow marking the flexor hallucis longus tendon.



**Fig. 4.** Intra-operative image, during resection of the Stieda process using a chisel. The arrow indicating the Stieda process being osteotomized.



**Fig. 5.** Intra-operative image, smoothing of the rough surfaces of the calcaneum with a burr after osteotomy.

Post operatively, the ankle was immobilised in a below knee POP slab for a week and then a cam walker boot was applied. Ankle

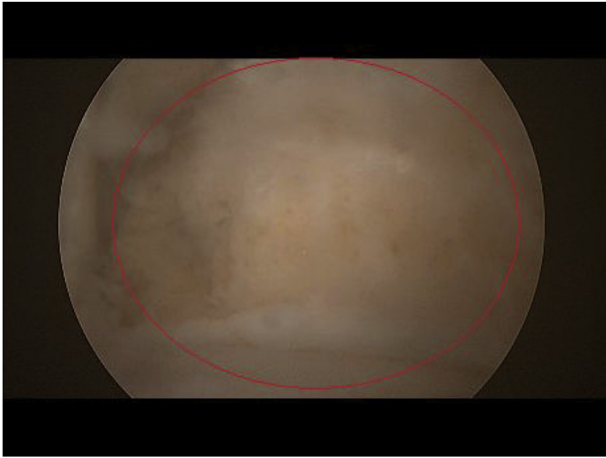


Fig. 6. Intra-operative image, after osteotomy of the Stieda process.

mobilisations were started after first week and the patient was allowed partial weight bearing for three weeks after which the walker boot was discontinued. Post-operative radiographs showed a satisfactory excision of the process with no irregularities [Fig. 7]. He was reviewed at regular intervals and range of motion exercises were started at three weeks. The AOFAS scores consistently improved to 74, 87 and 94 at one, two and three months followup respectively with significant resolution of symptoms.

### 3. Discussion

Impingement syndromes around ankle, though common anteriorly (footballer's ankle), can occur posteriorly also. Impingement could result from soft tissue or bony causes.<sup>8,9</sup> Posterior impingement could be acute due to a fracture or an avulsion of the posterior

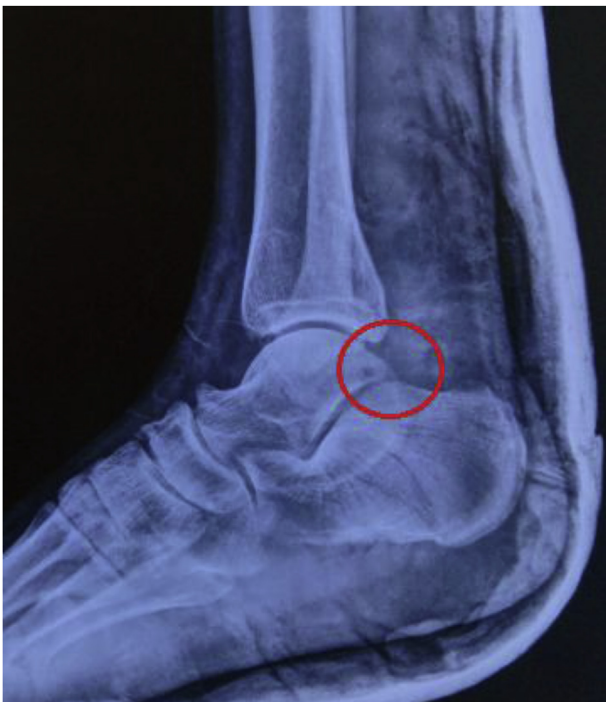

Fig. 7. Post-operative radiograph after the excision of the Stieda process marked by the empty circle.

process of talus and subacute or chronic injuries due to repetitive overuse injury.<sup>10</sup> An elongated lateral tubercle could produce impingement between the posterior tibial margin and calcaneum producing pain on running and walking on uneven surfaces.<sup>2</sup> Forced plantarflexion may be painful and swelling on either side of tendoachilles may be observed in some patients.<sup>2</sup> Magnetic Resonance Imaging has been the major modality of investigation.<sup>8,9</sup> Local anaesthetic infiltration under image guidance around the process will relieve the pain and serve as a diagnostic tool as well as a positive predictive indicator for surgical outcome as seen in this patient.<sup>11</sup> Cortisone infiltrations can result in short term temporary pain improvement.<sup>11</sup>

Arthroscopy assisted debridement and excision of the bony deformity cause less morbidity as compared to open surgery [10]. Injury to the posteromedial neurovascular bundle can be avoided by careful placement of the posteromedial portal and careful usage of the burr.<sup>10</sup>

C. Dijk reported reduced recovery time, complications and excellent results in 83% of the patients in 5–8 years of follow with arthroscopic management.<sup>12</sup> Lee and colleagues reported encouraging results after arthroscopic excision of os trigonum in bilateral ankles in a 32 year old adult.<sup>13</sup> Arthroscopic excision of Stieda process can result in good clinical improvement as seen in this patient and it is easy and reproducible, provided care is taken not to injure the neurovascular bundle.<sup>10</sup>

Good outcomes in terms of patient satisfaction are noted in both open and arthroscopic techniques. However, lower complication rates and quicker return to activity and sports were found with arthroscopic techniques.<sup>14</sup>

### Conflicts of interest

We hereby declare that there is no conflict of interest.

### References

- Ogut T, Ayhan E, Irgit K, Sarikaya AI. Endoscopic treatment of posterior ankle pain. *Knee Surg Sports Traumatol Arthrosc.* 2011;19:1355–1361.
- Yilmaz C, Eskandari MM. Arthroscopy. Arthroscopic excision of the talar Stieda process. 2006 Feb;22(2):225. e1–225.e3.
- Cerezal L, Abascal F, Canga A, et al. MR imaging of ankle impingement syndromes. *AJR Am J Roentgenol.* 2003;181(2), 551–9.
- Bureau NJ, Cardinal E, Hobden R, et al. Posterior ankle impingement syndrome: MR imaging findings in seven patients. *Radiology.* 2000;215(2):497–503.
- Robinson P, White LM. Soft-tissue and osseous impingement syndromes of the ankle: role of imaging in diagnosis and management. *Radiographics.* 22(6): 1457–69.
- Stieda L. Ueber secundäre fusswurzelknochen. *Arch Physiol Wissensch Med.* 1869:108–111.
- Niki H, Aoki H, Inokuchi S, et al. Development and reliability of a standard rating system for outcome measurement of foot and ankle disorders I: development of standard rating system. *J Orthop Sci.* 2005 Sep;10(5):457–465.
- Datir A, Connell D. Imaging of impingement lesions in the ankle. *Top Magn Reson Imag.* 2010;21:15–23.
- Russo A, Zappia M, Reginelli A. Ankle impingement: a review of multimodality imaging approach. *Musculoskelet Surg.* 2013;97:S161–S168.
- Lui HT. Arthroscopic management of posteromedial ankle impingement. *Arthrosc Tech.* 2015 Oct;4(5):e425–e427.
- Jones DM, Saltzman CL, El-Khoury G. The diagnosis of the os trigonum syndrome with a fluoroscopically controlled injection of local anesthetic. *Iowa Orthop J.* 1999;19:122–126.
- Dijk VN. Anterior and posterior ankle impingement. *Foot Ankle Clin.* 2006 Sep;11(3):663–683.
- Lee KB, Kim KH, Lee JJ. Posterior arthroscopic excision of bilateral posterior bony impingement syndrome of the ankle: a case report. *Knee Surg Sports Traumatol Arthrosc.* 2008 Apr;16(4):396–399.
- Zwiers M, Wiegerinck IJ, Murawski DC, Smyth AN, Kennedy JG, Dijk VN. Surgical treatment for posterior ankle impingement. *Arthrosc J Arthrosc Relat Surg.* 2013;29(No 7):1263–1270 (July).



# MAY THE SPORT OF LIFE NEVER STOP



Capital Equipment



Instruments



Implants



XYATA LIFESCIENCES LTD.  
HONG KONG  
www.xyata.hk



XYATA LIFESCIENCES PVT. LTD.  
INDIA  
www.xyata.in

*offers the highly specialized range*



## FOR OSTEOARTHRITIS MANAGEMENT

Cross Linked

**BIOVISC**  
**ORTHO SINGLE** PFS

Hyaluronic Acid Inj. 3ml (90mg / 3ml)

Optimum Volume, Sustained Effect

90 High Concentration HA

Cross-Linked

High Molecular Weight

**HYNEES**<sup>®</sup>  
PFS

Sodium Hyaluronate Inj. 2ml (10mg / ml)

For effective management of osteoarthritis

Non Avian Source

High Molecular Weight

## FOR OSTEOPOROSIS MANAGEMENT

Recombinant Human Parathyroid Hormone (1-34)

**ELEVOSTEO**<sup>®</sup>  
Teriparatide Injection (rDNA origin)

**ELEVATING OSTEOGENESIS**

Increases Bone Formation

Reduces Risk of Fractures

**ZOLVOID**<sup>®</sup>

Zoledronic Acid Infusion 5mg/100ml

The **GOLD STANDARD** in Osteoporosis Treatment

Once A Year Dose

Effective and Safe

# For Comprehensive Mobility Solutions

A WHO - GMP Certified Company

NATIONAL TOLL FREE HELPLINE: 1800 1111 55

An ISO : 9001 - 2008 Certified Company